

# The 'tuck-away' liver retraction technique: A safe, cost-effective strategy for hiatal exposure during pediatric laparoscopy

Original  
Article

Hesham M. Sheir<sup>a</sup>, Sherif Abdelmaksoud<sup>a</sup>, Sabina Siddiqui<sup>b</sup> and Tamer A. Wafa<sup>a</sup>

<sup>a</sup>Department of Pediatric Surgery, Mansoura Faculty of Medicine, Mansoura, Egypt,

<sup>b</sup>Arkansas Children's Northwest, University of Arkansas Medical Science, Springdale, Arkansas, United States of America.

## ABSTRACT

**Introduction:** Effective liver retraction is a crucial step in laparoscopic hiatal surgery, providing optimal exposure to the esophageal hiatus and esophagogastric junction. Various techniques have been developed to achieve adequate visualization, but many are associated with potential complications, including significant postoperative elevations in liver enzymes and more severe hepatic injuries such as lacerations, bleeding, and even liver necrosis. The 'tuck-away liver retraction' technique, which involves tucking the left lobe of the liver through a window in the falciform ligament, has been described as a safe alternative in single-port laparoscopic surgery. However, its application in standard laparoscopic procedures has not been extensively studied.

**Patients and Methods:** A retrospective review was conducted on 82 pediatric patients who underwent laparoscopic surgery for hiatal pathologies between January 2018 and December 2023. The 'tuck-away' liver retraction technique was employed in 9 cases where traditional retraction methods were insufficient due to large liver size or limited working space. Data on patient demographics, operative time, intraoperative complications, and postoperative liver enzyme levels were collected and analyzed.

**Results:** The 'tuck-away' liver retraction technique was successfully performed in 9 out of 10 (90%) cases. The mean operative time for the liver retraction procedure was 18±3.8 min. Minor liver abrasions were observed in 3 (33.3%) cases, managed effectively with cauterization. No major liver injuries, subcapsular hematomas, or significant postoperative liver enzyme elevations were reported, demonstrating the technique's safety and feasibility.

**Conclusion:** The 'tuck-away' liver retraction technique is a viable and safe alternative for liver retraction in laparoscopic hiatal surgery, particularly in challenging cases involving large livers or limited working space. Although technically demanding, this method offers excellent exposure with minimal risk of liver injury. Further studies with larger sample sizes are recommended to validate these findings and refine the technique's application.

**Key Words:** Fundoplication, laparoscopic, liver, retractor, tuck-away technique.

**Received:** 14 August 2024, **Accepted:** 12 September 2024, **Published:** 1 January 2025

**Corresponding Author:** Tamer A. Wafa, PhD, MRCS, Department of Pediatric Surgery, Mansoura Faculty of Medicine, Mansoura, Egypt. **Tel.:** +201005101415, **E-mail:** tamer\_ashraf@mans.edu.eg

**ISSN:** 1110-1121, January 2025, Vol. 44, No. 1: 288-292, © The Egyptian Journal of Surgery

## INTRODUCTION

Efficient liver retraction is a critical step in laparoscopic hiatal surgery to allow perfect exposure of the esophageal hiatus and the esophagogastric junction<sup>[1-3]</sup>. Several techniques for liver retraction were described to achieve a suitable surgical view and working space<sup>[4-6]</sup>. However, several studies have reported adverse effects on the liver, manifested as a significant postoperative rise in liver enzymes after laparoscopic surgery, raising concerns about potential hepatocellular injury<sup>[7,8]</sup>. More severe complications associated with liver retraction, such as major hepatic lacerations, bleeding, or even necrosis of the liver's left lobe, have also been documented<sup>[9-11]</sup>. A liver retraction technique involving tucking the liver into a window created in the falciform ligament has been described as an easy and safe alternative in single-port laparoscopic surgery<sup>[12]</sup>. Despite its potential advantages,

this technique has not been widely studied in standard laparoscopic procedures.

Since 2018, our institution has adopted the 'tuck-away liver retraction' technique as an alternative approach in selected cases of challenging hiatal surgeries, particularly when dealing with large livers or limited working space. This study aims to evaluate this liver retraction technique and provide a preliminary report on its feasibility and safety in our early cases.

## PATIENTS AND METHODS:

This is a retrospective study performed at Mansoura University Children Hospital by reviewing the records of the patients who underwent laparoscopic procedures for the upper abdomen during the period between January 2018 and December 2022. The study protocol was approved

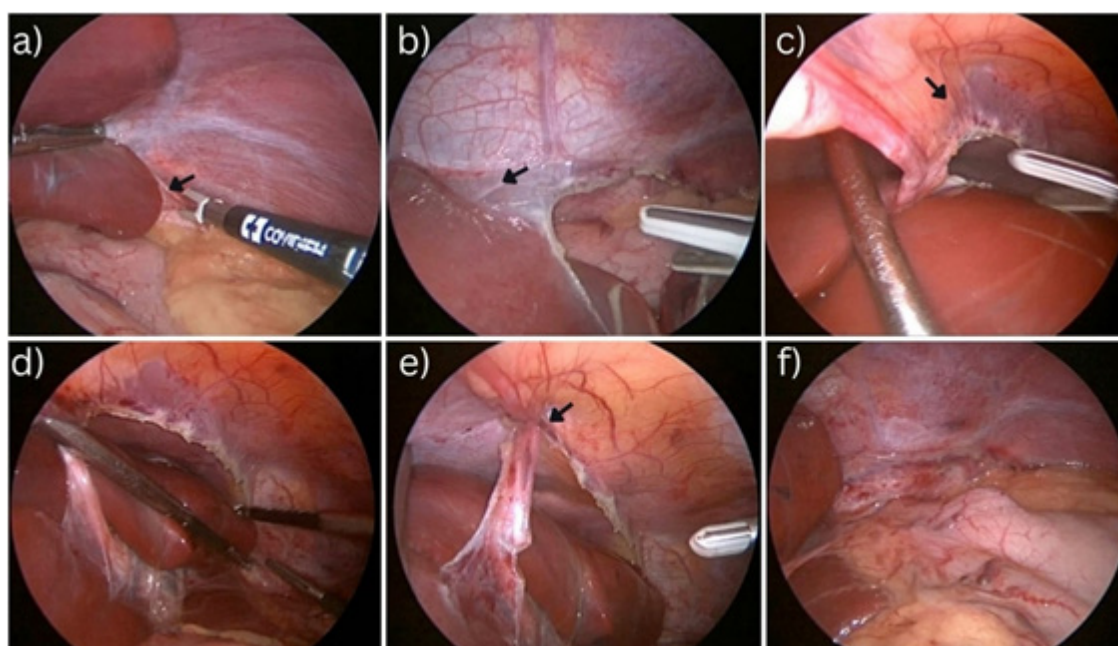
by the institutional review board. The selection of cases depended on the method of liver retraction performed by the laparoscopist and only the cases subjected to the ‘Tuck-away liver retraction’ technique were included in the study with the exclusion of cases that underwent other liver retraction techniques. The preoperative data of the selected cases was reviewed for age, sex, weight, type of laparoscopic intervention, preoperative alanine transaminase (ALT) and aspartate aminotransferase (AST). The operative time was calculated beginning from the division of the left triangular ligament till the liver was stabilized in the created window, and whether the technique succeeded or failed to achieve efficient liver retraction was reported. Any intraoperative or postoperative complications of the liver retraction technique were reported. Postoperative ALT and AST were reported if such data were available in the patients’ records.

### Statistical analysis

Testing for the normal distribution of data was done by using Shapiro–Wilki test of normality. Data were expressed as Mean±SD for quantitative parametric measures in addition to median and percentiles for quantitative nonparametric measures and both number and percentage for categorized data.

### Operative technique

A standard port placement is employed. Two working ports are positioned in the epigastrium, with an additional left hypogastric port designated for stomach retraction. The procedure begins with the division of the left triangular ligament of the liver, using either hook diathermy in smaller children or a bipolar energy device. The dissection is carefully extended toward the hepatic veins, ensuring the entire ligament is severed. Next, a window is created in the falciform ligament, which is then widened along its entire length. The left lobe of the liver is gently manipulated with two instruments, flipping it through the window in the falciform ligament to the right side. This delicate step requires precise and gentle handling to avoid liver injury. Once positioned, the left lobe is tucked beneath the abdominal wall, resting above the right hepatic lobe. To secure the liver in place, a hitch stitch is inserted through the midline epigastric abdominal wall under laparoscopic guidance, encircling the ligamentum teres. This suture prevents the liver from slipping, leaving the left hemidiaphragm fully exposed and allowing for the completion of the required hiatal procedure. After the surgery, the left lobe is carefully returned to its original position (Fig. 1).



**Fig. 1:** a) The left hepatic ligament is divided (arrow), b) The left hepatic ligament division is extended till the hepatic veins (arrow), c) A window is created in the falciform ligament (arrow) throughout its entire length, d) The left lobe of the liver is flipped over through the window in the falciform ligament, e) A hitch stitch is passed through the abdominal wall and the ligamentum teres to retain the liver in place, f) The final excellent exposure of the hiatal area.

**RESULTS:**

Between January 2018 and December 2023, 82 patients underwent laparoscopic surgery for hiatal pathologies, including gastroesophageal reflux disease and hiatal hernia. Among these, the 'Tuck-away' liver retraction technique was successfully employed in 10 cases, out of which 9 were successful. The cohort consisted of five females and four males, with ages ranging from 13 months to 4 years, and a mean age of  $27.5 \pm 11.9$  months. Their body weight ranged from 7.3 to 18.5 kg, with a mean of 10 kg. The liver retraction technique was used as part of the laparoscopic management for gastroesophageal reflux disease in 3 (33.3%) cases and for hiatal hernia in 6 (66.6%) cases, including three recurrent hiatal hernias. In one patient, the technique was unsuccessful due to the failure to retain the liver lobe in place hence, another technique was applied

(Crural Stitch). This makes the success rate in our series to be 90% (Table 1).

The operative time for the liver retraction technique ranged from 11 to 23 min, with a mean of  $18 \pm 3.8$  min. Minor liver abrasions were observed in 3 (33.3%) cases; two of these were managed by cauterizing the abrasion edges, while the third abrasion was trivial and required no intervention. No significant liver damage or subcapsular hematoma was reported (Table 2). Preoperative liver enzyme levels (ALT and AST) were within normal limits in all cases. Postoperative liver enzyme data were available for 5 cases, with slight elevations reported in 3 (60%) cases ranging from 2 to 2.5 folds. It was recorded on the first postoperative day and repeated on the first follow-up after 1 week. All patients had normal liver functions on follow-up.

**Table 1:** Patient's age, sex, body weight, and indication for surgery

Patient	Age	Weight	Sex	Indication	Operative time	Liver enzymes
1	2 year	11.1	f	GERD	16 min	
2	13 month	7.3	f	HH	18 min	
3	18 month	8.2	m	HH	23 min	
4	2 year 5 month	13.7	m	Recurrent HH	21 min	
5	3 year 10 month	15.2	f	Recurrent HH	22 min	Elevated
6	2 year	8.8	f	GERD+CP	15 min	Normal
7	4 year	18.5	f	Recurrent HH	24 min	Elevated
8	24 month	10 kg	m	HH	20 min	Elevated
9	1y10 month	9	m	GERD	11 min	Normal

**Table 2:** Operative and postoperative complications

Complications	Number (Percentage)
Liver abrasions	3/9 (33.3)
Liver Damage	0
Liver Enzymes Elevation	3/5 (60)
Failed	1/10 (10)

**DISCUSSION**

During laparoscopic procedures targeting upper abdominal organs such as the gallbladder, stomach, and esophagus, effective upward retraction of the liver is often necessary. Traditionally, this is achieved using external liver retractors, which are inserted through laparoscopic ports or small abdominal incisions. Common tools include the fan retractor, snake retractor, and Nathanson liver retractor<sup>[13,14]</sup>. Alternative techniques have also been developed to avoid the need for standard retractors. These include the Endolift retractor, liver suspension tape, vacuum-assisted retraction, and various dissection and suturing methods, all designed to displace the liver out of the operative field<sup>[15-18]</sup>.

In this study, the 'Tuck-away' liver retraction technique was selectively employed in difficult cases, such as those with a large liver, limited working space, or recurrent hiatal hernia, where standard retraction techniques were inadequate. Originally described by Surjan *et al.* in single-port laparoscopic surgery, this technique has been recommended for use in standard laparoscopic procedures<sup>[12]</sup>. Yet, to the best of our knowledge, no other studies examined the feasibility of the technique during standard laparoscopic procedures.

Liver retraction during upper abdominal laparoscopic procedures carries a risk of liver injury. Compression and entrapment of liver tissue by retractors can lead to venous congestion and minor injuries, often indicated by transient elevations in liver enzymes, particularly AST<sup>[9,19]</sup>. Mazahreh *et al.* reported significantly higher postoperative levels of ALT and AST in patients who underwent laparoscopic cholecystectomy, a change possibly linked to the effects of pneumoperitoneum and increased intra-abdominal pressure on hepatic blood flow<sup>[8,20]</sup>.

Morris-Stiff and colleagues found that AST levels following laparoscopic fundoplication were

significantly elevated, peaking at 8.7 times the baseline at 72 h postsurgery. This rise was attributed to the degree of liver retraction and the use of the Nathanson retractor. They also noted that AST levels were higher after laparoscopic Nissen fundoplication than after laparoscopic cholecystectomy, likely due to the more intensive liver retraction required<sup>[19]</sup>. In the current study, where no instrumental liver retraction was used, postoperative liver enzyme data were available for five patients. Of these, two exhibited slight enzyme elevations (2–2.5 times baseline) 24 h postoperatively. Enzyme levels returned to normal in all patients by the next follow-up visit, 1 week later.

While minor liver injuries are relatively common during laparoscopic liver retraction, more severe injuries can also occur, though they are less frequent. These injuries often manifest as parenchymal fractures or tears caused by direct contact with the retractor blade<sup>[19]</sup>. There have even been case reports of liver necrosis and acute liver failure related to laparoscopic traction injuries<sup>[9,10]</sup>. In this study, the ‘Tuck-Away’ liver retraction technique was used, and no major liver damage was reported. Minor abrasions occurred in three cases, all of which were easily managed. This outcome aligns with Surjan *et al.*’s predictions regarding the technique’s potential to reduce the risk of liver injury<sup>[12]</sup>.

However, our experience leads us to partially disagree with Surjan and colleagues’ assertion that this technique is fast, simple, and does not require specialized skills. We found it to be quite demanding, requiring advanced laparoscopic expertise. As a result, we do not recommend it as a routine liver retraction method. In our study, we applied this technique in only 10 out of 82 cases. The operative time needed to achieve adequate liver retraction ranged from 11 to 24 min (mean 18±3.8 min), with one case where the technique failed to provide sufficient retraction. Surjan *et al.* did not report any data regarding operative time or the potential for failure<sup>[12]</sup>. Finally, we found this technique a good alternative that can be added to the armamentarium of laparoscopic surgery, particularly in complex cases with large liver or recurrent cases with severe adhesions around the hiatus.

## CONCLUSION

The ‘tuck-away’ liver retraction technique is a viable and safe alternative for liver retraction in laparoscopic hiatal surgery, particularly in challenging cases involving large livers or limited working space. Although technically demanding, this method offers excellent exposure with minimal risk of liver injury. Further studies with larger sample sizes are recommended to validate these findings and refine the technique’s application.

## CONFLICT OF INTEREST

There are no conflicts of interest.

## REFERENCES

- Galvani CA, Choh M, Gorodner MW. Single-incision sleeve gastrectomy using a novel technique for liver retraction during single-port laparoscopic surgery. *J Laparoendosc Adv Surg Tech A* 2014; 24:35–37.
- Genser L, Torcivia A, Saget A, Vaillant JC, Siksik JC. Minimal invasive internal liver retractor in conventional and trans-umbilical single-incision laparoscopic sleeve gastrectomy: Video report. *Obes Surg* 2016; 26:704–705.
- Midya S, Ramus J, Hakim A, Jones G, Sampson M. Comparison of two types liver retractors in laparoscopic Roux-en-Y gastric bypass for morbid obesity. *Obes Surg* 2020; 30:233–237.
- Nathanson LK, Cuschieri A. The falciform lift: a simple method for retraction of the falciform ligament during laparoscopic cholecystectomy. *Surg Endosc* 1990; 4:186.
- Sweeny A, Buglino L, La Vella E, Yarbrough D. Comparison of a novel trocar-free internal liver retractor to standard liver retraction in bariatric surgery. *Obes Surg* 2019; 29:3071–3075.
- Hatao F, Imamura K, Ishibashi Y, Kawasaki K, Yamazaki R, Morita Y. Liver retraction using an L-shaped retractor during sleeve gastrectomy. *Surg Today* 2022; 52:574–579.
- Tan M, Xu FF, Peng JS, Li DM, Chen LH, Lv BJ, *et al.* Changes in the level of serum liver enzymes after laparoscopic surgery. *World J Gastroenterol* 2003; 9:364–367.
- Mazahreh TS, Aleshawi AJ, Al-Zoubi NA, Altabari M, Aljarrah Q. Comparison of postoperative liver function between different dissection techniques during laparoscopic cholecystectomy. *Future Sci OA* 2020; 6:4.
- Tamhankar AP, Kelty CJ, Jacob G. Retraction-related liver lobe necrosis after laparoscopic gastric surgery. *JLS* 2011; 15:117–121.
- Nozaki T, Kato T, Komiya A, Fuse H. Retraction-related acute liver failure after urological laparoscopic surgery. *Curr Urol* 2013; 7:199–203.

11. Antsaklis GI, Karanikas ID, Sakellaridis TE, Alexiou CP, Konstantinidou E, Economou N. Subcapsular hematoma of the liver: a rare complication of laparoscopic cholecystectomy. *Minerva Chir* 2009; 64: 322–323.
12. Surjan R, Makdissi FF, Machado MA. A new technique for liver retraction during single-port laparoscopic surgery. *J Laparoendosc Adv Surg Tech* 2014; 24:35–37.
13. Kinjo Y, Okabe H, Obama K, Tsunoda S, Tanaka E, Sakai Y. Elevation of liver function tests after laparoscopic gastrotomy using a Nathanson liver retractors. *World J Surg* 2011; 35:2730–2738.
14. Gan P, Bingham J. A clinical study of the LiVac liver retractor system. *Surg Endosc* 2016; 30:789–796.
15. Elazary R, Kedar A, Shussman N, Abu-Gazala M, Khalaileh A, Faroja M, *et al.* A novel totally internal laparoscopic liver retractor. *Surg Laparosc Endosc Percutan Tech* 2013; 23:e222–e224.
16. Zachariah SK, Tai C-M, Chang P-C, Se A-O, Huang C-K. The ‘T-suspension tape’ for liver and gallbladder retraction in bariatric surgery: feasibility, technique, and initial experience. *J Laparoendosc Adv Surg Tech A* 2013; 23:311–315.
17. Benzing C, Krenzien F, Junghans T, Both C, Pratschke J, Zorron R. Intraabdominal trocar-free vacuum liver retractor for laparoscopic sleeve gastrectomy (video). *Obes Surg* 2016; 26:1654–1655.
18. de la Torre R, Scott JS, Cole E. A suture-based liver retraction method for laparoscopic bariatric procedures: results from a large case series. *Surg Obes Relat Dis* 2015; 11:1377–1382.
19. Morris-Stiff G, Jones R, Mitchell S, Barton K, Hassn A. Retraction transaminitis: an inevitable but benign complication of laparoscopic fundoplication. *World J Surg.* 2008; 32:2650–2654.
20. Al-Jaberi TM, Tolba MF, Dwaba M, Hafiz M. Liver function disturbances following laparoscopic cholecystectomy: incidence and significance. *J Laparoendosc Adv Surg Tech A* 2002; 12:407–410.