

INTRA-OPERATIVE FROZEN SECTION FOR THE DISTAL RESECTION MARGIN: A PREREQUISITE FOR SAFE SPHINCTER SAVING SURGERY FOR MIDDLE AND LOWER THIRD RECTAL CANCERS

By

El-Hennawy MM, M.D., Moussa ME, M.D., El-Khishen MA, M.D., El-Saeidy MK, M.D., Shawky AM, M.D., Bassiouni AE, M.D., El-Dieb OA, M.D., El-Kayal EA, M.D., Bessa SS, M.D. and Badour NE, M.D.

The Departments of General Surgery and Pathology, Faculty of Medicine, Alexandria University, Alexandria, Egypt.

Sphincter-saving operations have become the treatment of choice for cancers of the lower thirds of the rectum. Any effort to ensure the safety of these procedures is commendable.

Aim: the aim of the present study is to evaluate the role of intra-operative frozen section in the management of cancers of the extraperitoneal rectum by restorative resection.

Patients & methods: 12 patients with operable middle & lower thirds rectal cancers were included in the present study. Sphincter preservation and restoration of bowel continuity after total mesorectal excision was attempted in all patients. Frozen section of the distal resection margin was performed prior to restoration of bowel continuity.

Results: In 9 patients the distal safety margin was 2 centimeters or more. In 7 of these patients, the distal resection margin was free of malignancy and intestinal continuity was restored. In 2 patients, the 2 centimeters distal resection margin was positive for malignancy. An extra-centimeter was taken which proved to be negative for malignancy thus allowing for restoration of bowel continuity in both patients. In the remaining 3 patients, the distal safety margin was 1 centimeter. In 1 of these patients, frozen section revealed that the distal resection margin was infiltrated by malignancy. In this patient, low anterior resection was abandoned in favour of abdominoperineal resection.

Conclusion: Frozen section has saved 3 patients from leaving residual tumour behind and thus from possible recurrence. Furthermore, frozen section has altered the therapeutic approach in 1 patient. Based upon these findings, it is felt that frozen section is highly indicated in all patients undergoing restorative resection especially when a distal resection margin of only 1 centimeter could be achieved.

Keywords: Rectal adenocarcinoma- Frozen section-Distal intramural spread- Low anterior resection.

INTRODUCTION

The shift from abdominoperineal resection to low anterior resection in the management of extraperitoneal cancers of the rectum has been the most dramatic change in the therapeutic approach to this aggressive disease over the past two decades. Such a change would have not been possible without the appreciation that a 5-centimeter distal safety margin was not necessary in all cases. The reduction of the distal safety margin to 2 centimeters or even less has

allowed for sphincter preservation. Most of the data on the adequacy of this new distal margin have been obtained from pathological or retrospective studies (1,2). A study that could assess the adequacy of this margin in a prospective manner using the frozen section technique would probably be useful.

Aim of the work:

The aim of the present study is to evaluate the role of

intra-operative frozen section (IFS) in assessing the clearance of the distal resection margin in middle and lower third rectal cancer patients treated by total mesorectal excision and sphincter saving surgery.

PATIENTS AND METHODS

The present study included 12 patients admitted to the surgical unit "C" at Alexandria Main University hospital with histopathologically proven adenocarcinoma of the extra-peritoneal rectum.

In all patients, a rigid proctoscope was used to measure the height of the tumour from the anal verge. The rectum was divided from 0-7 centimeters (i.e. lower third) and from 8-11 centimeters (i.e. middle third). Patients with tumours located more than 11 centimeters from the anal verge were excluded from the present study. All patients underwent endorectal ultrasonography to confirm that the lesion was confined to the bowel wall. Abdominopelvic C.T. scanning and chest X-ray were also performed in all patients to exclude distant metastases.

Low anterior resection with total mesorectal excision was the operative technique adopted in the present study^(3,4). Full rectal mobilization down to the level of the levators was insisted upon in every case. The extent of caudal dissection was not dictated by the level of the tumour but rather by the completeness of mesorectal excision. However the distal tail of the mesorectum was not trimmed off the back of the muscle tube. The site of bowel division was always 1 centimeter above or at the levator plane. When a stapled anastomosis was technically possible, the triple stapling technique was used⁽⁵⁾. To describe in short, a TA55 (AutoSuture, Ascot, UK) linear stapler was placed across the rectum at the site chosen for bowel division and fired. The gun was unlocked and removed leaving an occlusive row of staples across the rectum distal to the tumour. The rectum was then irrigated with half strength 4% Povidone-iodine⁽⁶⁾. A further cartridge was loaded on the TA55 gun, which was then reapplied across the cleansed rectum distal to the proximal occlusion staple line and fired. In cases where the pelvis was narrow, a roticulator (Ethicon, United States) was used. The rectum was then sectioned above the TA55 stapler gun (or the roticulator) and the completely sealed specimen was then sent for frozen section to detect whether the distal resection margin was infiltrated by malignant cells or not. When frozen section confirmed that the distal resection margin was free of malignancy, the standard double stapling technique was used to effect the anastomosis. In case of a dentate line resection, after full abdominal mobilization of the rectum, the perineal surgeon completed the excision transanally. The colon was then delivered to the perineal surgeon and a hand-sewn

interrupted single layer anastomosis was performed i.e. a hand-sewn transanal coloanal anastomosis⁽⁷⁾.

When frozen section revealed that the distal margin of resection was infiltrated by malignancy, a further 1-centimeter was taken (if possible) and sent for frozen section. If that proved to be technically impossible, the anal canal was widely excised from below i.e. abdominoperineal resection was performed.

The distal safety margin was defined as "the distance between the lower edge of the tumour and the distal resection margin as measured in the fresh unpinned specimen".

The technique of frozen section:

After submitting the specimen, the distal surgical resection margin was biopsied at a thickness of about 4 mm and divided into 3 segments to facilitate the placement on the special grids used for frozen section. Extreme caution was exercised during placing the specimens on the grid so that the actual distal margin is the one facing the microtome knife. The findings on frozen section were further confirmed by paraffin section on the final evaluation.

RESULTS

The present study included 12 patients. They were 7 females and 5 males. Their age ranged from 25-76 years with a mean of 55 years.

Six patients had middle third rectal cancer one of whom had cancer developing on top of ulcerative colitis while 6 had lower third cancers. All patients had operable cancers confined to the bowel wall with no evidence of distant metastases on preoperative evaluation. The patient characteristics are illustrated in (Table 1).

For all middle third rectal cancers, the distal resection margin ranged in length from 2-4 centimeters. Frozen section revealed that this margin was free of malignancy in 5 patients. In the sixth patient, however, frozen section revealed that the distal safety margin of 2 centimeters showed questionable glandular dysplastic changes mandating the take of an extra-centimeter. This extra-centimeter proved to be free on histological examination. In the 6 patients with lower third rectal cancers, the distal safety margin was 2 centimeters in 3 patients and 1 centimeter in the remaining 3 patients. Frozen section revealed that the distal resection margin was free of malignant infiltration in 2 of the 3 patients with a distal safety margin of 2 centimeters. In the third patient a stapled anastomosis was effected and the doughnut was sent for frozen section. This doughnut proved to be free of malignancy and thus restoration of bowel continuity was

successful. Furthermore, in 1 of the 3 patients with a distal safety margin of 1 centimeter, frozen section revealed that the distal resection margin was infiltrated by malignancy. Figure 1. Since the line of bowel transection in this patient was at the dentate line, low anterior resection was abandoned in favour of abdominoperineal resection.

preservation. The sphincter saving operations performed in these patients were: low anterior resection in 10 patients and total proctocolectomy and an ileal pouch-anal anastomosis for a cancer developing on top of ulcerative colitis in one patient. In 6 of these 10 patients a covering ileostomy was also constructed.

To sum up, 11 of the 12 patients underwent sphincter

Table (1): The characteristics of the 12 patients included in the present Study.

No.	Age	Sex	Locati-on in the rectum	Leugt-h of dsm	Infiltr-ated Drm	Ifiltrated lrm	Dukes stage	Number of ln	Degree of differentiation
1	60	female	Lower	1 cm	No	No	C	14	Well
2	30	female	Lower	1 cm	Yes	No	C	14	Well
3	55	female	Lower	1 cm	No	No	C	12	Well
4	68	female	Lower	2 cm	No	No	A	0	Well
5	45	male	Lower	2 cm	No	No	C	5	mucoid
6	60	male	Lower	2 cm	No	No	A	0	Well
7	25	female	Middle	3 cm	No	No	C	17	mucoid
8	35	female	Middle	4 cm	No	No	A	0	Well
9	28	male	Middle	3 cm	No	No	A	0	Poor
10	60	female	Middle	4 cm	No	No	A	0	Moderate
11	60	male	Middle	4 cm	No	No	A	0	Moderate
12	76	male	Middle	3 cm	No	No	A	0	Moderate

DSM: Distal Safety Margin.
DRM: Distal Resection Margin.

LRM: Lateral Resection Margin
LN: Lymph Nodes.

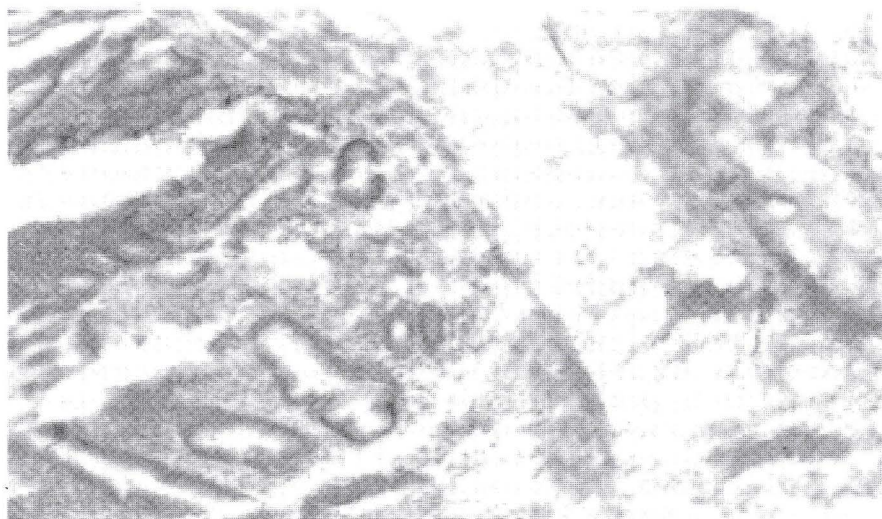


Fig. (1)

DISCUSSION

Throughout the last century, abdominoperineal resection has dominated the surgical management of rectal cancer. However, over the past two decades, there has been increasing interest in the application of surgical procedures that adequately resect rectal cancer and preserve fecal continence⁽⁸⁾. This change in therapeutic philosophy has been attributed to many factors namely; a better understanding of the mode of spread of rectal cancer, an improved understanding of the mechanisms underlying fecal continence and the introduction of the circular intraluminal staplers⁽⁸⁻¹⁰⁾. It was not surprising, therefore, that curative anterior resection has replaced abdominoperineal resection as the treatment of choice for most rectal cancers^(11,12).

The abandonment of the 5-centimeter rule of distal clearance has probably been the most significant factor underlying this dramatic change in therapeutic philosophy. The idea that a wide margin of apparently normal bowel should be resected distal to a rectal carcinoma originated from the early reports by Handley in 1910 and Cole in 1913^(13,14). Each reported a single case of extensive microscopic intramural spread distal to the macroscopic margin of the primary growth. In 1954, Grinnel found evidence of distal intramural spread in 12% of 76 potentially curative rectal carcinomas, the greatest distance of such spread being 4 centimeters⁽¹⁵⁾. He thus strongly advised that a margin of at least 5 centimeters of grossly normal bowel beyond the growth should always be insisted upon in a curative resection operation⁽¹⁵⁾. It was the observations of these workers that founded the basis of what became to be known as the "5 centimeters rule" of distal clearance. Since Goligher et al recommended that 5 centimeters distal to the primary tumour should be regarded as the "safe distance", this has subsequently become the "orthodox" safe margin and became widely known to the surgical community as the "5 centimeter rule" of distal clearance^(16,17).

On the other hand and as early as 1920 and again in 1931, Miles concluded that intramural spread was always trivial⁽¹⁷⁾. Others have reported similar findings^(18,19). In 1983 Williams et al studied the extent of distal intramural spread in 50 abdominoperineal excision specimens. They found that 90% of the patients either had no distal intramural spread whatsoever, or a spread of 1 centimeter or less. The remaining 10% of patients had spread of more than 1 centimeter. Those patients had a poorly differentiated Duke C lesion and each was dead or dying from distant metastases within 3 years of operation, despite the fact that rectal excision had been performed with a minimum of 5 centimeters of distal clearance (1). This fact was further confirmed by Pollet and Nicholls who reviewed the

literature and were unable to find any case with distal spread greater than 1.5 centimeters with survival over 5 years even when treated by total rectal excision⁽²⁾. It has been confirmed that a distal margin of 2 centimeters was adequate clearance to almost all operable rectal cancers. The results of the present study is not in total agreement with these studies. Frozen section of the distal resection margin revealed that this margin was free of malignancy in all but 2 patients where a distal safety margin of 2 centimeters could be achieved. In one of these 2 patients the take of an extra-centimeter was technically possible and in the other the stapled anastomosis was effected and the doughnut was considered to be an extra-centimeter added to this margin. Frozen section revealed that both extra-centimeters were free of malignancy thus allowing for safe restoration of bowel continuity.

Furthermore, Madsen and Christiansen have even concluded that all potentially curable carcinomas could be resected adequately with a distal margin of only 1.5 centimeters⁽²⁰⁾. Karanjia et al coined the term "close shave" to describe these operations in which the distal safety margin was 1 centimeter or less⁽²¹⁾. The results of the present study are not in total agreement with those observations. In 1 of 3 patients frozen section has revealed that a distal safety margin of 1 centimeters was not adequate clearance for this patient. Intra-operative frozen section has revealed malignant infiltration of the distal resection margin in this patient. As the line of bowel transection was at the level of the dentate line, no distal safety margin could be achieved except by excising the anal canal. In this patient frozen section has saved the patient from leaving malignant cells behind and has altered the surgeon's therapeutic approach i.e. abandoning low anterior resection in favour of abdominoperineal resection despite the technical possibility of restoring intestinal continuity.

In the present study, neither the degree of tumour differentiation nor the presence of a mucoid component have been of any predictive value of the status of the distal resection margin. Since the Dukes stage can only be verified after pathological evaluation of the resected specimen, it can be of no predictive value as well. In absence of any preoperative clue to the status of the distal resection margin, it is felt that a frozen section is highly indicated in those patients where the distal resection margin has to be 1 centimeter in order to preserve the anal sphincters. Intra-operative frozen section allows for an oncologically safe anastomosis in such conditions by verifying that the distal resection margin is free of malignancy. Through this policy it is hoped that local recurrence can be further reduced and that restorative resection can be a much safer procedure. A later report on the long-term follow-up of these patients will be presented in the future.

REFERENCES

1. Williams NS, Dixon MF, Johnston D. Reappraisal of the 5-centimeter rule of distal excision for carcinoma of the rectum: a study of distal intramural spread and of patient's survival. *Br J Surg* 1983; 70: 150-154.
2. Pollet WG, Nicholls RJ. The relationship between the extent of distal clearance and survival and local recurrence rates after curative anterior resection for carcinoma of the rectum. *Ann Surg* 1983; 198(2): 159-163.
3. Heald RJ, Husband EM, Ryall RDH. The mesorectum in rectal cancer surgery-the clue to pelvic recurrence. *Br J Surg* 1982; 69: 613-616.
4. Heald RJ. The "Holy Plane" of rectal surgery. *J R Soc Med* 1988; 81: 503-508.
5. Moran BJ, Docherty A, Finnis D. Novel stapling technique to facilitate low anterior resection for rectal cancer. *Br J Surg* 1994; 81: 1230.
6. Hill GL, Rafique M. Extrafascial excision of the rectum for rectal cancer. *Br J Surg* 1998; 85:809-812.
7. Parks AG. Peranal anastomosis. *World J Surg* 1982; 6: 531-538.
8. Yeatman TJ, Bland KI. Sphincter saving procedures for distal carcinoma of the rectum. *Ann Surg* 1989; 209: 1-19.
9. Williams NS. The rationale for preservation of the anal sphincter in patients with low rectal cancer. *Br J Surg* 1984; 71: 575-581.
10. Lane RHS, Parks AG. Function of the anal sphincters following colo-anal anastomosis. *Br J Surg* 1977; 64: 596-599.
11. Heald RJ et al. Abdomino-perineal excision of the rectum-An endangered operation. *Dis Colon Rectum* 1997; 40: 747-751.
12. Kirwan WO, O'Riordain MG, Waldron R. Declining indication for abdomino-perineal resection. *Br J Surg* 1989; 76: 1061-1063.
13. Handley Ws. The surgery of the lymphatic system. *Br Med J* 1910; 1:922-928.
14. Cole PP. The intramural spread of rectal carcinoma. *Br Med J* 1913; 1: 431-433.
15. Grinnell RS. Distal intramural spread of the rectum and rectosigmoid. *Surg Gynecol Obstet* 1954; 99: 421-430.
16. Goligher JC, Dukes CE, Bussey HJR. Local recurrence after sphincter saving excisions for carcinoma of the rectum and rectosigmoid. *Br J Surg* 1951; 39: 199-211.
17. Goligher JC. Incidence and pathology of carcinoma of the colon and rectum. In: Goligher JC, (ed.). *Surgery of the Anus, Rectum and Colon*, 3rd Ed. London: Bailliere Tindall, 1975; 481-518.
18. Black WA, Waugh JM. The intramural spread of carcinoma of the descending colon, sigmoid and rectosigmoid; a pathologic study. *Surg Gynecol Obstet* 1948; 87:457-464.
19. Quer EA, Dahlin DC, Mayo CW. Retrograde intramural spread of carcinoma of the rectum and rectosigmoid; a microscopic study. *Surg Gynecol Obstet* 1953; 96: 24-30.
20. Madsen PM, Christiansen J. Distal intramural spread of rectal carcinoma. *Dis Colon Rectum* 1986; 29: 279-282.
21. Karanija ND, Schache DJ, North LORS, Heald RJ. "Close shave" in anterior resection. *Br J Surg* 1990; 77: 510-512.