

Covered endovascular reconstruction of aortic bifurcation, early and mid-term outcomes: A retrospective study

Original
Article

Samir A. Zied, Mahmoud Nasser and Mohamed Ali

Department of Vascular Surgery, Faculty of Medicine, Cairo University, Giza, Egypt.

ABSTRACT

Introduction: Atherosclerotic peripheral vascular disease is a leading cause of limb loss with a subsequent disability, inflow problem can be managed by different surgical and endovascular methods with variable outcomes, the extent of the lesion, and resource availability might affect the surgeon's decision regarding modality selection for treatment.

Aim: To evaluate the feasibility and effectiveness of covered stent graft in patient with inflow problems as rather new modality of treatment with mid-term follow-up.

Patients and Methods: The single center retrospective study included all patients treated with covered endovascular reconstruction of aortic bifurcation in the period from February 2018 to February 2022 with Trans-Atlantic Inter-Society Consensus (TASC) C and D treated with this modality and follow-up of 18 months was rolled in.

Results: A total of 23 patients, 18 male and five females average age 63.7 ± 7 years, type II diabetes in 91%, hypertension 78%, dyslipidemia 69%, COPD 22%, and smoking 13%, presenting symptom was incapacitation claudication in 56% and critical limb ischemia in 44%, preoperative imaging showed aorto-iliac disease TASC C in 39% while TASC D in 61%, technical success in 100%, no immediate intraoperative complication, primary patency rate was 87% at 24 months, secondary patency rate was 95%. Two (9%) patients underwent re-intervention for unilateral external iliac occlusion and common femoral tight stenosis with decreasing walking distance and another one patient with unilateral occluded iliac stent managed conservatively.

Conclusion: Covered endovascular reconstruction of aortic bifurcation in selective patient's population gives good results with a low rate of complications and need for re-interventions, the high cost of this modality will be always a limiting factor despite of expected superiority over the permetal stents, larger multi-center randomized controlled studies are needed for better evaluation of this technique competed to surgical reconstruction and other endovascular techniques.

Key Words: Aorto-iliac disease, covered stent graft, endovascular, instent stenosis, peripheral vascular disease.

Received: 14 September 2024, **Accepted:** 1 October 2024, **Published:** 1 January 2025

Corresponding Author: Mohamed Ali, MD, Department of Vascular Surgery, Faculty of Medicine, Cairo University, Giza, Egypt. **Tel.:** 00201001174955, **E-mail:** mohamed.abdelfattah@kasralainy.edu.eg

ISSN: 1110-1121, January 2025, Vol. 44, No. 1: 466-473, © The Egyptian Journal of Surgery

INTRODUCTION

Aortoiliac occlusive disease (AIOD) is a frequently seen in clinical practice and is considered as one of the main causes of disabling limb claudication and possibly critical limb ischemia. AIOD presents a quite challenging pathologic process especially in patients with multiple comorbidities, making decisions between aorto bi-femoral (ABF) bypass and endovascular treatment relatively difficult^[1,2].

ABF bypass was considered the 'gold standard' treatment of AIOD, with accepted long-term patency rates and associated perioperative morbidity and mortality^[3].

During the past few decades, endovascular techniques have shown marvelous evolution. It is started to be the primary choice for the management of Trans-Atlantic Inter-Society Consensus (TASC) A and B aortoiliac

lesions by many physicians. With recent advances and rapidly growing experience, a more complex lesions in TASC C and D lesions are being treated with endovascular techniques^[2,4].

In a systematic review of 1711 patients undergoing endovascular treatment of extensive AIOD showed a 5-year primary patency rate of 60–86%.¹ Moreover, by the means of covered stents, covered endovascular reconstruction of aortic bifurcation (CERAB) can mimic both the physiology and anatomy of the aortic bifurcation, thus overcoming the disadvantages related to a bare metal kissing stents such as blood flow turbulence that might represent a major underlining causes of initiating intimal hyperplasia^[5,6].

According to previously published studies, CERAB can guarantee a satisfactory primary and secondary patency rate during 2 years follow-up reaching to 87 and

95%, respectively^[7]. Moreover, CERAB seems to be more suitable treatment option when compared with ABF for treating high-risk patients with AIOD being associated with lower complications rate^[8].

PATIENTS AND METHODS:

A retrospective study on 23 patients who presented to Kasralainy Hospitals, Cairo, Egypt, and Dr. Soliman Faqeeh Hospital, Jeddah, Saudi Arabia with aorto-iliac occlusive diseases and indicated for treatment according to the guidelines, this study was conducted from February 2018 to February 2022.

Patients with limb ischemia with Rutherford classification 3–5 and preoperative investigations showed Aorto-iliac occlusive disease with TASC C and D were enrolled in the current study. However, patients with juxtarenal block, supra-renal involvement (visceral segment of the aorta), associated aortic aneurysm, aortic co-arcitation and patients who refused interventions were excluded from this study.

All patients underwent full physical examination, laboratory assessment, arterial duplex and computed tomography to fully address the extend of the disease, comorbidities and confirm indication for intervention.

All patient with TASC C and D with or without outflow disease were included.

The demographic data, co-morbidities, presenting symptoms, radiological type and classification of the lesions, details of the intervention for each patient, completion angiography, intervention related complication, follow-up finding, and any re-interventions were documented for further evaluation.

Informed consent was taken from all the patients explaining the treatment options, intervention details, and expected outcome and complications.

All data collected and analyzed using SPSS statistical analysis package version 26 (IBM, Armonk, New York, USA).

Technique

All patients were advised to take oral activated charcoal chewable tablets all through the day before the intervention and to avoid oral intake of milk and/or other milk products to decrease the bowel gases as much as possible thus facilitate obtaining better angiographic images.

All patients were transferred to (Toshiba INFINIX 8000 C) machines catheter labs. After local anesthesia, we used ultrasound-guided (9-MHz linear probe, CHISION SonoEye P5; Wuxi, Jiangsu, China).

All patients were loaded with Clopidogrel (300 mg) and bilateral retrograde femoral accesses were used as a standard access with an adjunctive brachial access.

The 8-F end-hole introducer sheath for the femoral accesses was used while the 6-F end-hole long sheath (Radifocus; Terumo, Tokyo, Japan) was advanced through the brachial access. After obtaining access, patients were anticoagulated with a 5000-unit bolus of intravenous unfractionated heparin.

Ultravist (Bayer Healthcare, Leverkusen, Germany) was used as a contrast medium for image acquisition during the endovascular intervention. In patients with impaired kidney functions, The CO₂ guided endovascular procedure was done with the aid of automated injector system (Angiodroid, Italy).

A 6 Fr pigtail catheter was introduced through the brachial access. Injection of contrast through this catheter in combination with retrograde injection could be used for obtaining a better visualized angiographic image.

We used J-shaped tip standard and stiff 0.035 Terumo wire (Radifocus; Terumo, Tokyo, Japan) or V-18 standard wire (Watertown, Massachusetts, United States) with supporting catheter Trail-Blazer (Medtronic, Dublin, Ireland) or Renegade (Watertown, Massachusetts, US) to achieve guidance of the wire though the lesion.

After lesion crossing, predilatation of the aortic segment of the lesion was achieved by using Armada balloon (Abbott medical, Lake Bluff, Illinois, US) with 6 mm diameter and 80 mm length at an inflation pressure ranging between 6 and 12 atm pressure. Then two Armada balloons used to predilate both iliac arteries by kissing technique.

After predilation, two 9F introducer sheaths were inserted above the proximal margin of the aortic lesion. Thereafter, a 14–18 mm balloon expandable expanded polytetrafluoroethylene covered stent (Bentley BeGraft aortic, InnoMed GmbH, Hechingen, Germany) or (Viabahn VBX Balloon Expandable Endoprosthesis W. L. Gore and Associates, Inc. Arizona, USA) was placed within the aortic segment according to the available stent diameter. The distal end of the stent should be placed ~20 mm above the bifurcation in order to make stent cannulation from both iliac approaches easy. through the sheath placed in the side that was most difficult to recanalize and maintaining the contralateral iliac sheath at the level of the common iliac ostium.

Flaring of aortic-covered stent should be started proximally with a balloon adapted to the native diameter of the distal aorta, typically with a diameter of 16 to 20 mm, to ensure adequate and full apposition to the aortic wall. Also, this maneuver creates a funnel-shaped

configuration of stent with a distal segment that is still 12 mm in diameter. The aortic stent was then molded with short semi-compliant balloons (XXL Balloon Dilatation Catheter, Boston Scientific, Marlborough, Massachusetts, USA) to assure optimal aortic wall apposition.

Subsequently, two iliac covered stents, typically 8-10 mm, are positioned in the conic segment and simultaneously inflated using the kissing technique Bentley BeGraft aortic, InnoMed GmbH, Hechingen, Germany) or (Viabahn VBX Balloon Expandable Endoprosthesis W. L. Gore and Associates, Inc. Arizona, USA) was placed according to the on-shelf available stent. Overlapping with the aortic stent for 10–15 mm. Then ballooning with two kissing-compliant balloons was performed to adapt the parallel stents to the aortic one.

In some cases, distal extensions were required. In these situation, preservation of internal iliac arteries should be kept in consideration, if patent, 6-7 mm bare-metal stent (Bard Life-Stream, Murray Hill, New Jersey, USA) at these locations to prevent buttock claudication and erectile dysfunction.

After the procedure, patients were advised to receive oral anticoagulation, double antiplatelets, and statin for at least 6 months, then after, single antiplatelet and statin therapy were continued as life-long treatment (Figs 1 and 2).

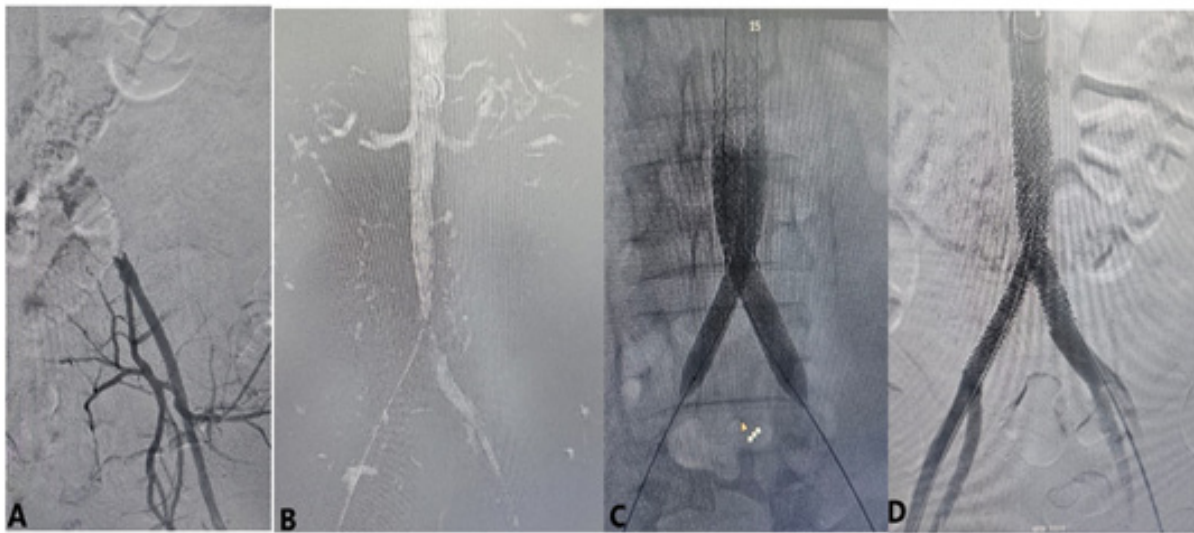


Fig. 1: Female patient 51 years old with right big toe nonhealing ulcer and absent femoral pulses, angiography showed distal aortic stenosis 50% with bilateral common iliac artery occlusion (A, B) Crossing both lesions in a retrograde manner with deployment of three covered stent-grafts in CERAM configuration (C) with good final results (D).

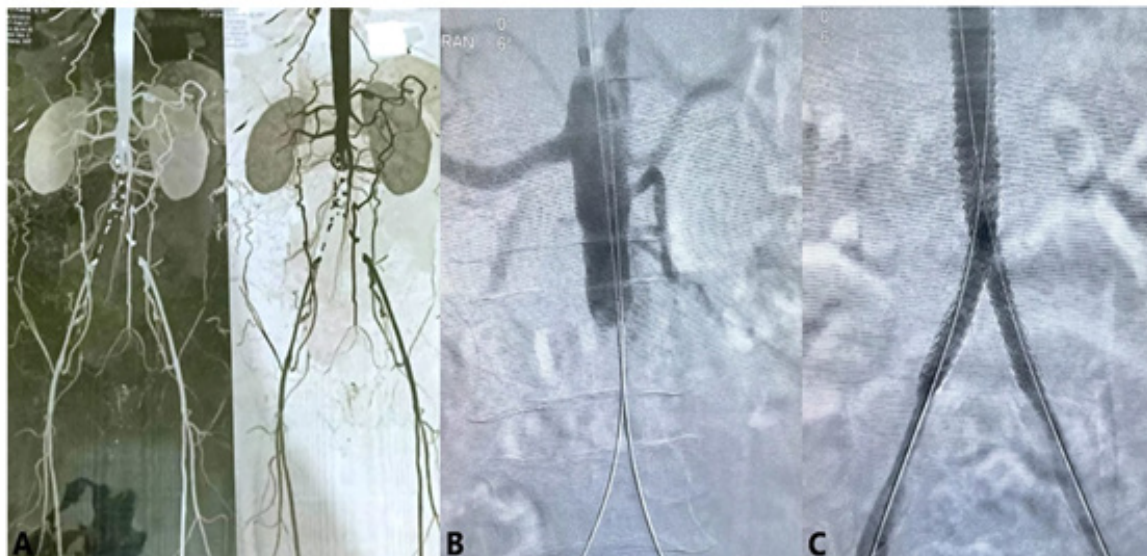

Fig. 2: TASC D lesion (A, B) with total aortic occlusion and bilateral common iliac occlusion successfully recanalized in antegrade-retrograde fashion (C) and CERAB stenting with good final results (D).

Patients follow-up

After the patient is discharged, regular follow-up at 1, 6, 12, 18, and 24 months, follow-up included assessment of the integrity of distal pulses, healing of the foot lesion if any, and any intervention related complication.

All patients were kept on dual antiplatelets for at least 30 days postintervention then single antiplatelets indefinitely. In cases with diminished or disappearance of previously felt pulses urgent radiological evaluation were done either duplex ultrasound or computed tomography angio as indicated.

Study outcomes

Clinical success was defined as the retrieval of femoral pulses postoperative with absence of immediate acute procedure-related complications, improved walking distance by at least 50%, ulcers healing, and disappearance of rest pain were all considered as signs of successful revascularization. Re-intervention was defined as endovascular or surgical correction of CERAB related complication after discharge of the patient.

RESULTS:

This study included 23 patients, 18 (78%) male patients and five (22%) female patients, mean age was 63.7 ± 7 years, as regarding comorbidities in this group, 91% were diabetics (21 patients) 78% hypertensive (18 patients), ischemic heart disease in 30% (seven patients) dyslipidemia 69% (16 patients) COPD 22% (five patients) and 56%^[9] patients were chronic smoker (Table 1).

Concerning the clinical presentation of our group more than half of our patients were presented with lifestyle limiting claudication 56% (13 patients), nonhealing ulcers in 22% (five patients), rest pain in 9% (two patients) and toe gangrene in 13% (three patients).

Regarding the characteristics of aorto iliac lesion 39% (nine patients) were TASC C, while 61% (14 patients) were TASC D. As regarding tandem lesions, three (13%) patients had femoro-popliteal disease, another two (9%) patients had infra-popliteal disease, the clinical presentation and classification of the lesion were summarized in (Table 2).

As regarding the procedural technical data (Table 3) all patient had bilateral percutaneous femoral access, 10 (43%) patients needed additional left brachial access for antegrade recanalization to facilitate true lumen re-entry.

The stent grafts used was VBX in 12 (52%) patients while B graft was used in 11 (48%) patients, contrast used 52 ± 18 ml per case, average procedure time was 123 ± 32 min.

Prostyle closure device was used for 23 (100%) patients for both femoral while manual compression for brachial access was done.

Only one (4%) patient needed SFA recanalization in the same setting.

Technical success with palpable femoral pulses was achievable in 100% of cases (23 patients) with no intraprocedural acute complications.

9% (two patients) developed small groin hematoma and 4% (one patient) developed brachial access hematoma with duplex ultrasound confirmed the absence of pseudoaneurysm and were managed conservatively, all resolved spontaneously over a week, average hospital stay was 2 ± 1 day.

Follow-up and delayed outcome

Clinical improvement estimated by increased walking distance by at least 50% was achievable in all claudicant patients' group, while ulcer healing was achievable with 2–6 weeks postrevascularization.

87% of cases (20 patients) the aorto-iliac grafts remain patent over 18 months follow-up without the need for further interventions.

13% (3 patients) presented with diminished femoral pulses and decreased walking distance 6–9 months after initial revascularization and CTA confirmed unilateral iliac occlusion in 2 cases and tight common femoral stenosis in 1 case (Fig. 3), re-intervention with extending the distal stent to external iliac artery and DCB angioplasty for the femoral artery stenosis with good results, while 1 case refused re-intervention and continued on medical treatment, gives final secondary patency rate of 95% (22 patients) in 24 months (Table 4).

Table 1: Patient demographic data

	Study patients (N=23) Mean±SD (minimum–maximum)
Age (years)	63.7±7 (51–75)
Sex, n (%)	
Male	18 (78)
Female	5 (22)
Comorbidities	n (%)
Diabetes	21 (91)
Hypertension	18 (78)
IHD	7 (30)
Dyslipidemia	16 (69)
COPD	5 (22)
Smoking	13 (56)
Total patients	23

Table 2: Clinical presentation and lesion characteristics

Clinical presentation and lesion characteristics	N (%)
Clinical presentation	
Claudication	13 (56)
Foot ulcer	5 (22)
Rest pain	2 (9)
Toe gangrene	3 (13)
Iliac lesion classification	
TASC C	9 (39)
TASC D	14 (61)
Tandem lesions	
Femoro-popliteal disease	3 (13)
Infra-popliteal disease	2 (9)
Total patients	23

Table 3: Technical data and complications

Technical data and complications	N (%)
Access	
Bilateral femoral	23 (100)
Left brachial access	10 (43)
Stent-graft type	
VBX	12 (52)
B-Graft	11 (48)
Contrast	52±18 ml
Procedural duration Addition interventions at the same sitting	123±32 min
Femoral angioplasty and stenting	1 (4)
Infra-popliteal angioplasty	0
Technical success	23 (100)
Postoperative complications	
Groin hematoma	2 (8)
Brachial hematoma	1 (4)
Total patients	23

Table 4: Patency rate and re-interventions

	N (%)
Primary patency rate	20 (87)
Secondary patency rate	22 (95)
Re-interventions	
Iliac angioplasty	1 (4)
Femoral angioplasty	1 (4)
Conservative management	1 (4)
Total patients	23

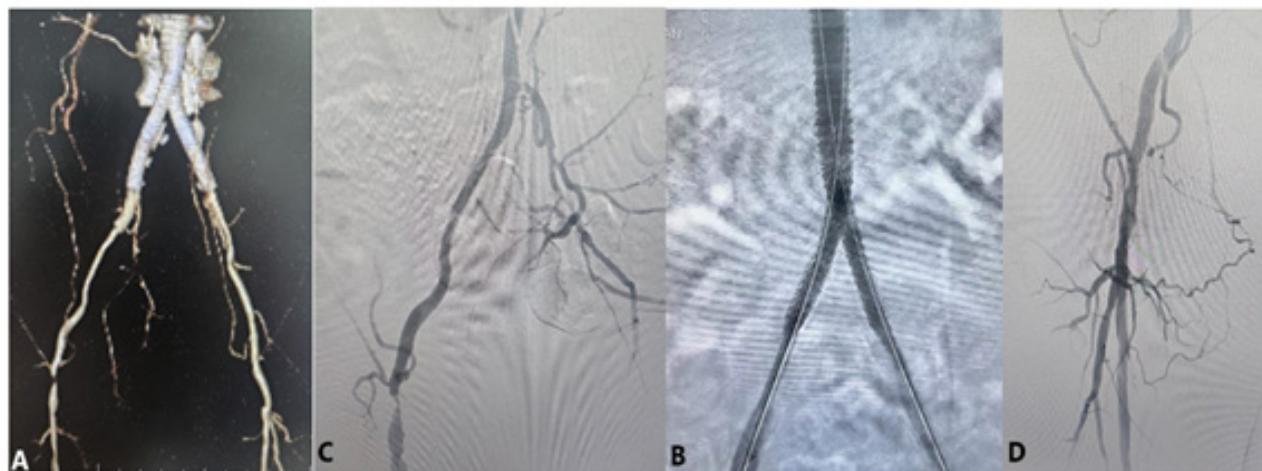


Fig. 3: Male patient presented 6 months post-CERAB with diminish right femoral pulse & short distance claudication, computed tomography angio showed tight common femoral stenosis (A, B), diagnostic angio showed patient CERAB stent-graft (C), the lesion was treated with balloon angioplasty and DCB (D) with palpable pedal pulse at the end of the procedure.

DISCUSSION

Aorto-iliac segment is unique arterial territory that showed excellent results with endovascular intervention comparable to open surgical revascularization, different endovascular modalities were implemented with well-established results, CERAB technique is rather new intervention introduced in 2013 with better outcomes^[10-12].

In this study, 23 patients with AIOD, TASC C 39 and D 61% lesion indicated for intervention were employed with 100% technical success at completion angiography. Our study showed patency rate 87 and 95% as primary and secondary patency rates at 24 months. Endovascular target lesion revascularization (TLR) was needed in two (9%) patients, limb salvage was achievable in 100% of cases. Procedural complications were minor includes access site hematoma in 13% of cases.

In study by Taeymans *et al.* that included 130 patients mostly with TASC D lesions, reported 97% technical success with primary and secondary patency rate of 84 and 97% at 2 years, limb salvage rate was 98%, need for TLR was 13%, minor and major procedural related complication rate 33 and 7%, respectively^[13].

In another study by Saratzis *et al.* that included 116 patients, 82% of his patient presented by TASC D lesions, he reported primary, primary assisted and secondary patency rate of 88, 94, and 98% over 18 months follow-up, TLR needed in 12.1%, 1.7% had major amputation. Sub analysis of his results found that TLR increases with TACS D lesion, severe aortic calcification and presence of tissue loss at the initial presentation^[14].

Borghese *et al.* published his results that included 24 patients TASC II C 29.2 and TASC D II 70.8%, with median follow up of 18 months, with primary and secondary patency rates of 87.5% and 100%, respectively, with TLR rate was 12.5% and peri-operative complication of 12.5%^[8]. a smaller series by Garcia *et al.* reported a lower primary patency rate of 66.7% and secondary patency rate of only 33% in his study that included nine patients^[15].

Percutaneous access greatly improved the patient experience in terms of shorter hospital stay, less inconvenience associated with groin wound to gain femoral access, added to this the used of closure device at the end of the procedure was associated with avoidance of groin compression allowing early mobilization of the patients all are considered optional steps that will not affect the patency rate but have good impact on both the patient and the surgeon in our study

100% of our cases were performed using percutaneous access this same as the study by Borghese *et al.*, in the study by Taeymans *et al.* with larger patients' cohort, he used percutaneous access in 67% of his cases with 33% needed surgical cut down^[8,13].

In CERAB technique, at least 3 covered balloon mounted stent-grafts are used, connected tightly with good wall apposition in treating complex aorto-iliac occlusive disease results in better geometric flow and avoiding mismatch that might affect the patency rate^[9].

The stent type and configuration seem to be important factor the affect both flow and patency, in Virto studies comparing iliac KS with CERAB assessing the effect of radial miss match on flow hemodynamics showed that the CERAB stents configuration is the most physiological construction, this is associated with fewer zones of recirculation less flow disturbance ,less radial miss match almost mimic native bifurcation , all these factors decreases the thrombus formation and improve the patency^[6,16].

The superiority of covered stent graft over bare metal stent in aorto-iliac segment was confirmed in COBEST study by Mwiipatayi *et al.* the 5-year results of the COBEST showed that the covered (CS) had a significantly higher patency rate than per-metal stent (BMS) at 18, 24, and 60 months (95.1, 82.1, and 74.7 for CS vs. 73.9, 70.9, and 62.5% for BMS)^[17]. these results were confirmed also by more recent COBRA European Multicenter Registry by Athanasios Saratzis *et al.* in 2022 that showed better freedom of TLR with CS compared with BMS^[14].

Compared with open surgical revascularization, CERAB has proven at least same patency results with minimally invasive nature, shorter hospital stays, suitability to more co-morbid patients' population at high surgical risk^[10,11].

Both techniques (kissing stent and CERAB) have basically the same initial approach, the different started at the stage of stents type selection, stents deployment and final stents configuration, the use of stent grafts require bigger sheath in most of cases that make the access rather challenging, also the high cost of the covered stent grafts compared with bare-metal stents are considered a limiting factor for this technique^[9].

Recently Torrealba *et al.* reported a single femoral access CERAB case with the use of a steerable sheath, in our expertise, at the time being, this technique is applicable in selected patients with less complex lesions^[18].

Our study results showed that CERAB has a promising result in treating complex aorto-iliac

occlusive disease but this result needs to be confirmed with larger multi-centric comparative studies to reach solid data that can be used to consider CERAB as the treatment of choice for this patient population.

CONCLUSION

Our study showed that CERAB in selective patient's population gives good results with low rate of complications & need for re-interventions, the high cost of this modality will be always a limiting factor despite of expected superiority over the per-metal stents, larger multi-center randomized controlled studies are needed for better evaluation of this technique compared to surgical reconstruction and other endovascular techniques.

CONFLICT OF INTEREST

There are no conflicts of interest.

REFERENCES

- Jongkind V, Akkersdijk GJ, Yeung KK, Wisselink W. A systematic review of endovascular treatment of extensive aortoiliac occlusive disease. *J Vasc Surg* 2010; 52:1376–83.
- Premaratne S, Newman J, Hobbs S, Garnham A, Wall M. Meta-analysis of direct surgical versus endovascular revascularization for aortoiliac occlusive disease. *J Vasc Surg* 2020; 72:726–37.
- De Vries SO, Hunink MG. Results of aortic bifurcation grafts for aortoiliac occlusive disease: a meta-analysis. *J Vasc Surg* 1997; 26:558–69.
- Kashyap VS, Pavkov ML, Bena JF, Sarac TP, O'Hara PJ, Lyden SP, *et al.* The management of severe aortoiliac occlusive disease: endovascular therapy rivals open reconstruction. *J Vasc Surg* 2008; 48:1451–7.
- Sharafuddin MJ, Hoballah JJ, Kresowik TF, *et al.* Longterm outcome following stent reconstruction of the aortic bifurcation and the role of geometric determinants. *Ann Vasc Surg* 2008; 22:346e–357.
- Groot Jebbink E, Grimme FA, Goverde PC, *et al.* Geometrical consequences of kissing stents and the covered endovascular reconstruction of the aortic bifurcation configuration in an in vitro model for endovascular reconstruction of aortic bifurcation. *J Vasc Surg* 2015; 61:1306–1311.
- Grimme FA, Verbruggen PJ, Reijnen MM. The first results of the covered endovascular reconstruction of the aortic bifurcation (CERAB) technique for aortoiliac occlusive disease. *Eur J Vasc Endovasc Surg* 2015; 50:638–647.
- Borghese O, Ferrer C, Coscarella C, Spataro C, Diotallevi N, Giudice R. Two-year single centre results with covered endovascular reconstruction of aortic bifurcation (CERAB) in the treatment of extensive aorto-iliac occlusive disease. *Vascular j* 2022; 30:500–508.
- Taeymans K, Goverde P, Lauwers K, Verbruggen P. The CERAB technique: tips, tricks and results. *J Cardiovasc Surg (Torino)* 2016; 57:343e9.
- McElligott H, Toale C, Kavanagh EG, *et al.* Hybrid covered endovascular reconstruction of the aortic bifurcation (CERAB) procedure is preferable to aortobi femoral bypass for limb-threatening aortoiliac occlusive disease during the COVID-19 crisis. *J Vasc Surg Cases Innov Tech* 2020; 6:703–706.
- Kashyap VS, Pavkov ML, Bena JF, *et al.* The management of severe aortoiliac occlusive disease: endovascular therapy rivals open reconstruction. *J Vasc Surg* 2008; 48:1451e1457.
- Hans SS, DeSantis D, Siddiqui R, Khoury M. Results of endo vascular therapy and aortobifemoral grafting for Transatlantic Inter-Society Type C and D aortoiliac occlusive disease. *Surgery* 2008; 144:583e590.
- Taeymans K, Groot Jebbink E, Holewijn S, *et al.* Three-year outcome of the covered endovascular reconstruction of the aortic bifurcation technique for aortoiliac occlusive disease. *J Vasc Surg* 2018; 67:1438–1447.
- Saratzis A, Argyriou A, Davies R, *et al.* Covered vs. Bare Metal Stents in the Reconstruction of the Aortic Bifurcation: Early and Midterm Outcomes from the COBRA European Multicentre Registry. *Eur J Vasc Endovasc Surg* 2022; 63:688e695.
- GarcíaL, F, Gomez-RodríguezJ, C, Lozada-MartínezI, D. Midterm outcomes of the covered endovascular reconstruction of the aortic bifurcation for aortoiliac occlusive disease in a latinoamerican population. *International Journal of Surgery Case Reports* 2021; 88:106572.
- Groot Jebbink E, Mathai V, Boersen JT, Sun C, Slump CH, Goverde PC, *et al.* Hemodynamic comparison of stent configurations used for aortoiliac occlusive disease. *J Vasc Surg* 2017; 66:251–60.

17. Mwipatayi BP, Sharma S, Daneshmand A, *et al.* Durability of the balloon-expandable covered versus bare-metal stents in the Covered versus Balloon Expandable Stent Trial (COBEST) for the treatment of aortoiliac occlusive disease. *J Vasc Surg* 2016; 64:e1.
18. Torrealba I J, Blessing E, Rohlffs F, *et al.* Single access covered endovascular reconstruction of the aortic bifurcation. *J Vasc Surg Cases Innov Tech* 2023; 9:101343.