

Bioactive effects of bread enriched with corn silk on serum lipid and inflammation in male rats

Asmaa Ahmed M. Hussein
Nutrition and Food Science
Department, Faculty of Home
Economics, Helwan University,
Egypt.

Enas Ashraf A. Elokda
Home Economics
Department, Women's College, Ain
Shams University, Egypt



المجلة العلمية المحكمة لدراسات وبحوث التربية النوعية

المجلد الحادي عشر - العدد الأول - مسلسل العدد (٢٨) - يناير ٢٠٢٥م

رقم الإيداع بدار الكتب ٢٤٢٧٤ لسنة ٢٠١٦

ISSN-Print: 2356-8690 ISSN-Online: 2974-4423

موقع المجلة عبر بنك المعرفة المصري <https://jsezu.journals.ekb.eg>

البريد الإلكتروني للمجلة E-mail JSROSE@foe.zu.edu.eg

Bioactive effects of bread enriched with corn silk on serum lipid and inflammation in male rats

Asmaa Ahmed M. Hussein
Nutrition and Food Science
Department, Faculty of Home
Economics, Helwan University,
Egypt

Enas Ashraf A. Elokda Home
Economics Department, Women's
College, Ain Shams University,
Egypt

تاريخ المراجعة ٣-١-٢٠٢٥م

تاريخ الرفع ٢٥-١١-٢٠٢٤م

تاريخ النشر ٧-١-٢٠٢٥م

تاريخ التحكيم ٢٢-١٢-٢٠٢٤م

Abstract

Examining the bioactive effects of bread enriched with corn silk on lipid and inflammation in serum on male rats was the aim of this study. After the adaption timing, Thirty two albino male rats Sprague –Dawley strain weighting 180 ± 5 g were classified into four groups, (8 rats each) control negative (-ve) group feed unfortified bread in a 1:1 ratio and three rat groups which feed 2% cholesterol for hypercholesterolemia and injected of 0.1 ml formalin (4%) to cause inflammation and reclassified into control positive (+ve) feed unfortified bread in a 1:1 ratio , the third and fourth group feed fortified bread containing 10% and 15% corn silk powder (CSP), respectively, Three rats were chosen from each rat's paw at the start of the eighth week of the experiment. The experimental period for 60 days. We deduced from the data that a group of rats fed a high-fat diet were a significant risk factor for the condition known as hyperlipidemia. According to our results, the bread fortified with 15% CSP was thought to be the most effective at lowering TC, TG, LDL-c and VLDL-c. The liver enzyme levels of ALT, AST,ALP and urea nitrogen and creatinine have improved of All treated groups under investigation When compared to the positive control group. All treated groups also showed a significant increase in superoxide dismutase (SOD) and a decrease in malondialdehyde (MDA) concentration and improvement in histological liver and Kidney tissues. Outcomes, which were in line with the biochemical analysis. For all groups fed bread enhanced with corn silk, the results also demonstrated a significant reduction in inflammation in the thickness of the paw of rat with hyperlipidemia using formalin .It can be recommended that the Increased consumption of corn silk may help to reduce of blood lipids in individuals suffering from hyperlipidemia and inflammation, according to results of this study. **Key words:** Corn silk, inflammation, Liver and renal function, hyperlipidemia, rats.

التأثيرات الحيوية لحرير الذرة على دهون السيرم والالتهابات في ذكور الفئران

الملخص العربي

تهدف هذه الدراسة هو التعرف علي التأثيرات الحيوية للخبز المدعم بحرير الذرة على دهون الدم والالتهاب في ذكور الفئران بعد انتهاء فترة التكيف تم تقسيم اثنين وثلاثين من ذكور الفئران من سلالة سبراج داولي ويتراوح اوزانهم بين 180 ± 5 جرام إلى أربع مجموعات (٨ فئران لكل مجموعة) المجموعة الاولي الكنترول السالبة والتي تتغذى وجبة قياسية مدعمة بالخبز غير المدعم بنسبة ١:١ وثلاث مجموعات فئران تتغذى الوجبة القياسية المضافة اليها ٢% كولسترول وذلك للإصابة بزيادة كولسترول الدم كما تم حقنهم ب ٠.١ مل فورمالين (٤%) لإحداث الالتهاب وتم إعادة تقسيمهم الي المجموعة الثانية الكنترول الموجبة والتي تتغذى على الخبز الغير مدعم بنسبة ١:١ والمجموعة الثالثة والرابعة تتغذى على خبز مدعم يحتوي على ١٠% و ١٥% مسحوق حرير الذرة على التوالي، وتم اختيار ثلاثة فئران من مخلب كل فأر في بداية الأسبوع الثامن من التجربة. واستمرت فترة التجربة ٦٠ يومًا حيث اسفرت نتائج الدراسة علي أن مجموعة من الفئران التي تتغذى على نظام غذائي عالي الدهون كان له تأثيرات عالية للإصابة في ارتفاع دهون الدم. بينما المجموعات التي تتغذي علي نظام غذائي عالي الدهون والمحتوي علي الخبز المدعم بنسبة ١٥% من حرير الذرة هو الأكثر فعالية في خفض مستويات TC كل من الكولستيرول والدهون الثلاثية والليوبروتينات منخفضة الكثافة ومنخفضة الكثافة جدا كما تحسنت مستويات إنزيمات الكبد ALT وAST وALP ونيروجين اليوريا والكرياتينين في جميع المجموعات المعالجة عند المقارنه بمجموعة الكنترول الموجبة . كما أظهرت جميع المجموعات المعالجة زيادة كبيرة في إنزيم سوبر اكسيد دسميوتيز وانخفاض في تركيز مالونديالدهيد وتحسن في أنسجة الكبد والكلى حيث كانت النتائج الهستوباثولوجية متوافقة مع التحليل الكيميائي الحيوي. وبالنسبة لجميع المجموعات التي تغذت على الخبز المدعم عزز بحريرة الذرة، أظهرت النتائج انخفاض كبير في الالتهاب في سمك مخلب الفئران المصابة بارتفاع دهون ويمكن التوصية بأن زيادة استهلاك حريرة الذرة قد يساعد في تقليل دهون الدم لدى الأفراد الذين يعانون من ارتفاع دهون الدم والالتهابات، وفقاً لنتائج هذه الدراسة.

Introduction

Hyperlipidemia, a disorder of lipid metabolism that causes abnormally elevated lipid levels, is indicated by low plasma concentrations of HDL-c, as well as high levels of triglycerides (TG), total cholesterol (TC), and low-density lipoprotein cholesterol (LDL-c). Globally, hyperlipidemia has increased within the last few decades (Liuyi et al., 2024)

The style and stigma of *Z. mays* L., which was brought to China during the Ming Dynasty, make up corn silk. It is thought to be a diuretic that helps relieve jaundice, calm the liver stimulate bile flow, enhance diuresis, and reduce edema. Acute and chronic nephritis, edema, and hyperglycemia can all be treated with corn silk, according to numerous Chinese medicine publications, including "Clinical Chinese Medicine." **Dong et al., (2023).**

Several bio-functional compounds, including isoquercitrin, tartaric acid, stigmasterol, hordenine, allantoin, resin, maysin, anticyanins and cryptoxanthin are present in corn silk (CS) extract (**Kim et al., 2014**). Maysin, a significant flavonoid in CS, is also present in high concentrations in CS extract (**Jae et al., 2016**). Maysin contains a flavone glycoside that has a carbohydrate bonded to luteolin, a compound that is biologically active.

Known in Arabic as "Quysoom-aletri," *Achillea fragrantissima* (yarrow) is a common plant in Arab nations (**Alshuai et al., 2022**). It has long been used as a medicinal tea to cure a number of illnesses, including diarrhea, diabetes, eye infections, problems with digestion, and respiratory infections (**Yasir et al., 2023**). Phenolic acids and many flavonoids, which are known to have strong antibacterial properties, are abundant in this plant.

Materials and methods

Materials:

The materials, which included cellulose, casein, vitamin mix, minerals, and the kits needed for biochemical examination were provided from El-Gomhoria Drug Trading Company in Egypt. The chemicals, medical supplies, and corn silk (*zea mays*) were provided from the Agricultural Research Center in Giza, Egypt.

Thirty-two Sprague-Dawley albino rats weighing approximately 180 ± 5 g were purchased from Helwan Farms for The experimental Animals in Cairo, Egypt.

Methods:

Bread ingredients: Wheat flour and other materials used in the making of bread were purchased from the local market and Corn silk was added according to the required proportions in the research.

Design of experimental animals

Basal diet Preparation

The basal diet preparation was based on **Reeves et al. (1993)**. 10 percent sugar, 20 percent protein, 2 percent choline chloride, 4.7 percent corn oil, 1 percent vitamin mixture, 5 percent fiber, and 3.5 percent salt mixture total in this composition.

There were four major groups. control negative (-ve) group feed unfortified bread in a 1:1 ratio and three rat groups which feed 2% cholesterol for hypercholesterolemia and injected of 0.1 ml formalin (4%) to cause inflammation and reclassified into control positive (+ve) feed unfortified bread in a 1:1 ratio , the third and fourth group feed fortified bread containing 10% and 15% corn silk powder (CSP), respectively, according to **Hassarajani et al. (2007)**.

The production of inflammation:

Three rats were chosen from each group at the start of the eighth week of the experiment following the corn silk feeding trial, and 0.1 ml of formalin (4%) was injected into the rat's paw to cause inflammation in accordance with **Northover and Subramanian (1962)** in order to determine the impact of corn silk on inflammation. All of the rats fasted overnight at the ending of the eight-week experiment while being mildly sedated with ether. Clean, dry plastic centrifuge tubes were used to collect the blood. Serum was taken from centrifuged blood samples and kept in a clean, well-stopped bottle at -20° C until analysis.

Grouping of rats and experimental design

The thirty two albino male rats Sprague –Dawley strain weighting 180 ± 5 g were classified into four groups, (8 rats each) control negative (-ve) group feed in basal diet and unfortified bread in a 1:1 ratio and three rat groups which feed 2% cholesterol in diet for hypercholesterolemia and injected of 0.1 ml formalin (4%) to cause inflammation according to **Northover and Subramanian (1962)**. and reclassified into control positive (+ve) feed unfortified bread in a 1:1 ratio , the third and fourth group feed fortified bread containing 10% and 15% corn silk powder (CSP), respectively, according to **Hassarajani et al. (2007)**. Three rats were chosen from each rat's paw at the start of the eighth week of the experiment. The study was assigned for 60 days. All the biological experimental procedures were performed according to Internationally Ethical Guidelines for the care and use of laboratory animals. Permission to conduct the experiment was obtained from the Research Ethics Committee at the Animal Health Research Center

Biochemical analysis

Triglycerides and serum total cholesterol were measured using the procedures outlined by **Fassati and Percipe (1982)** and **Allain et al. (1974)**, respectively. Using the calorimetric method described by **Lopez-Virella et al., (1977)**, serum HDL-C was measured. Formula (**Friedewald et al., 1972**) was used to determine serum VLDL-c in addition to LDL-c. The liver enzymes aspartate aminotransferase (AST), alanine aminotransferase (ALT), and alkaline phosphatase (ALP) were measured in accordance with **Roy (1970)**, **Young (1990)**, and **Sherwin**

(1984). The methods of Fossati et al., (1980) and Henry (1974) were used to measure the levels of serum urea nitrogen and creatinine, respectively. According to **Draper and Hadly (1990)**, serum MDA was evaluated. Serum SOD was analyzed in accordance with **Nishikimi et al., (1972)**.

Histopathological examination of liver and kidney tissues

The liver and kidney were fixed in 10% neutral buffered formaldehyde solution at pH 7.5 and cleared in xylol and embedded in paraffin. 4 μ m thick sections were prepared and stained with Hematoxylin and Eosin (H&E) for subsequent histopathological examination according to **Bancroft et al., (2012)**.

Statistical data analysis

The Dunk test, a multiple range post-hoc test, was used in the statistical analysis, which was conducted using SPSS, PC statistical software (Version 18.0 SPSS Inc., Chicago, USA). One-way analysis variance (ANOVA) was used to analyze the data. The data proved substantially different at $P < 0.05$, using **Snedecor and Cochran (1980)**.

Results and Discussion

Determination of chemical analysis in corn silk.

The chemical analysis of corn silk was displayed in Table (1). Carbohydrates had the highest concentration of corn silk, followed by fiber, protein, moisture, ash, and fat, according to the results in this table.

Table (1): Chemical composition of corn silk

Component (g / 100g)	
Moisture	11.204
Protein	14.86
Fat	1.918
Ash	4.49
Fiber	22.62
Carbohydrate	44.92

The Antioxidant activity of corn silk

The results of the radical scavenging activity for corn silk are displayed in table (2). The antioxidant activity was strong at 84.01% in 5% concentration.

Table (2): The Antioxidant activity of corn silk

SN	% DPPH Radical-Scavenging Activity			
	0.5%	1.0%	2.5%	5%
Corn Silk	20.30	40.99	60.11	84.01

Effect of corn silk fortified bread on lipid profile of hyperlipidemic rats.

The impact of bread fortified with corn silk on the lipid profile of hyperlipidemic rats was demonstrated by the results in Table (3). When compared to the negative control group, the results indicated that the

hyperlipidemic rats' serum levels of total cholesterol, triglycerides, high density lipoprotein, low density lipoprotein, and very low-density lipoprotein had changed significantly. When compared to the positive control group, treated rats that fed 10 and 15% corn silk fortified bread showed a substantial decrease in TC, TG, LDL-c, and VLDL-c ($P \leq 0.05$).

The hyperlipidemic group fed a basal diet that included fortified bread with 15% CS showed the highest results in lipid fractions among all treated groups. **Hala, (2018)** shown that corn silk substantially decreased the following parameters: serum TC, TG, homocysteine, leptin hormone, atherogenic index, malondialdehyde, LDL-c, and VLDL-c. These results agree with those of **Hala, (2018)** However, the data indicated that adiponectin and high-density lipoprotein levels had significantly increased.

Furthermore, **Yan et al., (2016)** found that no negative effects on healthy mice with consuming crude flavonoids derived from corn silk at a level of less than 500 mg/kg and that it showed strong anti-diabetic potential in addition to anti-oxidant and anti-hyperlipidemia properties. Compared to the diabetic control (DC) group, the diabetic CSF high dosage group (HD) had lower levels of serum TC, TG, LDL-c, BG, and liver glycogen. Furthermore, HDL-c levels were slightly rising.

Table (3): Effect of corn silk fortified bread on lipid profile of hyperlipidemic and negative control rats.

Parameters Groups	mg/dL				
	TC	TG	HDL-c	LDL-c	VLDL-c
(-ve)	83.86± 3.25 ^b	105.86± 0.44 ^{b,c}	75.57± 1.93 ^a	12.87± 2.35 ^b	21.17± 0.91 ^{b,c}
(+ve)	100.86± 6.24 ^a	122.06± 6.16 ^a	25.51± 2.47 ^d	51.95± 4.82 ^a	24.41± 1.61 ^a
Bread + 10% corn silk	73.29± 1.45 ^d	107.88± 0.232 ^b	38.71± 7.348 ^c	12.49± 7.383 ^b	22.09± 7.040 ^b
Bread + 15% corn silk	79.66± 5.83 ^c	103.33± 7.448 ^c	47.13± 7.237 ^b	11.87± 7.247 ^c	20.66± 7.086 ^c

Values are expressed as mean ± S.D. Means with the different superscript letters in the same column were significantly different at $P \leq 0.05$.

Effect of corn silk fortified bread on liver function of hyperlipidemic rats.

The impact of corn silk-fortified bread on the serum activity of alkaline phosphatase (ALP), aspartate aminotransferase (AST), and alanine aminotransferase (ALT) was demonstrated by the results in Table (4). The findings demonstrated that, in comparison to normal rats, hyperlipidemic rats (positive control group) had significantly higher serum levels of ALT, AST, and ALP. However, when compared to the positive control group, the serum concentrations of ALT, AST, and ALP

significantly decreased in all treatment groups. Rats fed fortified bread with 15% CS showed the greatest improvement in the results.

These results are consistent with those of Matsuzawa-Sanad et al., (2022) who reported that giving rats forssk on a high-fat diet improved their liver functions as indicated by the normalization of liver function indicators ALT, AST, and ALP.

The groups that received nicotine plus aqueous or methanol extracts of corn silk showed a substantial decrease in the ALT enzyme as compared to the nicotine group. Additionally, mice receiving nicotine showed a substantial decrease in AST when compared to the nicotine group due to the protective impact of aqueous and methanol extracts of corn silk. Nevertheless, the ALP enzyme dramatically reduced in mice administered nicotine in addition to aqueous or methanol extracts of corn silk compared to the nicotine group. (Mohammadi et al., 2024).

Table (4): Effect of corn silk fortified bread on liver function of hyperlipidemic and negative control rats

Parameters Groups	U/L		
	ALT	AST	ALP
(-ve)	9.71± 1.62 ^{b,c}	12.71± 2.17 ^{b,c}	45.29± 3.23 ^d
(+ve)	12.86± 4.32 ^a	18.71± 4.37 ^a	105.86± 2.42 ^a
Bread + 10% corn silk	10.29± 1.88 ^b	15.43± 4.48 ^b	71.42± 2.56 ^b
Bread + 15% corn silk	09.85± 1.84 ^{b,c}	12.38± 3.86 ^c	67.33± 2.63 ^c

All results are expressed as mean ± S.D. Means with the different superscript letters in the same column were significantly different at $P \leq 0.05$.

Effect of corn silk fortified bread on Serum Concentrations of Creatinine and Urea Nitrogen of hyperlipidemic rats.

The impact of corn silk on kidney function (urea nitrogen and serum creatinine concentration) is presented in Table (5). The results indicated that the positive control group, which included hyperlipidemic rats, had notably higher serum levels of urea nitrogen (mean value of 0.75±0.04 mg/dl) than the negative control group (0.66±0.03 mg/dl). In comparison to the positive control group, the data indicated that the levels of urea nitrogen and creatinine gradually decreased in accordance with the concentration of CS. The ratios reached 0.70±0.05 and 44.00±2.08 with corn silk fortified bread at 10%, and 0.65±0.02 and 34.33±2.84 mg/dl with corn silk fortified bread at 15%.

Sukandar et al., (2013) showed that corn silk extract improves kidney functions by increasing the amount of urine, which can assist remove waste and toxic substances, lowering creatinine levels. This study results aligned with their findings. Additionally, corn silk extract aids in the removal of excessive fluid, which might reduce fluid retention. Corn

silk extract helps lower high blood pressure, which is the most noticeable symptom. Chemicals in corn silk acting as diuretics and can also help lower inflammation and kidney disorders (*Miriam et al., 2015*).

Table (5): Effect of corn silk fortified bread on Serum Concentrations of Creatinine and Urea Nitrogen of hyperlipidemic and negative control rats.

Parameters Groups	mg/dl	
	Urea Nitrogen	Creatinine
(-ve)	0.66±0.03 ^c	37.33±2.66 ^{bc}
(+ve)	0.75±0.04 ^a	54.00±2.08 ^a
Bread + 10% corn silk	0.70±0.05 ^b	44.00±2.08 ^b
Bread + 15% corn silk	0.65±0.02 ^c	34.33±2.84 ^c

Effect of corn silk fortified bread on the Serum Concentrations of MDA and the Activity of SOD Enzymes of hyperlipidemic rats

The effects of CS on the antioxidant enzymes and tissue liver lipid peroxidation of experimental rats are shown in Table (6). As a measure of oxidative stress, the concentration of superoxide dismutase (SOD) was significantly lower in the positive control group compared to the negative control group, with mean values of 2.19± 0.56 and 4.31± 0.83 u/ml, respectively. Additionally, when CS-fortified bread was fed to hyperlipidemic rats, their SOD concentrations significantly increased in comparison to the positive control group.

Malondialdehyde (MDA) concentration, the first oxidative stress marker to be evaluated, was found to be higher in the hyperlipidemic control group than in the normal control group, with a mean value of 22.02± 2.44 nmol/ml compared to 12.93± 1.24 nmol/ml. The MDA concentration was significantly lower in all treatment groups than in the positive control group.

Lowering high blood glucose levels can be accomplished in a variety of ways. One of these is scavenging the reactive oxygen species that cause β -cell death. Oxidative stress is a major factor in the degradation of all biological systems. The wild plant, the acclimated plant, and the plants that gave IBA all produced significant antioxidant activity by reducing MDA in the serum sample of the treated rats. GSH is an intracellular antioxidant that can decrease oxidative stress, whereas MDA is a highly reactive indication of it (*Abdel-Hamed et al., 2021*). Biochemical indicators of antioxidant activity include MDA testing and the in vivo α -amylase inhibitory activity of different in vitro *A. fragrantissima* administered to STZ diabetic rats (*Goda et al., 2023*).

The presence of phytosterols, proteins, polyunsaturated fatty acids, antioxidant vitamins, carotenoids, tocopherols, and other compounds in corn silk is associated with a number of health beneficial effects (*Miriam*

et al., 2015). Hu and Deng (2011) indicate that CS effectively increases the levels of antioxidant enzymes involving SOD and CAT.

Table (6): Effect of corn silk fortified bread on the Serum Concentrations of MDA and the Activity of SOD Enzymes of hyperlipidemic and negative control rats

Parameters Groups	Parameter as Mean \pm SD	
	SOD (μ / mg)	MDA (μ mol /g)
(-ve)	4.31 \pm 0.83 ^a	12.93 \pm 1.24 ^c
(+ve)	2.19 \pm 0.56 ^c	22.02 \pm 2.44 ^a
Bread + 10% corn silk	4.10 \pm 0.75 ^{a, b}	17.55 \pm 1.50 ^b
Bread + 15% corn silk	4.35 \pm 0.73 ^a	15.97 \pm 1.68 ^b

Effect of corn silk fortified bread on the Paw's Thickness of Rats after Induction of Pedal Inflammation by Formalin.

Table (7) shows how the experimental rats' paw thickness changes when their diet is enhanced with varying amounts of corn silk fortified bread (CSFB) following formalin-induced pedal inflammation.

Following the induction of pedal inflammation by formalin, the experimental rats' paw thickness drastically decreased with a mean value of 2.70 ± 0.15 and 1.53 ± 0.26 mm, respectively, following diet fortification with varying levels of CSFB (10%, and 15%) ($P < 0.05$) when compared to the positive control rats (hyperlipidemic group), which had a mean value of 2.70 ± 0.15 mm. Additionally, rats fed a diet enriched with two levels of CSFB (10% and 15%) showed a significant decrease in the thickness of the paw's pedal inflammation after three hours of inflammation induction. The mean values were 1.17 ± 0.17 mm and 1.53 ± 0.26 mm, respectively ($P < 0.05$) when compared to the positive control rats (2.87 ± 0.33 mm). Furthermore, rats fed a diet supplemented with CSFB at any level of intake showed a substantial decrease in paw thickness after six hours of inflammation induction as compared to the positive control rats. Also following one day of formalin inducing pedal inflammation, the thickness of the paws of all hyperlipidemic rats fed on two levels of CSFB reduced significantly (1.33 ± 0.24 and 1.60 ± 0.21 , respectively) in comparison to positive control rats (3.23 ± 0.43). Added to that, after two days of inflammatory induction, rats fed diet supplemented with 10% and 15% CSFB showed a substantial decrease in paw thickness, with mean values of 1.47 ± 0.27 mm and 1.80 ± 0.35 mm, respectively. Level 1 of CSFB fortification was dramatically reduced, but level 2 was not statistically different compared to the positive control group after 4 days. In the day (6) following the induction of inflammation, the data revealed that there were no significant differences in any of the

hyperlipidemic groups, with the exception of rats fed a diet supplemented with 10% CSFB, which had a larger significant value (2.50 ± 0.50 mm) than the other hyperlipidemic groups.

According to Wang et al., (2012), our results supported their findings that corn silk had a protective effect against inflammation and assisted in its healing.

According to Guang et al., (2012), corn silk extract has anti-inflammatory properties in acute inflammatory problems. Corn silk extract was able to effectively inhibit the inflammatory exudate and leukocyte migration that carrageenin stimulates in the rat pleurisy test. According to Stow et al., (2009), these results demonstrate that the extract from corn silk had an anti-inflammatory impact because it inhibited the synthesis and/or release of proinflammatory cytokines.

Table (7): Effect of corn silk fortified bread on the Paw's Thickness of Rats after Induction of Pedal Inflammation by Formalin

Variables Groups	Millimeter (mm)						
	Control	3 Hr.	6 Hr.	1 Day	2 Day	4 Day	6 Day
Control (+)	2.70 ± 0.15^a	2.87 ± 0.33^a	3.07 ± 0.47^a	3.23 ± 0.43^a	3.03 ± 0.09^a	2.97 ± 0.03^a	1.53 ± 0.37^b
Bread fortified with corn silk (10%)	2.00 ± 0.58^b	1.17 ± 0.17^b	1.17 ± 0.1^b	1.33 ± 0.24^c	1.47 ± 0.27^c	1.77 ± 0.37^c	2.50 ± 0.50^a
Bread fortified with corn silk (15%)	1.53 ± 0.26^c	1.53 ± 0.26^b	1.53 ± 0.26^b	1.60 ± 0.21^b	1.80 ± 0.35^b	3.00 ± 0.50^a	1.37 ± 1.13^b

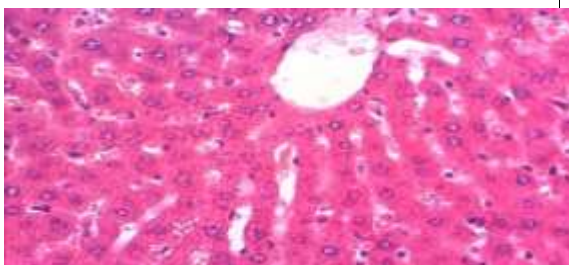
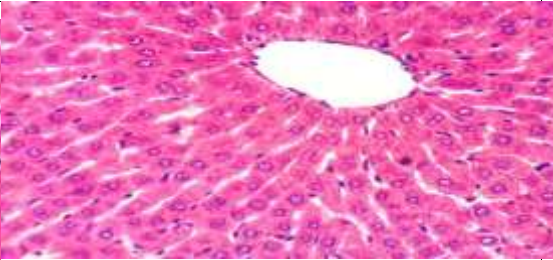
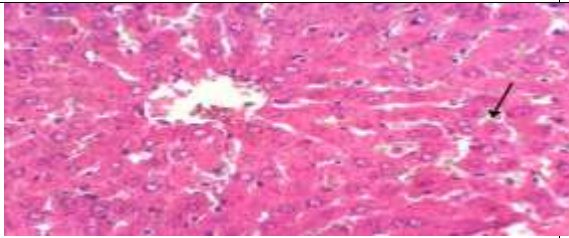
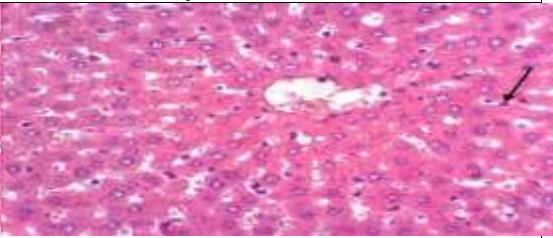
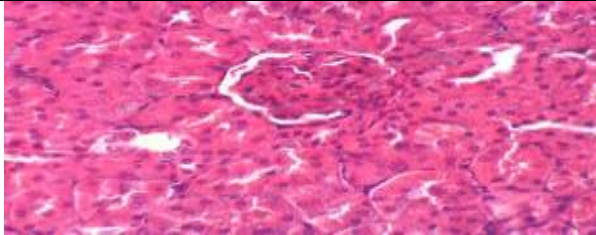
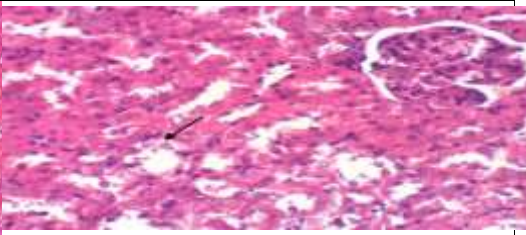
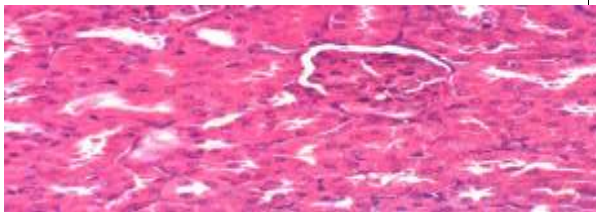
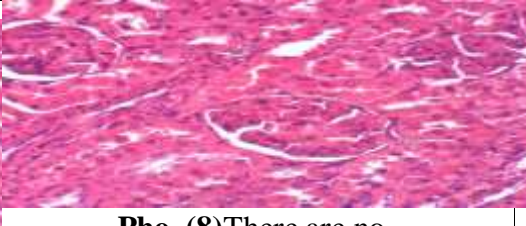
Values were expressed as means \pm SE.

Means with the same superscript letters are not significantly different, (at $P < 0.05$).

Histopathological results

Rats from group 1 had normal hepatic lobule histological structure when examined under a microscope (Pho. 1). However, the liver of rats in group 2 had localized hepatocellular necrosis related to the infiltration of mononuclear inflammatory cells (Pho. 2). On the other hand, liver in group 3 displayed mild hepatic sinusoidal congestion (Pho.3). Sections from group 4 that were examined revealed Kupffer cell activation (Pho.4).

Rats from group 1 had normal renal tissue histological structure when their kidneys were examined under a microscope (Pho.5). On the other hand, rats in group 2's kidneys indicated vacuolization of the renal tubule epithelium (Pho. 6). In contrast, no histopathological changes were seen in the sections from groups 3 and 4 (Pho. 7 and 8).

Liver Histopathological examination	
	
Pho. (1) The rat's liver from group 1 has a regular hepatic lobule histological structure (H & E X 400).	Pho(2) Group 2 rats' liver had focal hepatocellular necrosis along with the infiltration of mononuclear inflammatory cells (H & E X 400)
	
Pho. (3): Liver of Rat from group 3 has mild hepatic sinusoidal congestion (H & E X 400).	Pho (4) Rat' liver from group 4 demonstrating activation of Kupffer cells (H & E X 400).
Kidney histopathological examination	
	
Pho. (5): Rat' kidney from group 1 indicating normal renal tissue histological structure.	Pho.(6) Rat' kidney from group 2 appearing renal tubule epithelial lining vacuolization (H & E X 400).
	
Pho. (7): Rat' kidney from group 3 revealing no histopathological changes.	Pho. (8) There are no histopathological changes in kidney of the rat in group 4.

References

Abdel-Hamed, A.; Mehanna, E.; Hazem, R.; Badr, J.; Abo-Elmatty, D.; Abdel-Kader, M and Goda, M. (2021): Plicosepalus acacia Extract and Its Major Constituents, Methyl Gallate and Quercetin, Potentiate Therapeutic Angiogenesis in Diabetic Hind Limb Ischemia: HPTLC Quantification and LC-MS/MS Metabolic Profiling. *Antioxidants*, 10, 1701, 1-24.

Allain C., Poon L., Chan C., Richmond W and Fu P. (1974): Enzymatic determination of total serum cholesterol. *Clin Chem.* 20(4):470-5.

Alshuail N, Alehaideb Z., Alghamdi S., Suliman R., Al-Eidi H., Ali R., Barhoumi T., Almutairi M., Alwhibi M and Alghanem B. (2022): Achillea fragrantissima (Forssk.) Sch. Bip Flower Dichloromethane Extract Exerts Anti-Proliferative and Pro-Apoptotic Properties in Human Triple-Negative Breast Cancer (MDA-MB-231) Cells: In Vitro and In Silico Studies. *Pharmaceuticals*, 15, 1060, 1-30.

Bancroft, J. D and Layton, C. (2012): The hematoxylin and eosin. *Bancroft's theory and practice of histological techniques*, 7, 173-186.

Dong W., Zhao Y., Li X., Huo J. and Wang W. (2023): Corn silk polysaccharides attenuate diabetic nephropathy through restoration of the gut microbial ecosystem and metabolic homeostasis. ORIGINAL RESEARCH article, Volume 14.

Draper, H. and Hadley, M., (1990): Malondialdehyde determination as index of lipid peroxidation. *Methods Enzymol.* 186, 421-431.

Fossati, P.; Prencipe, L. and Berti, G. (1980): Enzymatic colorimetric method of determination of urea in serum. *Clin. Chem.* 6(18) 499-502.

Fassati P. and Percipe L., (1982): Serum Triglycerides Determined Colorimetrically with an Enzyme that Produces Hydrogen Peroxide. *Clinical Chemistry, Scientific Research Publishing*, 28, 2077-2080.

Friedewald W.T., Levy R.I. and Fredrickson D.S., (1972): Estimation of the concentration of low-density lipoprotein cholesterol in plasma, without use of the preparative ultracentrifuge," *Clinical Chemistry*, vol. 18, no. 6, pp. 499–502.

Guang Q., Tao X., Xue M., and Bao Y. (2012): Anti-inflammation Effects of Corn Silk in a Rat Model of Carrageenin-Induced Pleurisy. Published, Volume 35, pages 822–827.

Goda, M., Goda, S., El Sherif, F., Khattab, S., Hassanean, A., Alnefaie R., Alnefaie, D., Alnefaie M., and Ibrahim A. (2023): In Vitro Micropropagation of Endangered Achillea fragrantissima Forssk. Combined with Enhancement of Its Antihyperglycemic Activity. *Agronomy*, 13(2), 278.

Hala E., (2018): Evaluation of the Efficacy of Corn Silk and Vitamin D on Hyperlipidemia and Obesity in Experimental Rats. *Journal of Food and Dairy Sciences*. Article 21, [Volume 03, Issue 3](#), Page 169-175

Hassarajani S., Souza T., Mengi S. and Chattopadhaya Y. (2007): Efficacy study of the bioactive fraction (F-3) of *Acorus calamus* in hyperlipidemia. *Indian Journal of Pharmacology*, Vol. 39, No. 4, pp. 196-200.

- Henry, R. (1974):** Creatinine measurement with colorimetric method. In clinical Chem., Principles and technics. Second edition, Haper and Row publishers. hepatocytes. *Cancer Lett*, 97: 61-67.
- Hu, Q. and Deng, Z. (2011):** Protective effects of flavonoids from corn silk on oxidative stress induced by exhaustive exercise in mice. *Afr. J. Biotechnol.* ;10:3163–3167.
- Jae H., Sun R., Hyun J., Myung H., Ae W. and Woo K. (2016):** Corn silk extract improves cholesterol metabolism in C57BL/6J mouse fed high-fat diets. [Nutr Res Pract.](#) 2016 Oct; 10(5): 501–506.
- Kim SL, Kim MJ, Lee YY, Jung GH, Son BY, Lee JS, Kwon YU and Park YI. (2014):** Isolation and identification of flavonoids from corn silk. *Korean J Crop Sci.* 59:435–444.
- Liuyi W., Hao W., Xufeng W., Li W., Bo C. and Yunhui C. (2024):** Comprehensive review of plant-derived anti-hyperlipidemia peptides: Production, anti-hyperlipidemia mechanism, and structure-activity relationship study. *Journal of Food Chemistry. Volume 461*, 140715.
- Lopez-Virella M., Stone S., Ellis S. and Collwell G., (1977):** Cholesterol determination in density lipoproteins separated by their different in method; *Clinical Chemistry*, (5) 23: 882-886.
- Miriam,j.G.,Induja,T.A., Manoj,J.B. and Shivasamy, M.S. (2015):** Recent trends in effective utilization of by-product corn, *Indain Journal of Science*,22(76),18-26.
- Mohammadi, A., Ali, A., Mehdi, H., Seyedeh, M., Mojtaba, D., and Fatemeh, G. (2024):** Hypolipidemic and hepatoprotective effects of corn silk extract in nicotine-administered male mice. *Gastroenterol Hepatol Bed Bench.* 17(1): 64–73.
- Nishikimi, M., Appaji, N. and Yagi, K. (1972):** The occurrence of superoxide anion in the reaction of reduced phenazine methosulphate and molecular oxygen. *Biochem. Biophys. Res. Commun.*; 46(2): 849–854.
- Northover, B. and Subramanian, G. (1962):** Pedal inflammation induced by chemical agents. *British Journal of Pharmacology*, 18:346-349.
- Reeves, P.; Nielsen, F. and Fahmy, G. (1993):** Purified diets for laboratory rodents : Final report of the American Institute of Nutrition writing committee on the reformulation of the AIN- 76 a rodent diet. *J. Nurtr.* 123(51): 1939 – 1951.
- Roy, E., (1970):** Colorimetric determination of Co. St Louis. Toronto. Princeton; 1088-1273.
- Sanad, M., Abeer, H., and Naglaa E. (2022):** Evaluating the Effect of Moringa Peregrina (Forssk.) Fiori seeds on some Biochemical and Oxidative Stress Markers in Obese Experimental Rat. *Scientific Journal for Damietta Faculty of Science* 12(1), 156-162.

Sherwin, J. (1984): Liver Function. In Kaplan LA, Pesce AJ, eds. Clinical chemistry, theory, analysis, and correlation. St Louis: Mosby 55(25):420-438.

Snedecor, G. and Cochran, W. (1980): Statistical methods., 7th Ed., Iowa State University Press, Ames, USA (90).

Stow, J., Ching Low C., Offenhauser P. and Sangermani D. (2009): Cytokine secretion in macrophages and other cells: pathways and mediators. *Immunobiology* 214: 601–614.

Sukandar, Y., Sigil, J. and Ferdiana, L. (2013): Study of kidney repair mechanisms of corn silk (*Zea Mays* L. Hair Binahong (*Anredera cordifolia* (Ten) Steenis) Leaves combination in rat model of kidney failure, *International Journal of Pharmacology*, ISSN 1811-7775.

Wang G., Tao X. and Bao Y. (2012): Anti-inflammation effects of corn silk in a rat model of carrageenin-induced pleurisy. PMID: 21898269 ; 35(3):822-7.

Yan Z., Liying W., Zhongsu M., Jia C. and Jingbo L. (2016): Anti-Diabetic, Anti-Oxidant and Anti-Hyperlipidemic Activities of Flavonoids from Corn Silk on STZ-Induced Diabetic Mice. *Molecules*, 21(1), 7.

Yasir A., Mohammed H., Hamood A., Mohammed A., Fahd A., Meshari A. and Babu J. (2023): Effect of *Achillea fragrantissima* Extract on Excision Wound Biofilms of MRSA and *Pseudomonas aeruginosa* in Diabetic Mice. *Int J Mol Sci.* 5; 24 (11):9774.

Young, D. (1990): Effect of drugs on clinical laboratory tests. *Am. J. Clin. Pathol* 3(7):6-12.