

# Sensitivity of indocyanine green fluorescence imaging system for sentinel lymph node biopsies in early breast cancer patients

Original  
Article

Abdel-Rahman A. Zarka<sup>a</sup>, Abdelrazek Mohammed Abdelrazek<sup>a</sup>, Ashraf Abdelmoghny<sup>a</sup>,  
Mohamad El Azazy<sup>a</sup>, Amira Maher<sup>b</sup> and Karim F. Abd Elmoaty<sup>a</sup>

Department of General Surgery, Faculty of Medicine, <sup>a</sup>Ain Shams University, Cairo, <sup>b</sup>Galala  
University, Suez, Egypt.

## ABSTRACT

**Background:** Management in breast cancer is heading towards less invasive approaches with high survival and low recurrence rates. Axillary lymph node dissection (ALND) has a high morbidity in breast cancer patients; on the other hand, sentinel LN biopsy (SLNB) overcomes such morbidity with comparable survival and recurrence rates. A lot of substances used as tracers for sentinel LN (SLN), however, some of them still have several drawbacks. Indocyanine green (ICG) is one of those tracers that's recently used in SLN mapping.

**Patients and Methods:** Forty patients with early breast cancer presented at breast surgery unit at Ain Shams University hospitals from June 2022 till June 2023 underwent SLN detection using ICG followed by ALND if the sentinel lymph node was positive for metastatic disease.

**Outcome:** In this study, we aim to assess the diagnostic accuracy of ICG dye in SLNB in patients with early breast cancer.

**Results:** The mean age of our participants was 50.48±9.71. ICG SLNB was negative in 27 patients. The ICG dye was capable of detecting the positive lymph node metastasis in 13 patients with detection rate, sensitivity, specificity, accuracy, and positive and negative predictive values of 100% based on the total number of patients (n=40).

**Conclusion:** The ICG guided SLNB is a feasible, easy, and cost-effective method for the identification of SLN. It is also considered a highly sensitive, specific technique with a high detection rate of sentinel nodes and transcutaneous identification of lymphatic flow pathways with high safety and with no side effects from ICG. This technique has great potential to be an alternative method for the traditional sentinel node biopsy using the radioactive agents or the blue dyes..

**Key Words:** Breast cancer patients, indocyanine green fluorescence imaging, sentinel lymph node biopsies.

**Received:** 15 September 2024, **Accepted:** 16 October 2024, **Published:** 1 January 2025

**Corresponding Author:** Abdel-Rahman A. Zarka, MSc, Department of General Surgery, Faculty of Medicine, Ain Shams University, Cairo, Egypt. **Tel.:** 01019513893, **E-mail:** abdelrahman.zarka@med.asu.edu.eg

**ISSN:** 1110-1121, January 2025, Vol. 44, No. 1: 474-483, © The Egyptian Journal of Surgery

## INTRODUCTION

In recent years, with the application of sentinel lymph node (SLN). According to a recent report by Globocan 2020, female breast cancer is the most commonly diagnosed cancer in 2020, with an estimated 2.3 million new cases, representing 11.7% of all cancer cases. It is the fifth leading cause of cancer mortality worldwide, with 685 000 deaths, representing 6.9% of all cancer deaths. In Egypt, breast cancer is the second most commonly diagnosed cancer and the second leading cause of cancer deaths following liver cancer<sup>[1]</sup>.

The diagnosis and treatment of early breast cancer have significantly improved over the last few decades due to better screening methods, risk prediction models, and better understanding of gene expressions. The increase in detection rate of early-stage breast cancer has magnified the importance of less invasive management of clinically negative axilla and decreased unnecessary axillary lymph nodes dissection (ALND)<sup>[2]</sup>.

Nodal status is the most powerful determinant for prognosis and subsequent adjuvant therapies. SLN is an accurate diagnostic technique, and a reliable indicator of the metastatic status of the axilla<sup>[3]</sup>.

ALND has been traditionally used to evaluate axillary involvement and local control in women with node-negative breast cancer. However, conventional axillary dissection is associated with considerable morbidity, including lymphedema, pain, and shoulder stiffness<sup>[4]</sup>.

The SLN is defined as the first LN receiving lymphatic drainage from the breast and represents the actual nodal status. SLN biopsy (SLNB) is currently the standard of care for staging the axilla and decreases morbidity after lymphadenectomy<sup>[5]</sup>.

SLNB has become a standard procedure in early breast cancer detection, not only in western countries but also in Egypt, and large-scale studies have shown the drawbacks of ALND on the outcomes of patients with SLN-negative breast cancer<sup>[6]</sup>.

Five-year overall survival in patients with negative SLNB who did not undergo ALND was found to be equivalent to those who underwent ALND<sup>[7]</sup>.

Moreover, the American College of Surgeons Oncology Group's Z0011 trial suggested that avoidance of an ALND may be permitted even for SLN-positive patients<sup>[3]</sup>.

The American Society of Clinical Oncology's guideline recommendations published in 2014 stated that women without SLN metastases should not receive an ALND and that women with one to two metastatic SLNs planning to undergo breast-conserving surgery with whole-breast radiation should not undergo ALND in most cases<sup>[8]</sup>.

Radioisotope (RI) technetium-99m (RI) was the first tracer used to map SLN in 1993<sup>[9]</sup>, followed by blue dye (BD) in 1994<sup>[10]</sup>, then a gold standard for lymphatic mapping was a combination of both BD and RI<sup>[11]</sup>.

Breast cancer clinical practice guidelines currently available in Japan recommend an SLNB using a combination of the BD and RI methods based on several reports<sup>[12]</sup>.

However, RI has the disadvantages of requiring a radioactive facility, causing radiation exposure, and a high cost. In contrast, the blue dye method is easy to perform, even though SLN identification rate is reported to be lower when compared with the RI method, and some patients experience an allergic reaction<sup>[13]</sup>.

Patent blue V dye is a commonly used BD, it is easy to handle and cost-effective, yet alone, it has lower detection and higher false-negative rates and cannot be seen through skin or fatty tissues. Additionally, it can cause allergic reactions in rare cases up to anaphylaxis, and skin tattooing which may not fade after several months<sup>[14]</sup>.

The above-mentioned limitations of both standard tracers have led to the development of alternative contrast agents for SLNB such as indocyanine green (ICG) optical imaging, micro-bubble contrast agent, and super paramagnetic iron oxide guided SLNB with encouraging results in early breast cancer cases<sup>[15]</sup>.

ICG was first used in 1999 as a visible dye in daylight in detecting SLN in breast cancer<sup>[16]</sup>.

In 2005, ICG was first introduced for fluorescence visualization of lymphatic channels and SLNB in breast cancer<sup>[17]</sup>.

ICG in plasma emits light at the wavelength of 760 nm and produces fluorescence at 830 nm, which is visualized as a real-time image with a photodynamic eye camera. Therefore, the ICG fluorescence method is suited for intraoperative SLNB<sup>[17,18]</sup>.

Moreover, fluorescence is more sensitive than RI<sup>[19]</sup> and the ICG can spread further within the lymphatic basin

because of its low molecular weight water-soluble green dye with near-infrared (NIR) fluorescent properties and is approved by the US Food and Drug Administration in determining cardiac output, hepatic clearance, and ophthalmic perfusion low molecular weight<sup>[20]</sup>.

### **Aim**

To evaluate the efficacy and feasibility of the ICG fluorescence technique in SLN detection rate, number of SLNs, sensitivity, false-negative rate, safety and cost.

### **PATIENTS AND METHODS:**

It is a prospective pilot study including 40 patients diagnosed with early breast cancer from a breast surgery clinic at Ain Shams University hospitals from June 2022 to June 2023. Patients underwent SLN detection using ICG followed by ALND if the SLN was positive for metastatic disease.

Patients included were pathologically confirmed breast cancer patients (Tis/T1/T2 N0 M0) and clinically and radiologically free axillary LNs. Patients who received neoadjuvant chemotherapy were pregnant or refused consent were excluded.

All patients were subjected to triple assessment (clinical assessment, radiological assessment, and core needle biopsy), after confirming the diagnosis of breast cancer. Metastatic workup and preoperative workup were done. All cases were discussed in the multidisciplinary team weekly meeting.

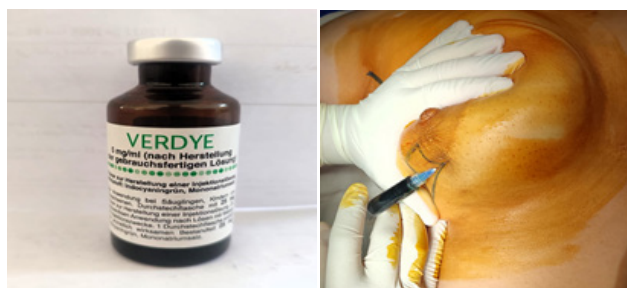Approval was obtained from the Ethics Review Committee at Ain-Shams University. Informed consent was obtained from all participants. Preoperative data collection included clinic-pathological data such as tumour site, grade, tumour pathology, hormone receptor status, and TNM classification. Postoperative data included morbidity and mortality.

The surgical technique was done by well-trained surgeons on SLNB procedure, as follows after induction of general anesthesia, the patient positioning in a supine position with an abducted arm, then prepping and draping of the patient. Then an injection of 2 cm of previously prepared ICG solution (one vial of ICG (Verdye, Diagnostic Green, Aschheim-Dornach, Germany) containing 25 mg of lyophilized sterile powder was dissolved in 10 ml sterile distilled water to a concentration of 2.5 mg/ml). The injection was done using a 23-gauge needle intradermally into the peri areolar area at 3, 6, 9, and 12 o'clock positions then gentle massage was applied for 3–5 min before incision (Fig. 1).

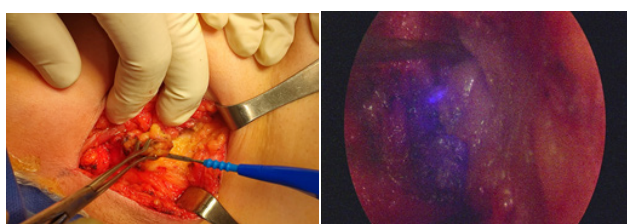
After 3.5–5.0 min of breast massage, the operating room light system was turned off with switching camera from normal to NIR mode to allow visualization of both anatomy and fluorescence signals, and then an appropriate skin incision was made at the point where the lymphatic

flow drained into the axillary area, and then the ICG stained lymph nodes were removed with the help of an ICG visualization system, the SN biopsy procedure was done. The system used was the HOPKINS NIR/ ICG scope, and D-LIGHT P light source, Karl Storz Endoskope, Tuttlingen, Germany (Fig. 2).


The resected lymph nodes were examined with an IMAGE 1 S camera system and were classified as SLNs or para-SLNs according to ICG fluorescence (Fig. 3).



**Fig. 1:** Injection of indocyanine green into retro-areolar area.



**Fi. 2:** The dissection of the stained sentinel lymph node by the indocyanine green dye.



**Fig. 3:** Specimen with the removed indocyanine green stained sentinel lymph node.

All fluorescence stained LNs were excised and sent for a frozen section to assess the positivity for LN metastasis.

In case SLNs were positive, then axillary clearance was done by excising level I and II LNs. All specimens eventually were sent for histopathological examination through paraffin embedded section.

### Statistical method

Statistical analysis was done using IBM SPSS statistics for windows, Version 23.0. Armonk, NY: IBM Corp. Sensitivity, specificity, accuracy, false negative rate, negative predictive value (NPV), positive predictive value (PPV), and diagnostic test performance (receiver operating characteristic curve) was calculated. The confidence interval was set to 95% and the margin of error accepted was set to.

### RESULTS:

Mean age of our study population was  $50.48 \pm 9.71$ . All patients were free from medical co-morbidities except 10 patients had co-morbidities such as hypertension, diabetes mellitus, and bronchial asthma. Most of the patients had negative family history for breast cancer except for six of them who had a history of first to second-degree relatives having breast cancer.

Mastectomy was performed in only four cases while breast conservative surgery was performed to majority of the cases. The mean BMI was  $27.2 \pm 2.58$  kg/m<sup>2</sup> and it ranged between 22 to 34 kg/m<sup>2</sup>. As shown in (Table 1).

The detailed clinical data and tumor characteristics are summarized in (Table 2), and were as follows, Mean size of the largest tumor was  $2.12 \pm 0.84$  ranging from (0.5–4), with 57.5% of the patients having T1 tumor located in the upper outer quadrant (UOQ) in most of cases.

Molecular classification was luminal A type in 85% of the patients. The axillary LN status was assessed clinically and radiologically by focused ultrasound to exclude a distinctly positive nodal status. 31 patients showed free axilla and nine patients with nonspecific lymphadenopathy. As shown in (Table 2).

All the patients had SLNB done, yet there were 13 (32%) patients identified with positive SLNB in frozen section and were followed by immediate ALND, among them five (46.7%) patients were T1 and T2 in eight (53.3%) patients.

The remaining 27 cases with negative SLNB were omitted further ALND with a mean number of 4 LNs retrieved as SLNB ranging from 3–6 LNs (Table 3).

The number of the ICG stained LNs in SLNB was four LNs in the majority of cases (52.5%). The 13 patients with positive SLNB, who underwent ALND were found to have an increased number of positive LN in the final paraffin section exceeding the number of positive LN retrieved in the SLNB meaning that there were seven positive LNs detected in paraffin section that were dissected in ALND and were not stained by ICG (Table 3).

Collectively, the total number of LNs retrieved among the 40 patients was 315 (100%) LNs. Among them 144 (45%) were stained by ICG, 121 (38.4%) LNs were removed in patients that underwent SLNB technique only and were negative in the frozen section, while 194 (61.6%) LNs were dissected from the remaining 13 patients with positive SLN in frozen section and had a complementary axillary clearance.

In this group of patients, 21 (6.7%) LNs were positive in frozen section biopsy while 28 (8.9%) were seen in the final paraffin section with seven LN not detected in the SLNB As shown in (Tables 3 and 4).

The ICG dye was capable of detecting the positive LN metastasis in 13 patients so the detection rate, sensitivity, specificity, accuracy and PPV and NPV of 100% based on the total number of patients (N=40). As shown in (Table 5).

Data analysis of the positive axillary LN group of patients only (no.=13) showed that the sensitivity of the sentinel technique to detect the positive LNs was 75% while the specificity and PPV was 100% and NPV 96% and accuracy 96.39%. As shown in (Table 6).

And this was slightly changed when we analysis data of all the study population in the term of NPV and accuracy (Table 7).

As regards postoperative complication among the group of ALND, there were patients presented with minimal to mild seroma formation 2 weeks postoperative which was aspirated guided with ultrasound and slight lymphedema on the long-term follow-up, one patient was complaining of tingling sensation and paresthesia. On revising those patient's history one of them was diabetic and two of them were obese with BMI greater than 30.

There was no wound infection or hematoma or wound dehiscence or limitation of arm movement, on the other hand there was no reported significant complication in the patients that underwent SLNB only. As shown in (Table 8).

**Table 1:** Demographic data and characteristics of the studied patients

	Total N=40 [n (%)]
Age	
Mean±SD	50.48±9.71
Range	35–70
Co-morbidities	
Negative	30 (75)
Positive	10 (25)
HTN	
No	33 (82.5)
Yes	7 (17.5)
DM	
No	33 (82.5)
Yes	7 (17.5)
Asthmatic	
No	39 (97.5)
Yes	1 (2.5)
Family history	
Negative	34 (85)
Positive	6 (15)
Marital status	
Single	9 (22.5)

Married	31 (77.5)
BMI	
BMI <25	15 (37.5)
BMI 26–29	22 (55)
BMI >30	3 (7.5)
Mean follow-up (months)	
Mean±SD	13.38±2.2
Range	9–17
Operation	
CBS	36 (90)
Mastectomy	4 (10)

DM, diabetes mellitus; HTN, hypertension

**Table 2:** Clinical and biological characteristics of the tumor among the studied patients

	Total N= 40 [n (%)]
Size of the largest tumor in (cm)	
Mean±SD	2.12±0.84
Range	0.5–4
Preoperative clinical T stage	
T1	23 (57.5)
T2	17 (42.5)
Radiological assessment of the axilla	
Free	31 (77.5)
Nonspecific lymphadenopathy	9 (22.5)
Side of the tumor	
Lt	21 (52.5)
Rt	19 (47.5)
Site of the tumor	
UOQ	16 (40)
LOQ (lower outer quadrant)	9 (22.5)
UIQ (upper inner quadrant)	5 (12.5)
LIQ (lower inner quadrant)	6 (15)
Central	4 (10)
Pathology diagnoses	
IDC (invasive ductal carcinoma)	30 (75)
ILC (invasive lobular carcinoma)	10 (25)
Histological grade	
Grade 1	8 (20)
Grade 2	32 (80)
Molecular classification	
luminal A	34 (85)
luminal B	5 (12.5)
Herr2 (human epidermal growth factor receptor)	1 (2.5)
TNBC (triple negative breast cancer)	0

Lt, left; Rt, right, UOQ, upper outer quadrant

**Table 3:** Descriptive data of the retrieved lymph nodes

		Total N=40 [ <i>n</i> (%)]
Technique		
Sentinel LN	27 (67.5)	
Sentinel LN followed by ALND	13 (32.5)	
Number of sentinel LNs stained by ICG		
2	1 (2.5)	
3	16 (40)	
4	21 (52.5)	
5	2 (5)	
Number of positive SLNs by frozen section		
0	27 (67.5)	
1	6 (15)	
2	6 (15)	
3	1 (2.5)	
Number of removed LN in SLNs patients		
Median (IQR)	<b>4 (4–5)</b>	
Range		<b>3–6</b>
Number of removed LN in SLNs + ALND patients		
Median (IQR)	15 (14–15)	
Range		13–18
Number of stained SLNs showing invasion by Paraffin section		
0	<b>27 (67.5)</b>	
1	<b>6 (15)</b>	
2	<b>6 (15)</b>	
3	<b>1 (2.5)</b>	
4		<b>0</b>
Total number of positive Ls detected by Paraffin section		
0	27 (67.5)	
1	3 (7.5)	
2	5 (12.5)	
3	5 (12.5)	

**Table 4:** Total number of lymph node removed by sentinel lymph node only or sentinel lymph node +axillary lymph node dissection and percentage of positive lymph node among the studied patients

Total removed LN, <i>n</i> (%)	315 (100.0)
Total stained LNs, <i>n</i> (%)	144 (45.7)
Positive sentinel LNs by frozen section, <i>n</i> (%)	21 (6.7)
Positive LNs by paraffin section, <i>n</i> (%)	28 (8.9)
Removed LN that underwent SLN only, <i>n</i> (%)	121 (38.4)
Removed LN that underwent SLN + ALND	194 (61.6)

**Table 5:** Assessment of the diagnostic accuracy of indocyanine green guided sentinel lymph node biopsy in histopathology in all study population (according to number of patients)

		Histopathology					
Paraffin Frozen	Negative <i>N</i> (%)	Positive <i>N</i> (%)	Sensitivity %	Specificity %	PPV %	NPV %	Accuracy %
SLN							
Negative	27 (100.0)	0	100	100	100	100.0	100.00
Positive	0	13 (100.0)					
Total	27 (100.0)	13 (100.0)					

PPV, positive predictive value; NPV, negative predictive value; SLN, sentinel lymph node

**Table 6:** Assessment of the diagnostic accuracy of SLN ICG guided in positive LN group of patients that underwent axillary clearance (according to number of LNs)

		Histopathology					
Paraffin Frozen	Negative <i>N</i> (%)	Positive <i>N</i> (%)	Sensitivity %	Specificity %	PPV %	NPV %	Accuracy %
SLN							
Negative	166 (100.0)	7 (25.0)	75	100	100	96.0	96.39
Positive	0	21 (75.0)					
Total	166 (100.0)	28 (100.0)					

ICG, indocyanine green, PPV, positive predictive value; NPV, negative predictive value; SLN, sentinel lymph node

**Table 7:** Assessment of the diagnostic accuracy of SLN ICG guided in whole study population (according to number of LNs)

		Histopathology					
Paraffin Frozen	Negative <i>N</i> (%)	Positive <i>N</i> (%)	Sensitivity %	Specificity %	PPV %	NPV %	Accuracy %
SLN							
Negative	287 (100.0)	7 (25.0)	75	100	100	97.6	97.8
Positive	0	21 (75.0)					
Total	<b>287 (100.0)</b>	<b>28 (100.0)</b>					

ICG, indocyanine green, PPV, positive predictive value; NPV, negative predictive value; SLN, sentinel lymph node

**Table 8:** Comparison between patients underwent sentinel lymph node and patients underwent sentinel lymph node then axillary lymph node dissection regarding rate of complications

	Sentinel LN <i>N</i> =27, <i>n</i> (%)	ALND <i>N</i> =13, <i>n</i> (%)	Test value	<i>P</i> value	Significance
Seroma formation					
Negative	27 (100.0)	10 (76.9)	6.736*	0.009	HS
Positive	0	3 (23.1%)			
Development of hematoma					
No	27 (100.0)	13 (100.0)	–	–	–
Yes	0	0			
Infection					
No	27 (100.0)	13 (100.0)	–	–	–
Yes	0	0			
Wound dehiscence					
No	27 (100.0)	13 (100.0)	–	–	–
Yes	0	0			
Arm numbness and paresthesia					
No	27 (100.0)	12 (92.3)	2.130*	0.144	NS
Yes	0	1 (7.7)			

Lymph edema of the arm					
No	27 (100.0)	9 (69.2)	9.231*	0.002	HS
Yes	0	4 (30.8)			
Limitation of arm movement					
No	27 (100.0)	13 (100.0)	–	–	–
Yes	0	0			
Cosmetic outcome					
Good	0	1 (7.7)	9.003*	0.011	S
Very good	3 (11.1)	6 (46.2)			
Excellent	24 (88.9)	6 (46.2)			

*P* greater than 0.05: nonsignificant (NS); *P* less than 0.05: Significant (S); *P* less than 0.01: highly significant (HS).

\*Chi-square test.

## DISCUSSION

Breast cancer is a growing threat. The Estimated future trends in total breast cancer cases/year, based on the available data in the Egyptian population will exceed 40 000 cases in 2040<sup>[21]</sup>.

There was significant progress in breast cancer diagnosis and management in the last decades<sup>[22]</sup>. Early diagnosis of breast cancer increases the chances of survival and, therefore, reduces mortality rates<sup>[23]</sup>.

Axillary LNs metastasis is considered the most important prognostic factor for the patients with breast cancer, so accurate staging and proper management of axillary LNs are crucial for the treatment of breast cancer. The survival rates decreased by 50% in patients with metastatic axillary LNs<sup>[24]</sup>.

In recent decades, surgery in breast cancer had evolved towards less invasiveness and morbidity. Nowadays SLNB is considered the standard of care in clinically negative axillary patients. SLNB emerged as a less invasive and less morbid choice with equal efficacy to ALND. Several techniques for SLN mapping exist including methylene BD, RI, and Carbon nanoparticles; however, the optimal modality remains challenging due to the pros and cons of each of these techniques<sup>[25]</sup>.

The optimal technique was thought to have high sensitivity, specificity, detection rate, and accuracy with low false negative rates, and best logistics in terms of cost, availability, and need for specific equipment.

The SLNB techniques depending on the radioactive colloids or blue dyes are difficult procedures with long learning curve. On the other hand, ICG/NIR fluorescence-guided SNB enables direct visualization of lymphatics and LNs which enables an easier learning curve and the evasion of complications that may result from unnecessary dissection<sup>[26]</sup>.

In our study, ICG had successfully identified SLN with excellent sensitivity, specificity and false negative rate of 100,100, and 0%, respectively.

These results were comparable with a study conducted in Cambridge Breast Unit, Addenbrooke's Hospital, Cambridge University Hospitals NHS Foundation Trust, on 100 women with clinically node negative breast cancer (95 unilateral; five bilateral) had SLNB using BD, RI, and ICG. Detection rates were: ICG alone 100%, ICG and BD 95.0%, ICG and RI 77.2%, ICG and BD & RI 73.1% and confirms the high sensitivity of ICG fluorescence for SLN detection in early breast cancer<sup>[27]</sup>.

Another one conducted at Shiga University of Medical Science, Seta-Tsukinowa, Japan enrolled 128 patients with clinically node-negative breast cancer and had similar results with a detection rate and sensitivity of 100% for the SLN mapping guided by ICG fluorescence imaging<sup>[28]</sup>.

In a recent network meta-analysis of 35 studies comparing different techniques for SLN detection, methylene BD had highest false negative rate 18.4% followed by RI (2.6%) and ICG (0.6%)<sup>[29]</sup>.

The higher detection rates of the ICG dye promotes it to be a better tracer for SNB procedure<sup>[30]</sup>. In all patients with observed subcutaneous lymphatic fluorescence spread (85.7%) the direction of the spread was towards the axilla. It was helpful to determine the site of the axillary incision<sup>[31]</sup>.

Studies showed that extraction of only one SN had a high risk of having a false negative result, while increasing the number of removed SNs, within limits, increased the accuracy and decreased the false negative rates.

Among our study population the number of SNs removed under the guidance of ICG/NIR was four LN

in 52.5% of total cases and this results in an excellent detection rate of pathologically positive nodes and helps in better assessment of axillary status.

This was comparable with the study of Hojo *et al.*, the average numbers of SLNs were 3.8 (fluorescence), 1.9 (blue dye only) and 2.0 (RI only). The average number of removed lymph nodes is higher in the ICG fluorescence technique because it can detect paralympathic tissue as well as SLNs.

And so, the mean number of SLNs removed guided with ICG/patient was 4.0 which is larger than that reported for the RI technique.

The lymphatic function declines with age, which may decrease the SN detection rate<sup>[20]</sup> but our study revealed that ICG/NIR detection rate was not affected by the increase in age. Liu *et al.* reported similar results<sup>[32]</sup>.

Obesity may also reduce the SN recognition rate, and layers of fat may obscure the visualization of the SN or may also hinder the lymphatic drainage<sup>[33]</sup>, however, our study showed that the fluorescence method can effectively overcome the effect of obesity on SNs detection.

Few recent reports and systemic reviews shows that ICG has a detection rate similar to RI with avoiding the disadvantages of RI as exposure to radiation, expensive cost and high radioactivity at Iry injection site may interfere with the detection of the nearby LNs<sup>[15]</sup>.

Thus, ICG may be a promising alternative for RI in SLN mapping, especially in countries where the use of RI is not feasible and only blue dye is the alternative technique<sup>[34]</sup>.

For tumors in the UOQ, diffusion of the RI causes substantial radioactive background, making identification of the SLN more difficult<sup>[35]</sup>. In our study, most of the study population (40%) was diagnosed with UOQ breast cancer however it did not affect SLN identification.

A famous meta-analysis based on six studies showed a false negative rate of using ICG equal 8%, which when compared with the National surgical adjuvant breast and bowel project B-32 including 5611 patients' false negative rate was 9.8% by using combined blue dye and RI double tracers and the value was comparable to that of ICG<sup>[36]</sup>.

Based on our results, ICG had a lower false negative rate (0%) in the term of number of patients however the 13 patients diagnosed with positive SLNB, who

underwent ALND were found to have increased number of positive LN in final paraffin section exceeding the number of the positive LN retrieved in the SLNB meaning that there were seven positive LNs detected in paraffin section that were dissected in ALND and were not stained by ICG, but this did not affect the false negative rate and specificity in our results as all the positive LN patients were successfully identified with the ICG dye.

Although ICG had a lower false negative rate compared with methylene blue, ICG had several cons including availability, cost, and need for special equipment (handheld fluorescence photodynamic eye camera)<sup>[37]</sup>.

Also, some problems remain to be solved: first it is difficult to perform fluorescence navigation and lymphatic dissection at the same time, since shadow less light in the operating room must be turned off during fluorescence observation; and second, the ICG contamination of the axilla with fluorescence with rough or blunt dissection leading to disruption of the lymphatics, this increases the difficulty to identify the SNs by ICG/NIR fluorescence. Contamination does not happen with fine manipulation and sharp dissection<sup>[25]</sup>.

None of our patients experienced any form of local or systemic adverse events; this finding was correlated to previous studies. In general, ICG is one of the safest medical dyes. Although few case reports reported anaphylactic reactions due to the iodine component, however, the exact pathophysiology was undetermined<sup>[38]</sup>.

Our experiences show that the ICG florescence SLNB appears to provide all surgeons with accurate location of the SLNs and optimal time to start SLNB and does not need special training with short-term learning curve.

In our study there was no long-term postoperative follow-up to assess the local axillary recurrence and survival rate of the patients and we focused on evaluating the efficacy and feasibility of the ICG fluorescence technique in SLNB in term of detection rate, number of SLNs, sensitivity, false-negative rate, safety, and cost.

## CONCLUSION

The ICG guided SLNB is a feasible, easy, and cost-effective method for identification of SLNs. It is also considered highly sensitive, specific technique with high detection rate of SNs and transcutaneous identification of lymphatic flow pathways with high safety and with no side effects from ICG. This



technique has a great potential to be an alternative method for the traditional SNB using the radioactive agents or the blue dyes.

### CONFLICT OF INTEREST

There are no conflicts of interest.

### REFERENCES

- Sung H, Ferlay J, Siegel RL, Laversanne M, Soerjomataram I, Jemal A, Bray F. Global cancer statistics 2020: GLOBOCAN estimates of incidence and mortality worldwide for 36 cancers in 185 countries. *CA Cancer J Clin* 2021; 71:209–249.
- Goonawardena J, Yong C, Law M. Use of indocyanine green fluorescence compared to radioisotope for sentinel lymph node biopsy in early-stage breast cancer: systematic review and meta-analysis. *Am J Surg* 2020; 220:665–676.
- Giuliano AE, Hunt KK, Ballman KV, Beitsch PD, Whitworth PW, Blumencranz PW, *et al.* Axillary dissection vs no axillary dissection in women with invasive breast cancer and sentinel node metastasis: a randomized clinical trial. *JAMA* 2011; 305:569–575.
- Mansel RE, Fallowfield L, Kissin M, Goyal A, Newcombe RG, Dixon JM, *et al.* Randomized multicenter trial of sentinel node biopsy versus standard axillary treatment in operable breast cancer: the ALMANAC Trial. *J Natl Cancer Inst* 2006; 98:599–609.
- Purushotham AD, Upponi S, Klevesath MB, Bobrow L, Millar K, Myles JP, Duffy SW. Morbidity after sentinel lymph node biopsy in primary breast cancer: results from a randomized controlled trial. *J Clin Oncol* 2005; 23:4312–4321.
- Rutgers EJ. Sentinel node biopsy: interpretation and management of patients with immunohistochemistry-positive sentinel nodes and those with micro metastases. *J Clin Oncol* 2008; 26:698–702.
- Zahoor S, Haji A, Battoo A, Qurieshi M, Mir W, Shah M. Sentinel lymph node biopsy in breast cancer: a clinical review and update. *J Breast Cancer* 2017; 20:217–227.
- Lyman GH, Temin S, Edge SB, Newman LA, Turner RR, Weaver DL, *et al.* Sentinel lymph node biopsy for patients with early-stage breast cancer: American Society of Clinical Oncology clinical practice guideline update. *J Clin Oncol* 2014; 32:1365–1383.
- Krag DN. Surgical resection and radio localization of the sentinel lymph node in breast cancer using a gamma probe. *Surg Oncol* 1993; 2:270–278.
- Spivack B, Khanna MM, Tafra L, Juillard G, Giuliano AE. Margin status and local recurrence after breast-conserving surgery. *Arch Surg* 1994; 129:952–957.
- Ferrucci, M., Franceschini, G., & Douek, M. (2018). New techniques for sentinel node biopsy in breast cancer. *Translational Cancer Research*, 7, S405–S417.
- Noguchi M, Motomura K, Imoto S, Miyauchi M, Sato K, Iwata H, *et al.* A multicenter validation study of sentinel lymph node biopsy by the Japanese Breast Cancer Society. *Breast Cancer Res Treat* 2000; 63:31–40.
- Kim T, Giuliano AE, Lyman GH. Lymphatic mapping and sentinel lymph node biopsy in early-stage breast carcinoma: a metaanalysis. *Cancer* 2006; 106:4–16.
- James TA, Coffman AR, Chagpar AB, Boughey JC, Klimberg VS, Morrow M, *et al.* Troubleshooting sentinel lymph node biopsy in breast cancer surgery. *Ann Surg Oncol* 2016; 23:3459–3466.
- Ahmed M, Purushotham AD, Douek M. Novel techniques for sentinel lymph node biopsy in breast cancer: a systematic review. *Lancet Oncol* 2014; 15:e351–e362.
- Motomura K, Inaji H, Komoike Y, Kasugai T, Noguchi S, Koyama H. Sentinel node biopsy guided by indocyanin green dye in breast cancer patients. *Jpn J Clin Oncol* 1999; 29:604–607.
- Kitai T, Inomoto T, Miwa M, Shikayama T. Fluorescence navigation with indocyanine green for detecting sentinel lymph nodes in breast cancer. *Breast Cancer* 2005; 12:211–215.
- Jung SY, Kim SK, Kim SW, Kwon Y, Lee ES, Kang HS, *et al.* Comparison of sentinel lymph node biopsy guided by the multimodal method of indocyanine green fluorescence, radioisotope, and blue dye versus the radioisotope method in breast cancer: a randomized controlled trial. *Ann Surg Oncol* 2014; 21:1254–1259.
- Ballardini B, Santoro L, Sangalli C, Gentilini O, Renne G, Lissidini G, *et al.* The indocyanine

- green method is equivalent to the <sup>99m</sup>Tc-labeled radiotracer method for identifying the sentinel node in breast cancer: a concordance and validation study. *Eur J Surg Oncol (EJSO)* 2013; 39:1332–1336.
20. Sugie T, Sawada T, Tagaya N, Kinoshita T, Yamagami K, Suwa H, *et al.* Comparison of the indocyanine green fluorescence and blue dye methods in detection of sentinel lymph nodes in early-stage breast cancer. *Ann Surg Oncol* 2013; 20:2213–2218.
  21. National Plans | ICCP Portal. WHO - Cancer Country Profiles Egypt 2020
  22. Miller KD, Nogueira L, Mariotto AB, Rowland JH, Yabroff KR, Alfano CM, *et al.* Cancer treatment and survivorship statistics, 2019. *CA Cancer J Clin* 2019; 69:363–385.
  23. Brown GR, Jones KT. Incidence of breast cancer in a cohort of 5,135 transgender veterans. *Breast Cancer Res Treat* 2015; 149:191–198.
  24. Malhotra C, Pawar R, Patni S, Sucheta ■, Kaushik M, Sharma N. Efficacy of periareolar versus peritumoral injection of TC99-labelled sulphur colloid and methylene blue dye for detection of sentinel lymph node in patients with early breast cancer: a comparative study. *Indian J Surg Oncol* 2021; 12:119–123.
  25. Agrawal SK, Hashlamoun I, Karki B, Sharma A, Arun I, Ahmed R. Diagnostic performance of indocyanine green plus methylene blue versus radioisotope plus methylene blue dye method for sentinel lymph node biopsy in node-negative early breast cancer. *JCO Global Oncol* 2020; 6:1225–1231.
  26. Schaafsma BE, Mieog JS, Hutteman M, Van der Vorst JR, Kuppen PJ, Löwik CW, *et al.* The clinical use of indocyanine green as a near-infrared fluorescent contrast agent for image-guided oncologic surgery. *J Surg Oncol* 2011; 104:323–332.
  27. Wishart GC, Loh SW, Jones L, Benson JR. A feasibility study (ICG-10) of indocyanine green (ICG) fluorescence mapping for sentinel lymph node detection in early breast cancer. *Eur J Surg Oncol (EJSO)* 2012; 38:651–656.
  28. Abe H, Mori T, Umeda T, Tanaka M, Kawai Y, Shimizu T, *et al.* Indocyanine green fluorescence imaging system for sentinel lymph node biopsies in early breast cancer patients. *Surg Today* 2011; 41:197–202.
  29. Mok CW, Tan SM, Zheng Q, Shi L. Network meta-analysis of novel and conventional sentinel lymph node biopsy techniques in breast cancer. *BJS open* 2019; 3:445–452.
  30. Guo J, Yang H, Wang S, Cao Y, Liu M, Xie F, *et al.* Comparison of sentinel lymph node biopsy guided by indocyanine green, blue dye, and their combination in breast cancer patients: a prospective cohort study. *World J Surg Oncol* 2017; 15:1–7.
  31. Ban EJ, Lee JS, Koo JS, Park S, Kim SI, Park BW. How many sentinel lymph nodes are enough for accurate axillary staging in t1-2 breast cancer?. *J Breast Cancer* 2011; 14:296–300.
  32. Liu J, Huang L, Wang N, Chen P. Indocyanine green detects sentinel lymph nodes in early breast cancer. *J Int Med Res* 2017; 45:514–524.
  33. Derossis AM, Fey JV, Cody III HS, Borgen PI. Obesity influences outcome of sentinel lymph node biopsy in early-stage breast cancer. *J Am Coll Surg* 2003; 197:896–901.
  34. Ang CH, Tan MY, Teo C, Seah DW, Chen JC, Chan MY, Tan EY. Blue dye is sufficient for sentinel lymph node biopsy in breast cancer. *J Br Surg* 2014; 101:383–389.
  35. Vidya R, Khosla M, Laws S, Harvey J, Kaushik M, Mullanpudi NA, Macmillan D. Axillary sentinel lymph node identification using superparamagnetic iron oxide versus radioisotope in early stage breast cancer: The UK SentiMag trial (SMART study). *Surg* 2023; 21:128–134.
  36. Krag K. Technical outcomes of sentinel-lymph-node resection and conventional axillary-lymph-node dissection in patients with clinically node-negative breast cancer: results from the NSABP B-32 randomized phase III trial. *Lancet Oncol* 2007; 8:881–888.
  37. He PS, Li F, Li GH, Guo C, Chen TJ. The combination of blue dye and radioisotope versus radioisotope alone during sentinel lymph node biopsy for breast cancer: a systematic review. *BMC Cancer* 2016; 16:1–2.
  38. Bjerregaard J, Pandia MP, Jaffe RA. Occurrence of severe hypotension after indocyanine green injection during the intraoperative period. *A&A Practice* 2013; 1:26–30.