

# Inflammatory myofibroblastic tumor: A clinical point of view Cardiothoracic surgery department, Al-Azhar University, case reporte

## Case Report

*Marwa R. Mohamed and Wasiem A. Mohammed*

*Department of Cardiothoracic Surgery, Faculty of Medicine (for girls), Al-Azhar University,  
Cairo, Egypt.*

### ABSTRACT

**Introduction:** Inflammatory myofibroblastic tumor (IMT) is a rare mesenchymal tumor usually seen in the first and second decade. They are very rare in adults, constituting less than 1% of adult lung tumors. It is usually benign, but it has an affinity for local recurrence. We reported a case of IMT in the lung in a 49-year-old male. In our setting, the case report was interesting due to the recurrent accumulation of the effusion until a pathological assessment was done.

**Discussion:** We reported this case in hopes it may aid clinicians in broadening their preoperative differential diagnosis. That is because IMT has an ambiguous clinical presentation, and needs to be differentiated from other lesions based on histopathological findings and immunohistochemical analysis. Usually, the diagnosis is made by pathological examination after complete surgical excision, which is the mainstay treatment advocated.

**Conclusion:** IMT is a rare benign tumor. Clinical and radiological presentation is variable and nonspecific and the diagnosis is rarely made before surgical management. Only histopathology can confirm the diagnosis.

**Key Words:** Pleural effusion, rare tumor, recurrent.

**Received:** 11 August 2024 2024, **Accepted:** 14 September 2024, **Published:** 1 January 2025

**Corresponding Author:** Marwa Ramadan Mohamed, MD, Department of Cardiothoracic Surgery, Faculty of Medicine (for girls), Al-Azhar University, Cairo, Egypt. **Tel.:** 01003090067, **E-mail:** marwaramadan.el20@azhar.edu.eg

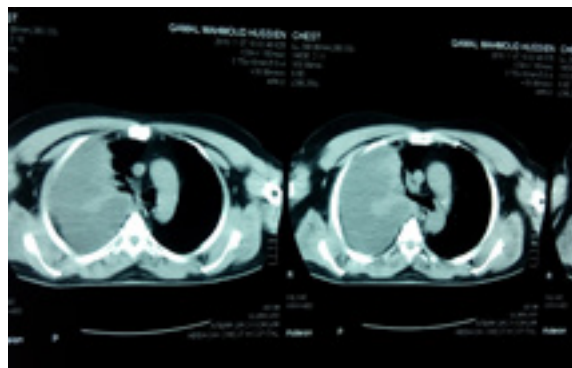
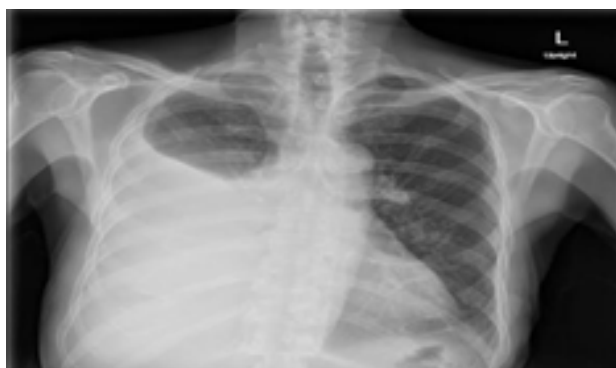**ISSN:** 1110-1121, January 2025, Vol. 44, No. 1: 528-532, © The Egyptian Journal of Surgery

### CASE PRESENTATION:

Our case was a male patient 49 years old, hypertension, not diabetic, who has had a right side atypical chest pain in the form of bone ache not controlled by analgesia of 3 months duration. So he asked for medical advice and by examination there was a stony dullness in percussion and decreased air entry over the right side of the chest. He had no history of past medical illness or surgery. His family history was unremarkable, and had no congenital or inheritable diseases present in the family.

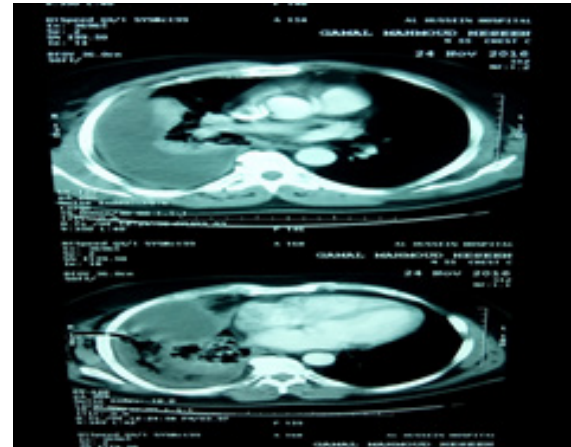
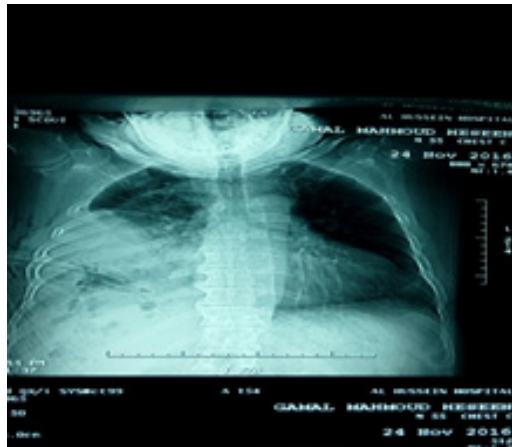
His vital signs and physical examination were unremarkable. Laboratory investigation showed: a mildly elevated white blood cell, and markedly elevated erythrocyte sedimentation rate (ESR), otherwise other investigations were normal. General physical examination and systemic examination besides the thorax were unremarkable.

Chest radiography showed a homogenous opacity at the right side of the chest rising to the axilla. Chest computed tomography scan showed a right side pleural effusion, with underlying lung collapse and mild pleural thickening.



Thoracocentesis was done twice within 1 week of about 1500 cc and the cytological examination of the effusion was not conclusive; Just an exudative reaction, free of atypical and malignant cells. The patient re accumulates massive effusion again very rapidly. At this stage in the workup of the case, the differential diagnosis most probably was malignancy due to :{ the rapid re accumulation of the effusion, elevated ESR, and the presentation of chest pain}.

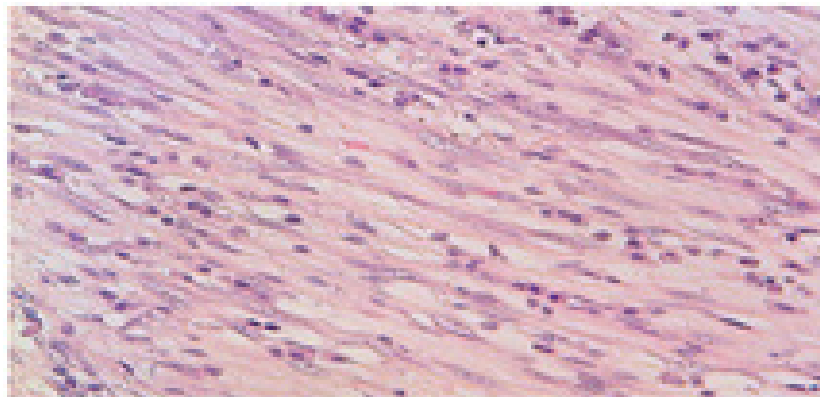
Because there's no definite histopathologic diagnosis that could be achieved through the cytological examination; the patient submits to a medical video-assisted thoracoscopic for diagnosis and treatment. The intraoperative findings include not only a pleural effusion but a dominant extensive adhesion and loculation so; a biopsy was taken from the pleura and the effusion, followed by the insertion of a chest tube.



#### ***Histopathology revealed:***

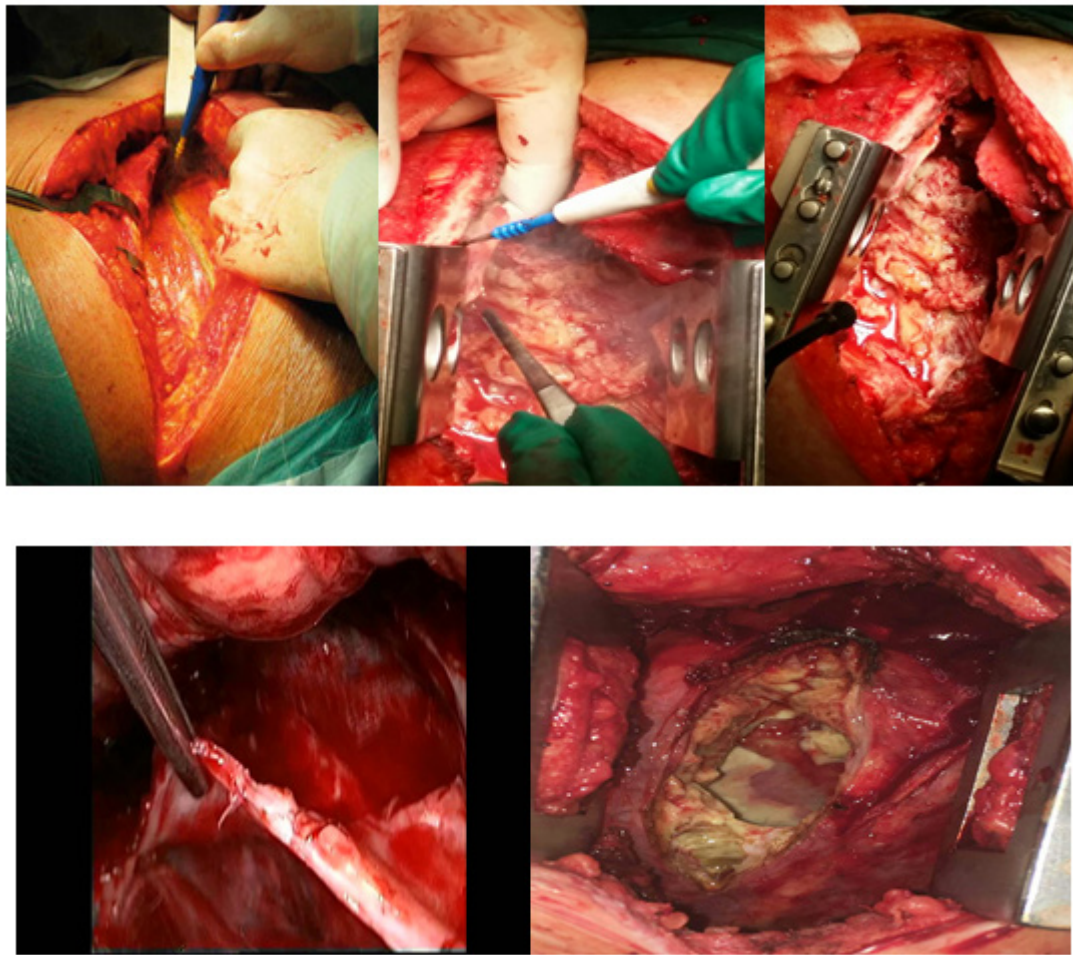
{Thick fibrotic pleura, with pleurisy, associated with exudative reaction}. The effusion re accumulate again. And the chest tube can not be removed, for more than 4 weeks. So the slide was reread.

Histopathology revealed inflammatory myofibroblastic tumor [IMT], which was confirmed by the strong positivity of the spindle cells for smooth muscle actin, while the reaction for ALK (Anaplastic Lymphoma Kinase), CD (Cluster of Differentiation), and calretinin was negative. According to these data; the diagnosis of IMT was confirmed.



Inflammatory myofibroblastic tumor is now known as a neoplastic lesion, and treatment is mainly surgical resection. So, the choice of surgery was for diagnostic

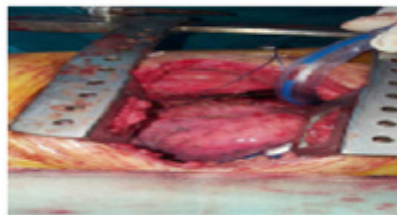
and therapeutic purposes, which was done via right-side decortication by posterolateral thoracotomy.



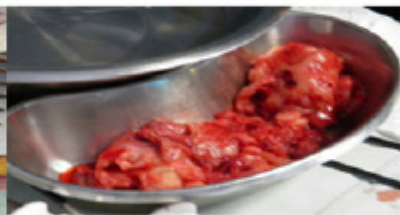On gross examination, the tumor was: {Huge in size, hard, homogeneous, and whitish in color} and on gross pathology: {in the surrounding lung tissue, infiltrative processes were found. There was an invasion in the mediastinum and pericardium with tumor-positive margins

at these sites}. Histopathology showed: a feature of {Spindle cell tumour}; which was established by immunophenotyping as {IMT}. After surgery, an oncological consultation was done and there was no recommendation of any chemo or radiotherapy.

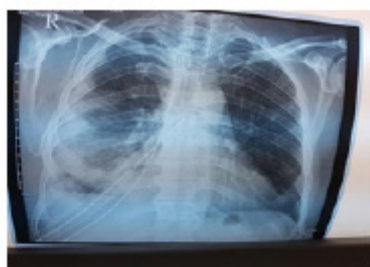
After decortication



The specimen



First day postoperative



## DISCUSSION

Inflammatory pseudo-tumors were first founded in 1905 by Birch-Hirschfeld, in the orbital tissues of four patients, with infiltration of the soft tissue with lymphocytes. IMT of the lung first described in 1939 was reported as a division of these Inflammatory pseudo-tumors<sup>[1]</sup>.

In 1994, the WHO defined IMT as an intermediate soft tissue tumor that is formed of myofibroblastic-differentiated spindle cells, inflammatory cells, plasma cells, and/or lymphocytes<sup>[2]</sup>.

This lesion has different names, such as plasma cell granuloma, xantho granuloma, inflammatory myofibroblastic proliferation, inflammatory pseudotumor, fibrous histiocytoma, plasma cell histiocytoma complex, and inflammatory fibro sarcoma<sup>[3]</sup>.

They are very rare tumors resemble less than 0.03% of all neoplasms. Its incidence is 2–4 cases/million/year with a wide age range at diagnosis<sup>[4]</sup>.

Commonly found in patients less than 40 years of age, with no sex preference. Endobronchial IMT is rare, with an incidence of 0–12%<sup>[5]</sup>.

Although it's a benign tumour; it tends recurrence. It usually has a benign clinical presentation, but malignant evolution has been described, with recurrent (between 2 and 25% of cases) and metastatic disease (less than 5% of cases)<sup>[3]</sup>.

The term pseudotumor was described because these lesions look like invasive malignant tumor, both clinically and radiologically. The most aggressive form of it; with documented metastasis, is known as: Inflammatory fibrosarcoma<sup>[2]</sup>.

The predisposing factors for this tumor are: previous trauma including surgical scars, hormonal factors, and genetic factors play a role. It commonly appears in young women during or after pregnancy and may regress after menopause, or after tamoxifen treatment thus suggesting the hormonal etiology of the lesion<sup>[6]</sup>.

Usually, it affects a single organ but multiple organs could be affected at the same time. any site can be involved, such as the brain, liver, spleen, lymph nodes, salivary glands, breast, soft tissues, and skin. The most common are the lung, abdominopelvic region, and retroperitoneum<sup>[7]</sup>.

In ~70% of cases, the disease is accidentally discovered, its symptoms are nonspecific and include

one or more of the following, cough, chest pain, shortness of breath, hemoptysis, fever, and fatigue, thus according to the site and size of the tumor<sup>[8]</sup>.

The Laboratory finding may include any of the following: microcytic anemia; increase in acute phase reactants such as ESR and C-reactive protein; thrombocytosis and polyclonal hyper gamma globulinemia, due to overproduction of interleukin 6<sup>[9]</sup>.

The radiography findings are nonspecific, the lesion may appear as a mass or a pulmonary nodule, either solitary or multiple, measuring 1–6 cm in diameter, sharply limited, and smooth. While by Computed tomography there is a heterogeneous nodule or mass with variable contrast enhancement. Calcifications and cavitations are rare. Pleural effusion is seen in less than 10% and atelectasis in 8% of cases<sup>[10]</sup>.

The lesion commonly affects the lower lobes, peripheral lung parenchyma, and subpleural locations. In 5% of cases, it extends to the mediastinum, diaphragm, pleura, or chest wall<sup>[11]</sup>.

The lesion may be bilateral, with endobronchial affection causing atelectasis. IMTs may show uptake of fluorodeoxyglucose; which is used as a monitor for the response to therapy<sup>[12]</sup>.

Imaging is necessary for surgical planning, demarcation of the tumor, and postoperative follow-up. However, the radiologic behavior is not diagnostic and a biopsy is mandatory for the final diagnosis<sup>[4]</sup>.

Fine needle aspiration biopsy and bronchoscopic samples are too small and insufficient for the diagnosis. Therefore, surgical excision of the lesion is the preferred diagnostic method<sup>[3]</sup>.

The histopathology shows myofibroblastic cells, arranged in a myxoid, fibrous, or calcified stroma associated with chronic inflammatory cells including lymphocytes, plasma cells, and eosinophils. Immunohistochemistry showed reactivity for vimentin and smooth muscle actin<sup>[13]</sup>.

Three histological patterns have been described. The first is loosely organized myofibroblasts in an edematous myxoid background with plasma cells, lymphocytes, eosinophils, and blood vessels, the second is dense aggregates of spindle cells in a variable myxoid and collagenized background with inflammatory infiltrate, plasma cells, and lymphoid nodules, and the third type is collagen sheets with scattered plasma cells and eosinophils<sup>[14]</sup>.

Therefore the differential diagnosis list is wide and includes localized fibrous tumors of the pleura, inflammatory pseudotumor, fibroma, mesothelioma, desmoplastic fibroblastoma, and metastatic disease<sup>[4]</sup>.

Other differential diagnoses include organized pneumonia, lymphoma, solitary fibrous tumor, desmoid fibromatosis, angiofibroma, fibrosarcoma, leiomyoma, and malignant fibrous histiocytoma<sup>[10]</sup>.

Surgical excision with a safety margin is the cornerstone for treatment. But in case of incomplete resection, medical therapy with radiation therapy could be considered. Rigid bronchoscopy and endobronchial resection are used for IMTs localized to the trachea<sup>[1]</sup>.

IMT has a variable course, ranging from spontaneous remission to multiple recurrences, regardless of the treatment modality<sup>[6]</sup>.

The prognosis depends on the size and the safety margin of the excised lesion. So with radical resection, the prognosis is excellent. Because this lesion has a tendency to recurrence so the patient affected by it needs close follow-up<sup>[3]</sup>.

## CONCLUSION

IMT is a rare benign tumor. Its clinical and radiological presentation is variable and nonspecific and the diagnosis is rarely made before surgical management. Only histological and immunohistochemical study can confirm the diagnosis. Despite being a benign lesion, its potential for recurrence and local invasion requires complete surgical resection. Most patients are cured by complete surgical resection.

Due to lack of accumulated experience, intrathoracic IMT should be under long-term follow-up.

## CONFLICT OF INTEREST

There are no conflicts of interest.

## REFERENCES

1. Khatri A, Agrawal A, Sikachi RR, Mehta D, Touro SS. Inflammatory Myofibroblastic Tumor of the Lung, Little Rock, USA. *Adv Respiratory Medicine* 2018; 86:27–35.
2. Gallego L, Santamarta TR, Blanco V, García-Consuegra L, Cutilli T, Junquera L. Case Report Inflammatory Myofibroblastic Tumor of the Lung and the Maxillary Region: A Benign Lesion with Aggressive Behavior. *Case Rep Dent* 2013; 2013:879792.
3. Brahama Y, Migaoua A, Njimab M, Achourc A, Saada AB, Mhamed SC, *et al.* Case report Inflammatory myofibroblastic tumor of the lung: A rare entity. *Respir Med Case Rep* 2020; 31:101287.
4. D'Hooghe L, Dekeyzer S, Dewaele T, Gieraerts K, Coenegrachts K. Images in Clinical Radiology: Intrathoracic Desmoid Tumor, Intrathoracic Desmoid Tumor. *J Belgian Soc Radiol* 2015; 99:123–124.
5. Iyer A, Radonic T, Heukamp LC, Thunnissen E, Daniels JMA, Iyer A, *et al.* Inflammatory myofibroblastic tumour of the central airways: treatment and molecular analysis *Thoracic Oncology. ERJ Open Res* 2021; 7:00151–02020.
6. Kim NR, Chung D-H, Lee J-I, Jeong SH, Ha S-Y. Intrathoracic Desmoid Tumor Mimicking Pleural Mass: A Case Report Departments of 1Pathology, 2Thoracic Surgery, 3Internal Medicine, Gachon University Gil Hospital, Incheon, Korea. *Tuberc Respir Dis* 2009; 67:5.
7. Marwah N, Bhutani N, Dahiya S, Sen R. Inflammatory pseudotumor: a rare tumor of lung. *Ann Med Surg* 2018; 36:106–109.
8. Sagar AES, Jimenez CA, Shannon VR. Clinical, histopathologic correlates and management strategies for inflammatory myofibroblastic tumor of the lung, A case series. *Med Oncol* 2018; 35:102.
9. Gómez-Román JJ, Sánchez-Velasco P, Ocejón-Vinyals G, *et al.* Presence of human herpesvirus-8 DNA sequences and overexpression of human IL-6 and cyclin D1 in inflammatory myofibroblastic tumor (inflammatory pseudotumor). *Lab Invest* 2000; 80:1121–1126.
10. Hammas N, Chbani L, Rami M, Boubbou M, Benmiloud S, Bouabdellah Y, *et al.* A rare tumor of the lung: inflammatory myofibroblastic tumor. *Diagn Pathol* 2012; 7:83.
11. Na Y, Park S. Inflammatory myofibroblastic tumor of the pleura with adjacent chest wall invasion and metastasis to the kidney: a case report. *J Med Case Rep* 2018; 12:253.
12. Dhoubi A, Barrazone C, Reverdin A, *et al.* Inflammatory myofibroblastic tumor of the lung: a rare cause of atelectasis in children. *Pediatr Radiol* 2013; 43:381–384.
13. Chauhan R, Sodhi K, Nada R, Virk R, Mathew J. Pediatric inflammatory myofibroblastic tumor of the trachea: imaging spectrum and review of literature. *Lung India* 2018; 35:516.
14. Coffin CM, Fletcher JA. 'Inflammatory myofibroblastic tumour :World Health Organization classification of tumors,' in *Pathology and Genetics of Tumors of Soft Tissue and Bone*, C. D. M. Fletcher, K. K. Unni, and F. Mertens, Eds., IARC Press, Lyon, France, 2002