

Case Reports

Dual Urethral plate Substitution in Staged Hypospadias Rrepair: Flap for the Shaft and Graft for the Glans

Amr Abdelhamid AbouZeid

Pediatric Surgery Department; Faculty of Medicine; Ain Shams University



ABSTRACT

Background: Regarding proximal hypospadias, there is worldwide trend back to two-stage repairs that involve transection of the urethral plate to prevent recurrence of chordee. However, there is an ongoing debate on the best urethral substitute: flaps versus grafts.

Case presentation: We present two primary cases of penoscrotal hypospadias who underwent two-stage repair while applying a modification of combined urethral plate substitution (flap + graft) during the first stage of repair. Skin flaps with its reliable blood supply provides a secure coverage for the penile shaft, while the thinner inner preputial graft is more suitable for the glans. The first boy was 42-month-old, while the second was 14-month-old at time of the first stage. Both cases had a straight penis with no residual chordee at follow up (6 months). Both were urinating freely (with no strictures) through a distal meatus. The site of the meatus was glanular in the first case, while it was distal penile (sub-coronal) in the second case.

Conclusion: The technique described in this report does not represent significant deviation from the standard/current practice for performing two-stage repair. Revisiting the buttonholing technique to re-cover the ventral shaft provides a smooth urethral plate for tubularization at second stage avoiding midline scars of the more popular Byars technique. Concomitant grafting of the under-surface of the glans represents the main modification to the standard flap technique aiming to facilitate glanular closure at the second stage.

Keywords: Flaps ; grafts ; penoscrotal ; proximal hypospadias; two-stage repair.

How to Cite: Amr Abdelhamid AbouZeid: Dual Urethral plate Substitution in Staged Hypospadias Rrepair: Flap for the Shaft and Graft for the Glans. *Ann Pediatr Surg.* 2024; 20:6, 1-4 DOI: 10.21608/APSJ.2024.255344.1048

BACKGROUND

Proximal hypospadias represents a persistent challenge with no consensus on the best type of repair^[1]. Recently, there has been an obvious worldwide trend back to two-stage repairs for proximal hypospadias^[2], which involve transection of the urethral plate to prevent recurrence of ventral curvature. However, there is an ongoing debate on the best urethral substitute: flaps versus grafts^[3]. In their report on the challenges with proximal hypospadias, Gong and Cheng described a combined flap and graft harvested from a transverse

island flap to substitute the urethral plate in two-stage repair; the dartos tissue is dissected off the distal end of the flap to create thinner graft lining for the incised glans^[4].

Here, we present a technique using the same principle of combined flap and graft to substitute the urethral plate in two-stage repair of proximal hypospadias.

CASE PRESENTATION

We present two primary cases of penoscrotal hypospadias

Received: 13 December 2023, Accepted: 26 August 2024

Corresponding Author: Amr Abdelhamid AbouZeid, Pediatric Surgery Department; Faculty of Medicine; Ain Shams University, Tel.: 0201116560566, E-mail: amrabelhamid@hotmail.com.

ISSN: 2090-0740, 2024

who underwent two-stage repair while applying a modification of combined urethral plate substitution (flap + graft) during the first stage of repair. The first boy was 42-month-old, while the second was 14-month-old at time of the first stage. No preoperative hormonal stimulation was used in either case. A similar surgical technique was applied in both cases as described below.

SURGICAL TECHNIQUE

First stage: We started by degloving of the penile skin. Ventral dissection was extended down to the scrotum exposing the bulbar urethra. Both cases had significant ventral curvature (chordee > 30°), for which the decision was made to sacrifice the urethral plate. The urethral plate together with all subjacent dysplastic tissue were meticulously excised to straighten the penile shaft while the meatus was relatively shifted to a more proximal position (neither ventral corporotomies, nor dorsal plication were applied). Part of the dorsal penile skin was transferred ventrally via ‘buttonholing’ to cover the penile shaft (figure 1); a plastic technique that was popularized by Reed Nesbit in 1941^[5]. Then, we shifted to the glans which was incised ventrally to create wide glanular wings. A free graft was harvested from the inner preputial skin, which was transversely placed within the split open glans. The graft was quilted to the glans and was further fixed with tie-over sutures over Vaseline gauze to facilitate its take (figure 2).

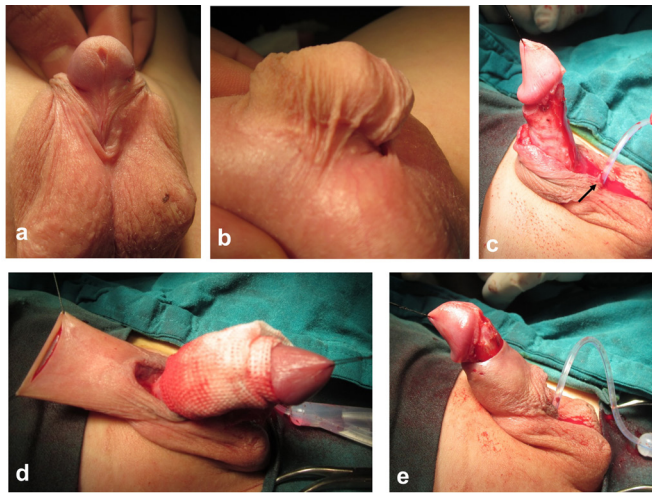


Fig.1: First case 42-month-old boy with penoscrotal hypospadias underwent two-stage repair. First stage: a) Preoperative photo demonstrating the phenotypic severity. b) Lateral view showing the configuration of the prepuce and dorsal penile skin (crooked prepuce). c) Degloving of penile skin and release of chordee by excision of urethral plate and subjacent dysplastic tissue, while the meatus is relatively transferred to a more proximal position (arrow). (d and e) Transfer of dorsal skin to cover ventral shaft via buttonholing

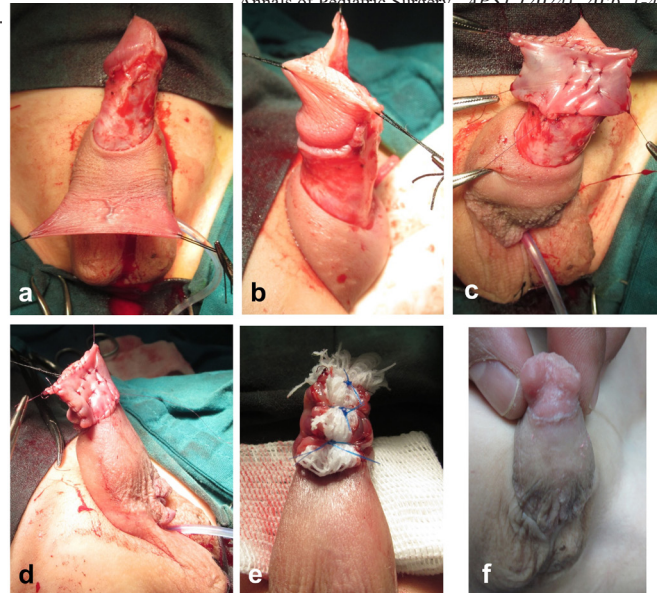


Fig.2: Continuing the first stage in first case: a) The penile shaft is covered by dorsal skin flap. b) The glans is incised ventrally to create wide glanular wings. c) A free graft (harvested from the inner preputial skin) is transversely placed within the split open glans. d) The graft is quilted to the glans. e) Tie-over sutures over Vaseline gauze. f) Good take of graft at two months follow-up.

Second stage: Six months later, a Thiersch-Duplay urethroplasty was performed to reconstruct the anterior urethra transferring the urinary meatus distally to the glans (figure 3). The urethroplasty was performed using polyglactin 6-0 continuous (full thickness) suturing technique; a second layer of interrupted sutures were applied at wide intervals to support the underlying continuous suture line of the urethroplasty. To decrease the incidence of fistulae, the urethroplasty was protected by second layer coverage using dartos (subcutaneous) flaps in the first case while the Smith technique (de-epithelialized double breasting skin closure) was used in the second case (figure 4)^[6,7].

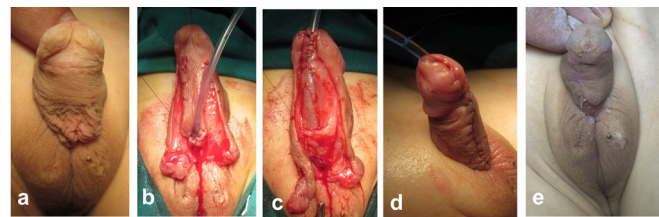


Fig. 3: The second stage for the first case (six months later). a) The penile ventrum covered by combined flap and graft in the first stage. b) Thiersch-Duplay urethroplasty. c) Dartos flaps to cover urethroplasty. d) At end of operation. e) Two months

later follow-up.

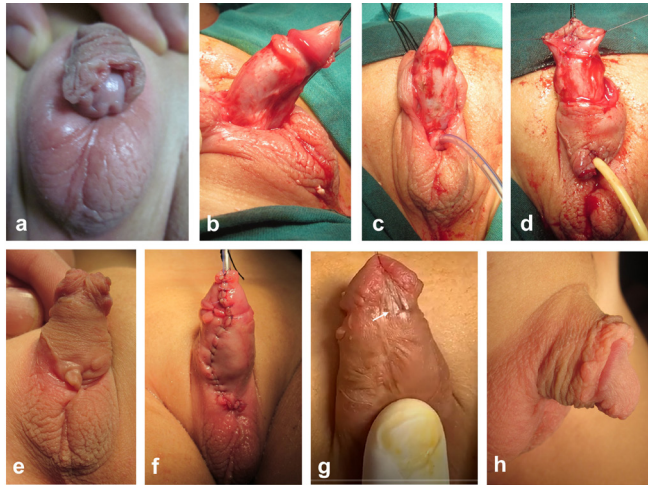


Fig.4: Second case 14-month-old boy with penoscrotal hypospadias underwent two-stage repair. Upper row (first stage): a) Preoperative photo. (b and c) Degloving of penile skin and release of chordee by excision of urethral plate and subjacent dysplastic tissue, while the meatus is relatively transferred to a more proximal position. (d and e) Transfer of dorsal skin to cover ventral shaft via buttonholing technique, while a free graft (harvested from the inner preputial skin) is transversely placed within the split open glans. Lower row (second stage six months later): e) The penile ventrum covered by combined flap and graft in the first stage. f) After completing Thiersch-Duplay urethroplasty. g) Sub-coronal meatus (arrow) at follow-up due to glanular dehiscence. h) Lateral view at follow-up demonstrating successful correction of ventral curvature

Follow-up after second stage: Both cases had a straight penis with no residual chordee at follow up (6 months). Both were urinating freely (with no strictures) through a distal meatus. The site of the meatus was glanular in the first case (figure 3e), while it was distal penile (sub-coronal) in the second case (figure 4g). The suboptimal position of the meatus in the second case is attributed to glanular disruption after second stage.

DISCUSSION

In early descriptions of staged hypospadias repair, the urethral plate was excised in the first stage and substituted by skin flaps to be tubularized (Thiersch-Duplay urethroplasty) six months later at the second stage^[5,8]. Later, grafts were introduced as an alternative to flaps in substituting the urethral plate^[8-11]. Advantages of grafts include better fixation of neourethra to the penis and availability even in circumcised and redo cases. However, grafts may be more liable for scarring, contractures, and shrinkage^[3,12]. On the other hand, flaps have reliable blood supply that have successfully stood the test of time with tried long-term follow up^[13]. The technique described in this report makes benefit of both flaps and grafts in substituting the urethral plate. The skin flaps

with its reliable blood supply provides a secure coverage for the penile shaft even when ventral corporeal lengthening procedures turns to be necessary^[14]. On the other hand, the thinner inner preputial graft is more suitable for the glans, avoiding the bulky subcutaneous tissue that may hinder glanular closure^[15].

Proximal hypospadias repair is associated with higher failure rates of glanular closure. This can be attributed to smaller size of the glans associating severe forms of hypospadias^[2]. Another factor may be related to the difficulty in providing a complete second layer coverage up to the most distal part of the longer neo-urethra in proximal hypospadias. In this report, we had a successful glanular closure in one, and a failure in the other ending with a distal/sub-coronal meatus. The latter may be considered both functionally and cosmetically accepted with respect to the original phenotypic severity of the case^[14,16]. Weighing the risk/benefit of reoperation to bring the meatus to a glanular position should be clearly discussed with parents.

The technique described in this report does not represent significant deviation from the standard/current practice for performing two-stage repair^[5,8,17]. Revisiting the buttonholing technique^[5] to re-cover the ventral shaft provides a smooth urethral plate for tubularization at second stage avoiding midline scars of the more popular Byars technique^[8,15]. Concomitant grafting of the under-surface of the glans represents the main modification to the standard flap technique aiming to facilitate glanular closure at the second stage. Although this aim was achievable in only 50%, yet this is just a preliminary report, while the technique still should be tested on a larger number of cases.

DECLARATIONS

Ethics approval and consent to participate: A written parental consent was taken before operation. The report was approved through expedited review by the scientific/ethical committee of the Pediatric Surgery department (Faculty of medicine; Ain-Shams University).

CONSENT FOR PUBLICATION:

Yes.

AVAILABILITY OF DATA AND MATERIAL

Yes on request.

COMPETING INTERESTS:

None.

FUNDING:

Self funded research. No external source.

AUTHORS' CONTRIBUTIONS:

Performed the surgery, reviewed the literature, writing the proposal, writing and reviewing the manuscript.

ACKNOWLEDGEMENTS:

None.

CONFLICT OF INTERESTS

No conflict of interest to declare.

REFERENCES

- Pippi Salle JL, Sayed S, Salle A, et al. Proximal hypospadias: A persistent challenge. Single institution outcome analysis of three surgical techniques over a 10-year period. *J Pediatr Urol* 2016; 12, 28.e1-28.e7
- Long CJ, Chu DI, Tenney RW, et al. Intermediate-Term Followup of Proximal Hypospadias Repair Reveals High Complication Rate. *J Urol* 2017; 197: 852-858
- Sennert M, Hadidi A. Flaps versus grafts. In: Hadidi A (editor). *Hypospadias surgery: an illustrated textbook*. Springer Nature Switzerland 2022; pp: 739-746
- Gong EM, Cheng EY. Current challenges with proximal hypospadias: We have a long way to go. *J Pediatr Surg* 2017; 13: 457-467.
- Nesbit RM. Plastic procedure for correction of hypospadias. *J Urol* 1941; 45:699-702.
- Smith D. A de-epithelialised overlap flap technique in the repair of hypospadias. *Br J Plast Surg* 1973; 26: 106-114.
- AbouZeid, A.A., Habak, R.A., Hamad, M.M. et al. De-epithelialized overlap flap to secure urethroplasty in second stage hypospadias repair: revisiting the Smith technique. *BMC Urol* 23, 143 (2023). <https://doi.org/10.1186/s12894-023-01312-8>
- Byars LT. Surgical repair of hypospadias. *Surg Clinics North America* 1950; 30:1371-8
- Nicolle FV. Improved repairs in 100 cases of penile hypospadias. *Br J Plast Surg* 1976; 29: 150-7.
- Cloutier AM. A method for hypospadias repair. *Plast Reconstr Surg* 1962; 30: 368-73.
- Bracka A. Hypospadias repair: the two-stage alternative. *Br J Urol* 1995; 76 (Suppl 3): 3141.
- AbouZeid AA, Shahin AEM, Elsadek M, et al. Urethral Plate Substitution in Two-Stage Hypospadias Repair: Grafts Versus Flaps. *J Pediatr Surg* 2023; 58: 2027-2033.
- Cendron M. Flap Versus Graft 2-Stage Repair of Severe Hypospadias with Chordee. *J Urol* 2015; 193: 761-2.
- Castagnetti M, El-Ghoneimi A. Surgical Management of Primary Severe Hypospadias in Children: Systematic 20-Year Review. *J Urol* 2010; 184: 1469-1475
- Snodgrass WT. Flap Versus Graft 2-Stage Repair of Severe Hypospadias with Chordee. *J Urol* 2015; 193: 760-1.
- Long CJ, Shukla AR, Zaontz MR. The Surgical Approach to Two-Stage Hypospadias Repair. In: Bhat A. (editor) *Hypospadiology: principles and practices*. Springer Nature Singapore 2022; pp: 187-200
- Retik AB, Bauer SB, Mandel J et al: Management of severe hypospadias with a 2 stage repair. *J Urol* 1994; 152: 749.