

Optical Coherence Tomography Angiography After Ranibizumab and After Macular Laser Treatment for Diabetic Macular Edema**Sara Salah Eldin Mahmoud Ali^{a*}, Mohammed Hussein El-Agouz^a, Khulood Muhammed Mahmood^a, Marwa Mahmoud Abdellah^a**^aOphthalmology Department, Faculty of Medicine, Sohag University, Sohag, Egypt**Abstract**

Background: Diabetic macular edema (DME) is a main cause of visual affection in diabetics. Optical coherence tomography (OCT) and optical coherence tomography angiography (OCTA) are non-invasive technology to have a cross-sectional image of the retina.

Objectives: is to assess macular thickness and ischemia that may occur after injection and after laser clinically and by using OCT and OCTA and its affection on best corrected visual acuity (BCVA).

Patients and methods: prospective, observational, cohort study with a total 89 eyes were enrolled in the study. They were evaluated using OCT and OCTA before and after intravitreal injection of ranibizumab or after macular grid laser used in patients diagnosed with clinically significant diabetic macular edema. They were divided into 2 groups: ranibizumab group (49 eyes) and macular grid laser group (40 eyes).

Results: There was highly significant improvement in BCVA in both groups ($p < 0.0001$). As regard macular thickness there was significant reduction of macular thickness in both groups ($p < 0.0001$). As regard foveal avascular zone (FAZ) there was more enlargement of FAZ post. Laser than post. Injection but this enlargement was non-statistically significant. Vascular density in superficial capillary plexus decreased more post. Laser than post. Injection but this reduction was non-statistically significant. Vascular density in deep capillary plexus decreased more post. Laser than post. Injection but this reduction was non-statistically significant.

Conclusion: Our result concluded that intravitreal injection of ranibizumab and macular grid laser are influential treatment for diabetic macular edema with more ischemia and more effect on macular perfusion with macular laser than with ranibizumab. OCT and OCTA are helpful during follow-up cases with DME to assess macular thickness, degree of macular ischemia and any complication that may result from injection or from laser.

Keywords: Ranibizumab; Macular laser; OCTA; CMT; BCVA.

DOI: 10.21608/SVUIJM.2023.209031.1581

***Correspondence:** sarasalah77666@gmail.com

Received: 9 May, 2023.

Revised: 9 July, 2023.

Accepted: 2 August, 2023.

Published: 27 January, 2025

Cite this article as Sara Salah Eldin Mahmoud Ali , Mohammed Hussein El-Agouz , Khulood Muhammed Mahmood , Marwa Mahmoud Abdellah.(2025). Optical Coherence Tomography Angiography After Ranibizumab and After Macular Laser Treatment for Diabetic Macular Edema. *SVU-International Journal of Medical Sciences*. Vol.8, Issue 1, pp: 148-157.

Copyright: © Ali et al (2025) Immediate open access to its content on the principle that making research freely available to the public supports a greater global exchange of knowledge. Users have the right to Read, download, copy, distribute, print or share link to the full texts under a [Creative Commons BY-NC-SA 4.0 International License](https://creativecommons.org/licenses/by-nc-sa/4.0/)

Introduction

Diabetic retinopathy (DR) is a main cause of blindness between adults in many countries, DR prevalence continues to increase all over the world (Russell and Han, 2021). Anti-vascular endothelial growth factor (anti-VEGF) known to be effective in treatment of diabetic macular edema (DME) (Arevalo, 2013). An important example of the anti-VEGFs, ranibizumab (RBZ) which is an antibody fragment which has high affinity for binding of VEGF-A (Aksoy et al., 2015). Now an approval of the US Food and Drug Administration for intraocular use of Ranibizumab (Lucentis), with a dose of 0.5 mg of Ranibizumab intravitreally is effective with minimal risks and side effects (Higazy et al., 2019). Also, Treatment of diabetic macular edema include macular laser photocoagulation, which considered the main treatment for DME since 1985, as considered by the Early Treatment Diabetic Retinopathy Study (ETDRS) (Aiello et al., 1994).

Fluorescein angiography (FA) was the main investigatory tool (Yannuzzi et al., 1986). But it is a relatively invasive need injection of fluorescein dye intravenously which carries many risks (Yannuzzi et al., 1986). and difficulty to quantify ischemia accurately specially the deep retinal capillary plexus. it may be limited to assess ischemia by masking effect of hemorrhage and leakage and hemorrhage and the inability to accurately assess the deep retinal capillary plexus (Weinhaus, 1995).

Optical coherence tomography angiography (OCTA) enables us to visualize the retinal microvasculature and non-invasive (Al-kady et al., 2022). The recent Angio Vue software can perform segmentation of images of OCTA into individual retinal vascular layer which are the superficial capillary plexus (SCP) that include the vasculature within the ganglion cell layer, and the deep capillary plexus

(DCP) that include the vasculature on the either side of the inner nuclear layer (INL) (Al-kady et al., 2022). The aim of the present study was to assess macular thickness, ischemia and complications after ranibizumab and after grid laser clinically and by using OCT and OCTA and its affection on BCVA.

Patients and methods

Study design: Prospective observational cohort study.

Subjects: The study included 2 groups: group 1: At first enrolled 65 eyes with native center involving diabetic macular edema who were treated with intravitreal ranibizumab injection, center involving macular edema was defined according to early treatment diabetic retinopathy study group (ETDRS). Of all 65 eyes, 9 of them missed their follow-up schedule. And 7 were excluded as they have non-measured FAZ or macular density at any time during their follow-up. We follow treat and extend (TAE) protocol. We start with 3 injections with 0.5 mg ranibizumab (0.1ml) one per month while the macular edema resolution is monitored by means of OCT and intervals are extended by 2-4 weeks. Once the patients longest intervals are found, he undergoes fixed interval injections. Group 2: included 40 eyes. At first the study enrolled 50 eyes with native non-center involving diabetic macular edema (diffuse) treated with macular grid laser, they were defined according to early treatment diabetic retinopathy study group (ETDRS). but 8 of them missed their follow-up schedule. And 2 were excluded as they have non-measured FAZ or macular density at any time during their follow-up. All eyes had undergone grid macular laser photocoagulation using argon laser (Zeiss-Humphrey systems, Carl Zeiss, Jena, Germany) which was adapted from the modified ETDRS. The Grid treatment utilizes spot size of 50 μ m for duration of

0.05 to 0.1 seconds, not placed within 500 um of the center of the macula or within 500 um of the disc margin, with treatment goal of mild retinal pigment epithelium grayness. The laser burns are placed approximately two visible burn widths apart in the areas of the macular edema (retinal thickening) that are thought to be related to diffuse leakage.

Data was collected between august 2020 and December 2022 at Sohag Ophthalmology Investigation Center and Sohag University Hospital.

Ethical consideration and written

informed consent: An approval of the study was obtained from Sohag University Academic and Ethical Committee. Also a consent for acceptance of the procedure was obtained from all patients after they were informed about the investigations that will be done to them.

Methods

Inclusion criteria: group (1): Patients with native clinically significant central involving macular edema. On OCT (central macular thickness > 250 Mm). Those patients were treated with anti-VEGF by 3 injections with a dose of 0.5 mg ranibizumab (0.1ml) at baseline and every 4 weeks. We take in consideration that all participants had good quality scans obtained by OCT and OCT angiography. Group (2): patients with native non – center involving macular edema (diffuse). On OCT, the retinal thickening involves 1 or more of the non-central fields on the ETDRS grid. Retinal thickening is defined as (>320 µm) and central subfield thickness (CST) of less than normal +2 SD (machine-specific) with BCVA < 6/9 were treated with grid macular laser. We take in consideration that all participants had good quality scans obtained by OCT and OCT angiography.

Exclusion criteria:1 - Patients with uveitis, glaucoma not controlled medically. 2- Patients with vitreous opacities or hemorrhages .3- tractional RD threaten the

macula.4- Eyes with media opacity significant enough to affect the images quality.5- Eyes with marked image distortion or significant artifact prevent measurement of the FAZ and vessel density accurately. 6- eyes with previous macular grid laser treatment. 7- eyes with previous anti-VEGF treatment.

Patient evaluation: Each participant was subjected to full history, Comprehensive ophthalmological examination, including refraction, best-corrected visual acuity (measured by Snellen`s or Decimal notation scale then all converted to decimal), IOP measurement using Goldman applanation tonometer, ant. Segment examination by slit lamp biomicroscopy and examination of fundus by auxiliary lens and \or indirect ophthalmoscope.

Examination of the macula before and after maneuver was done by Swept source OCT (SS- OCT) and by Optical coherence tomography angiography.

Methods of study : OCT was performed before, after maneuver and during follow-up periods using swept source OCT (SS-OCT).

1) OCT parameters:

- | | | |
|---|--|---------------------|
| <ol style="list-style-type: none"> 1- Central macular thickness. 2- Parafoveal thickness in 4 quadrants. 3- Perifoveal thickness in 4 quadrants. | | According to ETDRS. |
|---|--|---------------------|
- 4- Integrity of outer retinal layers (IS-OS ellipsoid layer, ELM integrity and interdigitation zone): if it disrupted or intact or absent. It is important to be evaluated in cases of DME.
 - 5- RPE integrity.
 - 6- Organization of inner retinal layers and detection of disorganization (DRIL).
 - 7- Post maneuvers we look for development of complications as ERM and scarring.

2) OCT angiography:

Was performed using an RTVue XR Avanti with Angio Vue software (Optovue, Inc., Fremont, California, USA). For each eye, a 6 X 6 -mm scan centered on the fovea. Automated OCT segmentation was Performed using the Angio-Vue module.

OCTA parameters: 1-Vessel density (superficial and deep capillary plexus). 2- FAZ area. FAZ the area of the central fovea in which there is no vessels. FAZ size was calculated automatically using the software of the machine.

Vessel densities: Vessel density is defined as the proportion of the measured area occupied by blood vessels in both deep vascular plexus (DVP) and superficial vascular plexus (SVP).

Follow -up with: BCVA (best corrected Visual acuity); OCT parameters; OCT angiography parameters. Follow-up was scheduled to be at one month, three months and 6 months.

Statistical analysis

Using SPSS version 18 we analyzed the data. Comparison was made between pre and post treatment follow up data at 1, 3 and 6 months (repeated measure ANOVA) RMANOVA test. Sphericity were examined using Mauchly's Test of Sphericity. Bonferroni post hoc test to examine the difference at each time point. The different time points used as within subject factors. Student t test was used to compare injection and laser group. Chi square test used for categorical data. P value was considered significant if it was < 0.05.

Results

The demographic characters of the study groups:

Group (1): age & gender: included 49 eyes totally with 27 eyes of 18 females and 22 eyes of 17 males with mean age 56.20±10.09 years old. Group (2): Age & gender: include 40 eyes with 17 eyes of 17 females and 23 eyes of 20 males with mean age 54.18±10.09 years old, (Table.1).

Table 1. Demographic criteria of studied groups

Variables	Injection group N=49	Laser group N=40	P value
Age/years			
Mean ± SD	56.20±10.09	54.18±10.09	0.35
Median (range)	57 (42:77)	54 (36:70)	
Gender			
Female	27 (55.10%)	17 (42.50%)	0.24
Male	22 (44.90%)	23 (57.50%)	
Eye			
od	27 (55.10%)	15 (37.50%)	0.10
os	22 (44.90%)	25 (62.50%)	

Percentage change of different parameters

We compare different parameters between injection & laser group (Table.2). When we compare visual acuity changes after injection and after laser, we can find that both associated with visual acuity improvement but we found significant p value with more improvement obtained

after intravitreal injection than after laser with mean improvement after injection of 51% and only 7.95% post. laser as shown in (Fig.1)

FAZ changes was about 9.06% enlarged after injection while it was 11.32% enlargement after laser as shown in (Fig.2).

Table 2. Comparison between injection group & laser group as regard percent change in different parameter

Variables	Injection group N=49	Laser group N=40	P value
VA change (%)			
Mean ± SD	51.12±55.00	7.95±12.33	<0.0001
Median (range)	28 (-50:220)	0 (0:28)	
FAZ change (%)			
Mean ± SD	11.95±28.09	26.99±46.93	0.19
Median (range)	9.06 (-29.81:173.81)	11.32 (1.15:197.84)	
Superficial vascular density change (%)			
Fovea			
Mean ± SD	-6.92±19.96	-4.60±3.40	0.93
Median (range)	-4.16 (-58.21:69.60)	-5.57 (-13.04:0)	
Parafovea			
Mean ± SD	-2.73±6.51	-2.37±1.36	0.91
Median (range)	-2.42 (-22.73:23.26)	-2.65 (-4.84:0)	
Perifovea			
Mean ± SD	-2.73±8.60	-2.25±1.89	0.54
Median (range)	-2.08 (-24.29:33.22)	-2.11 (-9.09:0)	
Deep vascular density change (%)			
Fovea			
Mean ± SD	-4.66±16.36	-2.44±1.63	0.69
Median (range)	-2.83 (-55.83:28.4)	-2.98 (-7.25:0)	
Parafovea			
Mean ± SD	-0.79±10.44	-2.19±1.52	0.57
Median (range)	-2.11 (-37.44:45.10)	-1.71 (-6.04:0)	
Perifovea			
Mean ± SD	-1.30±9.52	-2.10±0.98	0.21
Median (range)	-1.80 (-30:31.35)	-2.01 (-3.67: -0.34)	
Macular density change (%)			
CMT			
Mean ± SD	-38.53±8.90	-11.61±7.81	<0.0001
Median (range)	-37.92 (-54.13: -21.52)	-9.74 (-26.86: -0.93)	

Example for FAZ enlargement after ranibizumab injection as shown in (Fig.3) and after macular laser as shown in (Fig.4). Central macular thickness reduction was about 37.92% reduction post. Injection but only 9.74% reduction post. Laser. Superficial vascular density reduction in fovea was about 4.16% post. Injection but about 5.57% post. Laser while in parafovea it was 2.42% post.

Injection but 2.65% post. Laser In perifovea reduction was 2.08 % post injection while 2.11% post. Laser. Vascular density in deep capillary plexus changes in fovea was 2.83% post injection and 2.98% post. Laser. In parafoveal area 2.11 % post. Injection but 2.71% post. Laser. In perifoveal area changes was 1.80% post. Injection and 2.01% post. Laser.

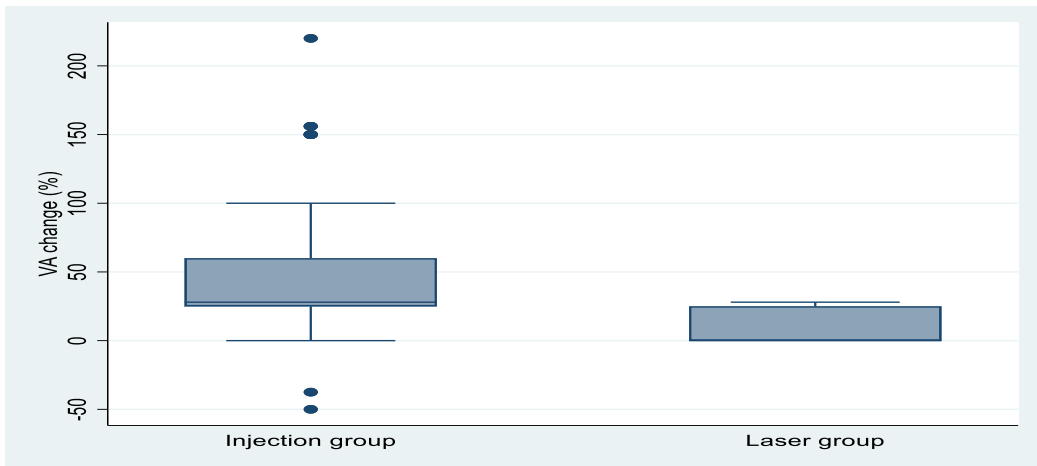


Fig. 1. Comparison between injection group & laser group as regard percent change in VA.

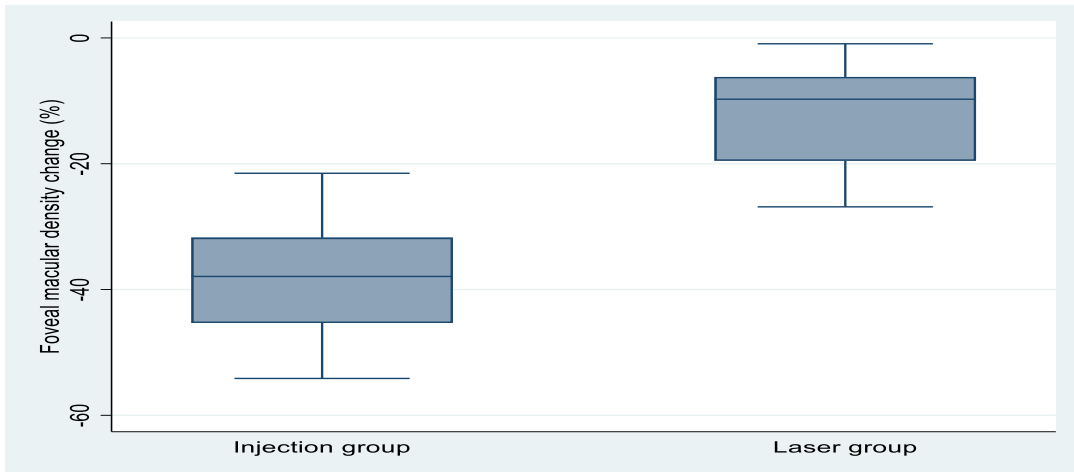


Fig. 2. Comparison between injection group & laser group as regard percent change in foveal macular density

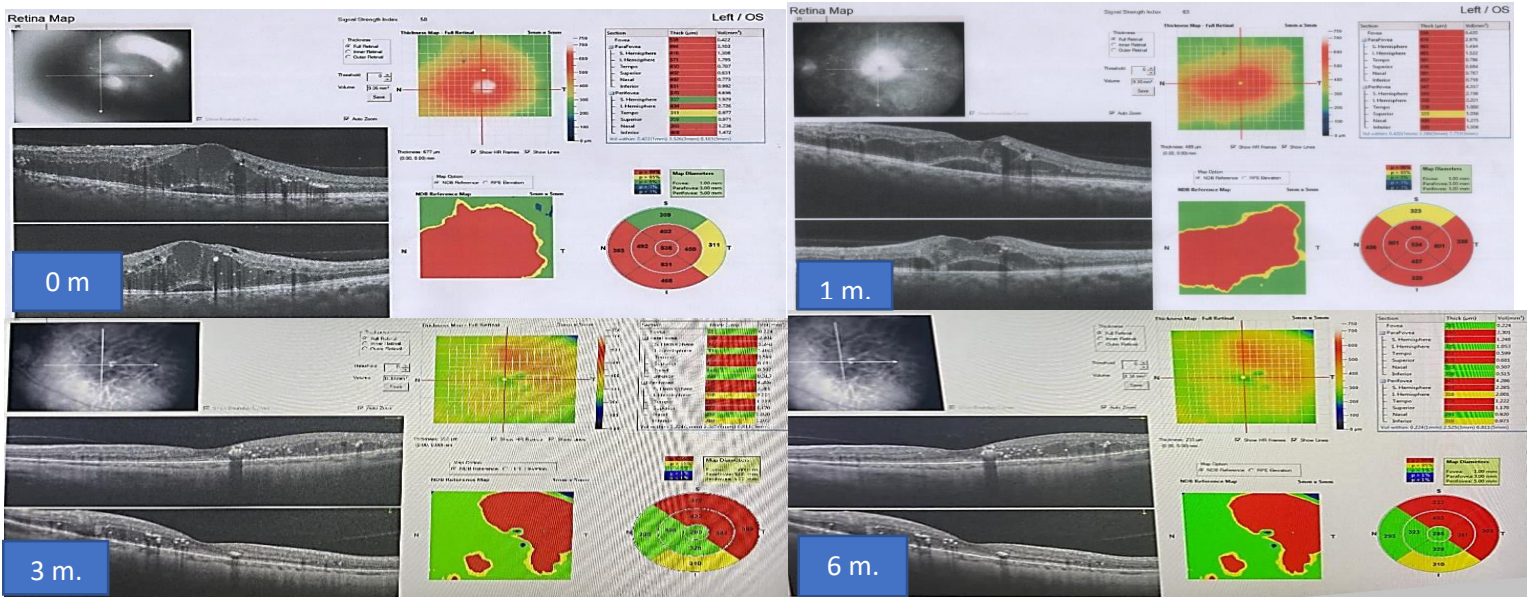


Fig.3. Macular thickness before and after ranibizumab injection




Fig. 4. OCTA images of male patient 61 years old reveal FAZ before and ranibizumab injection. A at baseline, B at 1st m., C at 3rd m., D at 6th m. of follow-up.

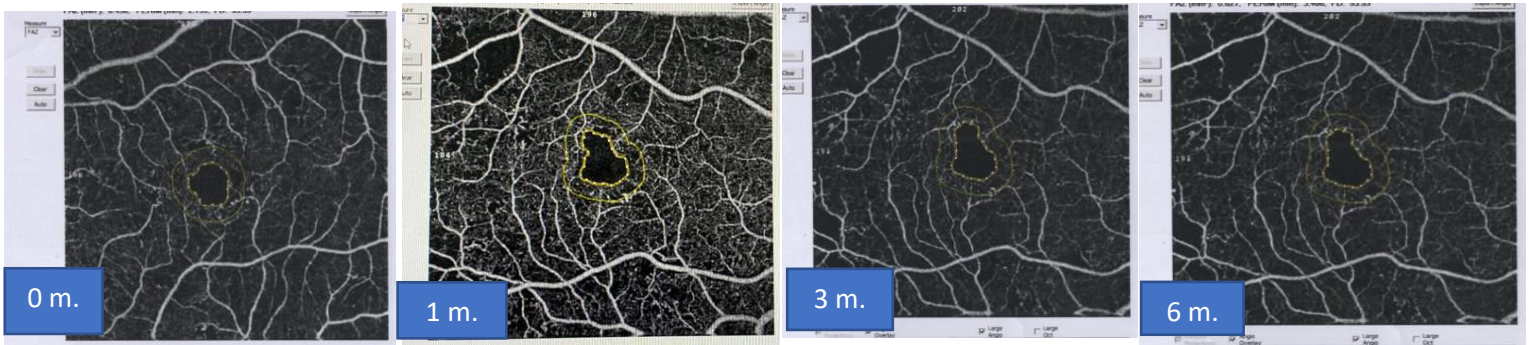


Fig. 5. OCTA images of male patient 52 years old reveal FAZ before and after macular laser treatment. A at baseline, B at 1st m., C at 3rd m., D at 6th m. of follow-up.

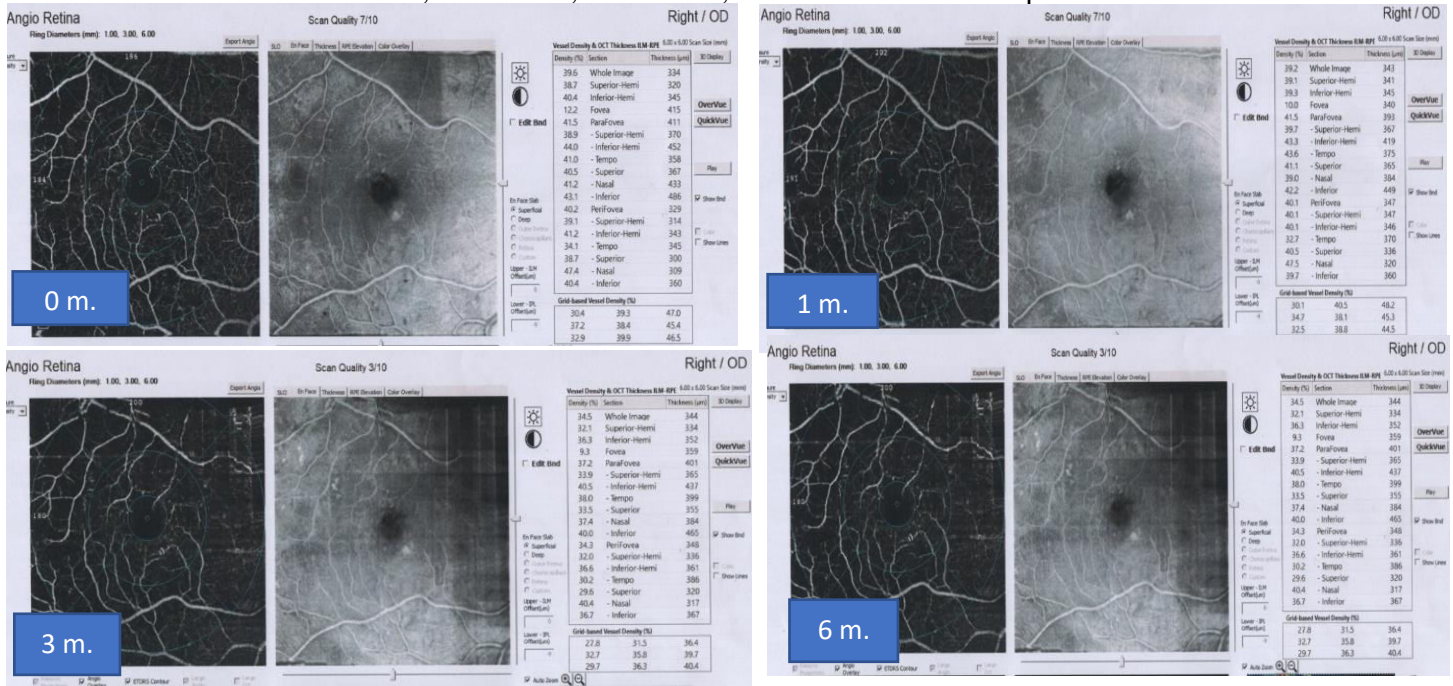


Fig.6. OCTA images of rt. eye of male patient 52y.old reveal vascular density in SCP. at baseline, 1st m., at 3rd m., at 6th m. follow-up after injection.

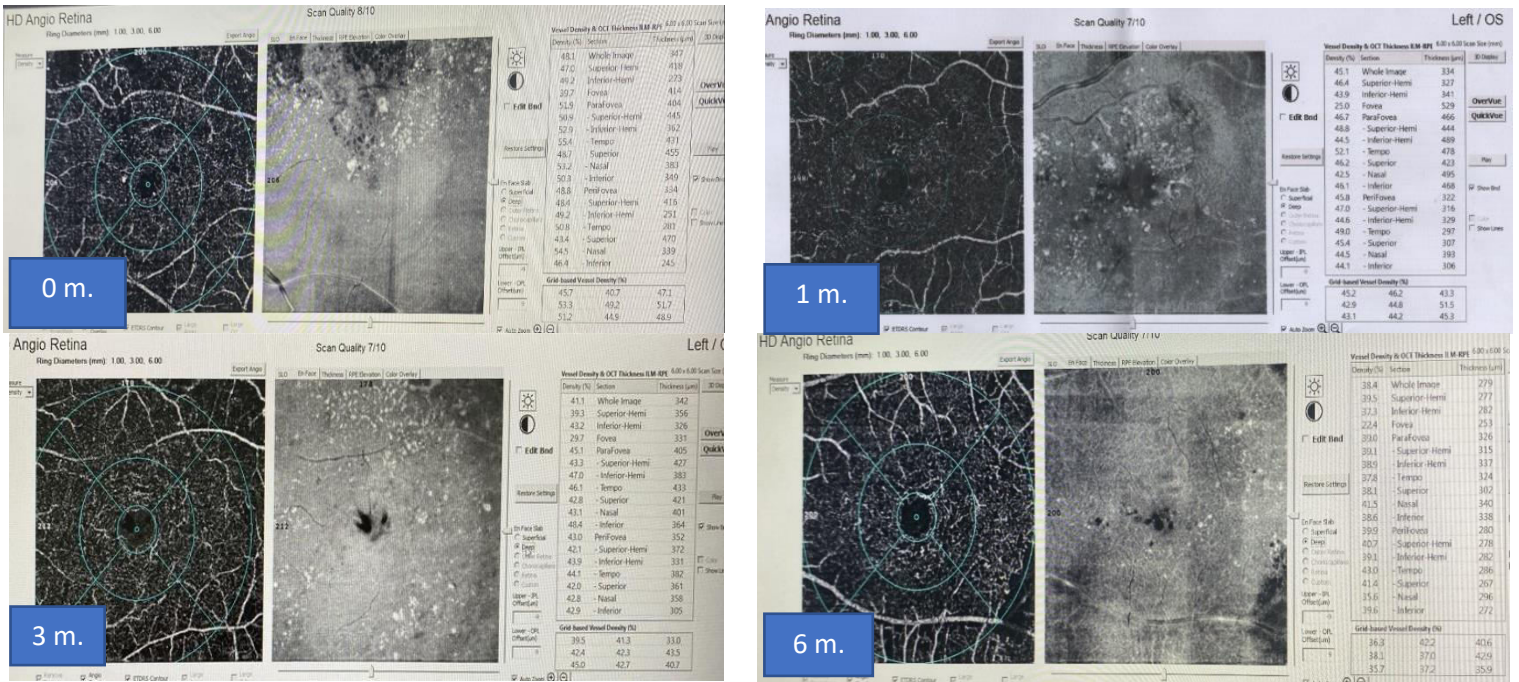


Fig.7. OCTA images of lt. eye of female patient 55y.old reveal vascular density in SCP. at baseline, 1st m., at 3rd m., at 6th m. follow-up after laser.

Discussion

In our study we found that both intravitreal injection and laser were associated with visual acuity improvement and both associated with central macular thickness reduction but more reduction(improvement) in intravitreal injection than in laser group. Improvement of visual acuity and macular thickness was statistically significant in both groups. When we assessed macular perfusion, we found that FAZ enlargement was more in laser group, Superficial vascular density reduced more post. Laser and vascular density in deep capillary plexus reduced more post. Laser but this was non-statistically significant. **Chew (2019)** study compared grid laser, intravitreal injection and found that no statistically significant differences were seen in the primary outcome, which was the proportion of participants who experienced decreased visual acuity of 5 or more letters from baseline: aflibercept (16%) and laser photocoagulation (17%). So, their effect in preventing visual acuity reduction is comparable. This study is different from of our study that they use aflibercept as anti-VEGF not ranibizumab. The

cumulative probabilities of receiving aflibercept in the laser group was 26%. **Re'gnier et al. (2014)** study found that Ranibizumab monotherapy on BCVA and CRT was statistically higher efficacy than laser. **Anwar et al. (2020)** study found that Intravitreal anti-VEGF injection was associated with improved BCVA most significantly in 1 month follow-up and Laser less significantly in one month follow up. Intravitreal Avastin decreased retinal thickness most significantly in one months and Laser decreased less significantly. They have shorter period of follow-up than our study and they did not study their effect on macular perfusion. **Anwar et al. (2020)** study found that Avastin therapy more effective in diabetic macular edema management than the Laser therapy in follow-ups.

This not the same in **Mahmoud et al. (2022)** study who found that both intravitreal ranibizumab injection and 810 subthreshold micropulse laser were both the same effective in improving visual acuity and central foveal thickness reduction. But

this different from our study as they use micro pulse laser.

That was not the same with Elnahry AG, Elnahry GA.(2021) study who only study the effect of intravitreal injection and found that the FAZ area enlarged by 8.1%, the VD of the SCP was reduced by 9.1%, the VD of DCP was reduced by 10.6% in the 6×6mm macular area imaged by OCTA which were all statistically significant ($p < 0.05$), which are higher values than found in our study. This difference may be due to difference in severity of diabetic retinopathy and our smaller study group.

Shahidi et al. (1994) study is in agreement with our study in that they demonstrated that focal laser treatment seem to be effective in preventing the progression of macular oedema by reducing or maintain the degree of thickening but they not quantify ischemia post laser.

Li et al. (2020) study is in agreement with our study as they found that superficial parafoveal vascular density decreased post laser, deep parafoveal vascular density also decreased, central macular thickness decreased.

Conclusion

From all that we can say that intravitreal injection associated with more improvement of visual acuity and more improvement of macular thickness with less ischemia (less effect on macular perfusion) than laser, so OCT and OCTA are helpful in diagnosis and follow-up of patients with diabetic macular edema.

References

- **Aiello LP, R L Avery, P G Arrigg , B A Keyt , H D Jampel , S T Shah, et al.(1994).** Vascular endothelial growth factor in ocular fluid of patients with diabetic retinopathy and other retinal disorder.the New England journal of medicine,329(1):21-26.
- **Aksoy S, Yilmaz G, Akkoyun I,Canan A .(2015).** Comparison of intravitreal bevacizumab and triamcinolone acetonide therapies for diffuse diabetic macular edema. International Journal of Ophthalmology, 8 (3):550-555.
- **Al-kady R, El-mongy MS, Hassan M.(2022).** Coherence Tomography Angiography in Diabetic Retinopathy: A Prospective Pilot Study. American journal of ophthalmology,51(4):2099-2112.
- **Anwar H, Khalil I, Ikram S, Akram S, Batool A, Iqbal S .(2020).** Comparison of laser and anti VEGF therapy in treatment of diabetic macular edema. Advances in Ophthalmology & Visual System 10(1):8-11.
- **Arevalo JF .(2013).** Diabetic macular edema: Current management 2013. World Journal of Diabetes, 4(6):231.
- **Chew EY. (2019).** Patients with Good Vision and Diabetic Macular Edema Involving the Center of the Macula: To Treat or Not to Treat? - Journal of the American Medical Association Med Assoc,321(19):1873-1875.
- **Elnahry AG, Elnahry GA.(2021).** Optical Coherence Tomography Angiography of Macular Perfusion Changes after Anti-VEGF Therapy for Diabetic Macular Edema: A Systematic Review.diabetes journal, 2021:1-14.
- **Higazy HM, Abdalla AMA, Ali MAE. (2019).** Ranibizumab Monotherapy or Combined with Laser versus Laser Monotherapy for Diabetic Macular Edema. Egypt Journal Hospital Medicine,77(4):5442-5447.
- **Li ZJ, Xiao JH, Zeng P, Zeng R , Gao X, Yi-Chi Z., et al.(2020).** Optical coherence tomography angiography assessment of 577 nm laser effect on severe non-proliferative diabetic retinopathy with diabetic macular edema. International Journal of Ophthalmology,45(6):1257-1265.
- **Mahmoud Z., Mohammed M. A**

- Hodieb .(2022).**Comparative Study between Intravitreal Ranibizumab Injection and Subthreshold Micropulsed Diode Laser (DSM) in Management of Diabetic Macular Edema. Al-Azhar International Medical Journal, 89-95
- **Régnier S, Malcolm W, Allen F, Wright J, Bezlyak V.(2014).** Efficacy of anti-VEGF and laser photocoagulation in the treatment of visual impairment due to diabetic macular edema: A systematic review and network meta-analysis. PLoS One journal, 9(7):1-10.
 - **Russell JF, Han IC.(2021).** Toward a New Staging System for Diabetic Retinopathy Using Wide Field Swept-Source Optical Coherence Tomography Angiography.Current Diabetes Reports, (8)21: 28.
 - **Shahidi M, Ogura Y, Blair NP, Zeimer R .(1994).** Retinal thickness change after focal laser treatment of diabetic macular oedema. British Journal of Ophthalmology,78(11):827-830.
 - **Weinhaus RS, Burke JM, Delori FC.(1995).**Comparison of fluorescein angiography with microvascular anatomy of macaque retinas. Experimental eye research journal, 61(1):1-16.
 - **Yannuzzi LA, Rohrer KT, Tindel LJ, R S Sobel, M A Costanza, W Shields, et al.(1986).** Fluorescein angiography complication survey. Ophthalmology,93(5):611-617.