

Safe zones of pin insertion in thoracic spine: a 'cadaveric study'

Mohammed A. Meselhy^a, Osama F. Ahmed^b

Departments of ^aOrthopedics Surgery,
^bAnatomy and Embryology, Benha University,
Benha, Egypt

Correspondence to Mohammed Anter Meselhy,
MD, Orthopedic Department, Benha University,
Kafer el Gazar, Banha, Qalyubia 13511;
Tel: +20 1007550217; fax: +20 (13) 3227518;
e-mail: m.anteroof@yahoo.com

Received 15 January 2016

Accepted 24 April 2016

The Egyptian Orthopaedic Journal
2017, 52:57–61

Purpose

This experimental study was conducted to identify the safe zones and angles of half pin insertion in thoracic vertebrae.

Materials and methods

Simple tools were used, power drill, 4, 5, and 6 mm half pins, goniometer, and portable radiographic apparatus.

There were two bony specimens comprising complete lumbar thoracic and cervical spine with ribs and sternum attached, and three cadaveric specimens preserved in formalin, comprising the thorax and abdomen with the back muscle dissected to show the thoracic pedicle.

The methodology comprised insertion of the Schanz screw in the thoracic pedicle from T1 to T12 using the free-hand technique in bony skeleton, and then this was repeated on the cadaveric specimens to evaluate the correct angle of insertion, checking the site of half pin insertion using radiography for the cadaveric specimen.

Results

The suggested safe angulation of half pins was 20°–30° at T1, 15°–25° at T2, 10°–15° at T3, 10°–15° at T4, and from T5 to T9 the safe angle was from 5° to 15°. In T11 and T12, the safe angle was between 0° and 5°. The safe angle of half pin insertion in the pedicle of the thoracic spine in the sagittal plane in all vertebrae from T1 to T12 was between 10° and 15°.

Conclusion

It was concluded that the application of the external fixator in the thoracic spine is safe, provided there is a better understanding of the anatomical properties of the thoracic spine.

Keywords:

external fixator, safe zones, thoracic spine

Egypt Orthop J 52:57–61
© 2017 The Egyptian Orthopaedic Journal
1110-1148

Introduction

The vertebral column in the thoracic region appears cylindrical. The width of the vertebral body decreases from the first thoracic vertebrae to the fourth thoracic vertebrae, and then the width increases again until the sacrum, to accommodate the load progression from the head to the lower lumbar region [1–4].

In 1977, Magerl developed spinal skeletal external fixator for stabilization and fixation of the lumbar and lower thoracic vertebrae; it consisted of two pairs of half pins attached to the vertebral bodies through the pedicles with an adjustable device [5].

The clinical application of this fixator was in the field of spinal infection, trauma, and instability; it allows compression, distraction, and scaffolding for neutral fixation [5].

The purpose of this experimental study was to identify the safe zones and angles of half pin insertion in thoracic vertebrae.

Materials and methods

In this cadaveric study we evaluated the pedicle as a safe zone of half pin insertion in the thoracic spine and determined the safe angle for half pin fixation. The study was approved by ethical committee of banha university and were in accordance with the ethical standards of the institutional and national research committee and with the 1964 Helsinki declaration and its later amendments or comparable ethical standards.

This study was conducted in our Faculty of Medicine in the Anatomy and Embryology Department, Laboratory Section, in cooperation with the Orthopedic Surgery Department.

This is an open access article distributed under the terms of the Creative Commons Attribution-NonCommercial-ShareAlike 3.0 License, which allows others to remix, tweak, and build upon the work noncommercially, as long as the author is credited and the new creations are licensed under the identical terms.

Simple tools such as power drill and half pins of 4, 5, and 6 mm in diameter were used; in addition, a portable radiographic apparatus was used.

In this cadaveric study, there were two bony vertebral columns with ribs at the thoracic region and three cadaveric specimens preserved in formalin, comprising the thorax and abdomen with the back muscle dissected to show the pedicle and ribs (Figs 1 and 2).

The methodology of this study comprised the insertion of the Schanz screw in the thoracic pedicle from T1 to T12 using the free-hand technique in bony skeleton, and then this was repeated on the cadaveric specimen to evaluate the correct angle of insertion. In addition, the site of half pin insertion was checked using radiography for the cadaveric specimen (Fig. 3).

The entry point is present at the junction of a vertical line along the lateral side of the pars interarticularis and a

transverse line bisecting the transverse process in half. On moving cranially toward the mid thoracic spine, the entry point moves medially. At T7–T9, the starting point lies most medial, located along a vertical line just lateral to the midpoint of the superior articular process at a transverse location along the superior border of the transverse process. On moving more proximally, the entry point shifted more laterally. At T1–T2, the entry point is found at the point of intersection of a vertical line along the lateral border of the pars interarticularis and a transverse line bisecting the transverse process.

Results

The half pins in the thoracic pedicle were inserted using the free-hand technique in both bony skeleton and the cadaveric specimens.

The data in this experimental study were collected by means of direct observation and using a goniometer to

Figure 1



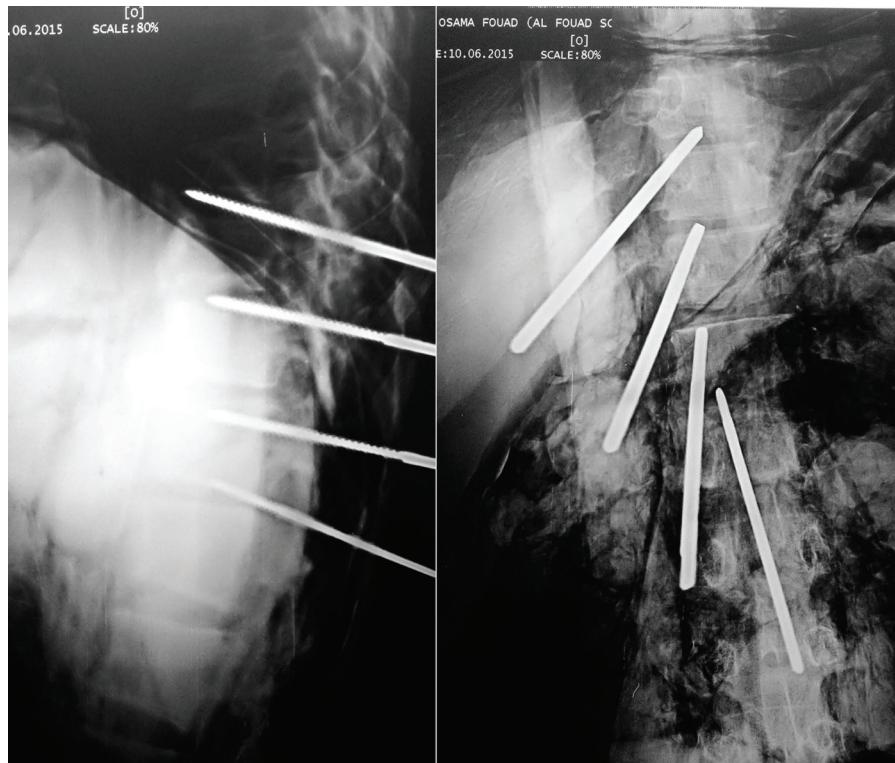
Bony specimen. (a) Clinical photos show angles of half pin insertion in pedicles of thoracic vertebrae in the sagittal plane; (b) clinical photos show angles of half pin insertion in pedicles of thoracic vertebrae in the transverse plane.

Figure 2



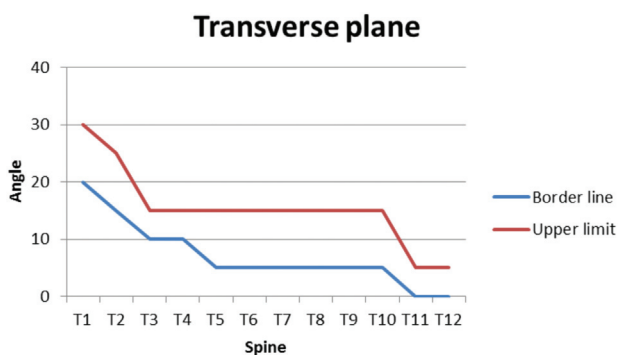
Cadaveric specimen. (a) Clinical photos show angles of half pin insertion in pedicles of thoracic vertebrae in the sagittal plane; (b) clinical photos show angles of half pin insertion in pedicles of the thoracic vertebrae in the transverse plane.

Figure 3



Radiography: anteroposterior and lateral views for the half pins in the cadaveric specimen.

Figure 4



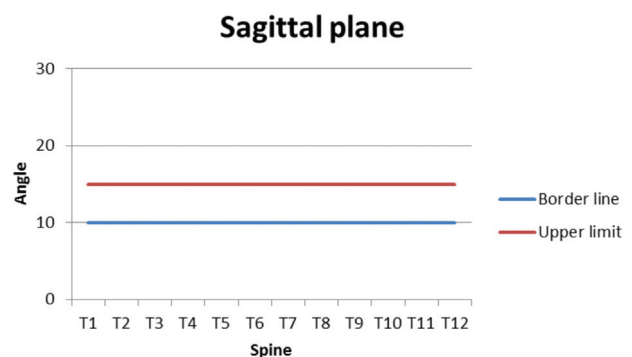
A chart showing safe angles of half pin insertion in the transverse plane.

measure the correct angle of half pin insertion in the pedicle.

In this current study, on analysis of the angles of half pin insertion on both bony skeleton and cadaveric specimens, it was found that the safe angle of half pin insertion in the pedicle in the transverse plane using the free-hand technique in the thoracic spine is as follows:

- T1: 20°–30°.
- T2: 15°–25°.
- T3: 10°–15°.
- T4: 10°–15°.

Figure 5



A chart showing safe angles of half pin insertion in the sagittal plane.

From T5 to T9 the safe angle was from 5° to 15°.

In T11 and T12, the safe angle of half pin insertion was between 0° and 5° (Fig. 4).

However, it was found that the safe angle of half pin insertion in the pedicle of thoracic spine in the sagittal plane in all vertebrae from T1 to T12 ranges from 10° to 15° (Fig. 5).

Discussion

The thoracic region consists of 12 vertebrae, which increase in size from cranial to caudal to accommodate

the load transmission; the dorsal spine is characterized by the presence of costovertebral complex [5].

According to anatomic classification, thoracic vertebrae are divided into typical and atypical vertebrae. Typical vertebrae have anteroposterior diameter more than the transverse diameter, whereas the second group, which comprises five vertebrae, are different [1-4,6].

The first dorsal vertebra considered as transitional site, while the seventh cervical vertebra, in addition the ninth thoracic vertebrae has only superior costal articulation, also the 11th looks like the lumbar vertebrae as it has large body and small transverse process because it lies between the mobile cervical vertebrae and slightly mobile thoracic vertebrae [1-3,5].

Thoracic aorta is in close relation with the vertebrae; it is the continuation of the arch of aorta at the level of T4, and it ends at the level of lower border of T12. Proximally, it is to the left of the vertebral column, but at the level of diaphragm it becomes central [6-11].

Intercostal arteries are of great relationship to this study purpose. They are located in the center of the vertebral bodies. They originate from the thoracic aorta, except for the upper two vessels, which arise from the subclavian artery [1,2,4,8,9,11-15].

The intercostal arteries divide into two branches: the anterior and posterior branches. The posterior branches are important during surgery, as they enter the intervertebral foramen and then divide into muscular and spinal branches. The spinal branch supplies the entire spinal cord [1,2,4,8,9,11-15].

Pedicle has a important relationship as the dura and the spinal cord lie medial to it and the roots of the spinal nerves pass below, and hence nerve root injury can occur [16,17].

To avoid injury of important structures that lie close to the pedicle, during percutaneous pedicle screw application, the accessory process is fractured by some surgeons to facilitate accurate screw insertion [16].

Preoperative planning allows accurate pedicular screw application. This is best when carried out using routine roentgenograms, transaxial computed tomography scan, and MRI to determine all features of the pedicle [16-22].

The transverse angle of the pedicle is changeable; it decreases from 30° convergent at T1 to 0° or 5° divergent at T12. The pedicle axis of the lower thoracic spine (T10, T11, and T12) becomes neutral to little divergent because of the presence of the rib head [16-18].

Pedicle screw should be introduced parallel to the upper surface of the vertebra with inclination to the sagittal plane of about 10°, which increases while descending caudally to 15°-20° at L5 [16,23,24].

In this current study, the angles of half pin insertion in the thoracic pedicles in both transverse and sagittal planes are corresponding to the anatomical consideration and anatomical angles of vertebral and lamina inclination.

In the study by Weinstein *et al.* [16] it was concluded that thoracic pedicles are inclined in the transverse plane by different angles with craniocaudal location, being less than 10° in the thoracic spine. The pedicles also show different angles in the sagittal plane. The pedicles are directed ~15° to 17° cephalad for the majority of the thoracic spine [16].

From our observation, the results of suggested safe angulation and zones of introduction of half pins were 20°-30° at T1 and 15°-25° at T2.

In T3 the safe angle was 10°-15°, and at T4 it was 10°-15°. From T5 to T9 the safe angle was from 5° to 15°.

In T11 and T12, the safe angle of half pin insertion was between 0° and 5°.

Moreover, it was found that the safe angle of half pin insertion in the pedicle of the thoracic spine in the sagittal plane in all vertebrae from T1 to T12 ranges from 10° to 15°.

It was concluded that the lower thoracic pedicles allow a strong site of the pedicle screw from a lateral entry point and 10°-15° convergent angle [23-25].

One of the important factors that allows safe screw insertion is the transverse pedicle diameter, as the lower three dorsal spines have the biggest pedicle diameter [26].

As regards the technique, an image intensifier is always necessary for correct insertion of the half pins, as they must enter the vertebral body through the pedicles and

should not to penetrate its anterior wall. With the image intensifier, the position of the pedicle is demarcated with the patient in prone position, and the image intensifier is placed perpendicular to the patient. The table is then tilted until the long axis of the pedicle corresponds with the center beam. The pedicle will then appear as a sharply defined oval. The half pin is inserted at the center of this oval through the long axis of the pedicle. This procedure is followed in the application of external skeletal spine fixator as well [19,27].

Magerl [5] discussed the direction and point of entry of the Schanz screws. The direction of the Schanz screws is 10°–20° convergent toward the sagittal plane. The point of entry is in the central axis of the pedicular tube, indicated by the intersection of the two lines. The vertical line touches the lateral border of the superior articular process; the horizontal line bisects the base of the transverse process [5].

Olerudi *et al.* [24] has described the use of image intensification when introducing 5 mm Schanz screws placed percutaneously into the pedicles. The Schanz screws are then connected to an external fixator [24].

The most important advantage of advanced imaging technology in the field of thoracic pedicle fixation is identifying the location of the aorta in relationship to the thoracic pedicle [16].

There were some limitations in this cadaveric study: the limited number of bony and cadaveric specimens, and the method of cadaveric specimen preservation, as the formalin changes the color of the soft tissues.

Conclusion

From our study we concluded that the application of an external fixator in the dorsal spine is safe, provided there is good understanding of thoracic spine anatomy and the inclination of the pedicle, in addition to the facilities of advanced imaging techniques that allow better and accurate half pin introduction into thoracic pedicles.

Financial support and sponsorship

Nil.

Conflicts of interest

There are no conflicts of interest.

References

- Clemente CD. Gray's anatomy. 30th ed. Baltimore: Williams & Wilkins; 1984. pp. 114–422.
- Terry RJH. Osteology. In: Schaeffer JP, editor. Morris' human anatomy. Philadelphia: Blakiston; 1947. pp. 77–265.
- White AA III, Panjabi MM. The problem of clinical instability in the human spine: a systematic approach. In: White AA III, Panjabi MM, editors. Clinical biomechanics of the spine. Philadelphia: Lippincott; 1978. pp. 236–251.
- Williams PL, Bannister HL, Berry MM, Collins P, Dyson M, Dussek JE, Ferguson MWJ. Gray's anatomy. London: Churchill Livingstone; 1995. pp. 522–543.
- Magerl FP. Stabilization of the lower thoracic and lumbar spine with external skeletal fixation. Clin Orthop Relat Res 1984; 189:125–141.
- Romanes GJ. Cunningham's textbook of anatomy. 12th ed. Oxford: Oxford University Press; 1981. pp. 220–227.
- Breathnach AS. Frazer's anatomy of the human skeleton. 6th ed. Boston: Little, Brown; 1965.
- Ferner H. Pernkopf Atlas of topographical and applied human anatomy. Baltimore: Urban & Schwarzenberg; 1980.
- Ferner H, Staubesand J. Sobotta Atlas of human anatomy. Vol. 2. Baltimore: Urban & Schwarzenberg; 1983.
- Patten BM. The cardiovascular system. In: Schaeffer JP, editor. Morris' human anatomy. Philadelphia: Blakiston; 1947. pp. 582–785.
- Platzer W. Pernkopf Anatomie. Munich: Urban & Schwarzenberg; 1987.
- Crock HV. An Atlas of vascular anatomy of the skeleton and spinal cord. St. Louis: Mosby; 1996.
- Dommissie GF. The blood supply of the spinal cord: a critical vascular zone in spinal surgery. J Bone Joint Surg Br 1974; 56B:225–235.
- Grieve GP. Common vertebral joint problems. New York: Churchill Livingstone; 1981. 33–50.
- Luyendijk W, Cohn B, Reijger V. The great radicular artery of Adamkiewicz in man: demonstration of a possibility to predict its functional territory. Acta Neurochir (Wien) 1988; 95:143–146.
- Weinsteind JN, Rydevik BL, Rauschnig W. Anatomic and technical considerations of pedicle screw fixation. Clin Orthop Relat Res 1992; 284:34–46.
- Cohen MS, Wall EJ, Brown RA, Rydevik B, Garfin SR. Cauda Equina Anatomy 11: Extrathecal nerve roots and dorsal root ganglia. Spine 1990; 15:1248.
- Krag MH. Biomechanics of transpedicle spinal fixation. In: Weinstein JN, Wiesel SW, editors. The lumbar spine. Philadelphia: W. B. Saunders; 1990. pp. 916–940.
- Krag MH, Beynon BD, Pope MH, Fry-Moyer JW, Haugh LD. An internal fixator for posterior application to short segments of the thoracic, lumbar, or lumbosacral spine. Clin Orthop Relat Res 1986; 203:75.
- Zindrick MR. The role of transpedicular fixation systems for stabilization of the lumbar spine. Orthop Clin North Am 1991; 22:333.
- Zindrick MR, Wiltse LL, Doornick A, Widell EH, Knight GW, Patwardan AG, *et al.* Analysis of the morphometric characteristics of the thoracic and lumbar pedicles. Spine 1987; 12:160.
- Zindrick MR, Wiltse LL, Widell EH, Thomas JC, Holland WR, Field BT, Spencer CW. A biomechanical study of intrapeduncular screw fixation in the lumbosacral spine. Clin Orthop Relat Res 1986; 203:99.
- Edwards CC. Sacral fixation device, design and preliminary results. Presented at the 19th Annual Meeting of the Scoliosis Research Society, Orlando, Florida; 19–22 September 1984, p. 135.
- Olerud S, Sjoström L, Karlström G, Ham-Berg M. Spontaneous effect of increased stability of the lower lumbar spine in cases of severe chronic back pain. Clin Orthop 1986; 203:67.
- Saillant G. Anatomical study of vertebral pedicles. Surgical application (in French). Rev Chir Orthop Reparatrice Appar Mot 1976; 62:157.
- Weinstein JN, Spratt KF, Spengler D, Brick C. Spinal pedicle fixation: reliability and validity of roentgenogram-based assessment and surgical factors on successful screw placement. Spine 1988; 13:1012.
- Whitecloud TS III, Skalley T, Morgan E, Cook S. Roentgenographic measurement of pedicle screw penetration. Clin Orthop Relat Res 1989; 245:57–68.