

Functional outcomes following arthroscopic ankle arthrodesis for isolated ankle arthrosis

Mohamed H. Khalil, Moustafa R. Hafez

Department of Orthopedic Surgery, Faculty of Medicine, Cairo University Teaching Hospitals, Cairo, Egypt

Correspondence to Mohamed H. Khalil, MD, Department of Orthopedic Surgery, Faculty of Medicine, Cairo University Teaching Hospitals, Giza, 12588 Cairo, 002, Egypt. Tel: +20 3797 6272; fax: 02 37494579; e-mail: mohamedhussein1980@gmail.com

Received: 24 September 2019

Revised: 1 October 2019

Accepted: 14 October 2019

Published: 18 August 2020

The Egyptian Orthopaedic Journal 2019, 54:161–167

Background

Painful ankle arthrosis is a challenging orthopedic problem. Ankle arthrodesis is deemed to be the treatment of choice for painful ankle arthrosis that failed to respond to conservative management. The arthroscopic technique in ankle arthrodesis revealed a better pain control during the postoperative period, less morbidity, a faster return to a normal life after rehabilitation, and reduced costs compared with open arthrodesis. The aim of this study was to evaluate the functional outcomes of arthroscopic ankle arthrodesis (AAA) using the American Orthopedic Foot and Ankle Society (AOFAS) score of the heel and hind foot.

Patients and methods

A total of 31 patients with advanced ankle arthrosis underwent AAA, comprising 20 (64.5%) male patients and 11 (35.5%) female patients. The mean age of the patients was 31.74 (range: 18–54) years. The right ankle joint was involved in 18 (58.1%) patients, whereas the left ankle was affected in 13 (41.9%) cases. Moreover, 27 (87.1%) patients had post-traumatic ankle arthrosis, whereas four (12.9%) patients had postseptic ankle arthrosis.

Functional assessment was done at 3, 6, and 12 months after surgery using the AOFAS score of the heel and hind foot.

Results

The mean follow-up period was 12.87 (range: 12–16) months. The mean operative time was 87.9 (range: 75–120)min. The mean AOFAS score of the heel and hind foot improved significantly from 39.71 (range: 17–65) preoperative to 82.61 (range: 57–92) points at the final follow-up period. Ankle joint fusion was accomplished in 28 (90.3%) patients after a mean time interval of 9.32 (range: 8–12) weeks.

Conclusion

AAA proved to be a successful and safe method of treatment in resistant end-stage ankle arthrosis with satisfactory functional outcomes.

Keywords:

advanced ankle arthritis, ankle fusion, arthroscopic ankle arthrodesis

Egypt Orthop J 54:161–167

© 2020 The Egyptian Orthopaedic Journal

1110-1148

Introduction

Ankle arthrosis affects ~1% of the world's adult population, leading to pain, dysfunction, and movement impairment [1,2]. Valderrabano *et al.* [2] reported that trauma is considered the main cause responsible for secondary ankle arthrosis. The incidence of primary ankle arthrosis is ~7–9% of patients with ankle arthrosis. Furthermore, secondary ankle arthrosis occurs as a result of rheumatoid arthritis, hemochromatosis, residual clubfoot deformity, avascular necrosis of the talus, osteochondral lesions, and postinfectious conditions [3,4].

The treatment of ankle arthrosis includes conservative and operative methods [5]. Conservative treatment of ankle arthrosis comprises nonsteroidal anti-inflammatory medications, orthosis, bracing, shoe modification, and corticosteroid injection [6,7].

Operative treatment methods of advanced ankle arthrosis include arthroscopic debridement, synovectomy, excision of impinging osteophytes, joint distraction [8], arthrodesis, and arthroplasty [9].

Ankle arthrodesis is considered the gold standard management for end-stage ankle arthrosis that failed to respond to conservative management [10].

Ankle arthrodesis can be accomplished using an open or an arthroscopic technique. The arthroscopic technique of ankle arthrodesis has several merits compared with the open technique, including less blood loss, shorter time interval to achieve joint

This is an open access journal, and articles are distributed under the terms of the Creative Commons Attribution-NonCommercial-ShareAlike 4.0 License, which allows others to remix, tweak, and build upon the work non-commercially, as long as appropriate credit is given and the new creations are licensed under the identical terms.

fusion, speedy rehabilitation, lower incidence of complications, less morbidity following surgery, and shorter hospital stay [11,12].

Despite these advantages, some concerns have been expressed regarding arthroscopic ankle arthrodesis (AAA), including the ability to correct significant angular deformities or bone loss [13]. In addition, AAA requires specialized instruments, and the procedure may be technically more demanding than the open technique.

The aim of this study was to evaluate the functional outcomes of AAA in treatment of end-stage ankle arthrosis resistant to conservative treatment. In theory, AAA is a safe and efficient treatment method in advanced ankle arthrosis resistant to conservative treatment.

Patients and methods

This study is a single-center case-series prospective study involving 31 patients who underwent AAA in Cairo University (Kasr Al Ainy) Hospital between August 2016 and October 2017. This study was approved by the ethical committee in orthopedic department in Cairo university teaching hospital.

The inclusion criteria were as follows:

- (1) Symptomatic advanced stage of ankle arthrosis resistant to conservative treatment.
- (2) Mild axial malalignment of the ankle joints less than 15°.
- (3) Age: 18–54 years.

The exclusion criteria were as follows:

- (1) Severe axial malalignment of the ankle joints greater than 15°.
- (2) Significant anteroposterior talar translation.
- (3) Extensive bony defect of the ankle joint.
- (4) Presence of active infection.
- (5) Rheumatoid arthritis.
- (6) History of previous failed arthrodesis.
- (7) Charcot arthropathy.

This study included 31 patients, comprising 20 (64.5%) males and 11 (35.5%) females. The mean±SD age of the patients was 31.74±10.84 (range: 18–54) years. The right ankle joint was involved in 18 (58.1%) cases, whereas the left side was affected in 13 (41.9%) patients. According to the etiology of ankle arthrosis, 27 (87.1%) patients were post-traumatic, whereas four (12.9%) patients experienced postseptic ankle arthrosis.

Clinical evaluation

Preoperative clinical assessment included history of pain severity, gait abnormality, previous conservative treatment, smoking, and type of daily activities. Local examination of the affected ankle joints included site of tenderness, ankle instability, clinical malalignment (Valgus heel angle between the bisector line of heel and the bisector line of the Achilles tendon while the patient is standing), range of motion of the ankle joint, and examination of the contralateral ankle, ipsilateral knee, and hip joints. Furthermore, skin condition, previous scar, and the condition of the limb vascularity were assessed.

Radiological evaluation

Preoperative radiographic evaluation was done using standard radiographs (anteroposterior, mortise, and lateral standing radiographs of the foot and ankle)] to assess the following:

- (1) Degree of ankle arthrosis (Figs 1, 2).
- (2) Degree of ankle joints malalignment.
- (3) Extent of bony defects.
- (4) Presence of subtalar and midfoot joints arthritic changes.

Postoperative radiographic assessment was done immediately postoperatively, at 1 month following arthrodesis, and then every 2 weeks until joint fusion was achieved (Fig. 3). Furthermore, follow-up radiographic assessment was done at 3, 6, and 12 months postoperatively. Joint fusion was defined clinically as a painless stable ankle on manipulation and weight-bearing with radiographic evidence of bridging bone trabeculae without failure of internal fixation or change in position.

Functional evaluation

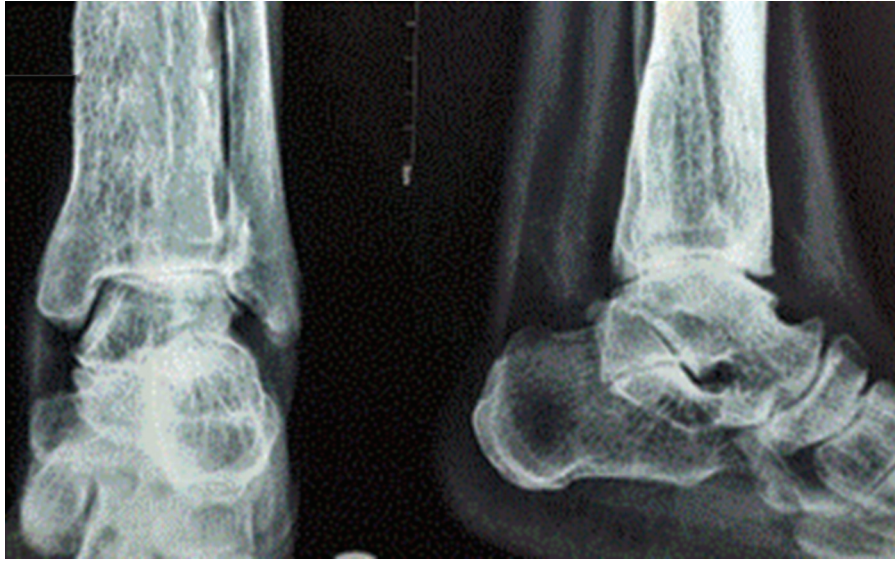Functional assessment was done at 3, 6, and 12 months after surgery using the American Orthopedic Foot and Ankle Society (AOFAS) [14] score of the heel and hind foot.

The AOFAS score was modified by elimination of the points for the sagittal motion (of the ankle joints), achieving a maximum of 92 points.

Statistical methods

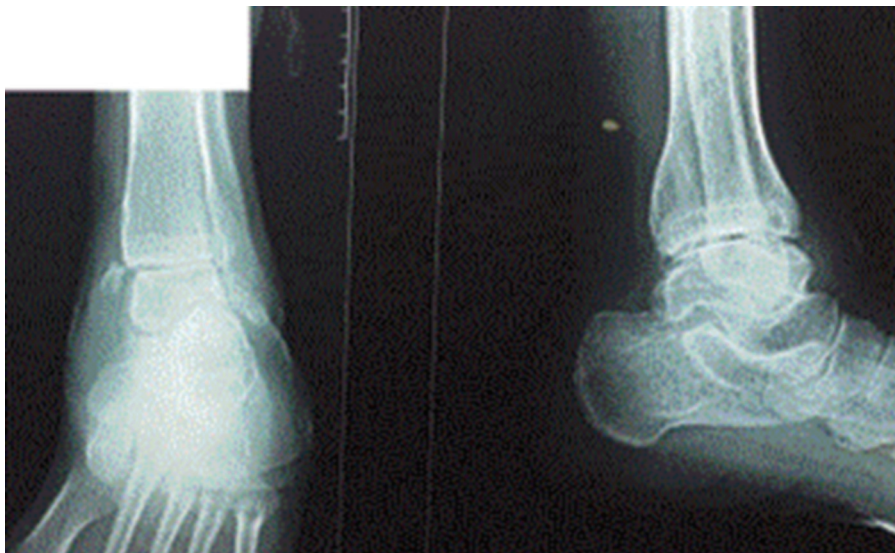Data were coded and entered using computer program IBM SPSS (statistical package for the social sciences; IBM Corp, Armonk, NY, USA) version 25 for Microsoft Windows. Data were summarized using mean, SD, minimum, and maximum for quantitative variables, and frequencies (number of cases) and

Figure 1



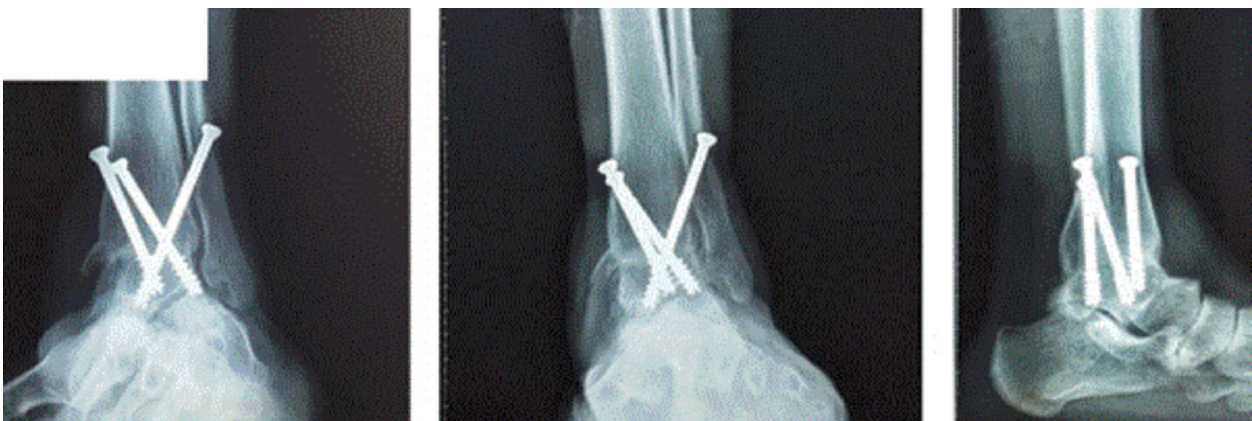Standing anteroposterior and lateral ankle radiographs showing narrowing of the ankle joint space and osteophyte formation.

Figure 2



Standing anteroposterior and lateral ankle radiographs showing complete erosion of the medial malleolus of the ankle joint.

Figure 3



Standing anteroposterior, mortise, and lateral ankle radiographs showing joint fusion 3 months postoperatively.

relative frequencies (percentages) for categorical variables. Comparison between preoperative and postoperative values was done using Wilcoxon signed rank test [15]. For comparing categorical data, χ^2 -test was performed. Exact test was used instead when the expected frequency is less than 5 [16]. *P* values less than 0.05 were considered as statistically significant.

Surgical technique

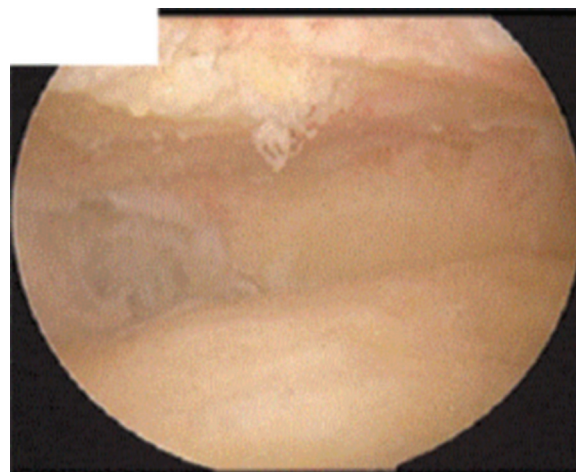
All patients were placed in the supine position with the ipsilateral knee flexed 90° after administration of either spinal or general anesthesia. Prophylactic antibiotics were administered 1 h before surgery followed by application of a tourniquet to the upper thigh of the involved limb. No traction device was used. Manipulation of the ankle joint was done under anesthesia and percutaneous Achilles tendon lengthening was done if neutral ankle dorsiflexion could not be reached. This was done in two (6.5%) patients.

The anteromedial (visualizing) portal was established first just medial to the tibialis anterior tendon. A 4-mm 30° arthroscope was used. The anterolateral (working) portal was then established lateral to the extensor digitorum communis and peroneus tertius tendons under direct vision using the outside-in technique. Care was taken to avoid damage of the superficial peroneal nerve during anterolateral portal establishment. Debridement of the soft tissues was then performed using a shaver and excision of anterior tibiotalar osteophytes was done to access the ankle joint. The entire cartilage of the ankle joint was removed using curettes, curved small osteotomes, and a burr. The lateral malleolus articular surface as well as the medial gutter was also prepared thoroughly over the entire of the medial malleolus.

After adequate preparation of the ankle joint surfaces (Fig. 4), microfractures were performed at both tibiotalar surfaces (Fig. 5).

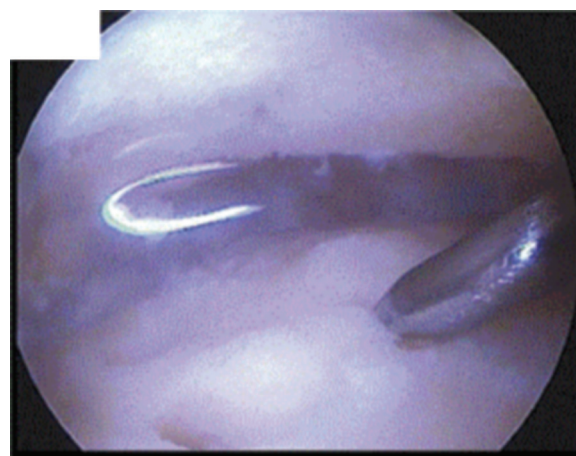
Under image intensifier guidance, three cannulated 6.5-mm screws were percutaneously inserted over guide wires to fix the ankle joint (Fig. 6) in the appropriate position (neutral at the sagittal plane, 5° of valgus at the coronal plane, and 5° of external rotation). Two screws were placed medially from the distal tibia into the body and neck of the talus, and the third screw was placed from lateral side (Fig. 6). Bone grafts or substitutes were not used. Care was taken to avoid penetration of the subtalar joint. Wound closure was done followed by application of a sterile dressing and a below-knee cast.

Figure 4



Arthroscopic image showing proper preparation and removal of the articular cartilage of the ankle joint.

Figure 5



Arthroscopic image demonstrating micro fractures of the prepared ankle joint.

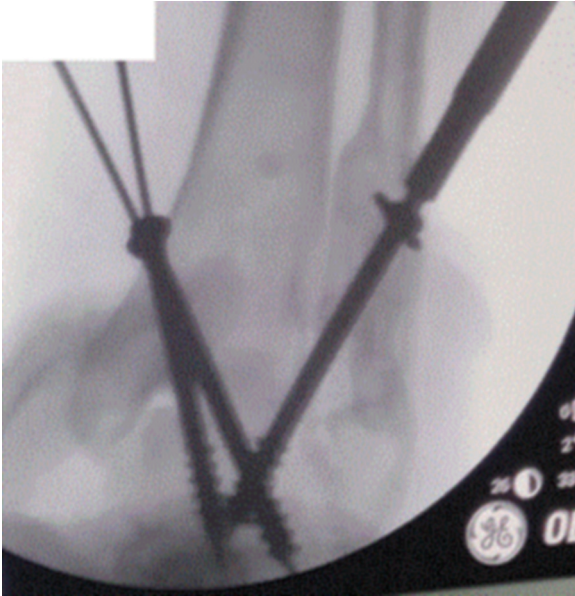Postoperative rehabilitation protocol

All patients were instructed to avoid weight-bearing during the initial 6 weeks after surgery. Partial weight-bearing was allowed 6 weeks after surgery, which was progressed to full weight-bearing 12 weeks postoperatively.

Results

The mean follow-up period was 12.87±1.31 SD (range: 12–16) months. All patients were available at the final follow-up period. The mean±SD operative time was 87.9±14.59 (range: 75–120)min. Ankle joint fusion was achieved in 28 (90.3%) patients. Nonunion was observed in three (9.7%) patients. The mean time interval required to achieve joint fusion was 9.32 ±1.01 SD (range: 8–12) weeks.

Figure 6



Intraoperative fluoroscopic image showing the cannulated screws insertional configuration over guide wires for ankle joint fixation.

Table 1 Complications detected in this study following arthroscopic ankle arthrodesis

Complications	Number of patients and their percentage within the group
Nonunion	3 (9.7)
Superficial wound infection	2 (6.5)
Superficial peroneal nerve injury	1 (3.2)
Implant-related complications	0
Adjacent joint arthrosis	0
Deep veins thrombosis	0

The mean \pm SD AOFAS score improved significantly from 39.71 \pm 13.4 (range: 17–65) preoperatively to 82.61 \pm 9.78 (range:57–92) at the final follow-up period ($P<0.001$).

Postoperative complications

Nonunion was detected in three (9.7%) patients who underwent revision surgery using the open technique and bone grafting. Superficial wound infection occurred in two (6.5%) patients which resolved after repeated wound dressing and oral antibiotics. Superficial peroneal nerve injury was observed in one (3.2%) patient. This injury might have occurred during establishment of the anterolateral portal and did not influence joint fusion. Neurotonic medications were given to enhance recovery of the observed nerve injury. Full recovery was achieved 9 months postoperatively without residual symptoms. No other complications

such as adjacent joint arthrosis, implant-related complications, or deep veins thrombosis were reported in this study (Table 1).

Discussion

Ankle arthrodesis is considered the gold standard management for end-stage ankle arthrosis that failed to respond to conservative management [10].

The prime targets of ankle arthrodesis are abolishing pain, correction of deformity of the degenerated ankle joint, and achievement of a plantigrade foot to obtain pain-free mobility [17].

Various studies in literature compared the results of arthroscopic and open ankle arthrodesis [11,12]. Myerson and Quill [11] proved that the time interval to achieve joint fusion was significantly shorter for AAA compared with open ankle arthrodesis. However, there was no statistically significant difference between both groups regarding the fusion rates. A comparative study by O'Brien *et al.* [12] showed that AAA achieved comparable fusion rates to open arthrodesis. However, the arthroscopic technique showed statistically significant shorter surgical time, hospital stay, less blood loss, and less morbidity compared with the open technique.

In this study, a rate of joint fusion of 90.3% of the patients was achieved after a mean time interval of 9.32 weeks. Furthermore, the mean AOFAS score improved significantly from 39.71 (range: 17–65) preoperatively to 82.61 (range: 57–92) points after a mean follow-up period of 12.87 months.

Various studies in the literature documented the successful outcomes following AAA [18–20]. Collman *et al.* [18] in a study including 39 patients who underwent AAA showed that the fusion rate was 87.2%, and the average time to obtain fusion was 47 days. Another study carried out by Ogilvie-Harris *et al.* [19] involving 19 patients who underwent AAA documented that the average length of hospital stay was only 1 day, fusion rate was 94.7%, and that 84.2% of the patients had excellent or good outcomes. Glick *et al.* [20] evaluated the results of 34 patients who underwent AAA and reported that the fusion rate was 97%, the mean time to obtain arthrodesis was 9 weeks, and excellent to good results were achieved in 86% of the patients.

The average time interval required to obtain fusion following AAA in this study was 9.32 (range: 8–12)

weeks. This was comparable to Myerson and Quill [11] and Glick *et al.* [20] who reported average fusion time intervals of 8.7 and 9 weeks, respectively. However, an average fusion time interval of 12 weeks was reported in other literature studies [21,22].

In this study, the rate of fusion was 90.3% following AAA. This is higher than the fusion rate obtained by Collman *et al.* [18] who reported a fusion rate of 87.2% only, whereas Winson *et al.* [21] reported a fusion rate of 92.4% which is comparable to the fusion rate achieved in this study. However, the fusion rate achieved in this study is less than that reported by Glick *et al.* [20] who reported a fusion rate of 97% in 34 patients.

Furthermore, the mean postoperative AOFAS score achieved in this study was 82.61 (range: 57–92) points, and this is comparable to literature studies carried out by Duan *et al.* [23] and Slater *et al.* [24] who reported mean AOFAS scores following AAA of 84 and 82.04, respectively.

Controversy existed about the postoperative rehabilitation protocol following AAA. Cannon *et al.* [25] compared the influence of early weight-bearing versus weight-bearing restriction on the extent and progression of joint fusion at 2 and 4 months following AAA. The previous study reported that there was no significant difference in the extent of union at 2 months, and that all patients in both groups achieved solid arthrodesis at 4 months postoperatively.

The extent of ankle deformity before AAA is also a matter of controversy. Gougoulas *et al.* [26] compared the results of AAA in treatment of 48 ankles with minor deformity and 30 ankles with more than 15° of preoperative varus or valgus angulation. Fusion was obtained in 98% of the patients with minor deformity and 97% of those with major deformity, and no significant difference was observed in the fusion rates or the time interval required for fusion.

Peterson *et al.* [27] carried out a study to analyze the cost difference between outpatient AAA and inpatient open ankle arthrodesis and proved that outpatient AAA proved to be less expensive compared with the inpatient open ankle arthrodesis.

The complications encountered in this study are shown in Table 1. Nonunion was observed in three (9.7%) patients, superficial wound infection occurred in two (6.5%) patients, and superficial peroneal nerve injury was detected in one (3.2%) patient.

Abicht and Roukis [28] in a systemic review reported that the incidence of nonunion following AAA was 8.6% using the two-portal anterior arthroscopic approach and fixation with two or three cannulated screws. The incidence of nonunion reported by Abicht and Roukis [28] is comparable to the incidence of nonunion in this study.

Several studies in literature reported other complications that may take place following AAA including removal of fixation screws (18.6–31%), deep infection (0.85%), superficial infection (2.5%), deep veins thrombosis, and malalignment requiring revision surgery (0.85%) [21,22].

The main limitations of this study is the lack of control group and the relatively short follow-up period.

Conclusion

The arthroscopic technique for ankle arthrodesis proved to be a successful and safe method of treatment in resistant end-stage ankle arthrosis with satisfactory functional outcomes. AAA offered a high fusion rate and successful functional outcomes. AAA has been associated with similar rates of fusion, less time to achieve joint fusion, decreased pain, shorter hospital stay, earlier mobilization, and fewer complications compared with open ankle arthrodesis.

Financial support and sponsorship

Nil.

Conflicts of interest

There are no conflicts of interest.

References

- 1 Glazebrook M, Daniels T, Younger A, Foote CJ, Penner M, Wing K, *et al.* Comparison of health-related quality of life between patients with end-stage ankle and hip arthrosis. *J Bone Jt Surg* 2008; 90:499–505.
- 2 Valderrabano V, Horisberger M, Russell I, Dougall H, Hintermann B. Etiology of ankle osteoarthritis. *Clin Orthop Relat Res* 2009; 467:1800–1806.
- 3 Saltzman CL, Salamon ML, Blanchard GM, Huff T, Hayes A, Buckwalter JA, *et al.* Epidemiology of ankle arthritis: report of a consecutive series of 639 patients from a tertiary orthopaedic center. *Iowa Orthop J* 2005; 25:44–46.
- 4 Kuettner KE, Cole AA. Cartilage degeneration in different human joints. *Osteoarthr Cartil* 2005; 13:93–103.
- 5 Katcherian DA. Treatment of ankle arthrosis. *Clin Orthop Relat Res* 1998; 349:48–57.
- 6 Tallia AF, Cardone DA. Diagnostic and therapeutic injection of the ankle and foot. *Am Fam Physician*. 2003; 68:1356–1362.
- 7 Merritt JL. Advances in orthotics for the patient with rheumatoid arthritis. *J Rheumatol Suppl* 1987; 14 Suppl 15:62–67.
- 8 Marijnissen ACA, Van Roermond PM, Van Melkebeek J, Schenk W, Verbout AJ, Bijlsma JWJ, *et al.* Clinical benefit of joint distraction in the treatment of severe osteoarthritis of the ankle: proof of concept in an open prospective study and in a randomized controlled study. *Arthritis Rheum* 2002; 46:2893–2902.

- 9 Giannini S, Leardini A, O'Connor JJ. Total ankle replacement: review of the designs and of the current status. *Foot Ankle Surg* 2000; 6:77–88.
- 10 Wasserman LR, Saltzman CL, Amendola A. Minimally invasive ankle reconstruction: current scope and indications. *Orthop Clin North Am* 2004; 35:247–253.
- 11 Myerson MS, Quill G. Ankle arthrodesis. A comparison of an arthroscopic and an open method of treatment. *Clin Orthop Relat Res* 1991; 268:84–95.
- 12 O'Brien TS, Hart TS, Shereff MJ, Stone J, Johnson J. Open versus arthroscopic ankle arthrodesis: a comparative study. *Foot Ankle Int* 1999; 20:368–374.
- 13 Coester LM, Saltzman CL, Leupold J, Pontarelli W. Long-term results following ankle arthrodesis for post-traumatic arthritis. *J Bone Joint Surg Am* 2001; 83-A:219–228.
- 14 Kitaoka HB, Alexander IJ, Adelaar RS, Nunley JA, Myerson MS, Sanders M. Clinical rating systems for the ankle-hindfoot, midfoot, hallux, and lesser toes. *Foot Ankle Int*. 1994; 15:349–353.
- 15 Chan YH. Biostatistics 102: quantitative data – parametric & non-parametric tests. *Singapore Med J* 2003; 44:391–396.
- 16 Chan YH. Biostatistics 103: qualitative data – tests of independence. *Singapore Med J*. 2003; 44:498–503.
- 17 Thordarson DB. Fusion in posttraumatic foot and ankle reconstruction. *J Am Acad Orthop Surg* 2004; 12:322–333.
- 18 Collman DR, Kaas MH, Schubert JM. Arthroscopic ankle arthrodesis: factors influencing union in 39 consecutive patients. *Foot Ankle Int* 2006; 27:1079–1085.
- 19 Ogilvie-Harris DJ, Lieberman I, Fitsialos D. Arthroscopically assisted arthrodesis for osteoarthrotic ankles. *J Bone Joint Surg Am* 1993; 75:1167–1174.
- 20 Glick JM, Morgan CD, Myerson MS, Sampson TG, Mann JA. Ankle arthrodesis using an arthroscopic method: long-term follow-up of 34 cases. *Arthroscopy* 1996; 12:428–434.
- 21 Winson IG, Robinson DE, Allen PE. Arthroscopic ankle arthrodesis. *J Bone Joint Surg Br* 2005; 87:343–347.
- 22 Ferkel RD, Hewitt M. Long-term results of arthroscopic ankle arthrodesis. *Foot Ankle Int* 2005; 26:275–280.
- 23 Duan X, Yang L, Yin L. Arthroscopic arthrodesis for ankle arthritis without bone graft. *J Orthop Surg Res* 2016; 11:1–8.
- 24 Slater GL, Sayres SC, O'Malley MJ. Anterior ankle arthrodesis. *World J Orthop* 2014; 5:1.
- 25 Cannon LB, Brown J, Cooke PH. Early weight bearing is safe following arthroscopic ankle arthrodesis. *Foot Ankle Surg* 2004; 10:135–139.
- 26 Gougoulias NE, Agathangelidis FG, Parsons SW. Arthroscopic ankle arthrodesis. *Foot Ankle Int* 2007; 28:695–706.
- 27 Peterson KS, Lee MS, Buddecke DE. Arthroscopic versus open ankle arthrodesis: a retrospective cost analysis. *J Foot Ankle Surg* 2010; 49:242–247.
- 28 Abicht BP, Roukis TS. Incidence of nonunion after isolated arthroscopic ankle arthrodesis. *Arthrosc J Arthrosc Relat Surg* 2013; 29:949–954.