

# Cementless total hip replacement for hip dysplasia: anatomical hip center is associated with better patient-reported functional outcome

Abdullah S. Hammad<sup>a</sup>, Hesham M. Gawish<sup>b</sup>

<sup>a</sup>Department of Orthopaedic Surgery and Traumatology, Faculty of Medicine, Alexandria University, Alexandria, <sup>b</sup>Department of Orthopaedic Surgery and Traumatology, Kafr El Sheikh University, Kafr El Sheikh, Egypt

Correspondence to Abdallah S. Hammad, MD, Zezenia Alexandria, Egypt  
Tel: +20 111 105 6406;  
e-mail: a\_hammad00@alexmed.edu.eg

**Received:** 12 May 2022

**Revised:** 19 May 2022

**Accepted:** 22 May 2022

**Published:** 14 April 2023

**The Egyptian Orthopaedic Journal** 2023, 57:238–252

## Background

Total hip arthroplasty in patients with dysplastic hips is a challenging procedure. The main goal of surgery is to achieve anatomical center of rotation to improve the abductor function, patient satisfaction, and implant survival. The aim of this study was to report the mid-term functional results using the Oxford hip score (OHS) after cementless total hip replacement (THR).

## Patients and methods

This was a retrospective analysis of the prospectively collected data of patients who had a THR done at our institution with hip dysplasia. Between September 2011 and December 2019, a total of 23 consecutive patients (26 hips) with Crowe II–IV developmental dysplasia were treated with primary cementless THR. The mean age for patients included were  $34.1 \pm 15.2$  years. Females were more than males. The left side was operated more than the right side, and there were three bilateral cases. The mean preoperative OHS was  $21 \pm 6.6$  points.

## Results

All patients were followed up for a mean of  $3.4 \pm 2.6$  years (range, 1–11 years). None of the cases were lost to follow-up. The mean OHS improved significantly from  $21.2 \pm 6.6$  points (range, 8–38) preoperatively to  $40.9 \pm 4.8$  points (range, 28–48) in the final OHS ( $Z=4.45$ ,  $P<0.001$ ). Regarding the final OHS, both Crowe types II and III were better than Crowe type IV, and the difference was statistically significant. The functional leg length discrepancy improved from a median of 3 (0–7) cm preoperatively to 0 (0–3) cm postoperatively ( $Z=4.3$ ,  $P<0.0001$ ). All cases that required shortening were Crowe IV dysplasia (five cases). A total of 22 (88%) hips were reconstructed within 2 cm of the other hip.

## Conclusion

Restoration of anatomic center of rotation as close as possible was associated with better functional outcome. Cementless fixation was possible in all cases.

## Keywords:

anatomical hip center, cementless hip replacement, Crowe III and IV, hip dysplasia

Egypt Orthop J 2023, 57:238–252

© 2023 The Egyptian Orthopaedic Journal

1110-1148

## Introduction

Total hip replacement (THR) is the gold standard treatment for end-stage osteoarthritis of the hip secondary to adult hip dysplasia. In mild degree of hip dysplasia, the procedure is relatively simple, described as just like primary THR for degenerative arthritis. On the contrary, THR for more severe hip dysplasia is a challenging procedure. The surgeon should be prepared to deal with a variety of soft tissue contractures, abnormal location of the hip center, and different presentations of bone defects. Although proven to be effective most of the time, previous pediatric orthopedic surgical interventions may add to the difficulty of THR in some cases. Retained hardware and the presence of posterior wall defect after anterolateral coverage osteotomies are two common examples [1,2].

The degree of the hip dysplasia is usually assessed by either Crowe [3] or Hartofilakidis [4,5] systems. The

assessment of the complexity of dysplasia should lead to a well-defined surgical tactic to address the expected surgical challenges. The goals of surgery should be alleviation of pain, restoration of hip joint biomechanics, in particular, the abductor muscle momentum, and the durable fixation of the implant.

There are two reconstruction procedures previously described in the literature, namely, the anatomic hip center (AHC) and the high hip center (HHC). In AHC, the acetabulum is reconstructed at the horizontal level of the true acetabulum. Adjuvant procedure may be required to manage bone defect and improve coverage. One method is medialization of

This is an open access journal, and articles are distributed under the terms of the Creative Commons Attribution-NonCommercial-ShareAlike 4.0 License, which allows others to remix, tweak, and build upon the work non-commercially, as long as appropriate credit is given and the new creations are licensed under the identical terms.

the cup after controlled break in the acetabular floor known as cotyloplasty. Structural graft or augment for roof augmentation is another method. A shortening osteotomy may be required to relocate a high riding Crowe type IV hip and to avoid excessive lengthening. In the HHC technique, the acetabulum is reconstructed at a slightly higher but still medial position to seek better bone stock and avoid shortening osteotomy.

The improvement of implant design and coating had shifted the gold standard practice of cemented anatomic hip reconstruction to a cementless fixation. The decreased acetabular offset and/or excessive anteversion is compensated from the femoral side by the use of modular or custom-made stems [1,2,6].

From the patient perspective, either treatment strategy should lead to significant improvement in their hip function and the overall quality of life. A person-centered and value-based care is most important for patients with dysplasia who usually have their hips replaced at a younger age relative to patients with primary OA. OHS is a patient-reported, more sensitive and validated score for evaluation of operative results after THR, especially in young adults [7]. A recent meta-analysis comparing the anatomic to the HHC concluded that the two techniques have comparable survival rate. When the two techniques were compared in terms of function, the available evidence did not provide a clear answer. Most of the previous reports used the Harris hip score (HHS) for evaluation of the results. As per authors' advice, future research should include more sensitive patient-reported outcome scores [8].

The primary outcome of this study was to report the mid-term functional results using the OHS after cementless THR for patients presented with hip dysplasia. The secondary outcome was to study the relation between factors such as accuracy of restoration of the hip center, the degree of dysplasia, and the functional outcome.

## Patients and methods

For each patient admitted for THR at our institution, an informed consent was obtained. A routine data sheet was filled and saved. Data collected included patients' demographics, diagnosis, pertinent clinical data, preoperative OHS [9], and operative data. Imaging studies were saved on a personal computer. A digital copy of the implant identification stickers was also saved.

As per our protocol, all patients are followed regularly. This includes early postoperative visits along with

yearly regular checks for the first 3 years. Thereafter, patients are asked to pay a visit every 3 years or if they feel something goes wrong with their hips.

This study is a retrospective analysis of the prospectively collected data of patients who had a THR done at our institution with a diagnosis of hip dysplasia, Crowe types II–IV. The study protocol was approved by the Institutional Review Board of Alexandria University. Between September 2011 and December 2019, a total of 23 consecutive patients (26 hips) with Crowe type II–IV developmental dysplasia were treated with primary cementless THR at our institution.

The mean age for patients included were  $34.1 \pm 15.2$  years. Females were more than males. The left side was operated more than the right side, and there were three bilateral cases (Table 1).

## Preoperative data

For all patients, a thorough clinical evaluation of their condition was carried out. This included detailed history and examination of the hip, lumbosacral spine, and the ipsilateral knee. Functional leg length discrepancy (LLD) was measured while the patients laid supine from the xiphi-sternum to both medial malleoli. This was done without correction of deformity to recognize the amount of soft tissue release required. The expected LLD for bilateral hip cases was measured after the first THR, and the value was recorded for both hips. Radiologic workup included anteroposterior (A/P) view of the pelvis and A/P and lateral view of the affected hip. A/P view of the pelvis was used in the preoperative planning. Lateral radiograph was used to detect the degree of femoral ante-version proximal femur bow or deformity. Long leg film was done to assess the overall alignment and true femoral length and to detect the presence of compensatory knee valgus.

**Table 1** Preoperative data collected for 23 patients with Crowe II–IV hip dysplasia treated by total hip replacement

Domain (N of hips=26) (N of patients=23)	Distribution	n (%)
Sex (N=23)	Male	6 (26)
	Female	17 (74)
Side	Right	6 (23)
	Left	17 (65)
	Bilateral	3 (12)
Crowe classification	II	9 (35)
	III	8 (31)
	IV	9 (35)
Preoperative LLD (cm)	Mean $\pm$ SD	3.2 $\pm$ 2
	Mean (minimum–maximum)	3 (0–7)
Pelvic obliquity 2ry to spine deformity		2 (8)
Proximal femoral deformity		8 (31)
Previous surgery		6 (23)

LLD, leg length discrepancy.

Computed tomography scan with three-dimensional reconstruction was done in cases with severe dysplasia to better estimate the extent and location of acetabular bone deficiency. The mean preoperative OHS was  $21 \pm 6.6$  points. Preoperative clinical and radiologic data are listed in Table 1.

Previous surgical interventions were in the form of pelvic osteotomies in four hips and combined femoral and pelvic osteotomies in one hip.

### Preoperative planning

Preoperative planning was carried clinically and on the standard A/P pelvis radiograph using IC measure software package, version 3.0.0.368. (Fig. 1). If clinical examination revealed functional LLD more than 4 cm, it was an indication for possible osteotomy. Correction of shortening was aimed at maximum of 3–4 cm to avoid nerve injury. This was thoroughly discussed and made clear for the patient. Preoperative template using acetate or digital template was not routinely carried in our unit. Instead, stepwise examination of the radiograph was done as illustrated in Fig. 1. Expected uncoverage more than 30% of the hemispherical cup

was taken in consideration for possible augmentation. Neck cut was carefully planned on the radiograph according to the pre-existing varus or valgus alignment (Fig. 1).

Small cementless shells starting from size 40 mm (Triology IT, Zimmer Biomet, Warsaw, Indiana, USA) were prepared. A variety of stems were available to adapt the increased version and narrow canal of the dysplastic femur (Table 2).

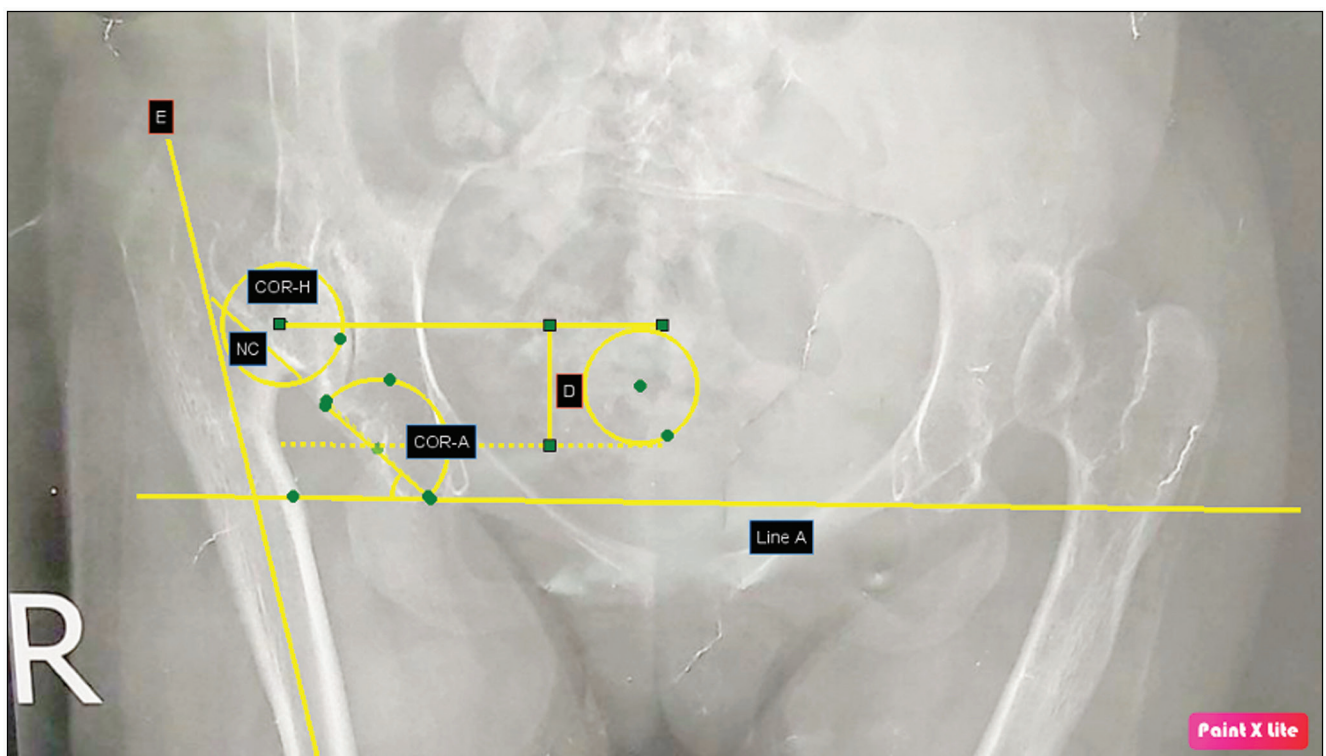
### Surgical technique

All procedures were done by a single surgeon via the posterolateral approach in a lateral decubitus position. All cases were operated under general anesthesia with 400 mg Teicoplanin as antibiotic prophylaxis taken 1 h before incision.

#### Exposure and sequential soft tissue release

We started with the release of piriformis, then the gluteus maximus tendon, followed by the U-shaped incision of the posterior capsule. The hip was then carefully dislocated posteriorly, the neck cut was done as planned, and the femoral head was removed and

Figure 1



Step 1: inter-tear drop line was drawn as a reference line (line A). Step 2: a hemisphere is plotted at  $45^\circ$  from line A so that its most medial point touches the ilio-ischial line; its inferior most point is on the reference line. The center of this hemisphere is the center of rotation of the acetabulum (COR-A). If present, the extent of superior uncoverage is related to the perimeter of the hemisphere; more than 30% uncoverage may require augmentation. This will help in proper cup positioning, expecting the need of adjuvant procedure. Step 3: determine the center of rotation of the femoral head (COR-H) by the best fit circle. Step 4: the distance D from CRO-H to CRO-A is related to the FH diameter which can be easily measured intraoperatively. If this distance was more than 3 cm, an osteotomy is anticipated. Step 5: planning the entry point of the femoral canal (line E) and the level of neck cut (NC). In this case, the canal had to be opened from the top of an over-riding GT. Narrow or bowed femur requires preparation of conical stems beforehand.

**Table 2 Patients' operative data**

Domain (N=26)	Distribution	n (%)
Acetabular reconstruction	No	10 (38)
	Yes	16 (62)
Type of reconstruction	Roof graft	3 (12)
	Cotyloplasty	8 (31)
	Both	5 (19)
Femoral osteotomy	No	21 (81)
	Yes	5 (19)
Site of femoral osteotomy	Subtrochanteric	2 (8)
	Supracondylar	3 (12)
Bearing surface	COC	1 (4)
	COP	15 (57)
	DM	2 (8)
	MOP	8 (31)
Stem type	Standard double wedge	23 (88)
	Short Wagner cone	2 (8)
	Long stem	1 (4)
Cup size mm	Minimum–maximum	40–55
Head size (mm)	22	5 (19)
	28	3 (12)
	32	18 (69)

kept for potential need as a graft. The release of the anterior capsule from the anterior neck was done over a curved right angle to protect the femoral vessels. The remnants of the ligamentous teres were followed to identify transverse acetabular ligament (TAL) at the inferior border of the acetabulum, and the overhanging inferior capsule was released from the neck cut to the TAL. Frequently, a bleeder from obturator artery branches is encountered and has to be cauterized. If this was not sufficient to rotate the femur to the 90–90 position of internal rotation and flexion, the iliopsoas tendon was released at the lesser trochanter. If the femur could not be delivered anteriorly, the rectus femoris tendon was released from the AIIS. Before starting reaming of the acetabulum, a posterolateral entry point to the femoral canal was done by the box chisel. The medullary finder was advanced gently. The femur was initially broached by the standard broaches to estimate the degree of the native ante-version and/or the need of conical stem.

#### *Smallest cementless cup fixation*

The acetabulum was then gradually reamed with hemispherical reamers till reaching the medial wall of the true acetabulum, with bleeding cancellous bone. In all cases, a cementless porous coated acetabular cup was press fitted into the true AHC and fixed with dome screws. The position of the cup was aimed at 40° of abduction. The position was checked by reproducing the amount of bone uncovered from the preoperative plan. Ante-version of the cup was aimed at 15–20°, taking the TAL as a reference. If excessive femur ante-version was expected from the initial broaching, combined ante-version was kept below 55°.

#### **Acetabular reconstruction**

Acetabular reconstruction was needed in 16 (62%) patients by one or both of the following techniques.

#### *Cotyloplasty*

In cases with global cup uncoverage with less than 70% rim fit, a small drill hole is made in the floor and the depth is measured. Careful medial reaming was done. The depth was repeatedly measured so that the medial penetration to be controlled. This thin periosteal layer was gently pushed by finger, and the floor was packed by a thin layer of bone graft (Fig. 2).

#### *Roof augmentation*

If the superior acetabular cup coverage was unsatisfactory (<70%), a bulk strut bone auto-graft from the resected femoral head was used to provide adequate coverage of the acetabular cup. The graft was fixed using two or three standard screws.

#### **Femoral stem preparation and osteotomy (if needed)**

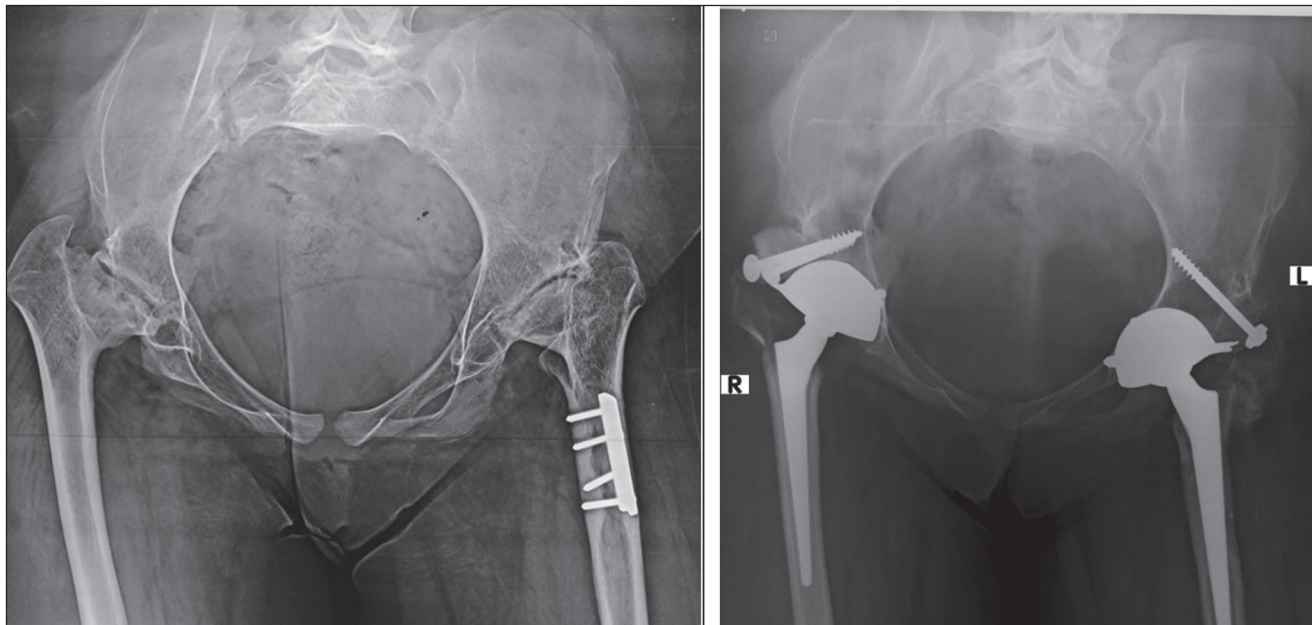
After insertion of acetabular cup, attention was then redirected to the femoral preparation. The stem type was chosen based on the proximal femur anatomy anticipated from the preoperative planning and from intraoperative finding. The proximal femur was reamed and broached to achieve appropriate stem size. One retained plate presented a challenge during removal as it was intra-cortical. After meticulous shaving of the cortical bone out of the plate, the integrity of the proximal femoral canal was saved (Fig. 2).

In two cases, a transverse subtrochanteric osteotomy was carried out, usually at 1–2 cm beneath the lesser trochanter, to shorten the femur by the planned amount. If hip reduction with a femoral trial stem was impossible, additional bone was gradually resected at the osteotomy site to achieve satisfactory hip reduction and avoid excessive tension on the sciatic nerve. The osteotomy was fixed using standard plate and screws after insertion of the stem. In addition, autogenous bone graft from the resected femoral bone fragment was used to fill any gap at the osteotomy site (Fig. 3).

In three hips, the decision was taken to perform a distal femoral osteotomy instead of subtrochanteric osteotomy to correct valgus malalignment of the distal femur. In those cases, the femoral stem was inserted, and then the distal medial closing wedge femoral osteotomy was performed. After relocating the hip, the amount of overlapping bone was resected. The osteotomy was then reduced and internally fixed using a distal femoral locked plate (Fig. 4).

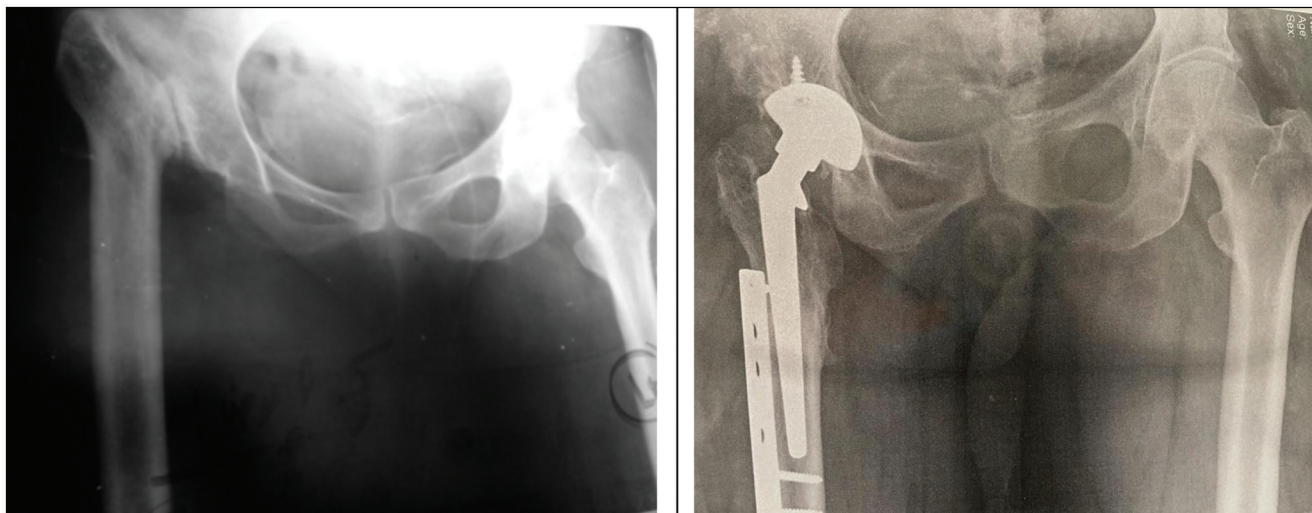
The mean operative time was  $3.01 \pm 0.9$  h (range, 2–5 h). The mean blood loss was  $1013 \pm 538.8$  ml (range, 300–2500 ml). Operative details are listed in Table 2.

Figure 2



A 19-year-old woman with bilateral Crowe III dysplasia. The left side had a retained plate from a previous derotation femoral osteotomy. Both sides were treated by effective medialization (cotyloplasty on the left side) and roof augmentation. The stems used were conical stem. Note the presence of intra-cortical plate on the left side. A dual mobility bearing surface was used. The patient had final OHS of 36 and 34 points for the right and left sides, respectively. OHS, Oxford hip score.

Figure 3



A 45-year-old woman presented with right-side hip dysplasia, Crowe IV. Her 7-year follow-up x-rays show a healed subtrochanteric osteotomy. A conical stem was used. Acetabular bone stock allowed the insertion of a 40-mm cup without the need for grafting or cotyloplasty.

**Postoperative protocol**

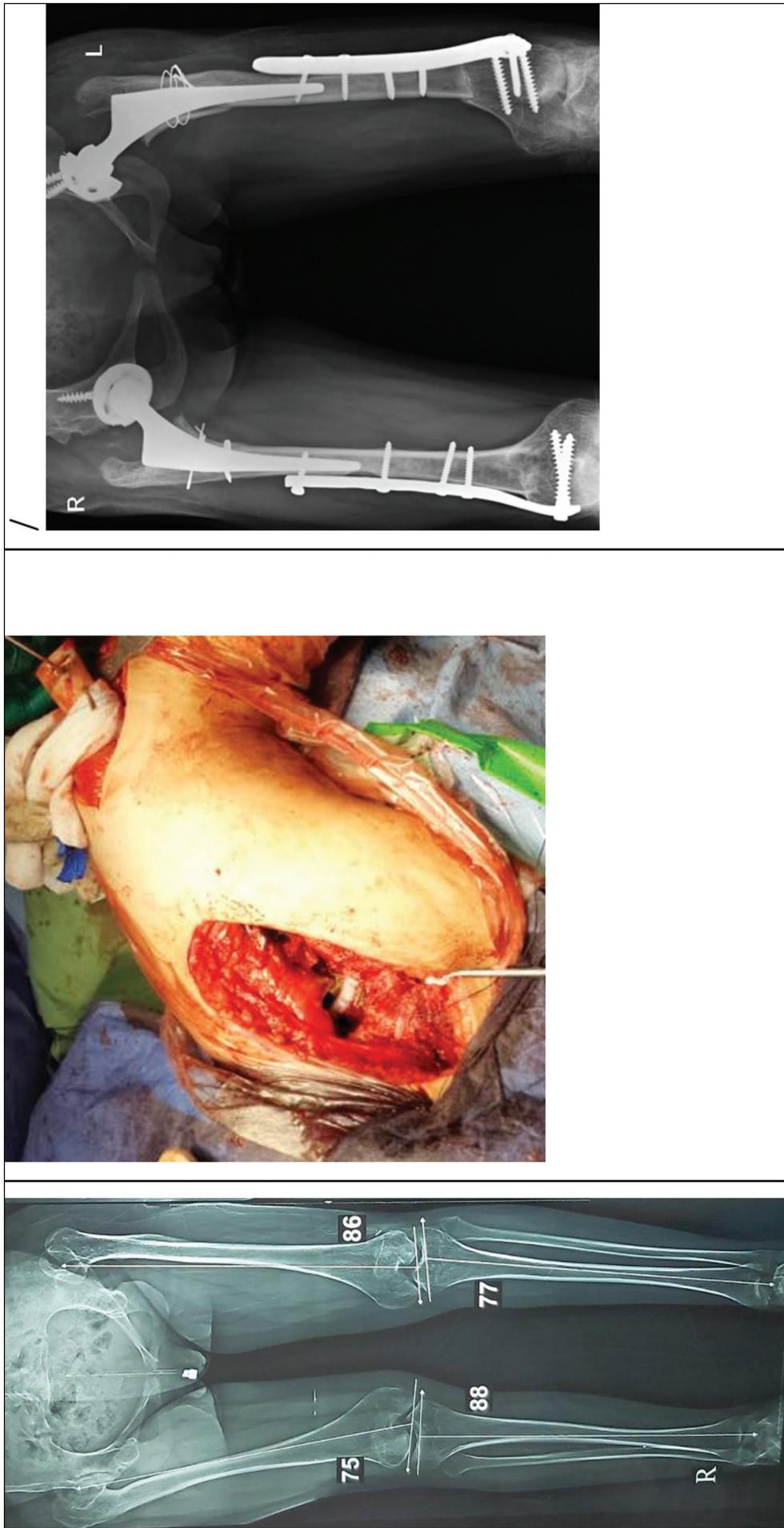
All patients were allowed early touch weight bearing for 6 weeks followed by partial weight bearing for another 6 weeks. The mean hospital stay was 3.5 days (range, 2–6). Subcutaneous enoxaparin 40 mg (Clexane) was given to all patients for 35 days for thrombo-prophylaxis. All patients received a second dose of intravenous Ticoplanin 400mg in the second postoperative day. Neurovascular status was checked. Typically, these patients need time to undo the long-standing compensatory pelvic obliquity, and for that

reason, functional leg length was not recorded except after 3–6 months of surgery.

The postoperative radiograph were systemically reviewed for the following:

- (1) The cup inclination angle, which is the angle between the plane through the opening of the acetabular cup and the horizontal inter-teardrop line [10].

Figure 4



Long leg film showing knee valgus more on the right side. The relocation of the hip was done after distal medial closing wedge osteotomy to determine the amount of bone resection. The 1-year follow-up after bilateral hip replacement.

- (2) Femoral component position.
- (3) The accuracy of restoration of the hip center [11,12].
- (4) The quality of ORIF of the osteotomy site.

The known size of the artificial femoral head was utilized to correct for magnification. The inter-tear drop line was plotted as a reference line. As described before by Ranawat, vertical line is dropped from the center of the artificial femoral head to the reference line and measured to give the vertical height of the THR. The horizontal distance is measured from the intersect of the vertical line with the reference line to the inferior point of the tear drop. On the contrary, the ideal horizontal and vertical location of the native hip center was calculated from the Pierchon index, as shown in Fig. 5 [11,12].

Cups placed 5 mm higher than the vertical distance of the native hip were considered nonanatomical. The overall accuracy of restoration of the hip center was calculated from the difference between the sum of coordinates (vertical and horizontal distances), of the ideal native hip center and that of actual THR center [13] (Fig. 5).

#### Follow-up

The minimum follow-up period was set to be 2 years. Follow-up was done during routine clinical visits. The OHS [9] was filled by patients. Clinical evaluation protocol also included clinical measurement of residual functional LLD and reporting any complication. The serial radiographs were also evaluated for the evidence of component migration, heterotopic ossification, osteolysis, subsidence, and linear polyethylene wear.

#### Statistical analysis

Categorical variables were described using numbers and percentages. Using Kolmogorov–Smirnov test, the distribution of the OHS was not found to be deviated from normality and thus was described using mean and SD. To test the improvement in the OHS and LLD from the preoperative to follow-up time, one-sample Wilcoxon signed-rank test was used. In bivariate analysis, the effect of different factors on the OHS were tested using the Mann–Whitney *U* tests. Statistical significance was defined as *P* value less than 0.05. The strength of association between age, restoration of the AHC, and the OHS was estimated using Spearman's rho rank correlation. Kruskal–Wallis test with post-hoc analysis was used to detect the difference among Crowe types II, III, and IV patients. Statistical analysis was performed with the use of MedCalc Statistical Software version 19.2.6 (MedCalc Software bv, Ostend, Belgium).

## Results

### Clinical outcome

All patients were followed up for a mean of  $3.4 \pm 2.6$  years (range, 1–11 years). None of the cases were lost to follow-up. The mean OHS improved significantly from  $21.2 \pm 6.6$  points (range, 8–38) preoperatively to  $40.9 \pm 4.8$  points (range, 28–48) in the final OHS ( $Z=4.45$ ,  $P<0.001$ , Fig. 6).

Patients were categorized according to Crowe classification. An analysis of variance – using Kruskal–Wallis test with post-hoc analysis – was done to detect the difference in the preoperative and postoperative OHS and to determine which group is different from others. We found that Crowe II has better preoperative OHS scores than the other two groups. Regarding the final OHS, both Crowe types II and III were better than Crowe type IV, and the difference was statistically significant (Table 3, Fig. 7a and b).

The functional LLD improved from a median of 3 cm (0–7 cm) preoperatively to 0 cm (0–3 cm) postoperatively ( $Z=4.3$ ,  $P<0.0001$ ). Preoperative shortening in cases that required shortening osteotomy was 6 cm (3–7 cm), whereas shortening in cases without osteotomy was 3 cm (0–4 cm) ( $U=21.5$ ,  $P=0.03$ ). All cases that required shortening were Crowe type IV dysplasia (five cases). A total of 22 (88%) hips were reconstructed within 2 cm of the other hip.

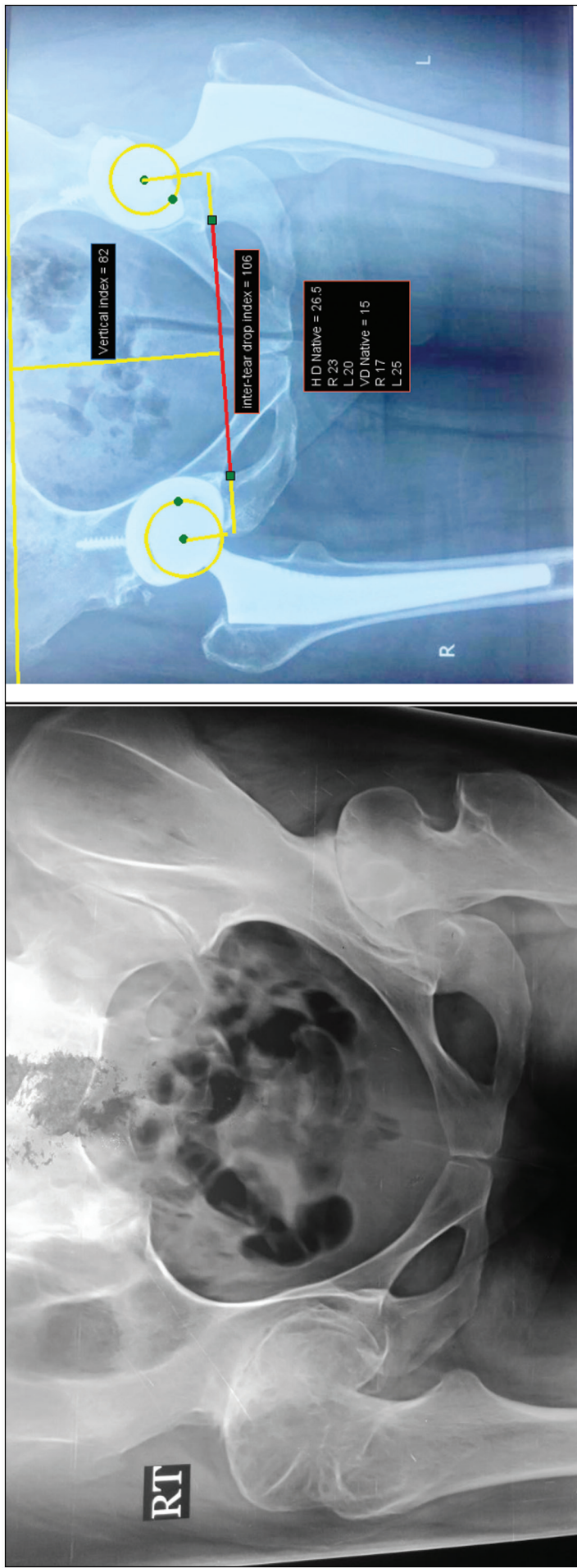
### Radiologic outcome

The mean cup abduction angle was  $44 \pm 3.5^\circ$  (confidence interval: 42.7–45.5). The median horizontal and vertical distances of the native hips were 33 mm (21–40 mm) and 14 mm (11–22 mm), respectively. The median horizontal and vertical distances for the THR were 25 mm (18–34 mm) and 14 mm (11–35 mm), respectively. The medialization of the cups resulted in a statistically significant decrease in the horizontal distance after THR ( $Z=4$ ,  $P<0.0001$ ).

Two cups were vertically placed more than 5 mm from the location of the native hip. One case had bilateral hip dysplasia with one anatomic and one HHC, as previously shown in Fig. 5. The other cup was placed 35 mm above inter-tear drop line; the vertical distance of the native hip was only 16 mm. This was done as the patient had a deficient posterior superior wall as a result of previous pelvic osteotomy (Figs 5, 8).

When categorized by Crowe classification, no difference was found regarding the ideal horizontal and vertical coordinates of the native hip center. After THR, however, cups were more medial in Crowe types III and IV as compared with Crowe type II ( $P<0.05$ ).

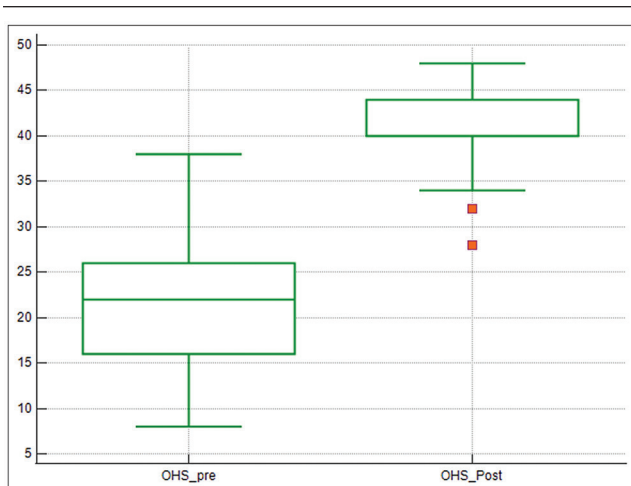
Figure 5



(a) Preoperative radiograph of a female patient with bilateral hip dysplasia (Crowe II). (b) Calculation of the accuracy of hip center restoration. The FH of 32mm diameter – on the right side – was used for calibrating the radiograph. Pierchon index of the ideal AHC was calculated as follows: the inter-teardrop distance was measured. In this case, it was 106 mm (red line). The horizontal distance of the ideal hip center is 0.3 in men and 0.25 in females of distance B. This means that the horizontal distance X of the ideal AHC of this case is  $112 \times 0.25 = 26.5$  mm. The vertical distance A between teardrop line and the line that joins the lower slope of the two sacroiliac joints is calculated. For this case, it was 82 mm. The vertical height of the ideal AHC is 0.2 in men and 0.18 in females from distance A. This means that vertical height the ideal AHC is  $82 \times 0.18 = 15$  mm. The actual AHC was 23 and 17 mm in horizontal and vertical distances, respectively, for the right hip and 20 and 25 mm, respectively, for the left hip. The vertical height of the left hip is more than 5 mm from that of the ideal hip center. This means the right hip was anatomical and the left one was high hip center. The final OHS was 48 and 40 for the right and left hips, respectively. AHC, anatomic hip center; OHS, Oxford hip score.



Figure 6



Boxplot showing the difference between pre and final OHS. OHS, Oxford hip score.

**Table 3 The comparison of the preparative and final Oxford hip score among patients categorized by Crowe classification**

	Crowe II	Crowe III	Crowe IV	Test value P value
Preoperative OHS	26 (22–38)	20 (14–30)	14 (8–26)	$H=11.94$ $P=0.002^*$
Postoperative OHS	44 (38–48)	43 (40–48)	36 (28–44)	$H=9.47$ $P=0.007^*$

H, Kruskal–Wallis test value; OHS, Oxford hip score.

\*P significant if less than 0.05.

This difference was not shown in the vertical location ( $P>0.05$ ) (Table 4).

On the final follow-up radiograph, no evidence of any cup loosening was found. All acetabular grafts showed solid union without resorption. Four osteotomies showed solid bone union. In one case, the subtrochanteric osteotomy did not heal and the long Wagner stem femoral component was loose. No other cases of femoral component loosening were observed.

#### Factors affecting the postoperative Oxford hip score

Age and sex were not found to affect the outcome ( $P>0.5$ ). The median OHS for nine patients with Crowe type II was 44 (40–46), whereas it was 40 (36–43) for the other 17 patients with Crowe types III–IV. The difference was statistically significant ( $U=2.03$ ,  $P=0.04$ ). However, the difference was not clinically significant as the MICD of OHS was five points [14].

Final OHS was not correlated to the vertical or to the horizontal differences between native and THR centers. However, adding the horizontal and vertical differences together resulted in moderate negative correlation between this value and the final OHS. The less the difference, that is, the closer the THR center to

the native center, the better the final OHS ( $R=-0.411$ ,  $P=0.03$ , Fig. 9).

#### Complications – revision

One patient developed postoperative DVT of the popliteal vein. This patient had supracondylar osteotomy, which might be a risk factor. The patient was instructed for nonweight bearing and received therapeutic dose of anticoagulant in the form of enoxaparin sodium 60 mg (Clexane 60 mg) twice until clot resolved. By the end of follow-up, there were no dislocation, deep infections, or sciatic nerve injury. All acetabular components remained stable. Two proximal femurs cracked intraoperatively and successfully treated by cerclage wires. One unrecognized intraoperative fracture of the posterior wall occurred, which healed conservatively, as mentioned before (Fig. 8).

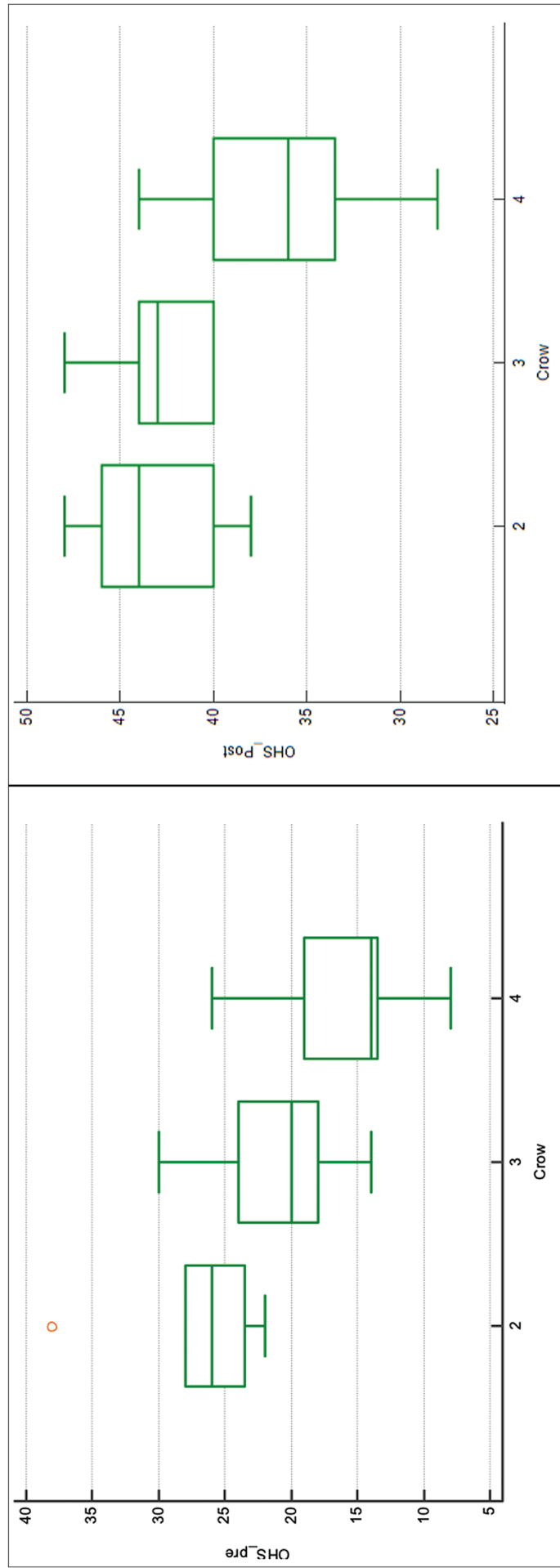
We revised one case that presented with osteotomy nonunion, tight ilio-tibial band due to excessive lengthening, and painful loose femoral component. The stem was revised from Wagner nonmodular stem to tapered fluted modular titanium stem (Revitan) (Fig. 10).

#### Discussion

In this retrospective analysis of 23 patients with 26 dysplastic hips, we were able to restore the anatomic center in all but two cases. The aim of this work then was to see the effect of anatomic center reconstruction on the functional outcome. As the mean follow-up was 3.4 years, we cannot compare our results to that of studies reported longer follow-ups. Nevertheless, we used a PROM score, which is a more sensitive tool than HHS, which was used mostly in the literature [7]. The final OHS score improved significantly from 21 to 41 points as compared with the preoperative one. The more accurate the restoration of the anatomical center, the better the function. Crowe type IV cases had worse scores in both the pre and final status, possibly owing to associated deformity and soft tissue contractures. We had to do osteotomies in five patients and to revise one loose femoral component associated with nonunited osteotomy. LLD was reduced from a median of 3–0 cm. We did not have any dislocation or nerve injuries in our series.

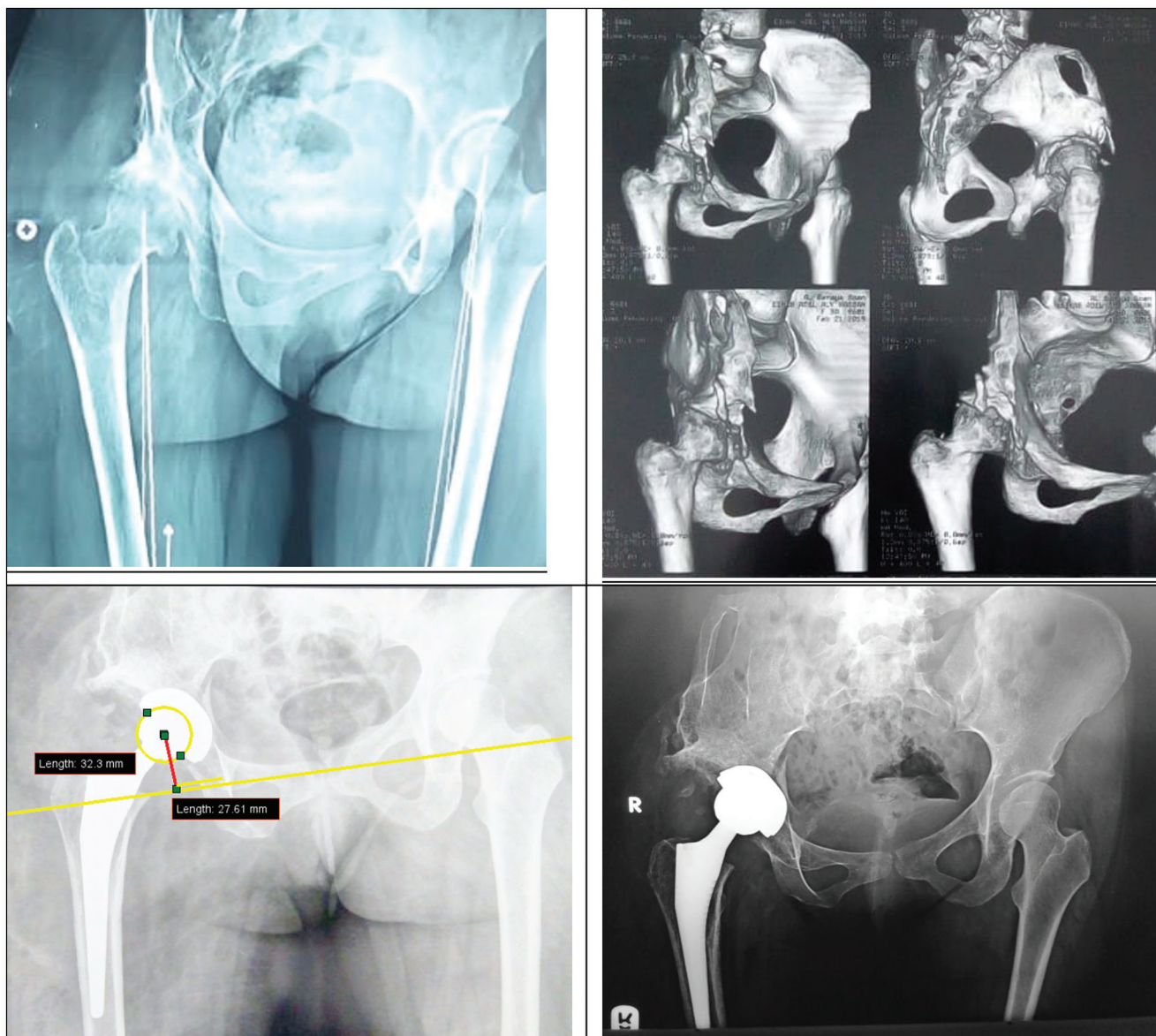
Similar to our work, Imam *et al.* [15] from Egypt performed a prospective study over 25 middle east women with Crowe IV DDH. All received cementless cup with subtrochanteric shortening femoral osteotomy and trochanteric advancement. Patients were evaluated using HHS and OHS. The mean OHS improved significantly from 17 points preoperatively

Figure 7



A boxplot showing that (a) the median preoperative OHS was higher in Crowe II as compared with other two groups. For the final OHS (b), the median values of both Crowe II and III are higher than Crowe IV group. OHS, Oxford hip score.

Figure 8



A 25-year-old woman presented with Crowe III acetabular dysplasia. The computed tomography scan showed posterior wall column deficiency as a result of pelvic osteotomy. Intraoperative medialization and higher hip center was done. The vertical distance (red line)=35 mm. A crack propagated to the posterior column during cotyloplasty was not recognized intraoperatively. The acetabular component was stable. Healing after conservative treatment is evident in the follow-up radiograph.

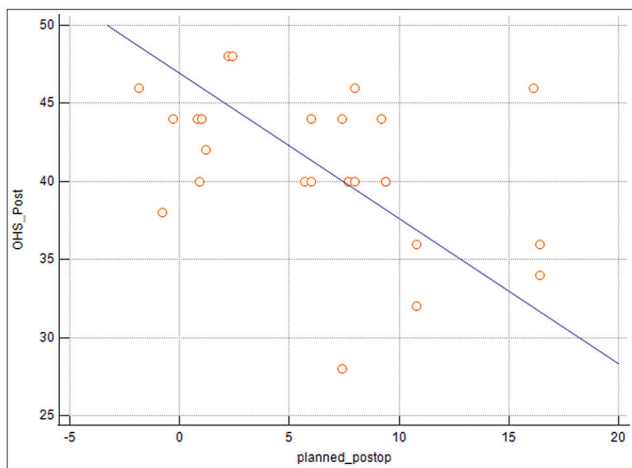
Table 4 The measurements of native and total hip replacement coordinates

	Ideal native hip center	THR center
Horizontal distance (mm) [mean (minimum–maximum)]		
Crowe II (9 cases)	34.5 (30–35.5)	29 (20–34)
Crowe III (8 cases)	28.5 (20.7–36.6)	25 (18–27)
Crowe IV (9 cases)	30 (28.8–39.9)	22 (20–24)
Test value		H=12.7
P value		P=0.002*
Vertical distance (mm) [mean (minimum–maximum)]		
Crowe II (9 cases)	14 (13.6–16.6)	14 (11–19)
Crowe III (8 cases)	14.4 (11.4–22.2)	16 (13–20)
Crowe IV (9 cases)	15.2 (12.18.8)	14 (13–35)
Test value		H=1.6
P value		P=0.4

H, Kruskal–Wallis test value; THR, total hip replacement.

\*P significant if less than 0.05.

Figure 9



Moderate negative correlation between OHS and difference between planned center of rotation and achieved center. OHS, Oxford hip score.

to 37.1 at 1 year and 38.6 points at 10 years. The mean postoperative LLD was 3 mm (0–8 mm). Two patients had dislocation after 3 months after surgery, which was managed successfully with closed reduction under anesthesia [15].

Wang *et al.* [16] performed a study on 62 Crowe type IV patients treated with cementless THR and subtrochanteric osteotomy (76 hips). They used hip dysfunction and Osteoarthritis Outcome Score and SF-12 score. Their mean follow-up period was 10 years, which is longer than the current study. As our protocol, the acetabular cup was implanted in placement of the AHC in all hips. The mean HHS significantly improved from 38.8 to 86.1 points. The mean limb length discrepancy was reduced from 4.3 to 1.0 cm. At a mean follow-up of 10 years, there were three cases of postoperative dislocation, two cases of transient nerve palsy, one case of nonunion, and four cases of intraoperative fracture. Revision surgery was performed in two patients due to isolated loosening of acetabular component and femoral stem, respectively [16].

Several other studies are available but direct comparison with our results are not possible. Some of these reports included Crowe type I patients, and most of them did not use functional PROM scores. For example, Faldini *et al.* [17] performed a cementless THR in 28 patients with DDH but included 16 Crowe I hips and used HHS.

Adequate preoperative planning emphasizes upon radiological determination of AHC, acetabular bone stock, cup position, coverage, and the site of femur osteotomy. Shi *et al.* [18] stated that digital template in

cases of hip dysplasia can poorly detect cup and stem sizes in comparison with patients without hip dysplasia. For this reason, small sized cups together with conical and modular stems should be on shelf.

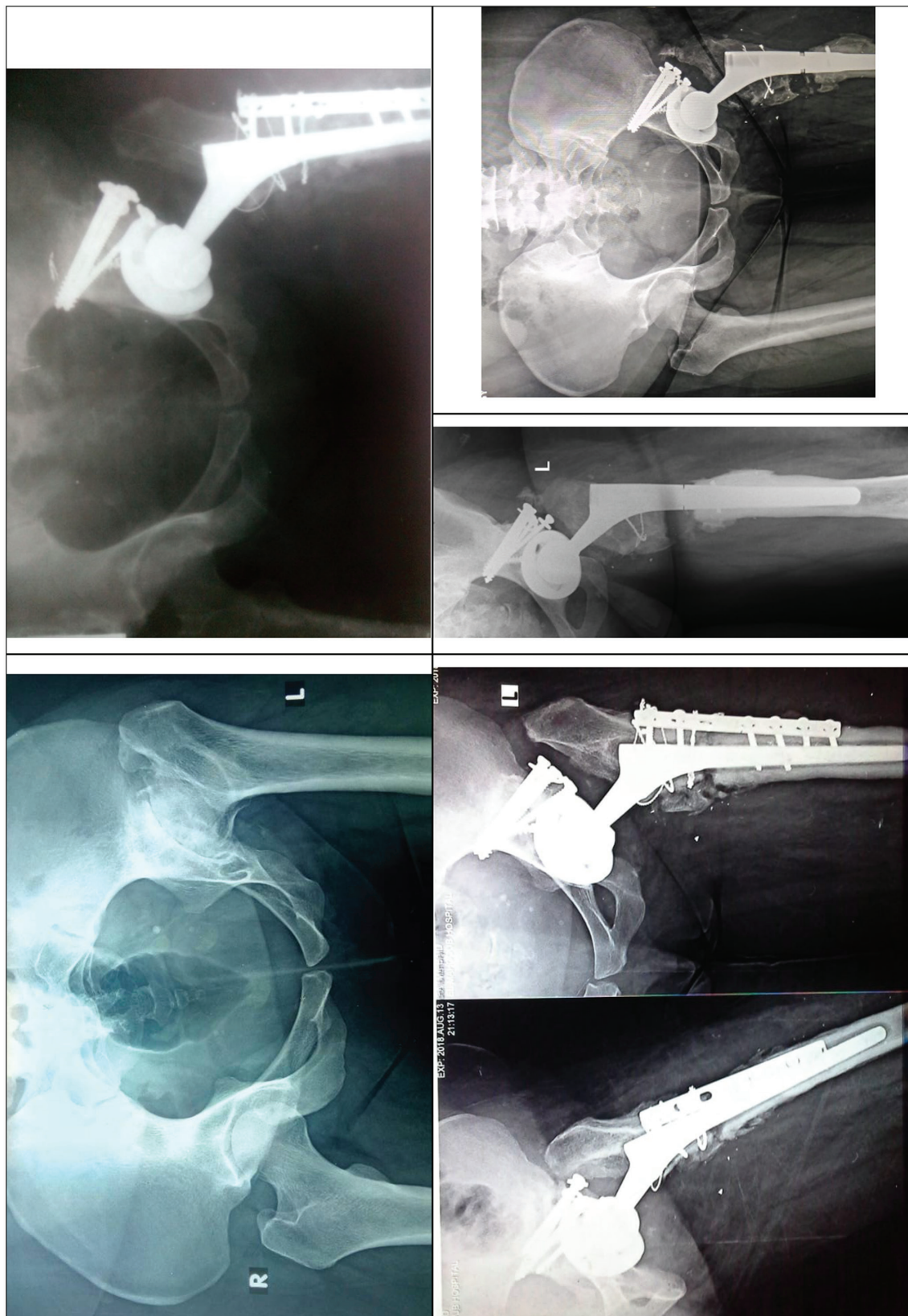
A la carte reconstruction of the hip allowed control of cup abduction, coverage, combined ante-version, and leg length. In two-thirds of our patients, the remaining defect was more than 70%. Tikhilov *et al.* [19] noted that without screw fixation, cup stability could be maintained only when the uncoverage was moderate (15–25%), whereas two-screw fixation was needed in cases of significant uncoverage (up to 35%). Percentages greater than this required supporting techniques besides screw fixation.

Medial protrusion was first described by Dunn and Hess [20] using osteotomes. Hartofilakidis *et al.* [4,21,22] later used a reamer and introduced the term cotyloplasty and reported satisfactory results of implanting cemented cups. The same technique was used with cementless shells as in Dorr *et al.* [23]. Cotyloplasty has advantages over HHC for potential better restoration of hip biomechanics, LLD, with avoidance of impingement and dislocation. In our series, for reconstructions, cotyloplasty was given priority over grafting. This allowed us to decrease the size of the needed graft, which may add to its intake and nonresorption. All cups remained stable at the final follow-up. As stated by Morsi *et al.* [24], good results can be expected when less than 50% of the acetabular component is supported by the bone graft.

Up to the best of our knowledge, there is no clear evidence about the effect of ideal placement of the THR at the AHC versus HHC and the functional outcome. According to Papachristou *et al.* [25], this may be due to the use of less sensitive clinical scores in previous reports. For this reason, we adopted OHS in this study. A lack of consensus regarding the definition of HHC is a second cause. Previous reports described 10, 15, and 30 mm from native centers as an upper limit. The highest limit was reported by Fujii *et al.* [26], who found that up to 35 mm from the tear drop will not affect the hip abductor strength, provided that an offset femoral stem is used for restoration of the abductor lever arm. One reason we routinely strive for AHC is that custom-made stems are not available at our unit.

In contrary to the report, Fujii *et al.* [26] and Bicanic *et al.* [27] found that better biomechanics is expected when the cup is placed low and medial. For every millimeter of proximal placement of the cup away from AHC, an increase of 0.1% in hip load should be expected. However, for every millimeter of medial

Figure 10



A 32-year-old woman presented with Crowe IV dysplasia of her left hip. Functional LLD was 7 cm. The postoperative radiograph of the index surgery showing placement of the cup at the AHC, roof graft, long Wagner stem, and plate osteo-synthesis of subtrochanteric osteotomy. One-year postoperative radiograph showing femoral component subsidence and osteotomy nonunion. The patient complained of pain and sense of excessive lengthening (functional LLD was 2 cm). Sciatic nerve was not affected. Infection was excluded. At 5-year follow-up, the revision was done by a tapered, fluted modular titanium stem. The stem is distally stable despite nonunion at the osteotomy site. An extra 2-cm shortening was done during the revision. AHC, anatomic hip center; LLD, leg length discrepancy.

cup placement, a decrease by 0.7% of hip load is expected. Mechanics will affect the function. This was reported by Jerosch *et al.* [28]. They found that proximal cup placement (15–35 mm) results in lower abductor strength and greater effort to maintain balance. Again, lateral hip center (5–25 mm) resulted in loss of action of tensor fascia lata. In this study, we did not find a correlation between the vertical height and the functional outcome as most of hips (24 hips) were reconstructed 5 mm within the ideal hip center, which is a stricter limit than the previously described. Horizontal distance of the actual THR from the ideal one was also not correlated to the final OHS as it may be affected by the individual anatomy of the dysplastic hip. On the contrary, a significant correlation was found between the final score and combined vertical and horizontal location of the actual THR from the ideal native one. This might be explained by the positive effect of medialization in restoring the normal hip biomechanics emphasizing the findings of Bicanic *et al.* [27].

A third reason to choose the AHC over HHC is the better adjustment of LLD. In this study, 88% of our hips were reconstructed within 2 cm of the other hip. LLD can be conceptually divided into structural and functional. The functional or apparent length is that matters to the patient as it reflects the persistence of preoperative deformity. On the contrary, most of patients can tolerate up to a cm of true shortening but never tolerate excessive lengthening. Although it might be appealing to utilize HHS as it may decrease the operative time and avoid osteotomy, we believe that the soft tissue pathology is not well addressed in this technique even with the use of special stems. Meticulous and stepwise approach described in our technique can allow better adjustment of LLD. Nawabi *et al.* [13] who report on HHC for Crowe types II and III stated that this technique is contra-indicated in Crowe IV owing to deficient bone stock in the superior acetabulum and these cases are usually presented with the highest LLD. We were fortunate not to have a single case of neurological damage. Kong *et al.* [29] recommended the use of nerve monitoring if leg lengthening was planned to avoid nerve damage. We believe that our low threshold for osteotomy in cases more than 4 cm LLD was the cause of avoiding nerve damage. Nevertheless, the deleterious effect of excessive lengthening expressed itself in terms of knee pain, stem loosening, and osteotomy nonunion in the single revision case, which was a learning curve-related factor [30].

Lastly, the choice of osteotomy site was based on the overall alignment of the lower limb. Subtrochanteric osteotomy is the work horse for hip dysplasia. Several

technically demanding techniques have been described before. The simplest is the transverse one. Koulouvaris *et al.* [31] first described the distal osteotomy to avoid compromising the proximal canal. They used custom-made stems to adapt for the deformed proximal femur. Our indication for distal osteotomy was based on the long leg film with the presence of bony valgus knee. Li *et al.* [32] described the development of structural valgus malalignment in the knee of the ipsilateral neglected DDH owing to decreased height of the lateral femoral condyle. On the contrary, Zhao *et al.* [33] stated that THR resulted in significant decrease in the valgus deformity immediately postoperative and maintained after 2 years. We are not able to comment on this finding owing to the small number of patients who underwent subtrochanteric and distal osteotomies.

This study has several limitations. First, the sample size is relatively small and the follow-up is short. This is however a single surgeon series for a relatively rare disease especially in our geographic area. Successful pediatric interventions may contribute to the lower incidence of neglected cases. We did not include Crowe type I cases as they are comparable to primary THR patients. Tamegai *et al.* [34] reported total hip arthroplasty in 220 Asian patients, but their series included 154 Crowe I hips. Crowe *et al.* [3] initially reported on 31 Crowe II–IV hips in 1970s and re-reported on 29 hips in 1990s. In their last report of 2014 [13] they reported the long-term results of only 32 hips. The short follow-up did not allow us to give a valid conclusion about the survival of the hip implants used. As a third limitation, a variety of stems were used to compensate for femoral and total offset, which may represent a possible confounder to the final results. Lastly, small number of cases banned performing a fitting regression model to determine whether the restoration of AHC is a true predictor of better outcome or the complexity of the disease predetermined this outcome.

---

## Conclusions

Restoration of anatomic center of rotation as close as possible was associated with better functional outcome. Cementless fixation was possible in all cases. Acetabular reconstruction was mandatory in two-thirds of our patients. The severity of the disease may have affected the functional outcome as Crowe IV cases were inferior to Crowe II and III in the preoperative and final functional scores. Further studies are needed to better know the results of cementless shells with combined use of cotyloplasty together with less or no graft in comparison with HHC. Femoral dysplasia is still underdiscussed in the literature.

**Financial support and sponsorship**

Nil.

**Conflicts of interest**

There are no conflicts of interest.

**References**

- 1 Perry KI, Berry DJ. Femoral CONSIDERATIONS FOR TOTAL HIP REPLACEMENT IN HIP DYSPLASIA. *Orthop Clin N Am* 2012; 43:377–386.
- 2 Dapuzzo MR, Sierra RJ. Acetabular considerations during total hip arthroplasty for hip dysplasia. *Orthop Clin N Am* 2012; 43:369–375.
- 3 Crowe JF, Mani VJ, Ranawat CS. Total hip replacement in congenital dislocation and dysplasia of the hip. *J Bone Joint Surg Am* 1979; 61:15–23.
- 4 Hartofilakidis G, Stamos K, Ioannidis T. Low friction arthroplasty for old untreated congenital dislocation of the hip. *J Bone Joint Surg Br* 1988; 70-B:182–186.
- 5 Zhu J, Fernando ND. Classifications in brief: the Hartofilakidis classification of developmental dysplasia of the hip. *Clin Orthop Relat Res* 2020; 478:189–194.
- 6 Bicanic G, Barbaric K, Bohacek I, Aljinovic A, Delimar D. Current concept in dysplastic hip arthroplasty: techniques for acetabular and femoral reconstruction. *World J Orthop* 2014; 5:412–424.
- 7 Kalairajah Y, Azurza K, Hulme C, Molloy S, Drabu KJ. Health outcome measures in the evaluation of total hip arthroplasties—a comparison between the Harris hip score and the oxford hip score. *J Arthroplasty* 2005; 20:1037–1041.
- 8 Stirling P, Viamont-Guerra MR, Strom L, Chen AF, Saffarini M, Nover L, *et al.* Does cup position at the high hip center or anatomic hip center in THA for developmental dysplasia of the hip result in better Harris hip scores and revision incidence? A systematic review. *Clin Orthop Relat Res* 2021; 479:1119–1130.
- 9 Kang S. Assessing responsiveness of the EQ-5D-3L, the Oxford Hip Score, and the Oxford Knee Score in the NHS patient-reported outcome measures. *J Orthop Surg Res* 2021; 16:18.
- 10 Jolles BM, Zangger P, Leyvraz PF. Factors predisposing to dislocation after primary total hip arthroplasty. *J Arthroplasty* 2002; 17:282–288.
- 11 Olmedo-Garcia N, Sevilla A. Comparative study of accuracy of Ranawat's and Pierchon's methods to determine hip centre with informatics tools. *HIP Int* 2010; 20(7\_suppl):48–51.
- 12 Pierchon F, Migaud H, Duquenooy A, Fontaine C. Radiologic evaluation of the rotation center of the hip. *Rev Chir Orthop Reparatrice Appar Mot* 1993; 79:281–284.
- 13 Nawabi DH, Meftah M, Nam D, Ranawat AS, Ranawat CS. Durable fixation achieved with medialized, high hip center cementless THAs for Crowe II and III dysplasia. *Clin Orthop Relat Res* 2014; 472:630–636.
- 14 Beard DJ, Harris K, Dawson J, Doll H, Murray DW, Carr AJ, *et al.* Meaningful changes for the Oxford hip and knee scores after joint replacement surgery. *J Clin Epidemiol* 2015; 68:73–79.
- 15 Imam MA, Fathalla I, Holton J, Nabil M, Kashif F. Cementless total hip replacement for the management of severe developmental dysplasia of the hip in the middle eastern population: a prospective analysis. *Front Surg* 2016; 3:31.
- 16 Wang D, Li LL, Wang HY, Pei FX, Zhou ZK. Long-term results of cementless total hip arthroplasty with subtrochanteric shortening osteotomy in Crowe type IV developmental dysplasia. *J Arthroplasty* 2017; 32:1211–1219.
- 17 Faldini C, Miscione MT, Chehrassan M, Aciri F, Pungetti C, D'Amato M, *et al.* Congenital hip dysplasia treated by total hip arthroplasty using cementless tapered stem in patients younger than 50 years old: results after 12-years follow-up. *J Orthop Traumatol* 2011; 12:213–218.
- 18 Shi XT, Li CF, Cheng CM, Feng CY, Li SX, Liu JG. Preoperative planning for total hip arthroplasty for neglected developmental dysplasia of the hip. *Orthop Surg* 2019; 11:348–355.
- 19 Tikhilov R, Shubnyakov I, Burns S, Shabrov N, Kuzin A, Mazurenko A, *et al.* Experimental study of the installation acetabular component with uncoverage in arthroplasty patients with severe developmental hip dysplasia. *Int Orthop* 2016; 40:1595–1599.
- 20 Dunn HK, Hess WE. Total hip reconstruction in chronically dislocated hips. *J Bone Joint Surg Am* 1976; 58:838–845.
- 21 Hartofilakidis G, Karachalios T. Total hip arthroplasty for congenital hip disease. *J Bone Joint Surg Am* 2004; 86:242–250.
- 22 Hartofilakidis G, Georgiades G, Babis GC, Yiannakopoulos CK. Evaluation of two surgical techniques for acetabular reconstruction in total hip replacement for congenital hip disease. Results after a minimum ten-year follow-up. *Bone Joint J* 2008; 90–724.
- 23 Dorr LD, Tawakkol S, Moorthy M, Long W, Wan Z. Medial Protrusion technique for placement of a porous-coated, hemispherical acetabular component without cement in a total hip arthroplasty in patients who have acetabular dysplasia. *J Bone Joint Surg* 1999; 81:83–92.
- 24 Morsi E, Garbus D, Gross AE. Total hip arthroplasty with shelf grafts using uncemented cups. *J Arthroplasty* 1996; 11:81–85.
- 25 Papachristou GC, Pappa E, Chytas D, Masouros PT, Nikolaou VS. Total hip replacement in developmental hip dysplasia: a narrative review. *Cureus* 2021; 13:e14763.
- 26 Fujii M, Nakamura T, Hara T, Nakashima Y. Is Ranawat triangle method accurate in estimating hip joint center in Japanese population? *J Orthop Sci* 2021; 26:219–224.
- 27 Bicanic G, Delimar D, Delimar M, Pecina M. Influence of the acetabular cup position on hip load during arthroplasty in hip dysplasia. *Int Orthop* 2009; 33:397–402.
- 28 Jerosch J, Steinbeck J, Stechmann J, Gth V. Influence of a high hip center on abductor muscle function. *Arch Orthop Trauma Surg* 1997; 116:385–389.
- 29 Kong X, Chai W, Chen J, Yan C, Shi L, Wang Y. Intraoperative monitoring of the femoral and sciatic nerves in total hip arthroplasty with high-riding developmental dysplasia. *Bone Joint J* 2019; 101-B:1438–1446.
- 30 Hou W, Lu Y, Xu P. Is high hip center technique an acceptable choice for total hip arthroplasty of the developmental dysplasia of the hip? *Ann Joint* 2017; 2:55–55.
- 31 Koulouvaris P, Stafylas K, Sculco T, Xenakis T. Distal femoral shortening in total hip arthroplasty for complex primary hip reconstruction. a new surgical technique. *J Arthroplasty* 2008; 23:992–998.
- 32 Li Q, Kadhim M, Zhang L, Cheng X, Zhao Q, Li L. Knee joint changes in patients with neglected developmental hip dysplasia: a prospective case-control study. *Knee* 2014; 21:1072–1076.
- 33 Zhao HY, Kang PD, Shi XJ, Zhou ZK, Yang J, Shen B, *et al.* Effects of total hip arthroplasty on axial alignment of the lower limb in patients with unilateral developmental hip dysplasia (Crowe type IV). *J Arthroplasty* 2019; 34:2406–2414.
- 34 Tamegai H, Otani T, Fujii H, Kawaguchi Y, Hayama T, Marumo K. A modified S-ROM stem in primary total hip arthroplasty for developmental dysplasia of the hip. *J Arthroplasty* 2013; 28:1741–1745.