

Intra Articular Calcaneal Fracture with Subtalar Joint Depression: Minimally Invasive Sinus Tarsi Approach for Open Reduction and Internal Fixation

Essayed Mahmoud Bayomy, Emad Sanad Hussein, Moustafa Mohamed Saad

Department of Orthopedics and Trauma Surgery,
Faculty of Medicine, Benha University, 13511,
Qalyubia, Egypt

Correspondence to Moustafa Mohamed Saad,
Department of Orthopedics and Trauma Surgery,
Faculty of Medicine, Benha University, 13511,
Qalyubia, Egypt.

Phone No: +201005027506,
e-mail: Dr_safsaf_2009@yahoo.com

Received: 04-Feb-2024

Accepted: 09-Mar-2024

Published: 24-Jul-2024

The Egyptian Orthopaedic Journal 2024,
59:191–197

Background

Numerous studies have demonstrated that fractures of the calcaneum, which account for a significant fraction of major tarsal bone fractures, are linked to severe and protracted impairment. This study aimed to evaluate minimally invasive sinus tarsi approach (STA) for open reduction and internal fixation of calcaneal fracture with joint depression to clarify and identify its benefits and drawbacks.

Methods

This prospective cohort research was performed on all adult cases with a displaced intra articular calcaneus fracture who were admitted to our institution. Patients aged of 14 to 60 years with unilateral, isolated, uncomplicated fractures were included.

Results

Our study conducted on 31 patients with 34 fractures with a mean age of 34 years (type II 47% and type III 53%). The mean duration of follow-up was 20.45 months, the mean American orthopaedic foot and ankle society was 91.38% and the mean Maryland foot score was 94.79%. Pain and discomfort were reported by 14 patients in regards to their foot. Seven individuals were found to have soreness at the locations of the posterior screws. The remaining 7 cases were identified as having complex regional pain syndrome, which is characterised by persistent foot pain, particularly when bearing weight. Sural nerve dystrophy was the only patient's complaint. One patient exhibited slight toe clawing.

Conclusion

The STA is a minimally invasive intervention utilised in the treatment of calcaneal fractures. It enables anatomic reduction of articular surfaces and allows for a clear view of the fracture.

Keywords:

Fracture calcaneus, Sanders, Sinus tarsi, Intra-articular fractures, Less invasive

Egypt Orthop J 2024, 59:191–197

© 2024 The Egyptian Orthopaedic Journal

1110-1148

Introduction

Numerous studies have demonstrated that fractures of the calcaneum, which account for a significant fraction of major tarsal bone fractures, are linked to severe and protracted impairment. Intraarticular calcaneum fractures elicit 75% of calcaneal fractures and 60% of tarsal injuries. The majority of these fractures are displaced intraarticular fractures involving the subtalar joint, which is the posterior articular facet. Although clinical data supporting surgical intervention for some cases is few, accounts of adverse outcomes and prolonged complications are prevalent [1].

The treatment trajectory of this fracture has been characterised by phases of fervent advocacy for surgical intervention, succeeded by phases of steadfast endorsement of restricted therapeutic alternatives. According to the research, non-operative management has generally resulted in unsatisfactory outcomes. The main factor behind poor outcomes

is the loss of position and inability to maintain reduction, which can result in a muscular imbalance, a reduction in subtalar joint mobility, widening of the hind foot, secondary osteoarthritis, or peroneal tendons' impingement. The ideal method for treating these fractures has historically generated a great deal of discussion [2].

The approach that has been utilised most frequently, open reduction and internal fixation by lateral extensile, has certain disadvantages. Gissane invented the most well-known minimally invasive technique for treating tongue type fractures; Westhues improved it; and Essex-Lopresti spreaded it [3].

This is an open access journal, and articles are distributed under the terms of the Creative Commons Attribution-NonCommercial-ShareAlike 4.0 License, which allows others to remix, tweak, and build upon the work non-commercially, as long as appropriate credit is given and the new creations are licensed under the identical terms.

We have treated complicated fractures with a less intrusive method, which lowers the likelihood of complications. Importantly, the main goals in such cases are to avoid varus or valgus deformity, decompress the retro-peroneal space, reconcile the posterior facet and subtalar joint in a congruent manner, restore the calcaneus's height (Bohler's angle), and reinstate the calcaneocuboid joint's integrity.

This study aimed to evaluate minimally invasive sinus tarsi approach (STA) for open reduction and internal fixation of calcaneal fracture with joint depression to clarify and identify its benefits and drawbacks.

Materials and Methods

This prospective research was performed on all adult cases with a displaced intra articular calcaneus fracture were admitted to our institution between December 2017 and December 2021.

The study was done after approval of ethical committee of Orthopaedic Surgery, Benha University, Egypt. Written informed consent was acquired from every patient.

Patients aged of 14 to 60 years, patients with intra-articular fractures of the calcaneus whether tongue type or Essex-Lopresti joint depression type. According to Sanders' classification, only type II and III fractures were included.

Individuals who have had intra-articular calcaneus fractures of Sanders' type I and type IV and extra-articular and open fractures were also excluded.

All patients underwent full history taking, clinical assessment and laboratory investigations.

Patients' evaluation

Fitness for surgery

Surgical suitability of the patients was determined by a review of their medical history, clinical examination, and laboratory tests. The patients were examined for any chest comorbidities as the patients were operated upon in prone position. Any chest problems were addressed before admission to surgery.

Musculoskeletal evaluation

Each case had a comprehensive preoperative history taking. Both preoperatively and postoperatively, clinical and radiological assessments were conducted on the patients' feet.

Clinical evaluation

The patients' skin condition was examined. All Patients were treated by leg elevation and were given medical treatment at their initial presentation. Patients were not admitted for surgery except after having positive wrinkle test (with the foot everted and the ankle dorsiflexed, before conducting a lateral exposure on the fractured calcaneus, the skin over the lateral face of the bone should be wrinkly and devoid of pitting edoema). A positive test is confirmed when the patient exhibits skin wrinkling and absence of pitting oedema; this indicates that the soft tissues have sufficiently healed to warrant a risk-free operational intervention [4].

Radiological evaluation:

Before surgery, plain X-rays and CT scans were utilised to assess all patients, classify their fractures and plan the operation.

Standard plain films and CT scans were used for radiographic evaluation. Following that, Sander's classification 5 was applied to all fractures. (Table 1)

Surgical technique

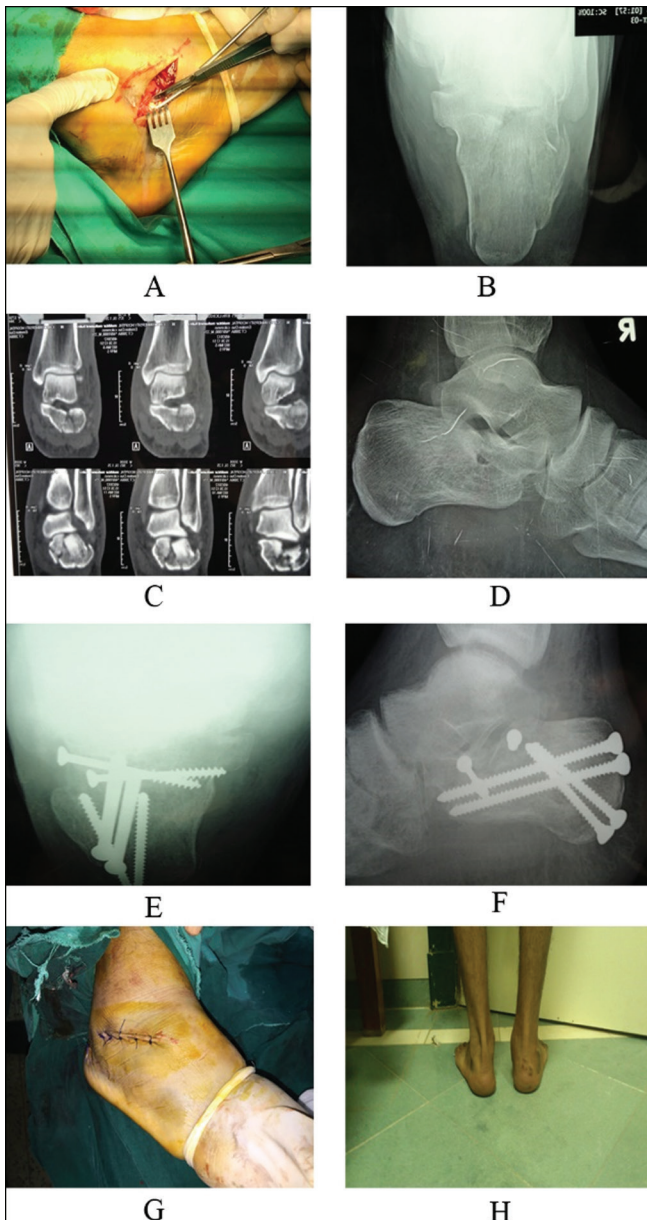
The injured foot of each patient was hung from the operating table's edge in the prone position, and tourniquets were applied. A 4-5 cm incision was made using image intensifier directly above the sinus tarsi, beginning at the lateral malleolus and moving towards the calcaneocuboid joint. Dissection was done cautiously to avoid damaging the calcanofibular ligament (CFL)

Table 1: Showing the demographics, side affected, scores of the patients according to Essex-Lopresti, Sanders, AOFAS ankle/hindfoot score, Maryland foot score.

		n=33
Age	Mean	34.25
	Range	14-60
Sex	Males	23
	Females	8
Side	Right	17
	Left	11
	both	3
Essex-Lopresti	Tongue type	2
	Joint depression type	32
Sanders	II	16
	III	18
AOFAS ankle/hindfoot score	Excellent (90-100)	24 (72.72 %)
	Good (80-90)	7 (21.21%)
	Fair (70-80)	1 (3.03%)
	Poor (less than 70)	1 (3.03 %)
Maryland foot score	Excellent (90- 100)	29 (87.88 %)
	Good (75-89)	3 (9.09 %)
	Fair (50-75)	1 (3.03 %)
	Poor (less than 50)	0 (0 %)

AOFAS: American Orthopaedic Foot & Ankle Society score

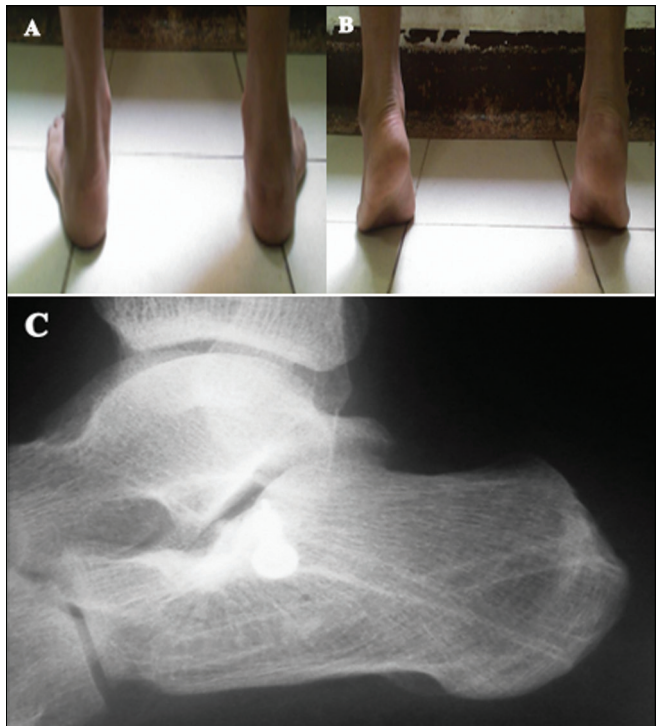
Figure 1



Case 1: A 22 years old male patient with Sanders' type II-B, joint depression fracture of the right calcaneus. There were no associated injuries. The patient was presented with severe edema and bad skin condition. Conservative measures in the form of leg elevation, posterior slab and medical treatment were given. The patient was operated upon 21 days following the trauma after improvement of the edema and skin condition. B and D: radiographs showing lateral view and Harris axial view of the calcaneus. C: CT showing coronal cuts of the calcaneus. E and F: radiographs showing postoperative lateral view of the calcaneus and Harris axial view of the calcaneus.

or the sural nerve (SN), as well as the peroneal tendons (Figure 1a). Exposure of the anterior process, the Gissane angle, and the posterior facet. Utilizing a blunt implement, the fragment was transferred medially to its anatomical location in respect to the more stable sustentacular fragment. Using fluoroscopy, K-wires were used for the preliminary fixation and the reduction was evaluated (Figure 2a). Once the portion of the

Figure 2



showing the patient (A) standing, (B) tip-toeing in the last follow-up, and (C) radiograph showing lateral view of the calcaneus after screw removal in the last follow-up.

strong sustentaculum was reduced to a sufficient size, the final fixation was achieved by employing one or two partly threaded 4.0-mm screws. Later, a 5.0-mm Schanz pin was introduced into the calcaneal tuberosity in a medial to lateral direction. Following distraction, the calcaneal length, breadth, and height were restored by manually correcting the varus malalignment, which was validated fluoroscopically. Following the placement of two parallel 3.2-mm drill bits in postero-anteriorly direction towards the calcaneocuboid joint through two independent minor skin incisions on either side of the tendo-Achilles, two 4.5-mm positioning screws were used to maintain the calcaneal length and alignment. In order to preserve the calcaneal height and raft the elevated posterior facet, two additional 4.5-mm screws were placed (Figure 1b, c, d, e, f). The wound was managed with many layers of dressing. A compression bandage was used to bandage the patients for the initial two weeks. Two weeks later, upon the patient's return, an assessment was conducted on the wound, the sutures were removed, and a temporary leg cast was applied. Complete weight-bearing was achieved at ten weeks, after the introduction of partial weight-bearing at six weeks. (Figure 1 g, h).

Postoperative care

The plan of postoperative care

Postoperative X-rays are requested immediately after surgery. New follow-up X-rays are ordered.

Assessment of the patient by Maryland score and American Orthopaedics Foot and Ankle Society (AOFAS) score is done. At the sixth month postoperatively, follow-up radiographs and assessment of the patient's Maryland score and AOFAS score are calculated. Assessment for the need of removal of hardware is done after the sixth month.

Assessment of the patients in the postoperative care

All the patients were assessed radiologically and clinically.

Clinical evaluation:

The patients were evaluated by AOFAS ankle/hindfoot score and Maryland scores.

The AOFAS ankle/hindfoot score:

It is a scoring system of 100 points. The assessment is solely clinical in nature, devoid of any radiologic components. Clinical variables, both subjective and objective, comprised the scale. The clinical results were graded as 90 - 100 excellent, 80-90 good, 70-80 fair, less than 70 poor [5]. As well as the presence of any recorded complications.

Statistical analysis

All statistical calculations were done using computer programs SPSS (Statistical Package for the Social Science; SPSS Inc., ARMONK, NY, USA) version 15 for Microsoft Windows. Quantitative variables were displayed as mean \pm standard deviation (\pm SD), median and range and the comparison between groups was performed by Student *t* test for independent test, while qualitative variables were displayed as frequencies (number of cases) and percentages when appropriate and the analysis was performed by Chi square (χ^2) test or Exact test when the expected frequency was $<$ 5. Pearson moment correlation equation was used for determining the correlation between various variables. A two-tailed *p* values $<$ 0.05 was deemed statistically significant.

Results

Our study included 31 cases with a mean age of 34 years (Table 1). The mean duration between injury and surgery was 8.5 days (range one–18 days). The mean duration of follow-up was 20.45 months (range 6–45 months). Congruity was restored to the subtalar joint in every case, and anatomical reduction of the intra-articular fragments and satisfactory reduction of the fracture were achieved. This reduction entailed the restoration of the calcaneal length, breadth, and height. (Figure 1) No occurrences of hardware displacement or reduction failure were reported. No cases experienced

subtalar arthritis that was severe enough to require surgery, there was just one instance of a superficial infection of the wound related to the screws removal throughout the follow-up period. Repeated dressing changes and antibiotics were administered to the patient. "Pain and discomfort" were reported by 14 patients in regard to their foot. Seven cases reported experiencing discomfort at the site of the posterior screws subsequent to further assessment; these concerns were successfully resolved with the removal of the screws. Table 1 provide a summary of the overall outcomes based on AOFAS ankle/hindfoot and Maryland scores. The mean AOFAS and MFS, respectively, were 91.38 and 94.79. This study includes 30 individuals with 33 fractures. All of the patients had their calcaneum aligned normally, with their heel height and width restored, according to clinical and radiological standards, and Their joint surface was restored adequately with $<$ 2mm incongruity. The average follow-up duration was 20.9 months on average (SD:12.22), ranging from 6 to 45 months. The average duration between the injury and the surgery was 8.23 days (SD: 5.18), with a range of 0 to 21 days. The AOFAS ankle/ hindfoot score at the last follow up ranged between 63 and 100 with a mean of 91.73 points (SD \pm 7.26). The Maryland foot score ranged between 67 and 100 with a mean of 95.09 (SD \pm 6.72). A significant correlation was reported between the AOFAS ankle/hindfoot score (Pearson correlation -0.477, *p*=0.008) and Maryland foot score (Pearson correlation -0.369, *p*=0.045) and the duration between the trauma and procedure. Both scores were found to be directly proportional to age and inversely proportional to the follow up duration, but these correlations were not statistically significant.

Table 2 display the relationship between score and sex, concomitant injuries, Sanders' classification, and Essex-Lopresti classification. The statistical significance of any of these relationships was not determined. One episode of superficial infection of wound with the screws removal occurred during the observation period. Repeated dressing changes and antibiotics were administered to the patient. "Pain and discomfort" were reported by 14 patients in regard to their foot. The posterior screw sites of seven cases were identified to have caused soreness. Their complaints were alleviated by removal after additional evaluation. Complicated regional pain syndrome (CRPS) was found in the seven remaining individuals, which is characterised by persistent foot pain, particularly when bearing weight. (Table 3) Both clinical and analytical tests revealed no signs of illness. Both medical care and physiotherapy were used to treat such patients. SN dystrophy was the only patient's complaint, and it

Table 2: showing the relation of AOFAS ankle / hindfoot score and Maryland foot score to sex, associated injuries, Sanders' classification and Essex-Lopresti classification

AOFAS ankle / hindfoot score		Number	Mean	Standard deviation	Range (AOFAS score)	Median	Test	p-value
Sex	Male	23	91.57	8.47	63 to 100	92	T test	0.86
	Female	7	92.14	3.85	87 to 97	92		
Associated injuries	No	23	92.58	5.54	77 to 100	92	T test	0.21
	Yes	7	88.17	13.20	63 to 100	91		
Sander's classification	Type II	15	91.73	6.341	77 to 100	92	T test	1.00
	Type III	18	691.72	8.137	63 to 100	92		
Essex-Loresti classification	Joint depression type	31	91.68	7.50	63 to 100	92	T test	0.88
	Tongue type	2	92.50	0.707	92 to 93	92.5		

Maryland foot score		Number	Mean	Standard deviation	Range (AOFAS score)	Median	Test	p-value
Sex	Male	23	95.26	7.52	67 to 100	97	T test	0.86
	Female	7	94.71	4.92	88 to 100	94		
Associated injuries	No	23	96.08	4.59	83 to 100	97	T test	0.40
	Yes	7	91.33	12.64	67 to 100	96		
Sander's classification	Type II	15	95.40	5.221	83 to 100	97	T test	0.81
	Type III	18	94.83	7.891	67 to 100	96		
Essex-Loresti classification	Joint depression type	31	94.97	6.87	67 to 100	95	T test	0.69
	Tongue type	2	97.00	4.243	94 to 100	97		

AOFAS: American Orthopaedic Foot & Ankle Society score

Table 3: showing complications

Complication	Frequency (%)
Wound infection	1 (3 %)
Sural nerve dysthesia	1 (3 %)
CRPS	7 (21.2 %)
Tenderness at screw site	7 (21.2 %)
Loss of reduction	0 (0 %)
Later subtalar arthrodesis	0 (0 %)
Mild claw toes	1 (3 %)

CRPS: Complex regional pain syndrome

was treated conservatively and resolved in four months. One patient exhibited slight toe clawing, but no therapy was administered because the patient's condition was neither cosmetically unappealing nor functionally problematic. No instances required subtalar arthrodesis later on and no cases were complicated by loss of reduction.

Discussion

Numerous surgical treatment modalities have been documented, including medial, lateral, and a combination of the two [6]. For the surgical treatment of intra-articular calcaneal fractures, several fixation methods have been implemented, including H cervical plates, Kirschner wires, and 3.5 mm reconstruction plates [7].

Numerous publications have favoured the lateral plate fixation extended lateral L-type method. 60% to 85%

of the instances had good to excellent results [8,9]. On the other hand, complications with skin healing are inherent in this method because to its extensive nature. The traumatic devascularization of the central and anterior portion of the lateral wall is exacerbated by this, given that vessels entering at this point contribute to 45% of the calcaneal vascularity [10].

The incidence of general complications varies between zero and 33%, with wound complications accounting for 32 %, infections for 32%, and SN damage and CRPS for 10% [11]. Within the scope of this investigation, both the incidence of infection and overall wound complications were 3% each. The incidence of SN injury was 3% and the incidence of CRPS was 21.2%. All these complications were conservatively managed.

The extensile lateral approach is the surgical method employed most commonly for the treatment of intra-articular calcaneal fractures. It enables a comprehensive visualisation of the calcaneus and anatomical reduction of the subtalar joint. A significant probability of wound complications, however, is its principal drawback [12]. Damage to the lateral calcaneal artery (LCA) at the site of the vertical incision results in ischemia and necrosis of the lateral calcaneal flap [13]. Numerous minimally invasive and percutaneous techniques were created to minimize the likelihood of wound complications [14].

The fundamental drawback of percutaneous procedures is their restricted exposure, which makes it harder to accurately reduce the articular surface and increases the reliance on intraoperative fluoroscopy for this purpose [15]. Palmer *et al.* [16] delineated an effective open reduction technique for calcaneal fractures via the sinus tarsi using a straight lateral approach. Furthermore, a 2008 research by Weber *et al.* [17] compared 24 participants to a comparable group of patients who were treated using the usual extensile lateral method. This study introduced a restricted lateral approach for percutaneous fixation and open reduction of calcaneus fractures. Following an average of 31 months of follow-up, all cases in both groups had a correct reduction with calcaneal heel width and height restoration. However, they found that the STA resulted in much shorter operating times and fewer wound problems.

We used the method outlined by Weber *et al.* [17] in our investigation. A few minor adjustments. In addition, a reduction in the articular fracture was achieved in our study prior to restoring the height and breadth of the calcaneus with manual traction in the absence of distractor usage. It was our belief that performing surgical procedures on all patients in the prone position as opposed to the lateral posture enabled a more straightforward and enhanced assessment of the posterior facet when employing the Harris axial view. In addition, four 4.5-mm positioning screws were employed instead of 3.5-mm screws due to our belief that the larger diameter of these screws enables superior defect filling (4mm more) without inflicting any damage.

The average AOFAS score in our study was 91.38, and 94% of the participants had outstanding to good results. Our findings revealed that the scores were greater than those provided by Weber *et al.* [17] in which 84% of participants achieved excellent to good outcomes, with a mean AOFAS score of 87.2. Additionally, in our study, the average MFS was 94.79%, and 97% of the individuals had exceptional outcomes.

In 1998, Tornetta *et al.* [18] reintroduced the Essex-Lopresti procedure, which was previously utilised to percutaneously repair Sanders iic fractures and tongue-type fractures. Their MFS functional outcomes were outstanding in 55% of cases and good in 32% of cases [19]. According to Gavlik *et al.*, [20] according to 18 separate studies that utilised the Creighton-Nebraska Health Foundation Assessment Score to evaluate cases involving percutaneous k-wire fixation, the average AOFAS and MFS scores for 15 patients who underwent percutaneous arthroscopic assisted

treatment and had Sanders type II fractures were 93.7 and 95.8, respectively. The average follow-up score provided was 83.919, and 85% of another study's participants saw excellent to good results.

Tomesen *et al.* [21] utilized a method comparable to that described by Forgon [22] at a mean follow-up duration of 66 months. Their mean MFS and AOFAS scores were 86 and 84, respectively. All the research described above, as well as our investigation, confirmed that displaced intraarticular calcaneal fractures can be successfully treated with limited open and percutaneous techniques, with satisfactory results.

At first, we held the belief that the restricted open strategy would yield greater benefits for Sanders type II as opposed to type III, due to the inability of the limited approach to adequately expose the centre fragment. Additionally, we pre-summated that screw fixation would offer comparatively less support for fractures consisting of three parts compared to two parts. This was untrue because we nearly equalized the mean MFS and AOFAS for both types and found no statistically significant differences between the two scoring systems when comparing both fractures. When talking about calcaneal fracture care, the most unwelcome complication by far is the overall wound complication rate. Only one postoperative superficial wound infection occurred in our study. 19 247 patients were treated in a different trial by Stulik *et al.* [23] using a minimally invasive technique and percutaneous k-wires fixation. They reported a rate of 8.7% for total wound complications, of which 1.7% were deep infections. In their analysis of 107 cases of calcaneal fractures mended with a single or multiple pins using the sinus tarsi method, Ebraheim *et al.* [24] examined 107 cases. Their 8.5% wound infection rate. In calcaneal fractures, posterior scar pain above the screw heads has been observed with every percutaneous fixation technique. This has led to the usage of headless or bioabsorbable screws as an alternative form of fixation [25].

Our strengths include the usage of the same preoperative assessment, operative method, the postoperative follow up and physiotherapy program for all patients.

Conclusion

Calcaneal fractures can be fixed using a less intrusive technique called the STA. It enables anatomic reduction of articular surfaces and allows for a clear view of the fracture. Additionally, it blatantly avoids the significant wound complication issues connected to the conventional extensile lateral technique. Treatment

for displaced intra-articular calcaneal fractures can include this.

We recommended Further studies on this approach and method of fixation should be conducted. The studies should include the patients with isolated unilateral fractures of the calcaneus to eliminate any confounders that can affect the AOFAS ankle/hindfoot score and Maryland score. Other studies should include Sanders' type IV patients to assess effect of the usage of the concept of minimally invasive osteosynthesis on the prognosis of these fracture.

The postoperative care can be modified to deal with this problem. The patient can be put in compression bandage for a longer time during the postoperative period.

Acknowledgements

There is none to be declared.

Financial support and sponsorship

This research did not receive any specific grant from funding agencies in the public, commercial, or not-for-profit sectors.

Conflict of interest

There is no conflict of interest.

Availability of data and materials

Available when needed.

Author contribution

1. Moustafa Mohamed Saad MD, (Contribution: Research idea, Study plan, Collection of scientific material, surgical intervention, Database creation, Research writing, performed measurements, manuscript preparation,)
2. Emad Sanad Hussein, MD (Contribution: study design, manuscript preparation, surgical intervention, Database creation, Research writing)
3. Essayed Mahmoud Bayomy, MD (Contribution: study design, manuscript preparation, surgical intervention, Database creation, Research writing)

References

- 1 Galluzzo M, Greco F, Pietragalla M, De Renzis A, Carbone M, Zappia M, *et al.* Calcaneal fractures: radiological and CT evaluation and classification systems. *Acta Biomed.* 2018;89:138-50. doi: 10.23750/abm.v89i1-S.7017
- 2 Yang Y, Zhao H, Zhou J, Yu G. Treatment of displaced intraarticular calcaneal fractures with or without bone grafts: A systematic review of the literature. *Indian J Orthop.* 2012;46:130-7. doi: 10.4103/0019-5413.93672
- 3 McGlenn EP, Sebastin SJ, Chung KC. A historical perspective on the Essex-Lopresti injury. *J Hand Surg Am.* 2013;38:1599-606. doi: 10.1016/j.jhsa.2013.04.031
- 4 Sanders R. Intra-articular fractures of the calcaneus: present state of the art. *J Orthop Trauma.* 1992;6:252-65. doi: 10.1097/00005131-199206000-00022
- 5 Lee BH, Fang C, Kunnasegaran R, Thevendran G. Tibiotalocalcaneal arthrodesis with the hindfoot arthrodesis nail: A prospective consecutive series from a single institution. *J Foot Ankle Surg.* 2018;57:23-30. doi: 10.1053/j.jfas.2017.05.041
- 6 Bernasconi A, Iorio P, Ghani Y, Argyropoulos M, Patel S, Barg A, *et al.* Use of intramedullary locking nail for displaced intraarticular fractures of the calcaneus: what is the evidence? *Arch Orthop Trauma Surg.* 2022;142:1911-22. doi: 10.1007/s00402-021-03944-7
- 7 Wei N, Yuwen P, Liu W, Zhu Y, Chang W, Feng C, *et al.* Operative versus nonoperative treatment of displaced intra-articular calcaneal fractures: A meta-analysis of current evidence base. *Medicine (Baltimore).* 2017;96:90-7. doi: 10.1097/md.00000000000009027
- 8 Park CH, Lee DY. Surgical treatment of sanders type 2 calcaneal fractures using a sinus tarsi approach. *Indian J Orthop.* 2017;51:461-7. doi: 10.4103/ortho.IJOrtho_143_16
- 9 Khurana A, Dhillon MS. Surgical treatment of sanders type 2 calcaneal fractures using a sinus tarsi approach. *Indian J Orthop.* 2018;52:209-10. doi: 10.4103/ortho.IJOrtho_484_17
- 10 Lakstein D, Bermant A, Shoihetman E, Hendel D, Feldbrin Z. The Posterolateral Approach for Calcaneal Fractures. *Indian J Orthop.* 2018;52:239-43. doi: 10.4103/ortho.IJOrtho_545_16
- 11 Su J, Cao X. Risk factors of wound infection after open reduction and internal fixation of calcaneal fractures. *Medicine (Baltimore).* 2017;96:84-9. doi: 10.1097/md.00000000000008411
- 12 Backes M, Schepers T, Beerekamp MS, Luitse JS, Goslings JC, Schep NW. Wound infections following open reduction and internal fixation of calcaneal fractures with an extended lateral approach. *Int Orthop.* 2014;38:767-73. doi: 10.1007/s00264-013-2181-1
- 13 Liu Y, Cai P, Cheng L, Li Y. Local random pattern flap coverage for implant exposure following open reduction internal fixation via extensile lateral approach to the calcaneus. *BMC Musculoskelet Disord.* 2021;22:567-73. doi: 10.1186/s12891-021-04427-x
- 14 Majeed H, Barrie J, Munro W, McBride D. Minimally invasive reduction and percutaneous fixation versus open reduction and internal fixation for displaced intra-articular calcaneal fractures: A systematic review of the literature. *EFORT Open Rev.* 2018;3:418-25. doi: 10.1302/2058-5241.3.170043
- 15 Li M, Lian X, Yang W, Ding K, Jin L, Jiao Z, *et al.* Percutaneous reduction and hollow screw fixation versus open reduction and internal fixation for treating displaced intra-articular calcaneal fractures. *Med Sci Monit.* 2020;26:926-32. doi: 10.12659/msm.926833
- 16 Palmer I. The mechanism and treatment of fractures of the calcaneus; open reduction with the use of cancellous grafts. *J Bone Joint Surg Am.* 1948;30:2-8.
- 17 Weber M, Lehmann O, Sägesser D, Krause F. Limited open reduction and internal fixation of displaced intra-articular fractures of the calcaneum. *J Bone Joint Surg Br.* 2008;90:1608-16. doi: 10.1302/0301-620x.90b12.20638
- 18 Tornetta P, 3rd. The Essex-Lopresti reduction for calcaneal fractures revisited. *J Orthop Trauma.* 1998;12:469-73. doi: 10.1097/00005131-199809000-00007
- 19 Tornetta P, 3rd. Percutaneous treatment of calcaneal fractures. *Clin Orthop Relat Res.* 2000;91:6. doi: 10.1097/00003086-200006000-00011
- 20 Gavlik JM, Rammelt S, Zwipp H. Percutaneous, arthroscopically-assisted osteosynthesis of calcaneus fractures. *Arch Orthop Trauma Surg.* 2002;122:424-8. doi: 10.1007/s00402-002-0397-4
- 21 Tomesen T, Biert J, Frölke JP. Treatment of displaced intra-articular calcaneal fractures with closed reduction and percutaneous screw fixation. *J Bone Joint Surg Am.* 2011;93:920-8. doi: 10.2106/jbjs.H.01834
- 22 Forgon M. Closed reduction and percutaneous osteosynthesis: technique and results in 265 calcaneal fractures. In: Tscherne H, J S, editors. *Major fractures of the pilon, the talus, and the calcaneus: current concepts of treatment.* Berlin: Springer-Verlag; 1993. p. 207-13.
- 23 Stulik J, Stehlik J, Rysavy M, Wozniak A. Minimally-invasive treatment of intra-articular fractures of the calcaneum. *J Bone Joint Surg Br.* 2006;88:1634-41. doi: 10.1302/0301-620x.88b12.17379
- 24 Ibrahim T, Mohamady E, Al-Ashhab M. Fixation of displaced intra articular calcaneal fracture through sinus tarsi approach. *BJAS.* 2022;7:23-30.
- 25 Zhang J, Xiao B, Wu Z. Surgical treatment of calcaneal fractures with bioabsorbable screws. *Int Orthop.* 2011;35:529-33. doi: 10.1007/s00264-010-1183-5