

**Original  
Article**

**EVALUATION OF THE ROLE OF EXTERNAL RADIATION THERAPY FOLLOWING PERCUTANEOUS DRAINAGE USING STEREOTACTICALLY IMPLANTED OMMAYA RESERVOIR SYSTEM IN THE MANAGEMENT OF GROSSLY CYSTIC CRANIOPHARYNGIOMA**

**Eman El-Sheikh<sup>1</sup> and Ashraf Al-Abyad<sup>2</sup>**

<sup>1</sup>Department of Radiation Oncology and Nuclear Medicine and <sup>2</sup>Department of Neurosurgery, Ain Shams University, Cairo, Egypt

---

**ABSTRACT**

---

**Background:** A prospective study to evaluate the effectiveness, safety and toxicity of radiation therapy (RT) following percutaneous drainage using Ommaya reservoir system (ORS) stereotactically implanted as a therapeutic option in the management of cystic craniopharyngioma.

**Patients and Methods:** Between January 2000 and August 2008, 30 patients were referred for stereotactic placement of ORS for drainage of their cystic craniopharyngiomas. There were 16 males and 14 females vary in age from 752- years (median 15years).Sex patients (20%) had ORS placement as a primary treatment, while 24 patients (80%) had undergone prior craniotomy. Twelve patients (40%) had purely cystic tumors, while 18 patients (60%) had mixed tumors. Patients were selected on the basis of having their CT scan and MRI disclosure of:1) Purely or predominantly unilocular cystic Craniopharyngioma, either primary or recurrent. 2)The craniocaudal dimension of the cyst was at least 2cm. 3)The cyst wall was not too thick or calcified to be punctured. All patients received RT.A median target dose of 52.2Gy (range 5057.6- Gy) was applied in a conventional fractionation of 1.8 Gy for 5 days per week.

**Results:** Twenty-five patients (83.3%) showed clinical improvement in the early post-operative period. No procedure related morbidity was encountered. Eleven patients (36.6%) had spontaneous regression of their cysts, 16 patients (53.3%) required multiple aspiration for symptomatic recurrence of their cysts; 11(68.7%) of them finally stabilized and the remaining 5(31.2%) patients continued to require infrequent aspiration at intervals ranged from 4 months to one year. Three patients (10%) required frequent aspiration every one to 2 weeks even after finishing a complete course of RT. Three patients (10%) eventually required revision of their ORS. Five patients (16.6%) necessitated subsequent craniotomy. After a median follow-up of 48 months (range 1270- months), local tumor control was 90% at 5-years.Overall survival and progression free survival rates at 5-years were 90% and 86.6%, respectively. Acute toxicity was mild in all patients. Long-term toxicity included growth hormone deficiency in 5 patients (16.6%) requiring hormonal replacement therapy. No radionecrosis or secondary malignancy were observed.

**Conclusion:** Treatment of cystic craniopharyngiomas by percutaneous aspiration via ORS implanted stereotactically combined with RT can be considered as a definitive treatment option in cases of recurrent grossly cystic or primary purely cystic tumors.

---

**Key Words:** Craniopharyngioma, stereotactic, ommaya reservoir, radiotherapy.

---

**Corresponding Author:** Eman El-Sheikh      Tel.: 0101225020      E-mail: emanelsheikh.169@gmail.com

---

**INTRODUCTION**

---

Craniopharyngiomas are benign tumors derived from epithelial origin that are believed to arise from the remnants of Rathke's pouch in and around suprasellar region. It is an uncommon tumor that accounts for 2-9% of all intracranial neoplasm. These tumors are usually well circumscribed and encapsulated. However, craniopharyngiomas are found in a very critical brain location. These tumors can be adherent to the optic nerves or chiasm, the major vessels of the

circle of Willis, infundibulum, the pituitary gland and the hypothalamus<sup>1</sup>.

Management of these tumors remains controversial. Complete tumor removal is often recommended where feasible. Large surgical series have shown that complete resection is possible in 57-90% of cases. Even after complete removal, recurrence rates have been found to be 15-37%.

However, aggressive surgery can be associated with mortality (1-3%), significant visual loss and neurologic dysfunction<sup>2,3</sup>.

Recent data suggested that subtotal resection followed by adjuvant radiation therapy (RT) may be an appealing substitute for gross-total resection, providing similar rates of tumor control without the morbidity associated with aggressive resection<sup>4,5</sup>.

Recurrent tumors have an additional burden of complexity and to date, there is no consensus regarding their optimal management strategy<sup>3,5</sup>. These considerations have prompted a measure of criticism about the effectiveness of the traditional surgical approach to craniopharyngioma and suggested the possibility of alternative management options that exploit the possibilities offered by limited surgery combined with RT in all its aspects<sup>2,5</sup>.

Special therapeutic options were considered for the treatment of cystic craniopharyngiomas, which represent as much as 60% of cases. When the tumor is predominantly composed of fluid, its reduction by percutaneous aspiration may enable palliative relieve of most of the problems connected with the neoplastic mass and allow the use of alternative therapies for the tumor<sup>6</sup>. The Ommaya reservoir system (ORS) is used as a permanent percutaneous draining system consisting of an inert catheter provided with few holes at its distal end, indwelling within the cyst and connected with a subcutaneous reservoir<sup>7</sup>.

Since the therapeutic role of percutaneous drainage of craniopharyngioma has been seldom stressed, precise knowledge about its usefulness and its main technical features is not easily obtained from the literature<sup>6</sup>. The aim of this study was to evaluate the role of percutaneous drainage using the ORS implanted stereotactically followed by RT as a therapeutic option in the management of primary and recurrent grossly cystic craniopharyngiomas.

## **PATIENTS AND METHODS**

---

This prospective single arm study was conducted on 30 patients who were referred for stereotactic placement of ORS for drainage of their cystic craniopharyngiomas followed by RT. Eligibility Criteria: Patients were selected on the basis of having their contrasted CT scan and /or MRI disclosure of ;

1. Purely or predominantly unilocular cystic craniopharyngioma, either primary or recurrent.
2. The craniocaudal dimension of the cysts was at least 2cm to ensure that the whole distal

perforated portion of the catheter (which is 1.6 cm in length) was totally introduced into the cyst cavity at the time of placement.

3. The cyst wall was not too thick or calcified to be punctured by the ventricular catheter with its inner stylet. Exclusion criteria: no prior malignancy, no prior RT and no other serious medical or psychiatric illness.

### **Pretreatment assessment:**

Initial evaluation included; history, neurologic examination, ophthalmologic examination (visual acuity, visual field and fundus examination), hormonal level assessment (prolactin, growth hormone, cortisol, follicle stimulating hormone, leutinizing hormone and thyroid profile), as well as radiologic investigations including contrasted computerized tomography (CT) and/or magnetic resonance imaging (MRI) scans. Parents of each patient and adult patients gave written informed consent before entering the study.

### **Treatment plan:**

#### **Surgical procedure:**

Two different models of ORS were used. The standard ORS with flat bottom reservoir and side inlet catheter and the burr hole reservoir with bottom inlet catheter. In all cases, stereotactic frame application and contrast enhanced CT scanning were performed under general anesthesia. The target was selected in the bottom of the cyst, 5 mm superior to the lowest cut where the cyst starts. A transfrontal approach with an entry point; 2 to 3 cm off midline at the coronal suture was chosen to access all lesions. A U-shaped flap centered over the entry point was drawn with its base directed posteriorly. The catheter was inserted directly and guided by the stereotactic arc to the predetermined target distance, then connected to the reservoir. Before skin closure, gentle cyst aspiration was performed aiming to reduce the cyst pressure and not to evacuate the cyst completely. CT scan was obtained within 24 hours after placement to verify the position of the catheter, ensure satisfactory cyst drainage and exclude cerebral hemorrhage.

### **Radiation therapy:**

External beam RT was administered with the cobalt-60 machine or 6 MV linear accelerator. All patients were treated in supine position. A thermoplastic mask was

Initially constructed then used for the entire simulation process and treatment course which greatly improves set-up reproducibility. The target volume encompassed gross tumor volume, as defined on post-

operative imaging (CT or MRI), with a safety margin of approximately 2 cm in each diameter. Three fields and two lateral parallel opposed fields' techniques were used. The total dose ranged between 50-57.6 Gy and delivered at 1.8Gy/ fraction, 1 fraction per day, 5 days per week. The target doses were prescribed to the isocenter, the 90% isodose encompassed the target volume. With respect to the localization of craniopharyngiomas, the eyes, optic nerves, chiasm and brainstem were of special concern during treatment planning. Patients received good dehydrating measures started at least 24 hours before RT.

#### **Evaluation of Response:**

Response criteria were evaluated from radiological brain imaging done one month after RT. The responses were then graded into four categories. Complete response (CR): Disappearance of all enhancing tumor on consecutive brain imaging scans. Partial response (PR): > 50% reduction in size of enhancing tumor. Progressive disease (PD): >25% increase in the size of enhancing tumor or any new tumor on brain scans. Stable disease (SD): All other situations. For response analysis, the solid area as well the cystic components were included.

#### **Follow-up**

Patients were requested to be seen in the out-patient clinic every month for the first 3 months and then every 3 months for the first year. The assessment involved full neurological and ophthalmologic examinations as well as hormonal investigations whenever indicated. Follow-up contrasted CT was performed at one and 6 ms visits and whenever there was clinical suspicion of cyst recurrence. MRI was performed routinely at the end of the first year then annually thereafter.

#### **Survival analysis:**

Overall Survival (OS) was measured from the date of entry into the study until death from any cause or last follow up. Progression free survival (PFS) was measured from the date of entry into the study until date of first evidence of disease progression. PASW statistical software package (V. 18.0, IBM Corp., USA, 2010) was used for data analysis. The following tests were done: 1- Chi-square test to study the association between variables as regards the categorized data. The probability of error at 0.05 was considered significant. 2- Survival analysis including calculation of survival rate at different points of the study and Kaplan Meier survival curve<sup>8</sup>.

#### **Assessment of normal tissue toxicity:**

Acute and late effects of RT were assessed according to the RTOG/EORTC radiation morbidity criteria<sup>9</sup>.

## **RESULTS**

The study included 30 patients with cystic craniopharyngioma presented to Ain-Shams University hospitals (Neurosurgery and Radiation Oncology Departments) between January 2000 and August 2008. The patients' age ranged from 7 to 52 years (Median age 15 years). The craniocaudal dimension of the cysts ranged from 2 to 8 cm, while the size of the solid component in mixed tumors ranged from one to 3 cm. Six patients (20%) had stereotactic ORS placement as a primary treatment while 24 patients (80%) had undergone prior craniotomy and tumor resection. The patients and tumors characteristics and previous treatments prior to ORS placement are shown in Table (1). The most prominent clinical manifestations were related to increased intracranial pressure (ICP) and to visual and endocrinological impairments. The pre-operative clinical findings are illustrated in Table (2).

A tissue diagnosis of craniopharyngioma was established in 24 patients (80%) who had undergone a prior craniotomy while in the 6 new cases (20%), the diagnosis was based mainly on the neuro-imaging and this was confirmed by examination of the cyst fluid taken during the insertion of the Ommaya reservoir.

#### **Early clinical outcome:**

Twenty five patients (83.3%) showed significant clinical improvement in the early post-operative period. The remaining 5 patients (16.6%) remained stable. This consisted of either improvement in symptoms and signs of raised ICP in 80% of patients (12/15) or improvement of vision in 70% of patients (14/20) with pre-operative impairment of visual acuity and/or field. Early improvement in manifestations of pituitary dysfunction was noted in 60% of patients (3/5) with diabetes insipidus and in 25% of patients (1/4) with hyperprolactinaemia. No further clinical endocrine dysfunction was encountered post-operatively in any of the patients. Of the 5 patients with pre-existing depressed mental status, 3 patients (10%) were improved significantly, while the other 2 (6.6%) had modest improvement in their symptoms. They required periodic cyst drainage but gradually deteriorated and died after 2 and 5 months following treatment despite local tumor control by performing periodic aspiration and no radiological evidence of tumor progression.

The CT scan done after initial aspiration revealed significant reduction in the cyst size in all patients. Procedure related morbidity such as hematoma or new neurological deficit was not encountered.

**Subsequent aspiration:**

The diagnosis of cyst recurrence was made based on findings in periodic neuro-imaging studies or on worsening of neurological deficits especially with regard to visual symptom and the CT scan confirmed cyst recurrence.

Eleven patients (36.6%); 8 (26.6%) with purely cystic and 3(10%) with mixed tumors, showed spontaneous and complete regression of their cysts and this was confirmed by repeated post-operative neuro-imaging.

Sixteen patients (53.3%) required multiple aspirations for symptomatic recurrence of their cysts performed at intervals of 4 to 8 weeks; 11 of these patients (36.6%) finally stabilized over a period of 4- 6 months and did not require further aspiration afterwards and the remaining 5 patients (16.6%) continued to require infrequent aspiration at intervals ranged from 4 months to one year. In 3 patients (10%), frequent symptomatic cyst refilling required repeated aspiration every one to 2 weeks over a period of 3,4 and 6 months, even after finishing a complete course of RT and eventually they underwent subsequent craniotomy for excision of their cysts.

**Further surgical intervention:**

Three patients (10%) eventually required revision of their ORS for technical failure. Three children (10%), age ranged (8-11years), required placement of ventriculo-peritoneal shunt to treat unresolving obstructive hydrocephalus at median 6 months post-operatively. Five patients (16.6%) necessitated subsequent craniotomy and cyto-reductive surgery due to significant re-growth of the solid component in 2 patients (6.6%). While in the other 3 patients (10%), craniotomy was performed at median 4 months following treatment due to the impractical symptomatic refilling of their cysts that required aspirations at very short intervals.

**Tumor control:**

The results with regard to tumor response after ORS placement and RT in the 30 patients are shown in Table (3). In 13 patients (43.33%) with purely cystic tumors, 8 patients (26.7%) had CR, 3 patients (10%) had PR and one (3.3%) had SD that required infrequent aspiration, while one patient (3.3%) had PD with a total tumor control rate of 92.3% (12/13). In 17 patients (56.7%), with mixed solid and cystic tumors 3 patients (10%) had CR, 8 patients (26.7%) had PR, 4 patients (13.3%) had SD that required infrequent aspirations, while two patients (6.7%) had PD with a tumor control rate of 88.2% (15/17). The overall tumor control rate was 90% (27/30). (Figures 1,2,3,4).

**Survival analysis:**

The median follow-up duration was 48 months (range from 12 -70 months ). At 5-years PFS and OS were 86.6% and 90%, respectively. (Figures 5, 6). The median time to disease progression was 60 months (95% confidence interval 50.05-62.95%). The median survival was 62 months (95% confidence interval 52.76-64.24%).

Correlation between the tumor control and survival analysis were studied in relation to patients and lesions variables. Tumor control and survival analysis were not found to be correlated significantly with the patient age, prior surgery, tumor type (pure cyst or mixed tumor), cyst volume or radiation dose.

**Side effects after radiation therapy:**

In the current study, The most frequent side effect of RT observed in all patients were loss of hair (alopecia) and mild skin erythema in areas of irradiation. By using a radiation dose ranged from 50 to 57.6 Gy (median 52.2 Gy), no patient developed sever toxicity to normal tissue structures, radiation necrosis or secondary malignancies. However, late hypopituitarism were developed in 5 patients (16.6%) with growth retardation that required hormonal replacement therapy.

**Table 1:** Characteristics of 30 patients with cystic craniopharyngioma.

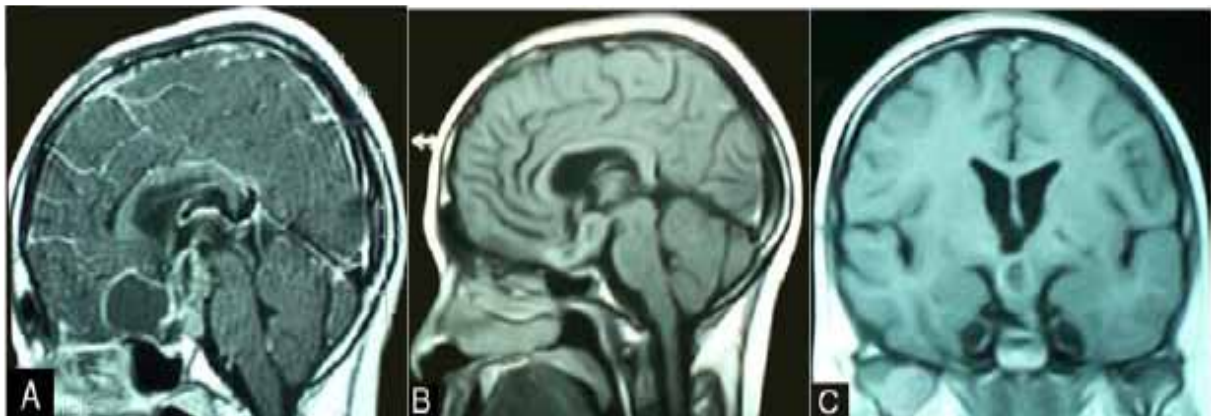
Characteristics	Classification					
		No.	%		No.	%
Age	≤16 years	19	63.33	>16 years	11	36.66
Sex	Males	16	53.33	Females	14	46.66
Tumor type	Purely cystic	12	40	Mixed	18	60
Occurrence	Primary	6	20	Recurrent	24	80
Previous Treatment	Craniotomy and tumor excision				24	80
	Ventriculo-peritoneal shunt				4	13.33

**Table 2:** Clinical findings in the 30 patients prior to the drainage procedure.

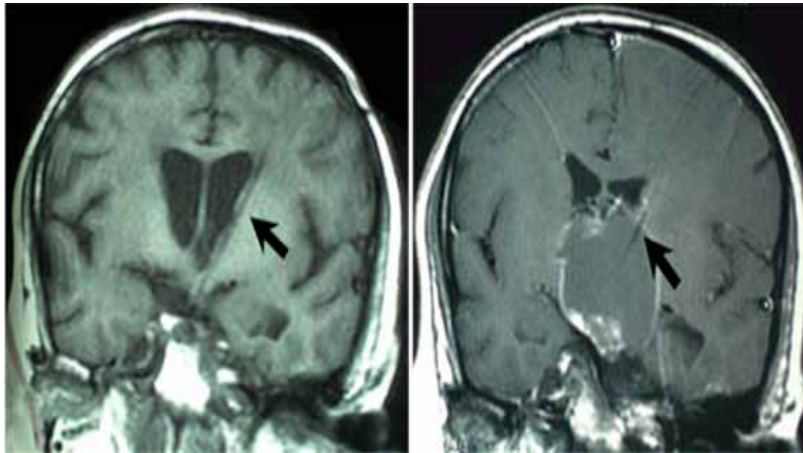
Symptoms and/or signs	No. of cases	%
Headache	15	50
Depressed mental status	5	16.6
<b>Related to visual dysfunction</b>		
- Reduced visual acuity	22	73.3
- Visual field deficits	16	53.3
- Combined reduced visual acuity and visual field deficits	10	33.3
- Papilloedema	7	23.3
- Optic atrophy	9	30
<b>Related to endocrine dysfunction</b>		
- Increased prolactin level	4	13.3
- Panhypopituitarism (growth retardation, diabetes insipidus, asthenia)	12	40
<b>Related to hypothalamic manifestations</b>		
- Hyperphagia, obesity	4	13.3
- Disturbed state of sleep and wakefulness	3	10

**Table3:** Tumor response after treatment in the 30 patients.

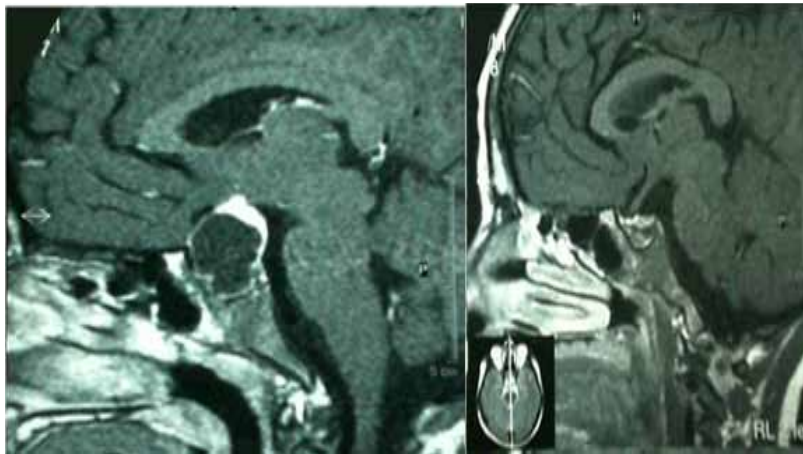
Response	Nature of the tumor					
	Purely cystic		Mixed		Total	
	No.	%	No.	%	No.	%
Complete response (CR)	8	26.7	3	10	11	36.7
Partial response (PR)	3	10	8	26.7	11	36.7
Stable disease (SD)	1	3.3	4	13.3	5	16.6
Progressive disease (PD)	1	3.3	2	6.7	3	10
Total	13	43.3	17	56.7	30	100



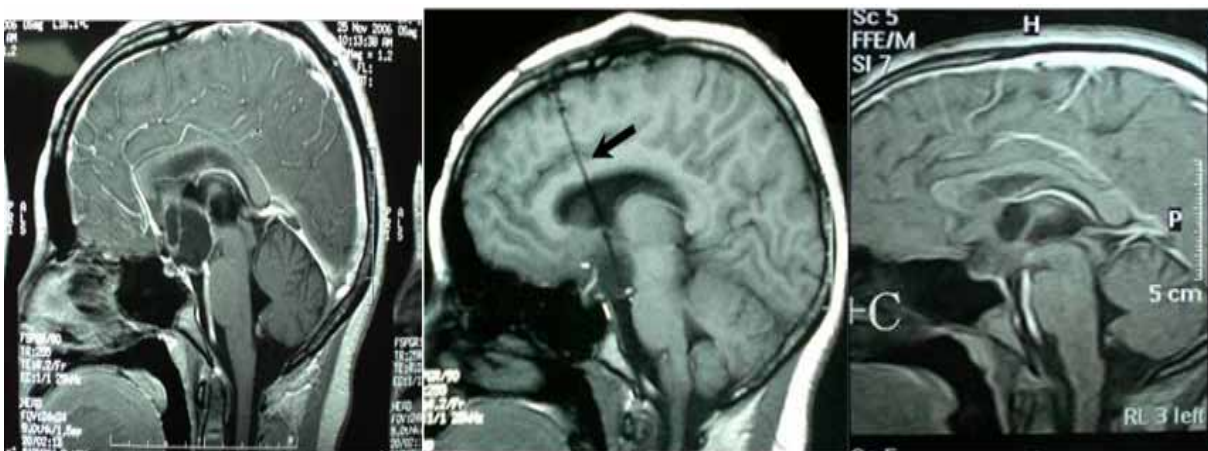**Figure 1:** Sagittal gadolinium enhanced MRI obtained in a 15 years-old boy who underwent previous craniotomy and partial excision of a craniopharyngioma. A: a recurrent mixed tumor with the solid part extending into the supra- and retro-sellar region. Following ORS placement and RT, the cyst required infrequent aspiration over a period of 3 months followed by spontaneous cyst regression. B: sagittal and C: coronal cuts performed 26 months following ORS placement showing significant cyst involution and marked regression of the solid part.



**Figure 2:** Coronal gadolinium enhanced MRI obtained in a 47 years-old male who underwent previous craniotomy for craniopharyngioma. A: early image following ORS placement showing a recurrent grossly cystic tumor with a small solid component. The cyst required aspiration in few occasions over a period of 4 months during which the patient received RT. B: image obtained 36 months following treatment showing complete solid tumor and cyst regression. Black arrow points to the ORS catheter within the cyst lumen.

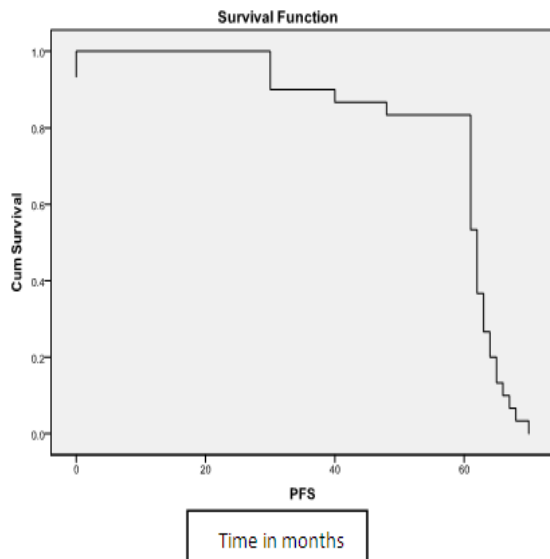


**Figure 3:** Sagittal gadolinium enhanced MRI obtained in a 17 years-old male. A: a sellar and supra-sellar cystic craniopharyngioma with minimal solid component. Following ORS placement, the cyst required a single episode of aspiration followed by spontaneous regression and the patient received RT. B: solid tumor and complete cyst regression 42 months following treatment.

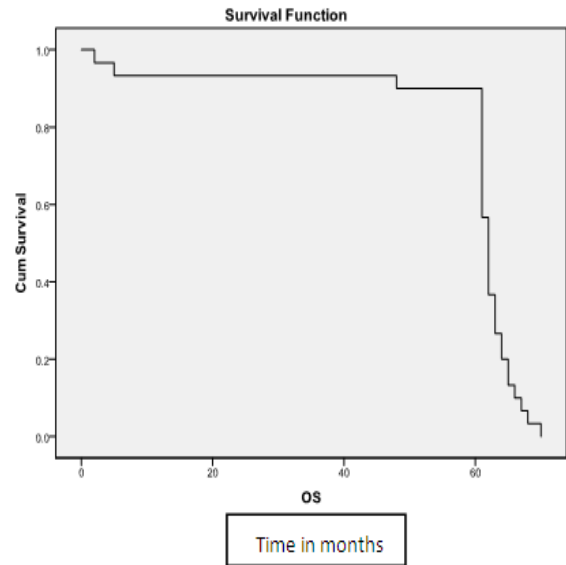


**Figure 4:** Sagittal gadolinium enhanced MRI. A: a cystic craniopharyngioma in a 16 years-old female. B: obtained 12 months following ORS placement and RT showing marked cyst regression which revealed only CSF on subsequent aspiration. C: obtained 14 months later showing complete cyst regression. Black arrow points to the ORS catheter.





**Figure 5:** Kaplan- Meier Estimate of 5-years PFS of 30 patients with cystic craniopharyngioma.



**Figure 6:** Kaplan- Meier Estimate of 5-years OS of 30 patients with cystic craniopharyngioma

## DISCUSSION

Craniopharyngioma very frequently presents as cystic component (about 80% of cases and almost 100% of recurrences)<sup>6</sup>. For the past decade, the management of craniopharyngioma has emphasized both long term quality of life and tumor removal. Unfortunately, high rates of post-operative morbidity particularly hypothalamic damage, visual deterioration and endocrine complications, which occur in 30-70% of patients were noted<sup>10,11,12</sup>. Radical resection remains important for patients with amenable solid or mixed tumors<sup>3,13</sup>. Continued advances in limited surgery and RT have maintained excellent local disease control while minimizing treatment-related sequelae<sup>14-16</sup>.

The surgical treatment of recurrent craniopharyngioma is considered more

Challenging than primary surgery because scars produced by previous surgery may

Enhance the technical difficulty of second surgery and therefore increase the risks of morbidity and mortality<sup>3,4</sup>. As a result, many authors who prefer to perform radical resection in the first surgery recommend RT or multimodal approach as a salvage treatment of recurrent cases<sup>2,4</sup>.

Special therapeutic options are open to treat grossly cystic craniopharyngioma. Given that this tumor is histologically benign, in theory it should be enough:

1. To reduce production of fluid in the cyst and/or
2. To prevent accumulation and encourage its discharge either to the outside or into the CSF pathways. The first goal is difficult to achieve due to the neoplastic nature of the cyst wall so, it is necessary to act by means which reduce its proliferation. This can be obtained by RT via the intracavitary route<sup>17,18</sup> or via the external route<sup>1,15</sup>. The second goal, that is drainage of the cyst contents, is a palliative treatment which can be easily and rapidly achieved<sup>19</sup>.

In many cases frequent drainage procedures are required, the indwelling Ommaya reservoir system was adopted by Fox<sup>19</sup> for draining a recurrent cystic suprasellar tumor that was probably a craniopharyngioma. Other studies have since documented the indications and the safety of implantation of this type of access into cystic craniopharyngioma<sup>20,21</sup>. However, clear evaluation of clinical results is somewhat difficult due to the few reports that regard such treatment as therapeutic "per se"<sup>22</sup>. In this prospective study, the effectiveness of this method combined with external beam RT were evaluated by assessment of the early post-operative results, the long term outcome with regard to the clinical and local tumor control, survival analysis and treatment related toxicity.

The ORS was implanted stereotactically in 24 patients (80%) for recurring grossly cystic craniopharyngiomas already treated surgically in

one or 2 occasions. In 6 other patients (20%) with purely cystic craniopharyngioma, drainage of the cyst was carried out in the first instance, followed by RT aiming at control the cyst wall production of fluid which necessitated frequent aspirations.

Technical problems with the stereotactic placement of ORS in cystic craniopharyngiomas have rarely been discussed<sup>22</sup>. One of the main technical obstacles is the difficulty of penetrating the cyst capsule due to its consistency as well as the presence of multilocular partitions which prevent the complete drainage of the cyst contents<sup>6</sup>. In the present study, patients were selected on the basis of having unilocular cyst with thin non-calcified wall in the pre-operative imaging to avoid these problems.

Another major technical difficulty has been in achieving adequate catheter placement because of the proximity of these cysts to normal CSF spaces or partial collapse of the cyst cavity following aspiration<sup>21</sup>. In the present study, this difficulty was tried to be overcome by pre-operative selection of patients having cysts with craniocaudal length of 2 cm or more and the target was chosen in the bottom of the cyst. In doubtful cases, an intra-operative lateral X-ray screening was performed in order to ensure that the catheter tip was placed at the selected target which is represented by the centre of the side ring of the stereotactic arc.

Although complications following these procedures are very rare, reports of frontal lobe hemorrhage and subarachnoid hemorrhage resulting in death have been documented<sup>22</sup>. In the present study, no hemorrhage was encountered in any case as

Cleared by early post-operative CT scan. Possible late complications related to the use

Of ORS include infection and obstruction of the catheter with debris or viscous fluid. Rogers and Barnett<sup>23</sup> reported a series of 20 patients who had ORS placed to access cystic brain tumors with no case of infection or obstruction of the catheter.

In the current study, there was no case of infection, while catheter obstruction with debris was encountered in 3 patients (10%) and necessitated revision.

In the literature, the operative mortality ranges from 0 to 14% and averages 3.7% in a multiseries review<sup>24,25,26</sup>. In the present study, no operative

mortality was encountered. However, 2 patients (previously treated by subtotal resection) died 2 and 5 months following treatment despite local tumor control by performing periodic aspiration and no radiological evidence of tumor progression. Such late mortalities, not related to recurrent tumor, are well known in the literatures and have been attributed to acute endocrinological deficits, infections or seizures<sup>27,28</sup>.

The growth of the solid component in mixed craniopharyngioma is problematic. Periodic cyst aspiration does not affect progression of the solid component of the tumor or prevent production of fluid in the cyst. In this context, the efficacy of RT in the control of craniopharyngiomas has been documented in many reports<sup>2,4,13</sup>. Rajan et al.<sup>29</sup> reported the results of 148 patients treated with limited surgery followed by RT and 45% of patients were children. The median radiation dose was 50Gy. The 10 and 20 year OS and PFS were 83%, 79% and 77%, 66%, respectively. Age <16year was the most important prognostic factor. An important indicator of radiation efficacy in this study was the lack of impact of extent of surgery on PFS<sup>29</sup>.

In another study from Institute Gustave Roussy, 37 children with craniopharyngiomas received RT (median dose of 50Gy). In 19 patients (51.4%), irradiation was part of initial management and in 18 cases (48.6%) it was administered at the time of relapse. After a mean of follow-up of 98 months the 10 year OS and PFS were 65% and 56.6%, respectively. Surgical resection and higher dose of RT (>50Gy) were significantly correlated with superior PFS<sup>30</sup>.

Isaac Yang et al.<sup>4</sup> identified studies publishing outcome data on patients undergoing surgery for craniopharyngioma. There were 442 patients who had tumor resection. Gross total resection (GTR) was achieved in 256 cases, subtotal resection (STR) followed by RT in 85 cases. The 5-year PFS for the GTR group vs. the STR followed by RT group were 67% vs. 69%. The 5-year OS for the GTR group vs. the STR followed by RT group were 98% vs. 99%. There was no significant difference in PFS or OS between the two groups. These data seem to support the idea that STR followed by RT is a the reasonable approach to achieve tumor control and limiting hypothalamic and hypophyseal morbidity associated with aggressive resection<sup>4</sup>.

Similar results were seen in the study of Stripp et al.<sup>31</sup> They found that when comparing the 57 patients



treated with surgery alone to the 18 patients treated with STR followed by RT (median dose 54Gy), a significant difference in local control rates at 5 years was noted (92% vs. 53%, respectively  $p = 0.004$ ). However, no statistically significant difference in OS was found between the two groups, because RT was highly effective as salvage therapy<sup>31</sup>.

Comparable results were found in the present study, at the time of the final evaluation of the 30 patients, the overall tumor control rate was 90% (92.3% for purely cystic and 88.2% for mixed tumors) and 73.3% of patients showed complete

Or marked reduction of their cysts without requiring further aspiration. The 5-year OS

Was 90% and 5-year PFS was 86.6%. Tumor control and survival analysis were not found to be statistically dependant on the patient age, prior surgery, tumor type (pure cyst or mixed tumor), cyst volume or radiation dose.

RT techniques continue to evolve with the use of modern 3D conformal RT utilizes CT and MRI for target localization. Advances in patient immobilization, computer hardware and software tools such as beam's eye views, dose-volume histograms, 3D dose calculations, computer-driven multileaf collimators and stereotactically guided irradiation have all increased the potential for improving the therapeutic ratio following RT<sup>30,32</sup>.

Stereotactic radiosurgery (SRS) and fractionated stereotactic radiotherapy (SRT) are increasingly being used in the management of craniopharyngioma. The use of stereotaxis for target localization, treatment planning and daily treatment immobilization allows for a more precise delivery of radiation dose when compared to conventional external beam irradiation. SRT and SRS could thus improve tumor control rates and decrease the incidence of acute and late complications<sup>32</sup>.

In a study of 98 patients treated with SRS, the reported PFS was 61% at 5-years<sup>33</sup>. Because of close proximity of craniopharyngiomas to the optic chiasm, it is likely that only small residual lesions were treated with SRS to avoid optic neuropathy which occurs in 1-2% of patients following doses to the optic chiasm below 10 Gy. The reported results of SRS for such tumors suggest that tumor control following SRS is inferior to that achieved with SRT<sup>30,33</sup>.

Combs et al.<sup>32</sup> reported the results of 40 patients treated with SRT. Most patients were treated for tumor progression after surgery. The median target dose was 52.2 Gy. Local tumor control was 100% at both 5 and 10 years. OS rates at 5 and 10 years were 97% and 89%, respectively<sup>32</sup>. Minniti et al.<sup>14</sup> reported similar results in 39 patients treated with fractionated stereotactic conformal RT (SCRT), with a PFS rate of 92% and an OS rate of 100% at 5 years. Local tumor control and toxicity were comparable to the results reported following conventional RT<sup>14</sup>.

Intensity-modulated RT (IMRT) makes it possible to modulate the radiation intensity of each small beamlet, e.g., 1×1 cm, of a certain field to get uneven dose distribution intentionally. With this, optimality of dose conformality can be much improved<sup>34</sup>. Puget et al.<sup>24</sup> have reported no treatment failures with this approach at a 14-month follow-up<sup>24</sup>. Meanwhile, there are also pitfalls in precision RT. The volume included in low isodose line from RT plan using multifield is 1.5–2 times larger than those from simple bilateral plan. Another point is prolonged time for each RT session in practical aspect and this can definitely add workload in busy departments<sup>34</sup>.

Another important issue is the timing of RT. It is currently still discussed controversially whether RT should be applied early in the time course or should be reserved for tumor recurrence. Regine et al.<sup>35</sup> reported 78% survival rate at 20 years in children treated at the time of diagnosis as opposed to 25% in children treated for recurrence<sup>35</sup>.

However other studies reported that RT is effective both adjuvantly and at relapse (31,34,36). Moon et al.<sup>34</sup> found that there was no difference in OS (84.6 vs. 89.6%) or PFS (91.2 vs. 91.3%) at 10 years between early RT and late RT<sup>34</sup>.

The external beam radiation dose for craniopharyngioma that represents the best balance of tumor control and a low complication rate has not been defined. Most published studies reported similar tumor control with doses between 50 and 60 Gy<sup>1,5,14,31</sup>. However, doses over 55 Gy were associated with an increased incidence of late toxicity without significant improvement in tumor control. Concerns about the maximum dose to the optic chiasm and optic nerves precludes treatment to higher doses<sup>4</sup>.

Other radiation modalities using stereotactic technique such as intracavitary irradiation with beta emitting radioisotopes have been utilized with better

sparing of normal tissue<sup>18</sup>. In the study of Hasegawa et al.<sup>49</sup> patients were treated with stereotactic 32P intracavitary irradiation. The 5-year OS was 90% and tumor control rate was 76%. The procedure proved to be effective with low risk of complication, for the control of tumor cysts but not of solid tumor<sup>18</sup>.

Many studies reported good preliminary results of intracystic bleomycin in the treatment of cystic lesions and cystic recurrences<sup>37,38,39</sup>. Intracystic bleomycin is effective in inducing at least more than 25% shrinkage of the craniopharyngioma cyst in up to 90% of patients<sup>40</sup>. At a mean follow-up of 2-7 years (the range of means for the studies), 43-70% of patients required no treatment in addition to bleomycin<sup>37,40,41</sup>, but there is no information about the durability of the bleomycin effect at 10 years or longer. In the Canadian experience<sup>40</sup>, which is similar to the other reported series, 94% responded to intracystic bleomycin, but the duration of response was < 1 year in 47%. Fatal complications from bleomycin leakage were reported in the literature<sup>41</sup>. Hader et al.<sup>42</sup> reported leaks in almost 45% of their cases, 2 weeks after catheter insertion<sup>42</sup>.

Hypopituitarism represents the most commonly reported late complication of RT, occurring in more than 30-50% of irradiated patients after 5-10 years<sup>14</sup>. The incidence following conservative surgery and RT is low (22%) compared to the (80%) incidence following radical surgery<sup>13</sup>. The incidence appears to be dose dependent, at levels higher than 60 Gy hypopituitarism may be as high as 80% vs. 36% incidence at lower doses<sup>5</sup>. In the present study new endocrine deficiencies were noted in 5 children (16.6%) who developed late growth retardation.

Visual deterioration occurring during RT has been well documented and is usually attributed to cystic progression and/or hydrocephalus. Cyst aspiration alone reverses vision loss when performed in a timely manner<sup>16</sup>. In the current study 16 patients (53.3%) required cyst aspiration in the time period during, or after RT. Improvement of vision occurred in 70% of 20 patients (14/20) with preoperative impairment of visual acuity and/or field of vision. Optic neuropathies and/or necrosis may also occur secondary to RT and appear to be dose dependent.

Minniti et al.<sup>43</sup> have not experienced any occurrences of optic neuritis or necrosis when the optic apparatus is treated to 54–55.8 Gy in 1.8-Gy fractions, a consensus dose in the Literature<sup>43</sup>. The same observation was found in the current study.

The risk of a radiation-induced secondary malignancy is estimated to be 1.9% at 10 years. literature review done by Erin and Thomas, found that, Of the 626 patients who received conventional radiation, there were only 4 reports of secondary malignancies<sup>5</sup>. In the present study no patient developed secondary malignancy.

---

## CONCLUSION

Treatment of cystic craniopharyngiomas by percutaneous aspiration via ORS implanted stereotactically combined with RT can be considered as a definitive treatment option in cases of cystic recurrences already treated surgically. If a craniopharyngioma presented primarily in a purely cystic form, a draining operation may be indicated as a primary treatment in order to overcome rapidly the pressure manifestations and aiming at achieving complete and spontaneous regression of the cyst by creating a communication between the cyst and the surrounding CSF spaces. Even if this objective is not achieved, the drainage procedure is expected to improve the results of subsequent treatment using RT by reducing the volume of the target and overcoming problems related to the fluid portion of the tumor on which the ionizing radiation has no effect. However, children with craniopharyngioma remain vulnerable to late treatment failures and side effects from RT including endocrinopathy and vasculopathy and secondary tumors, which may have a detrimental impact on quality of life. Long-term follow-up beyond 5 and 10 years is necessary to assess tumor control relative to functional outcomes.

---

## REFERENCES

1. Varlotto JM, Flickinger JC, Kondziolka D, Lunsford LD, Deutsch M. External beam irradiation of craniopharyngiomas: Long-term analysis of tumor control and morbidity. *Int.J.Radiat.Oncol.Biol.Phys.* 2002 Oct 1;54(2):492-9.
2. Van Effenterre R, Boch AL. Craniopharyngioma in adults and children: A study of 122 surgical cases. *J.Neurosurg.* 2002 Jul;97(1):3-11.
3. Minamida Y, Mikami T, Hashi K, Houkin K. Surgical management of the recurrence and regrowth of craniopharyngiomas. *J.Neurosurg.* 2005 Aug;103(2):224-32.
4. Yang I, Sughrue ME, Rutkowski MJ, Kaur R, Ivan ME, Aranda D, et al. Craniopharyngioma: A comparison of tumor control with various treatment strategies. *Neurosurg.Focus* 2010;28(4):E5.1-E5.11.
5. Kiehna EN, Merchant TE. Radiation therapy for

- pediatric craniopharyngioma. *Neurosurg.Focus* 2010;28(4):E10.1-E10.7.
6. Spaziante R, De Divitiis E, Irace C, Cappabianca P, Caputi F. Management of primary or recurring grossly cystic craniopharyngiomas by means of draining systems. Topic review and 6 case reports. *Acta Neurochir.(Wien)* 1989;97(3-4):95-106.
  7. Ammaya AK. Subcutaneous reservoir and pump for sterile access to ventricular cerebrospinal fluid. *Lancet* 1963 Nov 9;2:983-4.
  8. Kaplan EL, Meier P. Nonparametric estimation from incomplete observations. *J.Am.Stat.Assoc.* 1958;53:457-81.
  9. Perez CA, Brady LW. Principles and practice of radiation oncology. 2<sup>nd</sup> ed.: Lippincott Williams and Wilkins; 1992.
  10. Kalapurakal JA, Goldman S, Hsieh YC, Tomita T, Marymont MH. Clinical outcome in children with craniopharyngioma treated with primary surgery and radiotherapy deferred until relapse. *Med.Pediatr. Oncol.* 2003 Apr;40(4):214-8.
  11. Chakrabarti I, Amar AP, Couldwell W, Weiss MH. Long-term neurological, visual and endocrine outcomes following transnasal resection of craniopharyngioma. *J.Neurosurg.* 2005 Apr;102(4):650-7.
  12. Thompson D, Phipps K, Hayward R. Craniopharyngioma in childhood: Our evidence-based approach to management. *Childs Nerv.Syst.* 2005 Aug;21(8-9):660-8.
  13. Caldarelli M, Massimi L, Tamburrini G, Cappa M, Di Rocco C. Long-term results of the surgical treatment of craniopharyngioma: The experience at the Policlinico Gemelli, Catholic University, Rome. *Childs Nerv. Syst.* 2005 Aug;21(8-9):747-57.
  14. Minniti G, Saran F, Traish D, Soomal R, Sardell S, Gonsalves A, et al. Fractionated stereotactic conformal radiotherapy following conservative surgery in the control of craniopharyngiomas. *Radiother.Oncol.* 2007;82(1):90-5.
  15. Lin LL, El Naqa I, Leonard JR, Tae SP, Hollander AS, Michalski JM, et al. Long-term outcome in children treated for craniopharyngioma with and without radiotherapy. *J.Neurosurg.Pediatr.* 2008;1(2):126-30.
  16. Merchant TE, Kiehna EN, Kun LE, Mulhern RK, Li C, Xiong X, et al. Phase II trial of conformal radiation therapy for pediatric patients with craniopharyngioma and correlation of surgical factors and radiation dosimetry with change in cognitive function. *J.Neurosurg.* 2006 Feb;104(2 Suppl):94-102.
  17. Julow J, Backlund EO, Lányi F, Hajda M, Bálint K, Nyáry I, et al. Long-term results and late complications after intracavitary yttrium-90 colloid irradiation of recurrent cystic craniopharyngiomas. *Neurosurgery* 2007;61(2):288-95.
  18. Hasegawa T, Kondziolka D, Hadjipanayis CG, Lunsford LD. Management of cystic craniopharyngiomas with phosphorus-32 intracavitary irradiation. *Neurosurgery* 2004 Apr;54(4):813-20; discussion 820-2.
  19. Fox JL. Intermittent drainage of intracranial cyst via the subcutaneous Ommaya reservoir. Technical note. *J.Neurosurg.* 1967 Sep;27(3):272-3.
  20. Joki T, Oi S, Babapour B, Kaito N, Ohashi K, Ebara M, et al. Neuroendoscopic placement of Ommaya reservoir into a cystic craniopharyngioma. *Childs Nerv.Syst.* 2002 Nov;18(11):629-33.
  21. Vitaz TW, Hushek S, Shields CB, Moriarty T. Changes in cyst volume following intraoperative MRI-guided Ommaya reservoir placement for cystic craniopharyngioma. *Pediatr.Neurosurg.* 2001 Nov;35(5):230-4.
  22. Albright AL, Hadjipanayis CG, Lunsford LD, Kondziolka D, Pollack IF, Adelson PD. Individualized treatment of pediatric craniopharyngiomas. *Childs Nerv.Syst.* 2005 Aug;21(8-9):649-54.
  23. Rogers LR, Barnett G. Percutaneous aspiration of brain tumor cysts via the Ommaya reservoir system. *Neurology* 1991 Feb;41(2(Pt 1)):279-82.
  24. Puget S, Garnett M, Wray A, Grill J, Habrand JL, Bodaert N, et al. Pediatric craniopharyngiomas: Classification and treatment according to the degree of hypothalamic involvement. *J.Neurosurg.* 2007;106 (1 Suppl.):3-12.
  25. Dhellemmes P, Vinchon M. Radical resection for craniopharyngiomas in children: Surgical technique and clinical results. *J.Pediatr.Endocrinol.Metab.* 2006 Apr;19 Suppl 1:329-35.
  26. Couldwell WT, Weiss MH, Rabb C, Liu JK, Apfelbaum RI, Fukushima T. Variations on the standard transsphenoidal approach to the sellar region, with emphasis on the extended approaches and parasellar approaches: Surgical experience in 105 cases. *Neurosurgery* 2004;55(3):539-47.
  27. Pereira AM, Schmid EM, Schutte PJ, Voormolen JH, Biermasz NR, van Thiel SW, et al. High prevalence of long-term cardiovascular, neurological and psychosocial morbidity after treatment for craniopharyngioma. *Clin.Endocrinol.(Oxf)* 2005 Feb;62(2):197-204.
  28. Karavitaki N, Brufani C, Warner JT, Adams CB, Richards P, Ansorge O, et al. Craniopharyngiomas in children and adults: Systematic analysis of 121 cases with long-term follow-up. *Clin.Endocrinol.(Oxf)* 2005 Apr;62(4):397-409.
  29. Rajan B, Ashley S, Thomas DG, Marsh H, Britton J, Brada M. Craniopharyngioma: Improving outcome by early recognition and treatment of acute complications. *Int.J.Radiat.Oncol.Biol.Phys.* 1997 Feb 1;37(3):517-21.

30. Kalapurakal JA. Radiation therapy in the management of pediatric craniopharyngiomas--a review. *Childs Nerv.Syst.* 2005 Aug;21(8-9):808-16.
31. Stripp DC, Maity A, Janss AJ, Belasco JB, Tochner ZA, Goldwein JW, et al. Surgery with or without radiation therapy in the management of craniopharyngiomas in children and young adults. *Int.J.Radiat.Oncol.Biol. Phys.* 2004 Mar 1;58(3):714-20.
32. Combs SE, Thilmann C, Huber PE, Hoess A, Debus J, Schulz Ertner D. Achievement of long-term local control in patients with craniopharyngiomas using high precision stereotactic radiotherapy. *Cancer* 2007;109(11):2308-14.
33. Amendola BE, Wolf A, Coy SR, Amendola MA. Role of radiosurgery in craniopharyngiomas: A preliminary report. *Med.Pediatr.Oncol.* 2003 Aug;41(2):123-7.
34. Moon SH, Kim IH, Park SW, Kim I, Hong S, Park CI, et al. Early adjuvant radiotherapy toward long-term survival and better quality of life for craniopharyngiomas--a study in single institute. *Childs Nerv.Syst.* 2005 Aug;21(8-9):799-807.
35. Regine WF, Mohiuddin M, Kramer S. Long-term results of pediatric and adult craniopharyngiomas treated with combined surgery and radiation. *Radiother.Oncol.* 1993 Apr;27(1):13-21.
36. Pemberton LS, Dougal M, Magee B, Gattamaneni HR. Experience of external beam radiotherapy given adjuvantly or at relapse following surgery for craniopharyngioma. *Radiother.Oncol.* 2005 Oct;77(1):99-104.
37. Mottolese C, Szathmari A, Berlier P, Hermier M. Craniopharyngiomas: Our experience in Lyon. *Childs Nerv.Syst.* 2005 Aug;21(8-9):790-8.
38. Caceres A. Intracavitary therapeutic options in the management of cystic craniopharyngioma. *Childs Nerv.Syst.* 2005 Aug;21(8-9):705-18.
39. (Steinbok P, Hukin J. Intracystic treatments for craniopharyngioma. *Neurosurg.Focus* 2010; 28(4):E13.1-E13.6.
40. (Hukin J, Steinbok P, Lafay Cousin L, Henderson G, Strother D, Mercier C, et al. Intracystic bleomycin therapy for craniopharyngioma in children: The Canadian experience. *Cancer* 2007;109(10):2124-31.
41. Savas A, Erdem A, Tun K, Kanpolat Y. Fatal toxic effect of bleomycin on brain tissue after intracystic chemotherapy for a craniopharyngioma: Case report. *Neurosurgery* 2000 Jan;46(1):213-6; discussion 216-7.
42. Hader WJ, Steinbok P, Hukin J, Fryer C. Intratumoral therapy with bleomycin for cystic craniopharyngiomas in children. *Pediatr.Neurosurg.* 2000 Oct;33(4):211-8.
43. Minniti G, Esposito V, Amichetti M, Maurizi Enrici R. The role of fractionated radiotherapy and radiosurgery in the management of patients with craniopharyngioma. *Neurosurg.Rev.* 2009;32(2):125-32.

