

Comparison of the analgesic effects of mepivacaine, xylazine, and mepivacaine-xylazine combination for caudal epidural analgesia in donkeys

Ahmed S. Zohrey¹, Ahmed S. Soliman¹, Abdel-Nasser A. Abdel-Hady², Elhussein E. Mahmoud³, Fatma Abdelhakeem⁴, Fatma A. Madkour^{*4}

¹Department of Surgery, Anesthesiology, and Radiology, Faculty of Veterinary Medicine, Cairo University, Cairo, Egypt.

²Department of surgery, Anesthesiology, and Radiology, Faculty of Veterinary Medicine, Damanhur University, Egypt.

³Department of Surgery, Anesthesiology, and Radiology, Faculty of Veterinary Medicine, South valley university, Qena, Egypt.


⁴Department of Anatomy and Embryology, Faculty of Veterinary Medicine, South Valley University, Qena, Egypt.

*Corresponding author: Fatma A. Madkour.; madkour.f@vet.svu.edu.eg, madkour.fatma@yahoo.com

<https://doi.org/10.21608/svu.2025.355327.1365>

Submit Date, 2025-01-24 22; Revise Date, 2025-04-29, Accept Date 2025-05-05

Copyright: © Ahmed S. Zohrey et al. This is an open access article distributed under the terms of the creative common attribution license, which permits unrestricted use, distribution and reproduction in any medium provided the original author and source are created.



ABSTRACT

The current study aims to evaluate the analgesic and anaesthetic properties of epidurally administered mepivacaine HCl 3%, xylazine HCl 2%, and a combination of both in donkeys. Nine healthy donkeys were treated with three different regimens: mepivacaine HCl 3% alone, xylazine HCl 2% alone, and a combination of mepivacaine HCl and xylazine HCl. The injections were easily administered into the sacrococcygeal space. A morphometric analysis of this region can enhance the epidural anaesthesia technique by offering precise data on needle insertion depth, angle, and key anatomical landmarks. Analgesia was evaluated using superficial and deep muscle pin-prick tests to determine its onset, duration, and affected area. The degree of analgesia was assessed before drug administration (T0) and thereafter at T5, T10, T15, T30, T60 and T120. Additionally, respiratory rate, heart rate, and rectal temperature (°C) were recorded at 0, 5-, 15-, 30-, and 60-min post-injection. The findings of this study demonstrated that the optimal epidural doses for mepivacaine HCl 3% (M), xylazine HCl 2% (X), and their combination (M/X) in donkeys were 10 ml, 6 ml, and 5+3 ml, respectively. The mepivacaine HCl and xylazine HCl combination induced rapid anaesthesia within 1.5–2.25 min, without excitement, providing a prolonged duration of anaesthesia (125±6 min). Post-injection, heart rate remained stable with a slight, non-significant increase, while body temperature insignificantly increased following injection, reaching 37.5 C°. The respiratory rate remained within normal limits across all study groups.

Keywords: Donkey, Epidural Analgesia, Sacrococcygeal Space

INTRODUCTION

The epidural injection of local anaesthetic agents in equine clinical practice was first attempted in Germany more than a century ago to avoid the costs and risks associated with general anaesthesia and recumbency (Hall, 1971). The caudal epidural analgesia is a veterinary technique employed to facilitate diagnostic,

surgical, and obstetric procedures in the perineal region, as well as surgical interventions involving the tail, pelvic organs, and urinary tract in horses, all while the animal remains standing (Dhoble et al., 1990; Fatone et al., 1993; Chen et al., 2004; Skarda et al., 2005; Campoy L. et al., 2015; Babiker et al., 2023). In donkeys, caudal epidural anaesthesia is utilized

for similar indications (Skarda et al., 2005), achieved by injecting local anaesthetic drugs into the first and second intercoccygeal space (Hall, 1971; Burnham, 2002). Conversely, numerous authors (Robinson & Natalini, 2002; Lyon, 2006; Natalini, 2010; Love, 2012; Barton & Sandow, 2020; Hamed et al., 2025) have successfully utilized the sacrococcygeal space for epidural injection. Furthermore, various combinations and adjuvant medications have been employed to extend the duration of action in donkeys (Walker et al., 2002; Natalini, 2010).

Concerning the anaesthetic drugs used for epidural anaesthesia in equines, Mepivacaine HCL 3% (Carbocaine™) is a local anaesthetic drug widely used in epidural anaesthesia in equines (Harkins et al., 1999; Katzung, 2007; Natalini & Driessen, 2007). Mepivacaine exerts its effect by reducing the influx of sodium ions into cells, thereby decreasing the neuron's ability to depolarize and transmit nerve impulses (Bidwell et al., 2004). Xylazine is a non-narcotic compound utilized for sedation, pain relief, and muscle relaxation in veterinary medicine (Nunez et al., 2021). Furthermore, the latter authors found that Xylazine has a highly lipophilic nature; it directly stimulates central α_2 -adrenergic receptors as well as peripheral α -adrenergic receptors in a variety of tissues. It also decreases the release of neurotransmitters norepinephrine and dopamine in the central nervous system, contributing to its analgesic and anaesthetic effects (Ruiz-Colón et al., 2014). Xylazine HCL 2% (xyla-ject) is also employed for epidural analgesia in equines (Schwinn et al., 1991; Chevalier et al., 2004; Alkattan et al., 2012). The latter provides prolonged analgesia and sedation, making it suitable for routine surgical procedures, with only minor ataxia due to its mild effect on the hind limbs (England & Clarke, 1996; Ismail et al., 2018).

This study aimed to assess the effectiveness of epidural anaesthesia in donkeys by evaluating and identifying the most suitable anaesthetic drugs for epidural administration based on their analgesic

efficacy. Furthermore, it sought to determine the optimal injection sites for epidural analgesia and monitor associated changes in vital parameters following its administration in donkeys.

MATERIALS AND METHODS

All experiments were conducted following the guidelines and approval of the Animal Ethical Committee, Faculty of Veterinary Medicine, South Valley University (SVU), Qena, Egypt. Animals

This study utilized nine healthy local breed donkeys, aged 5-8 years, with a mean weight of 95 ± 8 kg, and both sexes. The animals were housed at the Faculty of Veterinary Medicine, South Valley University, during the study.

The donkeys were kept under standardized management and nutritional conditions, and fasting protocols were implemented with food withheld for at least 12 hrs and water for at least 2 hrs before induction of epidural anaesthesia.

Posterior epidural injection of local anaesthetic drugs

The donkeys were randomly assigned to one of three treatment groups as follows:

1. Group I (M): Received 3% Mepivacaine HCL (Mepecaine 3%®, Alexandria Company for Pharmaceuticals) at a dose of 3 mg/kg, administered in a 10 ml volume.
2. Group II (X): Received 2% Xylazine HCL (Xyla-ject®, ADWIA Co., 10th of Ramadan City, Egypt) in a 6 ml dose.
3. Group III (MX): Received a combination of 3% Mepivacaine HCL and 2% Xylazine HCL, administered in a 5+3 ml volume.

The sacrococcygeal area (injection site) was prepared by clipping, shaving, and aseptic cleaning with povidone-iodine. The donkeys were restrained in a standing position. A single injection was administered through an 18-gauge needle inserted into the sacrococcygeal space at a 45° angle. The needle was then removed, and the site was monitored for any signs of complications. Furthermore, the animals were monitored for 60 min post-injection for any adverse reactions.

Clinical evaluation

Post-epidural injection, the donkeys were monitored to describe the signs, onset and duration of analgesia along with limb status and the desensitized area. Respiratory rate (breaths/min), heart rate (beats/min), and rectal temperature ($^{\circ}\text{C}$) were recorded at 0, 5, 15-, 30- and 60-min post-injection which was evaluated by observation the reflex of anus, perineal region, thigh, and medial-lateral sides of the proximal and distal regions of the hind limbs using superficial and deep muscle pin-prick.

The reflexes were noticed closely and reported immediately according to the previously mentioned (Abdel-Hady et al., 2017) and represented as follows:

- +++ Normal reflex
- ++- Sluggish reflex
- +-- Very sluggish reflex
- Abolished reflex

Scoring of analgesia for Mepivacaine, Xylazine, and Mepivacaine-Xylazine combination was shown in Table 2.

Gross anatomy and morphometric analysis

A month after induction of epidural anaesthesia, all donkeys were euthanized with xylazine and magnesium sulphate I/V and the sacrococcygeal region was carefully separated from the body and dissected with a scalpel and forceps. After dissection, the region was cut sagittally using a manual saw (Madkour & Abdelsabour-Khalaf, 2021). Moreover, the photographs

were taken via a Samsung Phone camera (Samsung Galaxy A52s5G/SM-528BZWOMEA).

The gross morphological measurements were obtained using ImageJ software (available at <http://Fiji.sc/Fiji>). These measurements are described and presented in Table 3.

STATISTICAL ANALYSIS

All data were analyzed by ANOVA (analysis of variance) and Duncan's test using SPSS software. For data analysis, all values were calculated and expressed as the mean \pm standard deviation (SD) using the Statistical Package for Social Sciences (SPSS) software, version 17.0.

RESULTS

Evaluation of epidural anaesthesia of the selected drugs

The onset of anaesthesia was significantly faster with mepivacaine HCl 3% alone and the mepivacaine HCl 3% - xylazine HCl 2% combination compared to xylazine HCl 2% alone. Conversely, the longest duration of anaesthesia was measured with the mepivacaine-xylazine combination, surpassing that of both mepivacaine and xylazine alone.

The onset and duration of anaesthesia varied among the three groups as shown in Figure 1. Mepivacaine alone induced anaesthesia within 1.25–2.5 minutes, lasting 65 ± 8 minutes. Xylazine had a slower onset (3.5–5.5 minutes) but a longer duration (103 ± 4 minutes). The mepivacaine-xylazine combination provided a rapid onset of anaesthesia (1.5 – 2.25 minutes) with the longest duration (125 ± 6 minutes).

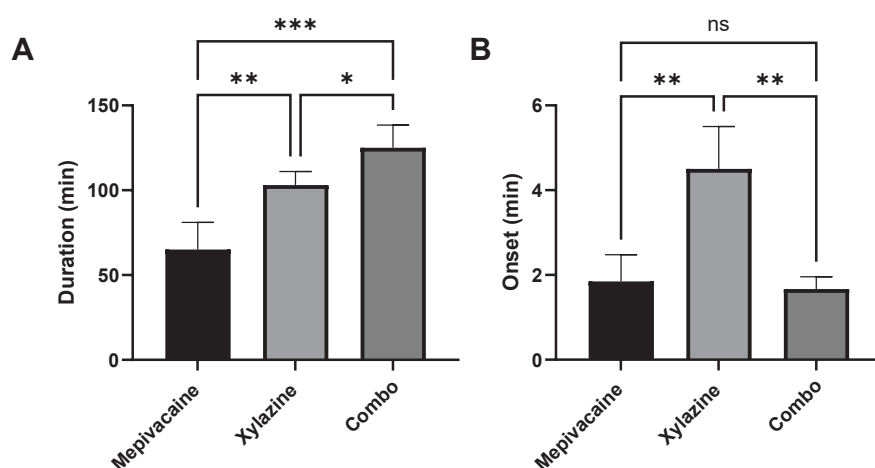


Figure 1: Evaluation of the duration and the onset of the anaesthesia for Mepivacaine HCL, Xylazine HCL, and Mepivacaine HCL Xylazine HCL injected by a dose of 10 ml, 6 ml, and 5 ml + 3 ml (combo)

Table 1: Physiological parameters: mean (\pm SD) respiratory rate, heart rate, and rectal temperature in donkeys after administration of Group I (3% Mepivacaine HCl), Group II 2% Xylazine HCl, and a combination of Mepivacaine and Xylazine

Time point	Group	Respiratory rate	Heart rate	Rectal Temperatures
Zero	Group I	15.06 \pm 1	45 \pm 1	37.01 \pm 0.01
	Group II	15 \pm 1	45 \pm 0.3	37.03 \pm 0.02
	Group III	16 \pm 1*	46.05 \pm 0.5*	37.01 \pm 0.01
5	Group I	15 \pm 1	45 \pm 0.3	37.01 \pm 0.01
	Group II	15 \pm 1	44 \pm 1	37.03 \pm 0.02*
	Group III	16.05 \pm 0.5*	46 \pm 0.5	37 \pm 0.01
15	Group I	13 \pm 1	45 \pm 0.3	37.01 \pm 0.01
	Group II	15 \pm 1	45.05 \pm 0.5*	37.02 \pm 0.01
	Group III	16 \pm 1	45.05 \pm 0.5	37.02 \pm 0.02
30	Group I	17 \pm 1	45 \pm 0.3	37.02 \pm 0.01
	Group II	15.05 \pm 1.5	45 \pm 1	37.02 \pm 0.01
	Group III	14.05 \pm 0.5*	45 \pm 1	37.01 \pm 0.02
60	Group I	14.05 \pm 0.5	45 \pm 0.3	37
	Group II	14 \pm 1	45 \pm 1	37.01 \pm 0.02
	Group III	14	45 \pm 1	37.03 \pm 0.02
After recovery	Group I	13.05 \pm 0.5	44	37
	Group II	14.05 \pm 0.5	44.03	37
	Group III	13.05 \pm 0.5	44.05 \pm 0.05	37.01 \pm 0.01

Both Xylazine, and Mepivacaine-Xylazine combination cause loss of tail muscle tone, anal sphincter relaxation, and complete loss of response to pinprick stimulation in the tail, anus, perineal region up to the second lumbar vertebrae, thigh, and hind limbs up to the hock joint. In contrast, Mepivacaine anaesthesia anaesthetized the tail, anus, perineal region up to the third lumbar vertebrae, and thigh. Throughout the study, all donkeys remained standing from the onset of analgesia to full recovery without experiencing any adverse reactions.

The heart rate exhibited a slight, insignificant increase after injection, stabilizing until the end of the experiment (60 minutes post-injection) across all groups. Respiratory rate and rectal temperature remained unchanged, showing no significant variations throughout the study (Table 1).

Gross anatomy and morphometric analysis

The epidural administration of local analgesic drugs was easily injected in the sacrococcygeal space in all donkeys by monitoring a negative pressure and minimal resistance to injection.

A morphometric study of the sacrococcygeal region in donkeys provides vital anatomical data that can help surgeons improve the safety and efficacy of procedures like epidural anaesthesia, surgical interventions, and diagnostic imaging. The study's findings can be used to refine the technique for epidural anaesthesia by providing more accurate data on needle insertion depth, angle, and safe anatomical landmarks. The sacrococcygeal space is suitable for epidural anaesthesia, as the space between the fifth sacral and first caudal vertebral spines is wide (Figure 2A, B), allowing the anaesthetic to be injected easily. As shown in Table 3 at this site, a larger diameter of the vertebral canal is observed (Figure 2C, D). In addition to the aforementioned, the tail muscles are fewer, and the spines of the sacral and coccygeal vertebrae are more

Table 2: Analgesia scores (0–3; means \pm SD) in donkeys administered different drugs epidurally

Mepivacaine HCl +xylazine Hcl	Xylazine Hcl2%	Mepivacaine HCl 3%	Observation times (min)
0	0	0	T0
0.75	1.2	1.8	T5
1.7	1.4 \pm .1	2.5 \pm .2*	T10
2.1*	2.5 \pm .2*	2.8 \pm .1*	T15
3	3	3	T30
3	3	2.9 \pm .1	T60
3	3	0	T120

*Indicates significance at $P \leq 0.05$ when compared to T0 within the same treatment group.

Table 3: Morphometric measurements of the vertebral canal within the sacrococcygeal region

Items	Mean	SD
Length from last sacral vertebra to 3rd caudal vertebrae	62.08 mm	1.49
Diameter of vertebral canal at level of: -Sacrococcygeal space	1.81 mm	0.25
-1st Intercoccygeal space	1.13 mm	0.18

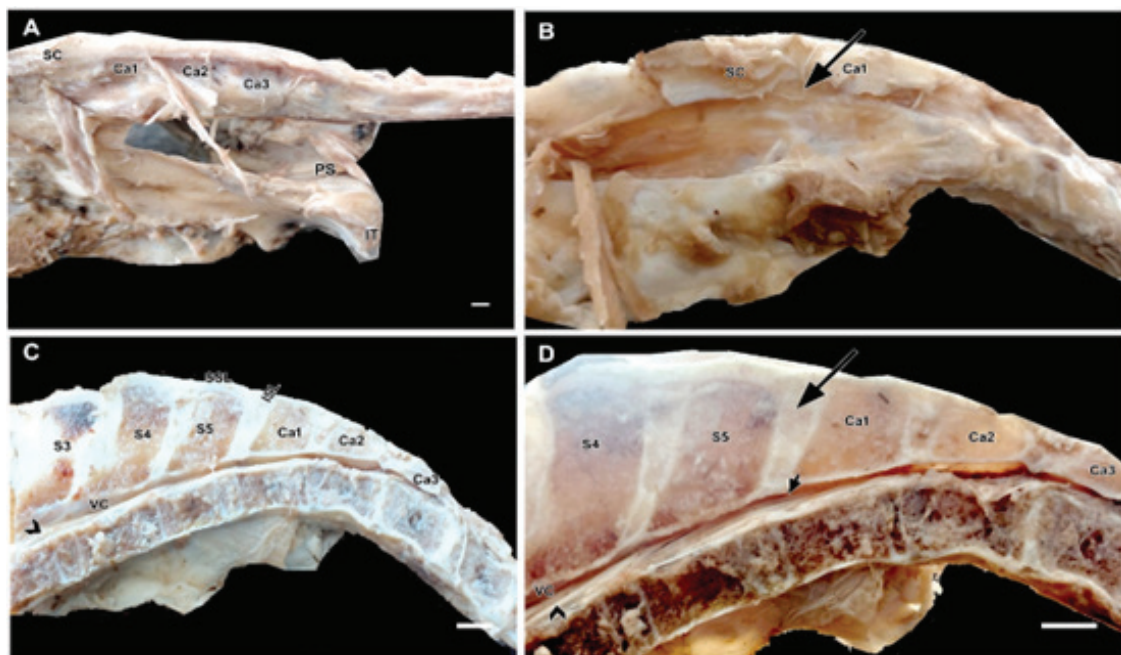


Figure 2: Dorsolateral view of the sacrococcygeal region (A, B) and sagittal section view of the sacrococcygeal region (C, D) in donkey showing: sacrum (SC), spines of 3rd sacral (S3), 4th sacral (S4), 5th sacral (S5), 1st caudal (Ca1), 2nd caudal (Ca2), 3rd caudal (Ca3) vertebrae, cauda equine (arrowhead), supraspinous (SSL), interspinous (ISL) ligaments, epidural space (short arrow), vertebral canal (VC).

easily palpated in donkeys, making the sacrococcygeal space suitable for the procedure (Figure 2 A-d).

DISCUSSION

The primary objective of this study is to investigate and compare the efficacy of various analgesic drugs in achieving optimal anaesthesia while minimizing postoperative adverse effects, with consideration for economic viability. Additionally, this study aims to determine the ideal site of injection for caudal epidural anaesthesia in donkeys. In the present work, the sacrococcygeal space was more convenient and efficient compared with the first inter-coccygeal space for epidural injection in donkeys. A fact agreed with many authors (Dhoble et al., 1990; Robinson & Natalini, 2002; De Rossi et al., 2003; Lyon, 2006; DeRossi et al., 2010; Natalini, 2010; Love, 2012; Barton & Sandow, 2020; Hamed et al., 2025) mentioned that the injection through sacrococcygeal can reduce the risk of inadvertent injection in the subarachnoid space as well as the risk of motor blockade of the pelvic limbs.

Mepivacaine HCl (Carbocaine-V) is a recommended epidural anaesthetic for donkeys, which is in agreement with previous reports that have demonstrated its efficacy and safety in this species (Zoetis, 2019). The results obtained with Mepivacaine HCl showed a rapid onset of anaesthesia, accompanied by effective muscle relaxation, which is in line with findings reported by several other authors (Skarda & Muir, 1983; Skarda et al., 1984; Suzuki et al., 2019), who also reported that the Mepivacaine HCl gave a long duration of action.

The findings in Group I (mepivacaine HCl), where the heart rate exhibited an insignificant increase, align with Roman T. Skarda (2009). This minor fluctuation in heart rate is expected with mepivacaine, as it is primarily a local anaesthetic with minimal systemic cardiovascular effects. The stability of heart rate after injection suggests that mepivacaine did not induce significant autonomic or hemodynamic alterations. On the other hand, the administration of xylazine HCl in Group II resulted in a long duration of anaesthesia, consistent with Makady et al. (1991), Skarda & Muir (1996), and Abid (2002). This prolonged effect can be attributed to xylazine's α_2 -adrenergic agonist

properties, which lead to central nervous system depression, analgesia, and muscle relaxation. Xylazine's ability to extend the duration of anaesthesia is particularly beneficial in surgical and obstetrical procedures as observed in previous studies (Abid, 2002). Our observations, along with those of the latter author, confirm that the effect of xylazine HCl extended to the second lumbar vertebrae. This finding aligns with previous research, suggesting that xylazine's epidural administration leads to a widespread analgesic effect, which is sufficient to make obstetrical and surgical innervations.

Furthermore, anaesthesia with xylazine led to an insignificant increase in heart rate, which remained stable at 60 minutes post-injection, while the respiratory rate remained within normal limits. These findings are consistent with the results reported by Alkattan et al. (2012) and Khalil et al. (2022), reinforcing the safety and stability of xylazine-induced anaesthesia in donkeys. The low molecular weight of xylazine facilitates meningeal penetration when administered epidurally, enhancing its sedative, anaesthetic, and cardiorespiratory depressant effects. This mechanism, as described by several scholars (Robinson & Natalini, 2002; Alkattan et al., 2012), contributes to its effective and prolonged analgesic action, making it a reliable choice for epidural anaesthesia in large animals. In Group III, the available literature presents limited studies on the combination of mepivacaine HCl and xylazine HCl for epidural anaesthesia. However, the present study in donkeys demonstrated complete epidural analgesia, characterized by loss of tail muscle tone, relaxation of the anal sphincter, and absence of response to pinprick stimulation in the tail, anus, perineal region, thigh, and hind limbs up to the hock joint. These findings align with previous reports in which the mepivacaine-xylazine combination was effectively used to facilitate surgical procedures, including the removal of a descended testis, highlighting its efficacy and broad anaesthetic coverage.

CONCLUSION

This study demonstrates that the sacrococcygeal space is a more practical and safer site for epidural injection in donkeys compared to the first intercoccygeal space. Our findings indicate that the combination

of Mepivacaine HCl 3% and Xylazine HCl 2% (Group III) provides optimal analgesia, making it the most effective choice for various surgical interventions in donkeys. This combination ensures a smooth recovery and minimal impact on vital parameters. Xylazine HCl alone is a suitable alternative, while Mepivacaine HCl 3% is the least favourable option for epidural analgesia in donkeys. All drugs are safe for donkeys.

Availability of data and materials: On the reasonable request from the corresponding author.

Competing interests: No competing interests.

Funding: No fund

Author' contributions: **Ahmed S. Zohrey:** Conceptualization; data curation; formal analysis; methodology; writing–original draft; writing–review and editing. **Fatma A. Madkour:** Conceptualization; data curation; formal analysis; methodology; writing–review and editing. **Ahmed S. Soliman, Abdel-Nasser A. Abdel-Hady:** Conceptualization; data curation; formal analysis and writing–original draft. **Elhussein E. Mahmoud and Fatma Abdelhakeem:** Formal analysis; methodology and visualization.

REFERENCES :

- Abdel-Hady, A. A. A., Abdelbasset, K. M. & Soliman, A. S. (2017). Comparative experimental study on two designed intravenous anaesthetic combinations in dogs. *Excli j*, 16: 770-779. <https://doi.org/10.17179/excli2017-298>
- Abid, T. A. (2002). Caudal epidural injection of xylazine in cattle. *Al-Qadisiya J Vet Med Sci*, 2: 32-33.
- Alkattan, L., Layth, M. & Alkattan, L. (2012). Analgesia and anesthesia with epidural Xylazine/Ketamine in donkeys. *Diagnostic and Therapeutic Study*, 1(2): 37-44.
- Babiker, Y. O. H., Najmi, M. H. S., Muslihi, I. M. A., Amri, A. F. M., Magafi, T. Y. M., Alughbi, W. M. H., . . . Abdelwahab, S. I. (2023). Knowledge and Attitudes towards Epidural Analgesia among Women of Childbearing Age in Jazan, Saudi Arabia: A Community-Based Cross-Sectional Study to Identify Predictors through Multivariate Modeling. *Healthcare (Basel)*, 11(4). <https://doi.org/10.3390/healthcare11040626>
- Barton, C. & Sandow, C. (2020). *Surgery STAT: How to perform a caudal epidural in horses*.
- Bidwell, L. A., Brown, K. E., Cordier, A., Mullineaux, D. R. & Clayton, H. M. (2004). Mepivacaine local anaesthetic duration in equine palmar digital nerve blocks. *Equine Vet J*, 36(8): 723-726. <https://doi.org/10.2746/0425164044848154>
- Burnham, S. L. (2002). *Anatomical differences of the donkey and mule*. AAEP proceedings.
- Campoy L., M., R. & S., P. (2015). Canine and feline local anesthetic and analgesic techniques. In: Grimm K.A., Lamont L.A., Tranquilli W.J., Green S.A., Robertson S.A. (eds.). *Veterinary Anesthesia and Analgesia*. Fifth edition, Lumb and Jones. Fifth ed, Wiley Blackwell, Iowa, USA, p 827-856.
- Chen, C. P., Tang, S. F., Hsu, T. C., Tsai, W. C., Liu, H. P., Chen, M. J., . . . Lew, H. L. (2004). Ultrasound guidance in caudal epidural needle placement. *Anesthesiology*, 101(1): 181-184. <https://doi.org/10.1097/00000542-200407000-00028>
- Chevalier, H. M., Provost, P. J. & Karas, A. Z. (2004). Effect of caudal epidural xylazine on intraoperative distress and post-operative pain in Holstein heifers. *Vet Anaesth Analg*, 3 .10-1 :(1)1 <https://doi.org/10.1111/j.1467-2995.2004.00140.x>
- De Rossi, R., Bucker, G. V. & Varela, J. V. (2003). Perineal analgesic actions of epidural clonidine in cattle. *Vet Anaesth Analg*, 30(2): 63-70. <https://doi.org/10.1046/j.1467-2995.2003.00089.x>
- DeRossi, R., Ruzzon, R. H., Verde-Selva, A. B. & Bertoni, R. A. (2010). Evaluation of segmental dorsolumbar epidural analgesia with ketamine hydrochloride administered by use of nonstyletted multiple-port catheters via the caudal approach in cattle. *Am J Vet Res*, 71(1): 17-23. <https://doi.org/10.2460/ajvr.71.1.17>
- Dhoble, R., Sharma, S., Vashista, N., Singh, M. & Singh, M. (1990). Rectal prolapse in a donkey associated with heavy strongyle infestation. *Ind. Vet. J.*, G7: 108 2.
- England, G. C. & Clarke, K. W. (1996). Alpha 2 adrenoceptor agonists in the horse--a review. *Br Vet J*, 152(6): 641-657. [https://doi.org/10.1016/s0007-1935\(96\)80118-7](https://doi.org/10.1016/s0007-1935(96)80118-7)
- Fatone, S., Edens, L. & McElhaney, B. (1993). Challenging cases in internal medicine: what's your diagnosis?[epidural haemangiosarcoma]. *Vet. Med.*, 88: 1039- 1044.

- Hall, L. W. (1971). Spinal Analgesia. In: Hall LW, editor. Wright's Veterinary Anaesthesia and Analgesia. 7th ed. London: Bailliere Tindall. p. 102-103.
- Hamed, M. A., Hamouda, H., Elmetwally, M., Farrag, F., Rizk, M. A., Abumandour, M. M. A., ... Samy, A. (2025). Comparative experimental anesthesia efficacy study of epidural injection at the sacrococcygeal space using ultrasound guidance versus blindness technique in Egyptian donkeys (*Equus asinus*). *BMC Vet Res*, 21(1): 57. <https://doi.org/10.1186/s12917-025-04475-8>
- Harkins, J. D., Karpiesiuk, W., Woods, W. E., Lehner, A., Mundy, G. D., Rees, W. A., . . . Tobin, T. (1999). Mepivacaine: its pharmacological effects and their relationship to analytical findings in the horse. *J Vet Pharmacol Ther*, 22(2): 107-121. <https://doi.org/10.1046/j.1365-2885.1999.00189.x>
- Ismail, Z., Abu-Basha, E., Alzghoul, A., Salah, A. & Al-Zoubi, I. (2018). Epidural co-administration of neostigmine and lidocaine or xylazine enhances systemic sedation but not perineal analgesia in adult dairy cows. *Veterinárni medicína*, 63(.7
- Katzung, B. G. (2007). "Local Anesthetics." Basic & Clinical Pharmacology. 10th ed. United States McGraw-Hill Medical.
- Khalil, A., Abd Al Galil, A., Zeineldin, M., Abo-Korae, S. & Sabek, A. (2022). Sedative, analgesic and behavioral changes of caudal epidural injection of xylazine, magnesium sulphate in Egyptian water buffalo (*Bubalus bubalis*). *Mansoura Veterinary Medical Journal*, 23(1): 1-9.
- Love, E. J. (2012). Equine pain management. *Equine Surgery* 4th Edition, Amsterdam: Elsevier: 263-270.
- Lyon, L. (2006). Local anesthesia&analgesia , <https://www.Western.edu/mediafiles/veterinary/vet>.
- Madkour, F. & Abdelsabour-Khalaf, M. (2021). Gross anatomical and morphometrical study of the nasal cavity (cavum nasi) of Egyptian goat (*Capra hircus*) and Egyptian Baladi dog (*Canis lupus*). *SVU-InternationalJournalofVeterinarySciences*, 4(3):80-93. <https://doi.org/10.21608/svu.2021.86098.1134>
- Makady, F., SELEIM, S. M., Seleim, M. & ABDEL ALL, T. S. (1991). Comparison of lidocaine and xylazine as epidural analgesics in donkeys .*Assiut Veterinary Medical Journal*, 25(49): 189-195.
- Natalini, C. C. (2010). Spinal anesthetics and analgesics in the horse. *Veterinary clinics: equine practice*, 26(3): 551-564.
- Natalini, C. C. & Driessen, B. (2007). Epidural and spinal anesthesia and analgesia in the equine. *Clinical Techniques in Equine Practice*, 6(2): 145-153.
- Nunez, J., DeJoseph, M. E. & Gill, J. R. (2021). Xylazine, a Veterinary Tranquilizer, Detected in 42 Accidental Fentanyl Intoxication Deaths. *Am J Forensic Med Pathol*, 42(.11-9 :(<https://doi.org/10.1097/paf.0000000000000622>
- Robinson, E. P. & Natalini, C. C. (2002). Epidural anesthesia and analgesia in horses. *Vet Clin North Am Equine Pract*, 18(1): 61-82, vi. [https://doi.org/10.1016/s0749-0739\(02\)00010-x](https://doi.org/10.1016/s0749-0739(02)00010-x)
- Roman T. Skarda, H .,John A.E. (2009). Equine anesthesia: monitoring and emergency therapy, elsevier Health sciences.
- Ruiz-Colón, K., Chavez-Arias, C., Díaz-Alcalá, J. E. & Martínez, M. A. (2014). Xylazine intoxication in humans and its importance as an emerging adulterant in abused drugs: A comprehensive review of the literature. *Forensic Sci Int*, 240: 1-8. <https://doi.org/10.1016/j.forsciint.2014.03.015>
- Schwinn, D. A., Correa-Sales, C., Page, S. O. & Maze, M. (1991). Functional effects of activation of alpha-1 adrenoceptors by dexmedetomidine: in vivo and in vitro studies. *J Pharmacol Exp Ther*, 259(3): 1147-1152.
- Skarda, R., Grosenbaugh, D. & Muir, W. (2005). Caudal regional anaesthesia in horses. *Equine Veterinary Education*, 15(S7): 108-116.
- Skarda, R. T. & Muir, W .(1996) .Analgesic, hemodynamic, and respiratory effects of caudal epidurally administered xylazine hydrochloride solution in mares. *Am J Vet Res*. 57:193 – 200. .
- Skarda, R. T. & Muir, W. W. (1983). Segmental epidural and subarachnoid analgesia in conscious horses: a comparative study. *Am J Vet Res*, 44(10): 1870-1876.
- Skarda, R. T., Muir, W. W. & Ibrahim, A. I. (1984). Plasma mepivacaine concentrations after caudal epidural and subarachnoid injection in the horse: comparative study. *Am J Vet Res*, 45(.1971-1967 : (10
- Suzuki, S., Gerner, P. & Lirk, P. (2019). Local anesthetics. *Pharmacology and Physiology for Anesthesia*, Elsevier: 390-411.

Walker, S. M., Goudas, L. C., Cousins, M. J. & Carr, D. B. (2002). Combination spinal analgesic chemotherapy: a systematic review. *Anesth Analg*, 95(3): 674-715. <https://doi.org/10.1097/00000539-200209000-00033>

Zoetis (2019). Inc. Kalamazoo, MI 49007, 4020551 - PH 1085A&P. .