



## Evaluation of Dose Dependent Chemopreventive Effect of Diosmin on Induced Oral Squamous Cell Carcinoma

Menna-tallah K. Osman <sup>1\*</sup>, Amany M. Taha <sup>2</sup>, Nadia A. Radi <sup>3</sup>, Eman A. AboHager <sup>4</sup>

Codex : 14/22.07

azhardentj@azhar.edu.eg

http://adjg.journals.ekb.eg

DOI: 10.21608/adjg.2022.72736.1352

Oral Medicine & Surgical Sciences  
(Oral Medicine, Oral & Maxillofacial  
Surgery, Oral Pathology, Oral Biology)

### ABSTRACT

**Purpose:** This study aimed to evaluate the chemoprevention efficacy of diosmin on experimentally induced hamster buccal pouch (HBP) squamous cell carcinoma utilizing Ki 67 as a proliferative marker. **Material and Methods:** Seventy Syrian male hamsters were used as experimental animals, these hamsters were divided into five groups, Group I (negative control): 5 hamsters were left untreated. Group II (DMBA treated group): 20 hamsters were divided equally into two subgroups, painted with 0.5% DMBA where subgroup IIa: for 8 weeks while subgroup IIb: for 14 weeks. Group III: 5 hamsters were orally administrated diosmin 150 mg/kg for 14 weeks. Group IV: 20 hamsters were divided equally into two subgroups, treated with diosmin 100mg/kg and DMBA where subgroup IVa: for 8 weeks while subgroup IVb: for 14 weeks. Group V: 20 hamsters were divided equally into two subgroups, treated with diosmin 150mg/kg and DMBA where subgroup Va: for 8 weeks while subgroup Vb: for 14 weeks. **Results:** Comparing all groups and subgroups revealed that the mean values have been arranged with the following descending pattern subgroup IIa, subgroup Va, subgroup IIb, subgroup Vb, subgroup IVb, subgroup IVa, group III and group I. ANOVA test revealed a statistically significant difference between groups. **Conclusion:** Diosmin 100mg/kg is considered a promising chemopreventive agent in preventing induced HBP squamous cell carcinoma.

### KEYWORDS

Diosmin, DMBA,  
Squamous cell carcinoma, Ki 67

- A paper extracted from a thesis titled “Evaluation of Dose Dependent Chemopreventive Effect of Diosmin on Induced Oral Squamous Cell Carcinoma”
- 1. Demonstrator of Oral and Dental Pathology. Faculty of Dental Medicine. Modern Sciences and Arts University (M.S.A.), Giza, Egypt.
- 2. Lecturer of Oral and Dental Pathology. Faculty of Dental Medicine for Girls, Al Azhar University, Cairo, Egypt.
- 3. Associate Professor of Oral and Dental Pathology. Faculty of Dental Medicine for Girls, Al Azhar University, Cairo, Egypt.
- 4. Professor of Oral and Dental Pathology. Faculty of Dental Medicine for Girls, Al Azhar University, Cairo, Egypt.

\* Corresponding author email: menna-tallahkamal@azhar.edu.eg

## INTRODUCTION

Cancer occurrence involves several steps requiring the accumulation of the defects of genetic and epigenetic factors as well as the clonal expansion of these affected cells resulting in their abnormal expression, growth rate and function <sup>(1,2)</sup>. A lot of predisposing factors can increase the incidence for the oral cancer occurrence as tobacco in its various ways smoked, smokeless, alone or in combination with alcohol drinking, viruses especially the human papilloma virus and oral potentially malignant lesions <sup>(3)</sup>.

Oral cancer usually starts with transforming the normal keratinocytes of the oral cavity into unstable keratinocytes with the ability to transform into altered potentially malignant cells considering the histological evaluation of these altered cells as a warning sign of the possibility of finally turning into malignant neoplastic cells, this can be expressed by their cytogenetic alterations and epigenetic factors causing the modification of the cell cycle progression, mechanisms of the repair of DNA, differentiation of cells and their apoptosis <sup>(3,4)</sup>.

In Egypt there are approximately 4,500 individuals diagnosed with oral cancer annually <sup>(4)</sup>. Nearly 92 to 95% of all oral malignant neoplasms are oral squamous cell carcinomas <sup>(1)</sup>. Oral squamous cell carcinoma is derived from normal keratinocytes that are exposed to a chronic stimulus that disturbed their homeostasis causing the proliferation of the epithelium then its alteration with the dysplastic features in its various degrees then turning into carcinoma in situ that has a very high potential to finally turn into frank invasive carcinoma <sup>(3,4)</sup>. As oral squamous cell carcinoma tends to send metastasis through the lymph it should be detected as soon as possible <sup>(3)</sup>.

The animal model choice is highly important in the identification of the etiology of several human diseases as well as testing new drugs before trying them on humans, so regarding oral squamous cell

carcinoma they are important in the identification and understanding the abnormal stages that occur before carcinoma to understand the factors that contribute in the process of carcinogenesis <sup>(5)</sup>. Regarding the animal model used in oral squamous carcinoma is the hamster due to the hamster's immunoprivileged cheek pouch as the molecular and cellular changes of oral cancer that occur in the hamster is similar to that occurring in human <sup>(6)</sup>.

The carcinogen 7, 12 Dimethylbenz[a]anthracene (DMBA) is known to cause squamous cell carcinomas in hamsters that is similar in its morphology, histology and even genetically to that observed in humans <sup>(6)</sup>. Cancer chemoprevention can be defined as giving natural, artificial or biological agents to decrease or slow down the malignancy incidence or even prevent its further progression <sup>(7)</sup>.

Flavonoids intake was proven to decrease the risk of developing cancer as they pose various chemopreventive mechanisms as hindering the development of new neoplastic cells, preventing various carcinogens from reaching their activation sites or inhibiting the metabolism of various carcinogenic compounds so decreasing their toxicity effect, they also have molecular mechanisms such as inducing apoptosis, arresting cell cycle at G1 or G2/M phase and others <sup>(8)</sup>.

Diosmin (3',5,7-trihydroxy-40-methoxyflavone-7-rhamnoglucoside) is an unsaturated glycoside flavone, a member of flavonoid family that can be easily obtained from several citrus fruits and plant lemon leaves, it was isolated from *Scrophularia Nodosa* plant to be used as a therapeutic agent since 1969 <sup>(9)</sup>. It has several biological activities as being anti lipid peroxidation, antioxidant, anti-inflammatory, anti-hyperglycemic and antimutagenic. It was also proven that it can restore the level of antioxidant enzymes therefore able to prevent the oxidation stress and decrease the DNA disintegration <sup>(10)</sup>.

Ki 67 is a nuclear proliferation marker protein that is expressed in cells that are proliferating from

G1 to M phase in the cell cycle decreasing in the late phases of mitosis and is absent in the non-proliferating G0 resting phase and as cell proliferation is a vital biological aspect in tumor diagnosis Ki 67 has proven to play an important role in neoplasm diagnosis due to its a positive correlation with the proliferation of neoplasm and its invasion providing an indication for cell proliferation and a marker for neoplasm aggressiveness which is reflected by neoplasm grade and stage helping in the selection of a proper treatment <sup>(11)</sup>.

## MATERIALS AND METHODS

The experimental animals used were golden Syrian hamsters. Seventy animals, five weeks old and weighing about 80-120g were obtained from the animal house in Cairo, Egypt. Hamsters were housed in show box cages at the experimental animal unit in Nasr City (Cairo-Egypt) under controlled environmental conditions. All hamsters were fed standard diet and watered libitum. The experiment was conducted according to the ethical and research committee protocol of the Faculty of Dental Medicine for Girls, Al-Azhar University (REC-PA-21-01). DMBA, 0.5% was obtained from Sigma-aldrich Company, dissolved in paraffin oil (0.06-1.5%) and administrated by painting using a number 4 camel's hair brush. Diosmin was obtained from Marcyrl import and export company, prepared with two doses 100mg/kg and 150mg/kg, dissolved in 0.5% dimethyl sulfoxide and was orally administrated. Several investigations were done including hematoxylin and eosin (H&E) staining and immunohistochemical (IHC) staining utilizing antibody against Ki 67.

### Experimental design

After a week of adaptation, the animals were divided randomly into five groups. In group I five hamsters weren't treated, serving as negative controls. In group II (DMBA treated positive control group) twenty hamsters were divided equally into

two subgroups, the right HPB were painted with 0.5% DMBA in paraffin oil using a number 4 camel hair brush three times a week with subgroup IIa for 8 weeks, while subgroup IIb for 14 weeks. In group III five hamsters were treated with diosmin 150mg/kg dissolved in 0.5% DMSO and was orally given to the hamsters through gavage tube for 14 weeks. In group IV twenty hamsters were divided equally into two subgroups, treated with Diosmin 100mg/kg and DMBA starting with diosmin one week before the exposure to DMBA and continuing on alternate days with the DMBA painting where subgroup IVa was for 8 weeks, while subgroup IVb was for 14 weeks. In group V twenty hamsters were divided equally into two subgroups, treated with diosmin 150mg/kg and DMBA starting with diosmin one week before the exposure to the DMBA and continuing on alternate days with the DMBA painting where subgroup Va was for 8 weeks, while subgroup Vb was for 14 weeks.

### Investigations

The hamsters were sacrificed on the terminating period of the experiment by cervical decapitation under anesthetic conditions (Xylazine 30 mg/kg. i.p.). The buccal cheek pouches were excised then fixed in 10% neutral buffered formalin, processed routinely and then embedded in paraffin blocks for the preparation so that it could be examined histologically and immunohistochemically.

### Regarding the histological examination

The specimens that were fixed in buffered solution for twenty-four hours were then washed with ethanol of concentration seventy percent so that any fixative can be removed before continuing the processing then they were dehydrated in an ascending ethanol series with concentration eighty percent, ninety percent, hundred percent and finally another round of hundred percent ethanol to remove any water in the tissue, they were then inserted in methyl benzoate and were finally embedded in paraffin wax for nearly three hours to form the

paraffin blocks. Several longitudinal and transversal sections of the tissue were cut into 4 $\mu$ m thick using microtome, mounted on the slides, processed and stained with hematoxylin and eosin (H&E) *stain* for light microscopic examination<sup>(12)</sup>.

### Immunohistochemical analysis

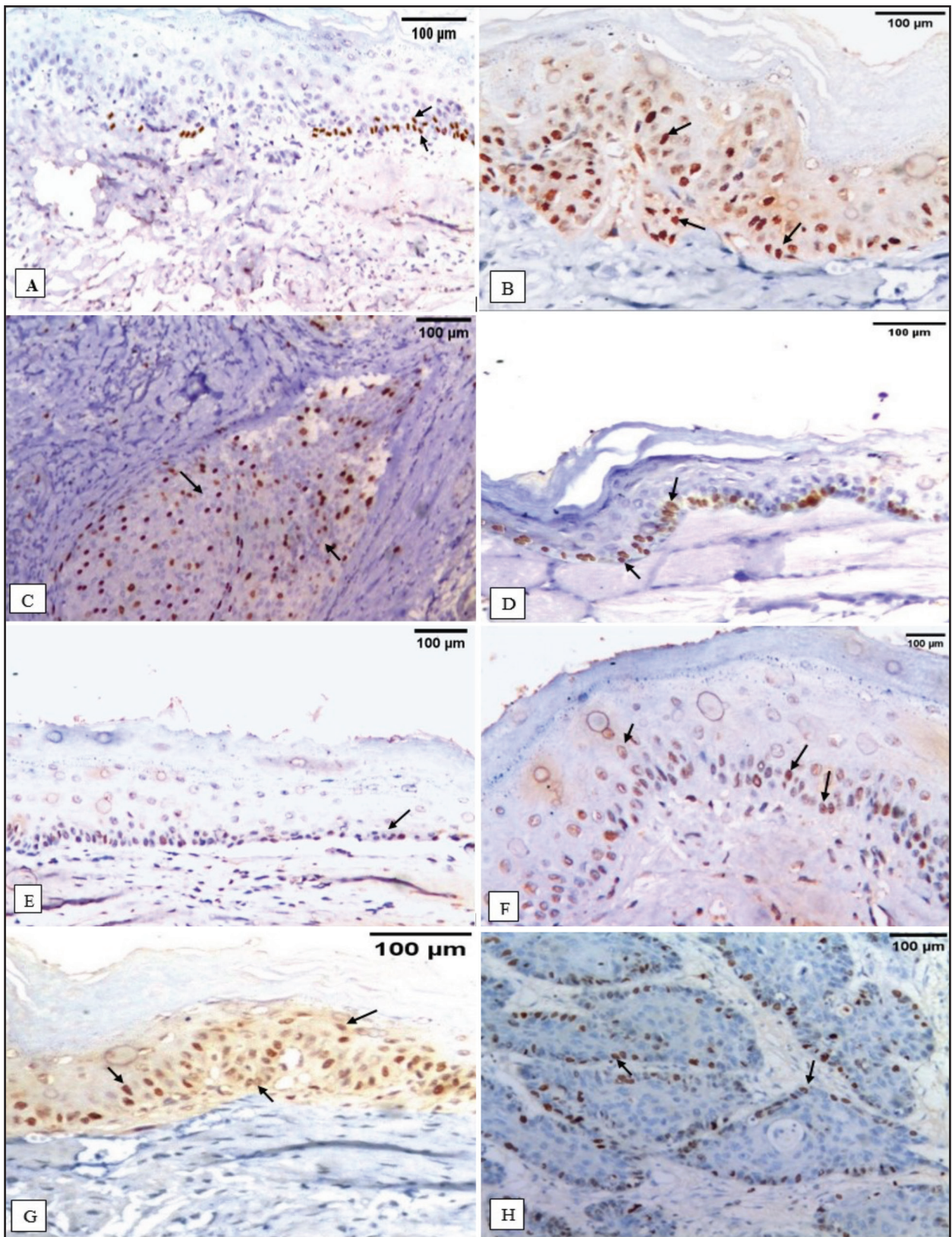
The paraffin blocks were left to cool using ice cubes, were cut into sections each of 4  $\mu$ m thickness, mounted on adhesion slides and then were left the whole night in order to dry. The slides were heated in the oven at sixty degrees the whole night. The slides were ready to enter the deparaffinization and rehydration stage as they were exposed to three changes of xylene, each change was for nearly ten minutes then rehydrated with different concentrations of alcohol starting with hundred percent, another dose of hundred percent, eighty percent and seventy percent afterwards they were rinsed with two changes of deionized water each change of water may reach up to five minutes. Slides were then ready to be blocked using hydrogen peroxide with concentration of three percent for five minutes, washed in deionized water for five minutes, placed in citrate buffer and heated in the microwave at hundred degrees for five to ten minutes paying attention at the level of the buffer to be suitable the entire period. The slides were then left to cool at the room temperature for fifteen minutes, washed with deionized water then washed with phosphate buffer for five minutes. Tissue sections then received one or two drops of the primary antibody Ki 67 mouse monoclonal antibody in a dilution range of 1:800 in Tris buffer solution, then were incubated overnight. Then they were washed with PBS and Biotinylated secondary antibody was added and incubated for 30 minutes at room temperature. The tissue sections were applied with diaminobenzidine for 2-4 minutes in order to obtain suitable then were washed and stained with hematoxylin and were covered with a mounting medium. Examination of these immunostained sections was done using the light microscope in order to evaluate the prevalence

of positive cases as well as to localize the immunostaining within the tissue sections adding to that the image analysis computer system was used to determine area percentage of the positive cells of the immunostaining<sup>(13)</sup>.

### RESULTS

The IHC staining of group I revealed normal tissues with mild positive Ki 67 nuclear expression (mean=4.64) that was restricted to the cells of the basal and parabasal layers (Fig. 1-A). Subgroup IIa revealed positive Ki 67 nuclear expression (mean=20.89) that was seen in cells present in basal, parabasal and some cells of the spinous cell layers in areas of moderate dysplasia while in severe epithelial dysplasia more cells in the spinous cell layer were positively stained (Fig. 1-B). Subgroup IIb revealed moderately differentiated squamous cell carcinoma with positive Ki 67 nuclear expression (mean=18.25) that was peripherally located as well as in parts of the central areas of the islands (Fig. 1-C). Group III (mean=6.73) revealed no significant differences compared to the control hamsters group (Fig. 1-D). Subgroup IVa revealed mild dysplasia with positive nuclear Ki 67 expression (mean=8.94) in the lower third of the epithelium (Fig. 1-E). Subgroup IVb revealed mild to moderate dysplasia with positive Ki 67 nuclear expression (mean=13.69) in the lower third of epithelium in case of mild dysplasia extending to middle third of epithelium in case of moderate dysplasia (Fig. 1-F). Subgroup Va revealed moderate to severe dysplasia with positive Ki 67 nuclear positive expression (mean=19.56) in cells of basal, parabasal and some cells of the spinous cell layers in areas of moderate dysplasia while in severe epithelial dysplasia more cells in the spinous cell layer were positively stained (Fig. 1-G). Subgroup Vb revealed well differentiated squamous cell carcinoma with positive nuclear Ki 67 expression (mean=15.47) in the periphery of the nests and not in the center of the nests (Fig. 1-H). (Fig. 1&2, table 1)





**Figure (1):** Ki 67 immunostaining in [group I, subgroup IIa, subgroup IIb, group III, subgroup IVa, subgroup IVb, subgroup Va, and subgroup Vb, (A-H, respectively X 200)]

**Table (1)** Descriptive statistics and comparison of all groups and subgroups (ANOVA test)

	Mean	Std. Dev	Std. Error	95% Confidence Interval for Mean		Min	Max	F	P
				Lower Bound	Upper Bound				
<b>Group I (control)</b>	4.64 <sup>d</sup>	.93	.41	3.49	5.79	3.24	5.53	34.21	0.00*
<b>Subgroup IIa (DMBA-8 W)</b>	20.89 <sup>a</sup>	2.56	.81	19.06	22.72	18.70	25.64		
<b>Subgroup IIb (DMBA-14W)</b>	18.25 <sup>a,b</sup>	3.12	.99	16.01	20.48	13.77	22.98		
<b>Group III (Diosmin)</b>	6.73 <sup>d</sup>	1.29	.57	5.14	8.33	5.24	8.65		
<b>Subgroup IVa (Diosmin 100mg/kg-8W)</b>	8.94 <sup>d</sup>	2.12	.67	7.42	10.46	6.05	11.76		
<b>Subgroup IVb (Diosmin 100mg/kg-14W)</b>	13.69 <sup>c</sup>	4.11	1.30	10.75	16.64	8.96	19.72		
<b>Subgroup Va (Diosmin 150mg/kg -8W)</b>	19.56 <sup>a,b</sup>	2.87	.91	17.51	21.61	16.24	23.47		
<b>Subgroup Vb (Diosmin 150mg/kg- 14W)</b>	15.47 <sup>c</sup>	2.83	.89	13.44	17.49	11.35	18.75		

Significance level  $p \leq 0.05$ , \*significant. Tukey's HSD post hoc test: Means sharing the same superscript letter are not significantly different.

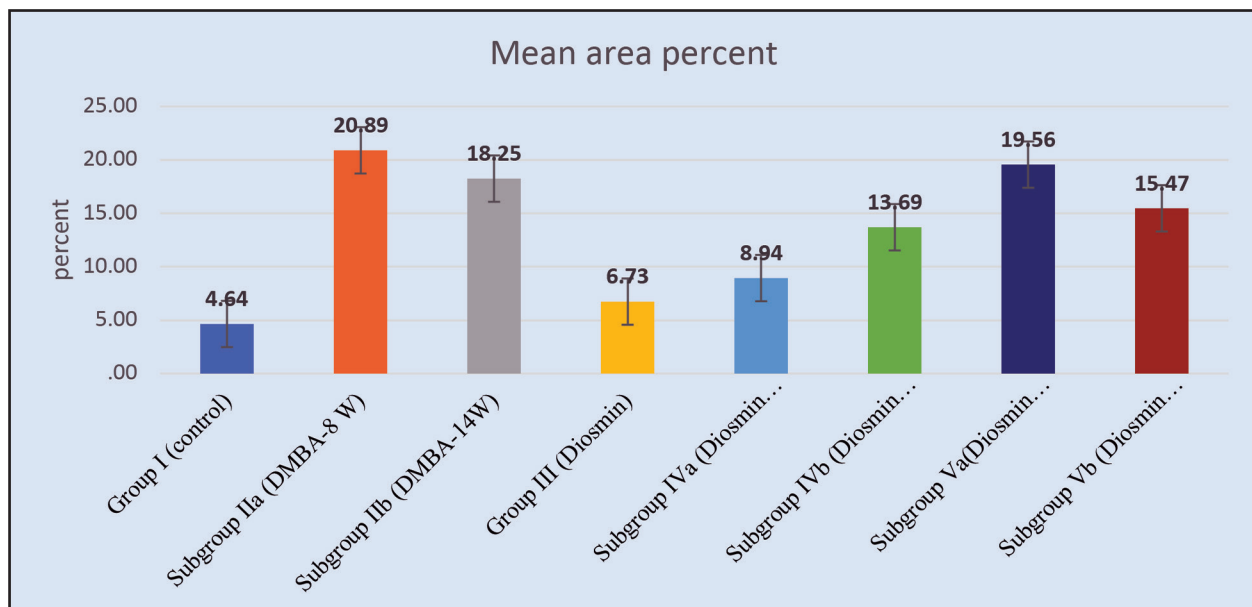


Figure (2): Bar chart illustrating mean area percent value in different groups and subgroups (ANOVA test)

## DISCUSSION

In the present study, the immunohistochemical staining in group I showed positive Ki 67 nuclear expression (mean= 4.64) in the basal cell layer, as well as the parabasal cell layers which are the segment consisting of: the cells located in the two layers found directly above the basal cell layer, while no Ki 67 nuclear expression was seen in the remaining layers which is in agreement with another study<sup>(15)</sup>, this can be explained by the basal cell layer physiological proliferative activity. As the division of cells normally occur in the stratum germinativum. While the parabasal positive staining could be explained by parabasal presence of transient amplifying cells obtained from the epithelial stem cells resulting from the asymmetric cell division of these stem cells normally present in the basal layer which is in agreement with various studies<sup>(16,17)</sup>. While in subgroup IIa the immunohistochemical staining of Ki 67 (mean= 20.89) showed nuclear positive expression in moderate to severe dysplasia which is in agreement with another study<sup>(18)</sup>. The Ki 67 nuclear positive expression was seen in the severe dysplasia more than the moderate dysplasia considering the increase in cell number and alternation at a genetic and molecular level of the tissue as features usually associated with the dysplasia of the epithelium due to the alteration of the maturation of the epithelial cells as a result of the increase in the suprabasal layer proliferative activity<sup>(18)</sup>. This can be explained by the DMBA toxic metabolites especially reactive oxygen species (ROS) which are able to bind to the adenine residues of DNA leading to the damage of the chromosomes, also ROS production was found to decrease the glutathione, S-Adenosyl methionine and S-Adenosyl homocysteine substances encouraging the oncogenic transformation; that is why as the ROS production is increased the more the cells will proliferate and damage the DNA, lipids and proteins the higher the chance for the oncogenic transformation to occur<sup>(4, 14-23)</sup>. DMBA was also found to be able to decrease the methylation of oncogenes and increase the methylation of tumor

suppressor genes which will result in increasing cell proliferation facilitating cancer occurrence<sup>(22)</sup>.

In subgroup IIb the immunohistochemical staining of Ki 67 in moderately differentiated squamous cell carcinoma (mean area %= 18.25) were present peripherally as well as in parts of the central areas of the islands which is in agreement with another study<sup>(18)</sup>. It was noted that the transformation of the normal epithelium to dysplastic epithelium then transforming it to frank malignant neoplasm is accompanied by the increase in the proliferation of cells and angiogenesis. Ki 67 expression is variable in the various groups as its expression is directly proportional with the disease progression. This is probably due to the further increase in reactive oxygen species production by time and due to metabolization of DMBA which is activated by phase I enzymes as cytochrome P450 and epoxidation by Cyp-b5 to its eventual carcinogenic metabolite dihydrodiol epoxide that bind to as well as damage DNA favoring in mutations. DMBA generation for reactive oxygen species as peroxides cause oxidative damage and lipid peroxidation which could be detected through plasma and erythrocytes TBARS and finally causing cancer due to increase in oxidative pressure as a result of imbalance between reactive oxygen species and enzymatic and non-enzymatic antioxidant defenses fighting against the reactive oxygen species. Binding of ligands, growth factors or cytokines to their receptors on the cell surface result in their dimerization and JAK-1 activation, this will activate and phosphorylate the transcription factor STAT-3 causing its translocation to the nucleus and the stimulation of cyclin D1 expression allowing the cells to proliferate, normally STAT-3 is activated temporary but DMBA was able to increase the expression of JAK-1/STAT-3 phosphorylated forms and its translocation to the nucleus resulting in increasing JAK-1/STAT-3 signal increasing the proliferation of cells<sup>(18,23-30)</sup>

In the present study group III with (mean=5.963) revealed no significant differences compared to



the control hamsters group. In the current study, we wanted to trace and discover the effect of the diosmin at 8 weeks as the reported results were after the 14 weeks only. So in subgroup IVa, the immunohistochemical staining of Ki 67 in mild epithelial dysplasia (mean area %=8.94) were found in lower third of the epithelium which is in agreement with another study<sup>(18)</sup>. While in subgroup IVb, the immunohistochemical staining of Ki 67 in mild to moderate epithelial dysplasia (mean area %=13.69) which is in agreement with another study<sup>(18)</sup>.

This can be explained as diosmin at dose 100mg/kg to DMBA painted hamsters acted as a perfect scavenger against the ROS generated by DMBA as it is tremendously reactive as electron donor limiting the damage caused by ROS in cells<sup>(30)</sup>, its effective antioxidant effect helped in tumor reduction which could be seen by the increased TBARS in the plasma and erythrocytes, while it is decreased in the buccal tissues due to the ability of that dose to restore glutathione reductase which becomes able to scavenge free residual radicals, Vitamin C and Vitamin E levels, both vitamins have various biological importance influencing the prevention of the damage of the gene and lipid through their modification of any carcinogenic metabolic stimulator; so diosmin at that dose was able to normalize the toxicity induced by DMBA suggesting that diosmin has anti lipid peroxidative property and that it balances the harmful oxidants and protective antioxidants as it can adjust the antioxidant enzymes. It also decreases the levels of JAK-1/STAT-3 phosphorylated forms and so its translocation to the nucleus resulting in inhibiting JAK-1/STAT-3 signal decreasing the proliferation of cells<sup>(23-31)</sup>.

This study aimed to figure out the effect of a new dose of diosmin (150mg/kg to DMBA painted hamsters) that wasn't used before. In subgroup Va, the immunohistochemical staining of Ki 67 in moderate to severe dysplasia (mean area %=19.56). While in subgroup Vb immunohistochemical

staining of Ki 67 in well differentiated squamous cell carcinoma (mean area %=15.47). This can be explained by the ability of diosmin 150mg/kg with DMBA to have restored TBARS levels but failed to restore the levels of antioxidant enzymes which was stated by various studies upon explaining the less effective effect of doses 110 and 120 mg/kg compared to the optimum dose 100mg/kg<sup>(17, 18, 24)</sup>.

The detection of Ki 67 was in the periphery of the nests and not in the center suggesting that cells which are less differentiated are located peripherally in the nests while cells that are more well differentiated with the ability to produce keratin are located in the center where Ki 67 didn't show any expression where the quantity of staining present in the well differentiated OSCC was less than that present in moderately differentiated which is in agreement with previous study<sup>(20)</sup>. The reason for the higher mean index of Ki 67 in case of sever dysplasia in comparison to well and moderately differentiated squamous cell carcinoma could be explained by the ability of Ki 67 in evaluating cells that are in state of proliferation and not their rate of proliferation so a neoplasm with low proliferation rate and long cell cycle can have high Ki 67 mean index due to presence of many cells in the cycle while a neoplasm with high proliferation rate and short cell cycle can have low Ki 67 mean index due less number of cells present in the cycle<sup>(32)</sup>.

## CONCLUSION

The effect of diosmin could be a promising chemopreventive agent in regression of DMBA induced hamster buccal pouch carcinogenesis as it has antiproliferative properties confirmed upon using Ki 67 marker.

## ACKNOWLEDGEMENTS

This work was done under the supervision of the staff members of Oral and Dental Pathology Department, Faculty of Dental Medicine for Girls, Al-Azhar University, Cairo.



## RECOMMENDATIONS

Biochemical assays should be done for the Diosmin 150mg/kg dose for further explanation about its less effectiveness as a chemopreventive agent compared to Diosmin 100mg/kg. Also studies on Diosmin using other antiproliferative markers or DNA sequencing techniques should be done to measure its validation as a therapeutic agent.

## FUND RECEIVED FOR THIS STUDY

There was no fund received for this study

## CONFLICT OF INTEREST

The authors declare the presence of any conflict of interest

## REFERENCES

- Kaisar S, Kale U. Role of micronucleus as a potential biomarker in oral carcinogenesis. *EC Dent Sci.* 2019; 18: 749-54.
- Venkatesh A, Wadhwan V, Aggarwal P, Vandana Reddy V, Preeti Sharma P, Gotur SP, et al. Elevated p63 expression as an indicator for poorer prognosis in squamous cell carcinomas of the oral cavity an immunohistochemical study. *Indian J Med Paediatr Oncol.* 2018; 39: 146-52.
- Huang F, Xin C, Lei K, Bai H, Li J, Chen Q. Noncoding RNAs in oral premalignant disorders and oral squamous cell carcinoma. *Cell Oncol.* 2020; 43: 763-77.
- Al-Dosoki MA, Ahmed M, Mansour AM, Ahmed MM. Effect of oxygenated water as a new treatment modality on experimentally induced hamster buccal pouch carcinogenesis. *Al-Azhar J Den Sci.* 2018; 21: 261-73.
- Martínez AD, Gómez PA, Castro CA, Pérez JE. DMBA-induced oral carcinoma in syrian hamster increased carcinogenic effect by dexamethasone co-exposition. *Biomed Res Int J.* 2020; 2020: 140868.
- Yapjikakis C, Kalogera S, Papakosta V, Vassiliou S. The hamster model of sequential oral carcinogenesis an update. *In Vivo J.* 2019; 33: 1751-5.
- Siemianowicz K, Likus W, Dorecka M, Wilk R, Dziubdziela W, Markowski J. Chemoprevention of head and neck cancers does it have only one face. *Biomed Res Int J.* 2018; 2018: 9051854.
- Amawi H, Ashby CR, Tiwari AK. Cancer chemoprevention through dietary flavonoids what's limiting. *Chin J Cancer.* 2017; 36: 50-70.
- Gandhi GR, Vasconceios ABS, Wu DT, Li HB, Antony PJ, Li H, et al. Citrus flavonoids as promising phytochemicals targeting diabetes and related complications: a systemic review of in vitro and in vivo studies. *Nutrients J.* 2020; 12: 1-16.
- Feldo M, Woźniak M, Kosior MW, Sowa I, Waśik AK, Aszyk J, et al. Influence of Diosmin Treatment on the Level of Oxidative Stress Markers in Patients with Chronic Venous Insufficiency. *Oxid Med Cell Longev.* 2018; 2018: 2561705.
- Jing Y, Zhou Q, Zhu H, Zhang Y, Song Y, Zhang X, et al. Ki 67 is an independent prognostic marker for the recurrence and relapse of oral squamous cell carcinoma. *Oncol Lett.* 2018; 17: 974-80.
- Abdel-Hafeez HH, Abou- Elhamd AS, Soliman SA. Morphological and immunohistochemical phenotype of tcs in the intestinal bulb of grass carp and their potential role in intestinal immunity. *Sci Rep J.* 2020; 10: 1-17.
- Magaki S, Hojat SA, Wei B, So A, Yong WH. An introduction to the performance of immunohistochemistry. *Methods Mol Biol.* 2019; 1897: 289-98.
- Bruna F, Rodríguez M, Plaza A, Espinoza I, Conget P. The administration of multipotent stromal cells at precancerous stage precludes tumor growth and epithelial dedifferentiation of oral squamous cell carcinoma. *Stem cell Res J.* 2017; 18: 5-13.
- Mondal K, Mandal R, Chandra B. Importance of Ki 67 labeling in oral leukoplakia with features of dysplasia and carcinomatous transformation an observational study over 4 years. *South Asian J Cancer.* 2020; 9: 99-104.
- Moreci RS, Lechler T. Epidermal structure and differentiation. *Curr Biol J.* 2020; 30: 144-49.
17. Sanz-Gómez N, Freije A, Gandarillas A. Keratinocyte Differentiation by Flow Cytometry. *Methods Mol Biol J.* 2020; 2109: 83-92.
- Takkem A, Barakat C, Zakaraia S, Zaid K, Najmeh J, Ayoub M, et al. Ki 67 prognostic value in different histological grades of oral epithelial dysplasia and oral squamous cell carcinoma. *Asian Pac J Cancer Prev.* 2018; 19: 3279-86.
- Suwasini S, Chatterjee K, Purkai SK, Samaddar D, Chatterjee A, Kumar M. Expression of p53 protein and

- Ki 67 antigen in oral leukoplakia with different histopathological grades of epithelial dysplasia. *J Int Soc Prev Community Dent.* 2018; 8: 513-22.
20. Moreci RS, Lechler T. Epidermal structure and differentiation. *Curr Biol J.* 2020; 30:144-9.
21. Huerta ER, Maldonado E. Transit-amplifying cells in the fast lane from stem cells towards differentiation. *Stem Cells Int J.* 2017; 2017: 7602951.
22. Szabo L, Molnar R, Tomesz A, Deutsch A, Darago R, Nowrasteh G, et al. The effects of flavonoids, green tea polyphenols and coffee on dmba induced line 1 dna hypomethylation. *Plos One J.* 2021; 16: 1-14.
23. Suresh K, Rajasekar M, Kumar RA, Sivakumar K. Protective effect of diosmin on 7,12-dimethylbenz (a) anthracene (dmba) induced hamster buccal pouch carcinogenesis. *Life Sci Arch.* 2016; 2: 601-9.
24. Liu Z, Ren Z, Zhang J, Chuang CC, Kandaswamy E, Zhou T, et al. Role of ROS and nutritional antioxidants in human diseases. *Front Physiol.* 2018; 9: 477-93.
25. Mohamed AM, Mansour AM, Zouair MG. Effect of oxygenated water as a new chemopreventive modality in experimentally induced hamster buccal pouch carcinogenesis. *Al-Azhar J Dent Sci.* 2018; 21: 99-112.
26. Shoemaker RH, Fox JT, Juliana MM, Moeinpour FL, Grubbs CJ. Evaluation of the STAT3 inhibitor GLG-302 for the prevention of the estrogen receptor positive and negative mammary cancers. *Oncol Rep.* 2019; 42: 1205-13.
27. Wang J, Hu Y, Wang Y, Yang Y, Li S, Hou Y et al. D-carvone attenuates biochemical and molecular expression via oncogenic signaling in aryl hydrocarbon-induced hamster mucosal carcinogenesis. *Pharm J.* 2020; 16: 303-10
28. Naveed M, Ullia M, Javed K, Butt A, Khawar M, Amjad F. Targeting STAT3 signaling pathway in cancer for development of novel drugs advancements and challenges. *Genet Mol Biol.* 2020; 43: 1-25.
29. Rajasekara M, Suresha K, Sivakumar K. Diosmin induce apoptosis through modulation of STAT-3 signaling in 7,12 dimethylbenz(a)anthracene induced hamster buccal pouch carcinogenesis. *Biomol Pharmacol J.* 2016; 83: 1064-70.
30. Perumal S, Langeswaran K. Diosmin anti-tumor efficacy against hepatocellular carcinoma. *Biomed Res.* 2019; 30: 1-10.
31. Sheelam S, Reddy SP, Kulkarni PG, Nandan SRK, Keerthi M, Raj GS. Role of cell proliferation and vascularity in malignant transformation of potentially malignant disorders. *J Oral Maxillofac Pathol.* 2018; 22: 281-92.
32. Beevi BH, Nayak SR, Peter CD, Haridas AK, Jacob L, Aboobakker A. Analysis of Ki 67 expression in oral premalignant lesions and normal oral mucosa an immunohistochemical study. *J Pharm Allied Sci.* 2019; 11: 232-5.