



Assessment of Root Changes and Bone Density Accompanying Different Methods of Accelerated Orthodontic Tooth Movement

Amany M. Ibrahim^{1*}, Samir A. Ibrahim², Susan A. Hassan³, Fatma A. Abd el-Samad⁴ and Mai S. Attia⁵

Codex : 78/20.10

azhardentj@azhar.edu.eg

<http://adjg.journals.ekb.eg>

DOI: 10.21608/adjg.2020.13117.1148

Pediatric Dentistry & Orthodontics
(Pediatric Dentistry, Orthodontics)

ABSTRACT

Purpose: This study was carried out to evaluate root surface changes and bone density accompanying two different methods of accelerated orthodontic tooth movement by Cone beam computed tomography (CBCT). **Patients and methods:** The present study was applied to twenty patients. With bimaxillary dento-alveolar protrusion or Angle Class II Division 1 malocclusion. The line of treatment was the extraction of the upper first bicusps and then cuspid distalization. The patient's sample was divided into two equal groups. In the group I, one side of the maxillary arch was chosen for treatment with peizocision, and in the group II, injectable platelet-rich fibrin (i-PRF) injection was used. The opposite sides in two groups acted as controls. Canine distalization was performed in both sides by 150 gm. of force applied from nickel titanium closed coil spring. The following parameters were measured from cone-beam tomography: volumetric root length and bone density. Besides this, the canine retraction rate was measured from casts. **Results:** The canine retraction rates were greater in experimental sides than in the control sides in the two groups. Decrease volumetric root length and bone density were recorded in both groups after canine retraction. **Conclusions:** Piezocision technique and i-PRF injection are efficient procedures that reduce the time needed for canine distalization. No significant differences regarding volumetric root resorption were observed in both groups between the experimental side and the control one after canine retraction.

KEYWORDS

*Piezocision, injectable PRF,
Cone Beam Computed
Tomography*

- Paper extracted from Doctor Thesis titled "Assessment of Root Changes and Bone Density Accompanying Different Methods of Accelerated Orthodontic Tooth Movement".
 - 1. Assistant Lecturer of Orthodontic Department, Faculty of Dental Medicine for Girls, Al-Azhar University.
 - 2. Professor of Orthodontic Department, Faculty of Dental Medicine for Girls, Al-Azhar University, Cairo, Egypt
 - 3. Professor of Oral and Maxillofacial Surgery Department, Faculty of Dental Medicine for Girls, Al-Azhar University, Cairo, Egypt
 - 4. Professor of Orthodontic Department, Faculty of Dental Medicine for Girls, Al-Azhar University.
 - 5. Assistant Professor of Oral medicine, Periodontology, Diagnosis and Radiology Department, Faculty of Dental Medicine for Girls, Al-Azhar University, Cairo, Egypt
- * Corresponding author email: amanyortho@yahoo.com

INTRODUCTION

The number of adult patients who needed orthodontic treatment to enhance their esthetic or oral functions have been increasing in the last decade. These patients represent the important stump as they always need perfect result in the shortest time. Tissue reaction and biological events that occur as a result to orthodontic force make the rate of subsequent tooth movement about 1mm per month. And hence, in case that needs to extract upper first premolar and then canine retraction and maximum anchorage can almost take 7 mm; this may lead to an overall treatment interval about 2 years^(1,2).

Reducing the duration of treatment through increasing the rate of orthodontic tooth movement is preferred to both clinicians and patients because of prolonged duration usually related to several problems like increase occurrence of dental caries, gingival inflammation, and risk for root resorption^(3,4).

Platelet-rich plasma (PRP) is concentrated platelets in a small volume of plasma and is represented as a highly enriched source of growth factors and leukocyte⁽⁵⁾. However, The most serious drawback of PRP is the addition of anticoagulants to the blood sample, which may be the cause for delayed wound healing⁽⁶⁻⁸⁾. A frontier production of a new version of platelet-rich fibrin which is in liquid condition and can be injected without the need for the addition of anticoagulants by decreasing centrifugal speed and time⁽⁹⁾.

Piezocision is a novel minimally invasive accelerated technique for orthodontic tooth movement. This technique involved cuts and injuries with piezoelectric tips which leads to the same effect of corticotomy with little invasiveness⁽¹⁰⁻¹²⁾. These cuts or bone insults are in charge of the initiation of the first demineralization process that called the regional acceleratory phenomenon (RAP). The fleeting osteopenia connected this phenomenon increase rate of orthodontic tooth movement because this movement occurs in a malleable medium⁽¹³⁻¹⁵⁾.

Root resorption (RR) is an undesirable effect that occurs during orthodontic treatment. It is defined as a reduction of root length or cringe. Because of RR is a multifactorial issue, it is serious to know and focusing on the controlling factors that cause root resorption. So, the method of management may be modified to prevent it^(10,17).

A series of biological events occur in bone tissues after the application of orthodontic forces. These events lead to bone remodeling and modeling and then tooth movement occurs. The resultant newly formed bone has a slight degree of mineralization with transient reduction of the tooth surrounding alveolar bone mineral density which may impair its structural resistance^(18,19).

So, the present study was carried out to assess root surface changes and bone density accompanying accelerated orthodontic tooth movement by injectable platelet rich fibrin injection and Piezocision.

PATIENTS AND METHODS

The present study was done on 20 patients according to sample size power test aged 15-19 years old. These participants were selected from those coming to the orthodontic clinic, faculty of Dental medicine for Girls, Al Azhar University. This study obtained the approval from the committee of ethics of the faculty Dental medicine of Al-Azhar University, Cairo, Egypt.

The study design is a single center randomized clinical study with a parallel design where the participants needed extraction of maxillary first premolar in orthodontic treatment and canine retraction.

The selected patients fulfilled the following criteria, Patients with dentoalveolar bimaxillary protrusion or class II div 1, no previous orthodontic treatment, no record of trauma, no presence of root resorption on the pretreatment panoramic radiographs, good oral hygiene, highly motivation and cooperation, The treatment plan should require extraction of the upper first bicuspid, and patients should be free from any systemic diseases that might affect bone metabolism or consistency as osteoporosis.

The study groups: Participants were divided in an equal and random pattern into two groups: Group I: a peizocision group in which a peizocision was performed on the experiential side of the upper jaw and Group II: an injectable platelet rich fibrin (i-PRF) group in which injection was performed on the experiential side of the upper jaw. The opposite sides in two groups acted as controls

The foremost phase of teeth alignment and leveling was completed first with a straight wire 0.022-in slot Roth appliance. The day prior to the application of two technique, one upper first bicuspid was extracted, and the latter bicuspid was extracted in the same day of the surgery, to avoid having two bleeding sites.

Surgical protocol: Piezocision involved performing incisions in gingiva and vertical cuts in cortical bone without flap reflection. Mesial and distal incisions were made through the gingiva on the buccal surface of the canine with a number 15 blade in award-Parker blade handle number 3. Vertical interproximal cuts were done 5 mm Apical to interdental papillae in mesial and distal one of upper canine. Cuts lengths were about 10 mm in apical direction⁽¹⁴⁾ using a Piezotome (VarioSurg3; NSK, Tokyo, Japan.).

I-PRF: a total volume of 10 cc of autologous venous blood was withdrawn from the patients using a 10 ml needle. About 10 ml of patients' blood without the use of any anti-coagulant was subjected to 700 rpm centrifugal speed and for 3 minutes centrifugal time.⁽⁸⁾ The uppermost 1 mL layer of plasma was then collected and represented as i-PRF and then injected mesial and distal to maxillary left canine (submucosal and inter ligamentary) under local anesthesia.

In all groups, a 0.016 x 0.022-in stainless steel wire was placed promptly after both techniques and started canine retraction with nickel-titanium closed-coil springs that applied 150 g of force on each side. Canine distalization started promptly after surgery to trade on the RAP initiated by bone

insult. The coil springs were stretched between the canine and the miniscrews placed between second bicuspid and first permanent molar.

CBCT measurements: All patients under this study were submitted for Cone beam computed tomography (CBCT) scanning before and after treatment. CBCT images were acquired using a next-generation iCAT scanner (ISI, USA). The volume was calculated based on a certain threshold is given to differentiate between the densities of dentin from that of bone and surrounding structures at the pre and post-scan. After thresholding, cropping is made to confine the mask to the canine region, then manual clean-up was made to confine the created mask to the canine density. The volume of the assigned mask was then automatically calculated and tabulated. The same procedure was repeated for the canine teeth at the post-scan using the same threshold values. **Cast measurement:** Measurements were made on both sides with a digital caliper to obtain the orthodontic tooth movement rate on each side in both groups.

RESULTS

Tooth movement Rate: In both groups (group I and group II group), the statistical analysis (independent t test) showed a higher mean value was recorded on the experiential side, with a highly significant statistical difference ($p=0.001$) (Table 1).

Volumetric root length (Mm3): Paired t-test revealed that the difference between the before and after treatment mean values in both groups was statistically significant on the right control side ($p=0.00$) and on the experiential site (Table 2).

Mann Whitney U test revealed that there no statistical difference in percent change of volumetric root length (mm^3) between groups in the experiential side (Table 3).

Bone density: As shown in (Fig. 1) both groups there is no statistical difference in percent change of Bone density (H.U.) between groups in the experiential side.

Table (1): Comparison of tooth movement rate (mm/day) in control and experiential sides within the same group.

Groups	Mean	SD	Difference			
			Mean	SD	t	P
Piezocision group (control)	0.053	±0.032	0.062	±0.016	3.85	0.001*
Piezocision group(experimental)	0.115	±0.039				
i-PRF group (control)	0.0644	±0.0175	-0.0576	±0.0127	4.54	0.001*
i-PRF group (experimental)	0.122	±0.036				

Significance level $p^* \leq 0.05$, SD=standard deviation.

Table (2): Comparison of volumetric root length (mm³) before and after within the same group.

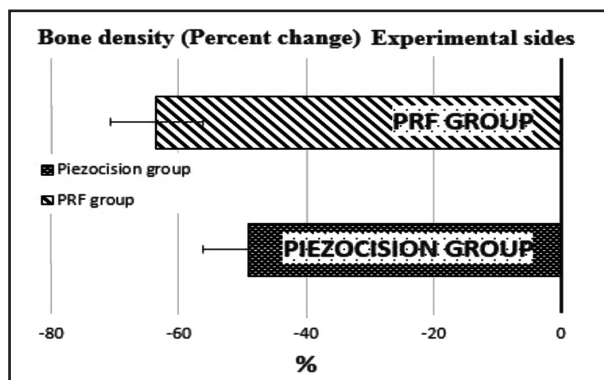
Groups	Side	Time	Mean	SD	Difference		
					SD	t	P
Piezocision	Control	pre	913.03	±127.38	±8.91	6.32	0.000*
		Post	895.22	±123.70			
i-PRF	Control	pre	905.58	±144.27	±10.08	4.69	0.001*
		Post	890.64	±137.41			
Piezocision	Experimental	pre	901.73	±121.74	±7.24	10.21	0.000*
		Post	878.36	±118.01			
i-PRF	Experimental	pre	860.47	±151.79	±17.13	3.72	0.005*
		Post	840.30	±153.70			

Significance level $p^* \leq 0.05$, SD=standard deviation.

Table (3): Comparison of percent change of volumetric root length (mm³) between groups in the experiential side.

Side	Groups	volumetric root length (mm ³)			P value (between groups)	Sig
		Mean	SD	SEM		
Experimental	Piezocision group	-2.58	±0.66	±0.21	0.190	NS
	i-PRF group	-2.43	±2.18	±0.69		

Significance level $p \leq 0.05$, Ns=non-significant, SD=standard deviation



Figure(1) Bar chart illustrating mean \pm SD of bone density (H.U.) in both groups.

DISCUSSION

Several methods are used to reduce the time required for orthodontic treatment by increasing the rate of orthodontic tooth movement. These methods can be divided into different approaches like 1) use of biological materials, 2) physical energizing of the bone surrounding the tooth and 3) surgical techniques⁽⁴⁾.

Accelerated orthodontic tooth movement is preferred and a great demand for patients needing orthodontic treatment especially adults. Those Create a motive for every clinician to looking for different modalities that may help in reducing the duration of the treatment.

The present study design was a randomized clinical trial, in which the participants were assigned randomly to separate groups. Neither the researchers nor participants were aware of which group to the patient was allocated. So, any differences in result between both groups could be attributed to the intervention.

As root resorption is a three-dimension phenomenon, and its extent must be accurately measured. In the present study, CBCT was used as a measurement tool for root resorption. This finding was in accordance with a previous study⁽¹⁶⁾ which concluded that CBCT is the great method to detect root resorption in all dimension compared to periapical radiographs which have Zoom errors and lack of accurate landmark parameters. CBCT is advisable in patients with a high risk of root resorption.

The current study showed that there was a highly significant statistical difference in the orthodontic tooth movement rate between control and experiential side in Piezocision group where the higher mean value recorded on the experiential sides. These results are in agreement with the other studies^(14, 15) that concluded that Piezocision-beautifying canine retraction increases the rate of canine retraction and reduce the total treatment time.

This present study also showed that a highly significant statistical difference between control and experiential side in i- PRF group. Recent studies^(8, 9) have concluded that this unique formula of concentration of platelet without the need for the addition of anti-coagulants (i-PRF) was able to greatly affect osteoblast manner by affecting the peregrination, proliferation, and differentiation of human osteoblasts when compared to PRP. The change in time and speed of centrifugation leads to the formation of

the new formula of platelet concentrate with a high concentration of leukocytes and growth factors as for each element it is own specific gravity at which sedimentation occur.

A new formula i-PRF that is composed of the patient's own blood without the use of additives or anticoagulant which seems to delay wound healing that is what making i-PRF is a unique formula of platelet concentrate. It has been postulated that the Injection of PRP could increase the rate of orthodontic tooth movement. This may be due to their effect on bone mineral density and the occurrence of transient osteopenia⁽⁵⁾.

These results could be attributed to the effect of RAP, which is featured by increasing bone metabolism and decreasing bone mineral density in a passing way which returns to a normal level after a definite time. Initiation of inflammatory cascade before application of orthodontic force to start the movement is the key for a lot of accelerated methods.

The current study showed that the difference between the pre and post mean values of volumetric root length (mm^3) in both groups was statistically significant in the control side and in the experiential side. Finding of this reaserch were in agreement with other studies that concluded that distalization force of about 124- cN able to cause external root resorption and also, pointed out that the orthodontic force may not the predominant cause of root resorption. And the load is a contributing factor causing external root resorption^(16, 17).

Root resorption is a multifactorial process and it seems to be a very complicated issue to explain the main cause for root resorption occurring with orthodontic force. Experiments and a lot of researches take the responsibility to explain the causes of root resorption and it is amount. And also, research about methods that may be useful for decreasing the incidence of root resorption.

The difference between the pre and post mean values of bone density was statistically significant

on the control side and on the experiential side. This finding was in agreement with the several studies^(18,19) concluded that after active orthodontic treatment for maxillary arch the bone density around the teeth of the anterior maxilla decreased by about 24% in the eight patients scanned in the mentioned study.

Bone remodeling in the tension site described by the pressure-tension theory. These changes occur due to the opposition of a newly formed bone with a little mineral content. The newly formed bone that result from tissue reaction and changes have alittle mineral content which affect the density of alveolar bone surrounding the tooth and impar it is structural integrity.⁽¹⁸⁾

CONCLUSION

Within the limitations and findings of the present study, it could be concluded that Peiziocision technique and i-PRF injection are efficient procedures that reduce the time needed for canine distalization. Both modalities showed non-significant difference regarded volumetric RR and bone density changes when compared with control.

REFERENCES

1. Ksakallia S, Berra Calik B, Burcak Kara and Zirganli S. Accelerated tooth movement with piezocision and its periodontaltransversal effects in patients with Class II malocclusion. *Angle Orthod.* 2016; 86:59-64.
2. Pilon J, Kuijpers-Jagtman A and Maltha J. Magnitude of orthodontic forces and rate of bodily tooth movement: an experimental study. *Am J Orthod Dentofacial Orthop.* 1996; 110:16–23.
3. Ristic M, Svabic M, Sasic M and Zelic O. Clinical and microbiological effects of fixed orthodontic appliances on periodontal tissues. *Orthod Craniofac Res.* 2007; 10:187-95.
4. Segal G, Schiffman P and Tuncay O. Meta-analysis of the treatment-related factors of external apical root resorption. *Orthod Craniofac Res.* 2004; 7:71-8.
5. G€ulec A, Banu C, Bakkalbas A, Cumbul A, Uslu B and Yaratc A. Effects of local platelet-rich plasma injection on the rate of orthodontic tooth movement in a rat model: A histomorphometric study. *Am J Orthod Dentofacial Orthop.* 2017; 151:92-104.
6. Choukroun J and Ghanaati S. Reduction of relative centrifugation force within injectable platelet-rich-fibrin (PRF) concentrates advances patients' own inflammatory cells, platelets and growth factors: the first introduction to the low-speed centrifugation concept. *Eur J Trauma Emerg Surg.* 2018; 44: 87-95.
7. Miron R, Fujioka M, Hernandez M, Kandalam U, Zhang Y, Ghanaati S , et al. Injectable platelet-rich fibrin (i-PRF): opportunities in regenerative dentistry. *Clin Oral Investig.* 2017; 21: 2619-27.
8. Abd El Raouf M, Wang X, Miusi S, Chai J , Abdel-Aal A, Helmy M,et al. Injectable-platelet rich fibrin using the low-speed centrifugation concept improves cartilage regeneration when compared to platelet-rich plasma. *Platelets.* 2017; 2017:1401058.
9. Lopez P, Sanchez A, Amaral R and Tobias A. Medication-related osteonecrosis of the jaw: Is autologous platelet concentrate application effective for prevention and treatment? A systematic review. *J Cranio Maxillofac Surg.* 2016; 44:1067–72.
10. Elkalza A, Hashem A and Alam M. Comparative study of root resorption between two methods for accelerated orthodontic tooth movement. *J Oral Res;* 2018: 7:348-53.
11. Yia J, Xiao J, Li Y Li, and Zhao Z. Efficacy of Piezocision on accelerating orthodontic tooth movement: A systematic review. *Angle Orthod.* 2017; 87:491-8.
12. Nimeri G, Kau C, Abou-Kheir N and Corona R. Acceleration of tooth movement during orthodontic treatment - a frontier in Orthodontics. *Progress in Orthod.* 2013; 42:1-8.
13. Davidovitch Z, Finkelson M, Steigman S, Shanfeld J, Montgomery P and Korostoff E. Electric currents, bone remodeling, and orthodontic tooth movement. II. Increase in rate of tooth movement and periodontal cyclic nucleotide levels by combined force and electric current. *Am J Orthod.* 1980; 77:33–47.
14. Abbas N, Sabet N and Hassan I. Evaluation of corticotomy-facilitated orthodontics and piezocision in rapid canine retraction. *Am J Orthod Dentofacial Orthop.* 2016; 149:473-80.
15. Bakathir M, Hassan A, and Bahammam M. Piezocision as an adjunct to orthodontic treatment of unilateral posterior crossbite. *Saudi Med J.* 2017; 38:425–50.

16. Sherrard J, Rossouw P, Benson B, Carrillo R, and Buschange P. Accuracy and reliability of tooth and root lengths measured on cone-beam computed tomography. *Am J Orthod Dentofacial Orthop.* 2010; 173:s100-8.
17. Jiang F, Chen J, Kula K, Gu H, Du Y and Eckert G. Root resorptions associated with canine retraction treatment. *Am J Orthod Dentofacial Orthop.* 2017; 152:348–54.
18. Hsu J, Chang H, Huang H, Yu J, Li Y, and Tu M. Bone density changes around teeth during orthodontic treatment. *Clin Oral Invest.* 2011; 15:511–9.
19. Hsu J, Chang H, Huang H Yu J, Li Y and Wu Y. Effects of orthodontic tooth movement on alveolar bone density. *Clin Oral Invest.* 2012; 16:679–88.