



## Evaluation of Cephalometric Changes in Treatment of Skeletal Class III Malocclusion Using Miniscrews and Intermaxillary Coil Spring

Randa M. Mahmoud<sup>1\*</sup>, Samir A. Ibrahim<sup>2</sup>, Sara M. Elkabbany<sup>3</sup>

Codex : 20/22.07

azhardentj@azhar.edu.eg

http://adjg.journals.ekb.eg

DOI: 10.21608/adjg.2022.76291.1390

Pediatric Dentistry & Orthodontics  
( Pediatric Dentistry, Orthodontics )

### ABSTRACT

**Purpose:** The aim of this study was evaluation of cephalometric changes in treatment of skeletal class III malocclusion using miniscrews and intermaxillary closing coil springs. **Material and methods:** Ten patients with skeletal Class III malocclusion due to maxillary deficiency were selected, their age range from 12 to 15 years old with erupted all permanent teeth. Miniscrews (Hubit, Hubit co, Korea) were inserted (1.6 mm diameter, 10 mm length) in upper arch between upper second premolars and first molars and (1.4 mm diameter, 8 mm length) in lower arch between canines and first premolars were used. A fixed posterior bite plate was used to eliminate occlusal interferences and facilitate bite jumping. The force was immediately delivered (250g) per sides using closed coil spring (Ortho Technology, TAD coil spring, 9mm, USA). Dentoskeletal and soft tissues cephalometric changes were measured by using Orisceph RX3 software (Italy) for pre and after 6<sup>th</sup> months. **Results:** Regarding specific cephalometric measurements there was statistically significant difference and soft tissue improvement. **Conclusion:** Intermaxillary miniscrews supported coil spring is a promising protocol for skeletal class III patient. Success depends on proper presurgical patient counseling and miniscrews placement.

### INTRODUCTION

The diagnosis, treatment preparation, and treatment mechanics of skeletal and dental Class III malocclusion present a challenge to the orthodontist. The need for orthodontic or surgical approaches in class

### KEYWORDS

Class III, Miniscrews,  
anchorage, coil spring.

- Paper extracted from Master thesis titled “ Evaluation of Cephalometric Changes in Treatment of Skeletal Class III Malocclusion Using Miniscrews and Intermaxillary Coil Spring ”
- 1. Dentist at Egyptian Ministry of Health, Cairo, Egypt
- 2. Professor of Orthodontics, Orthodontic Department., Faculty of Dental Medicine for Girls, Al-Azhar University, Cairo, Egypt.
- 3. Lecturer of Orthodontics, Orthodontic Department, Faculty of Dental Medicine for Girls, Al-Azhar University, Cairo, Egypt.

\* Corresponding author email: randamohamed.badr@gmail.com

III is decided by the amount and direction of growth pattern<sup>(1)</sup>.

Recently, using skeletal anchorage for maxillary retrognathia as orthopedic care has increased for preventing the dentoalveolar and skeletal side effects of tooth borne devices and enhance maxillary protraction<sup>(2)</sup>.

Intermaxillary elastics between miniplates in the maxillary zygomatic crests and in the anterior mandibular region were used to accomplish maxillary protraction, as a new perspective in orthopedic treatment of Class III malocclusions. The extra oral face mask is no longer required with this method, and intermaxillary traction can be used 24 hours a day. A case report demonstrates the use of two surgical miniplates and two miniscrews as anchoring for maxillary protraction during the pre-peak period of growth<sup>(3,4)</sup>.

Skeletal anchoring is based on the idea that if reactive pressures can be absorbed by skeletal components, tooth movement can be confined to the therapeutic movements, and it is possible to completely avoid the unfavorable reactive side effects. A situation like this can currently be achieved by temporarily implanting tiny devices into the patient's jawbone and using them as tooth movement anchors<sup>(5)</sup>.

The new orthodontic treatment options as implant assisted orthodontics was created as a result of the advancement of modalities that optimize anchorage regulation while reducing patient compliance requirements. Despite the fact that osseo-integrated dental implants provide stable anchorage for malocclusion management, their applications are limited due to their considerable size. The miniplate is more stable than the miniscrew. However, insertion and removal require flap surgery, which causes swelling and discomfort<sup>(6)</sup>. Because of their advantages, such as their lesser cost and easier of placement and removal, miniscrew implants have become the common temporary anchorage devices. The miniscrew implant's small and convenient size allows it to be used in a variety of anatomical areas, including the

interdental region<sup>(7)</sup>.

There was a study<sup>(8,9)</sup> found that miniscrews on the side of the mouth loaded with lighter forces were substantially more stable than those loaded with larger forces. In another investigation, miniscrews loaded with 100 or 200 g had much greater success rates than unloaded miniscrews and those loaded with 50 g<sup>(10)</sup>.

Subsequently, evaluation of cephalometric changes in skeletal class III patients using Inter-maxillary miniscrews supported coil spring was our main aim in this study.

## MATERIAL AND METHODS

This study was a randomized clinical trial including a total number of ten patients their age was from 12 to 15 years old selected from the outpatient clinic of Orthodontic Department, Faculty of Dental Medicine for Girls, Al-Azhar University.

Inclusion criteria; Skeletal class III due to maxillary deficiency, Eruption of all permanent teeth, and a concave or straight profile. The patients who had previous orthodontic treatment, any medical problems interfere with orthodontic treatment, Bad oral hygiene were excluded.

With a power of 80% and a significance level of 0.05 percent, the effect size is 0.2, a total sample size of 8 would be sufficient plus 25 % drop out resulting in a total sample size of 10 people.

Research ethic committee approval of the Faculty of Dental Medicine for Girls was obtained. The code number is REC18-OR-028

All patients were informed about the nature, benefits and / or risk of being involved in the present study and informed consent was applied.

Routine orthodontic records were taken including; study cast, lateral cephalometric radiograph, panoramic radiograph, intraoral and extraoral photograph.

### Material used in the study:

1. A Self-drilling pure titanium alloy mini-screws [ Hubit. Hubit co, Korea] with 1.6 mm diameter, 10 mm length; in upper arch and 1.4 mm diameter, 8 mm length; in lower arch were used.
2. The force was immediately delivered 250g using force meter [DTC, orthodontic force meter] on both sides by Nickel Titanium closed coil spring [Ortho Technology, TAD coil spring, 9mm, USA]
3. A fixed posterior bite plate using chemical curing glass ionomer [ Kromoglass, LASCOD, Italy].

A Self-drilling pure titanium alloy mini-screws with 1.6 mm diameter, 10 mm length; in upper arch and 1.4 mm diameter, 8 mm length; in lower arch were used. The position of the miniscrews was determined to be in the buccal dentoalveolus, between second premolar and first molar bilateral with in upper arch and between canine and first premolar bilateral in the lower arch, at the level of mucogingival junction. Each patient had four miniscrews one in each quadrant. the four miniscrews were placed at the same time. the force was immediately delivered (250g using force meter) on both sides by closed coil spring.

### Miniscrews placement (Fig. 1)

The patient was instructed to rinse his/her mouth for 30 seconds with a 0.12% chlorhexidine mouth wash to disinfect the oral tissues. The miniscrews position was assessed relative to the roots using Panoramic or periapical radiographs.

Immediately before insertion, the area of placement swapped with 10% povidone-iodine<sup>^</sup>, Moreover 1mm of local anesthesia solution injected in the mucogingival sulcus adjacent to the placement area. After the area became anesthetized, gingiva was bunched by periodontal probe producing bleeding point which indicates the exact site of the miniscrew insertion.

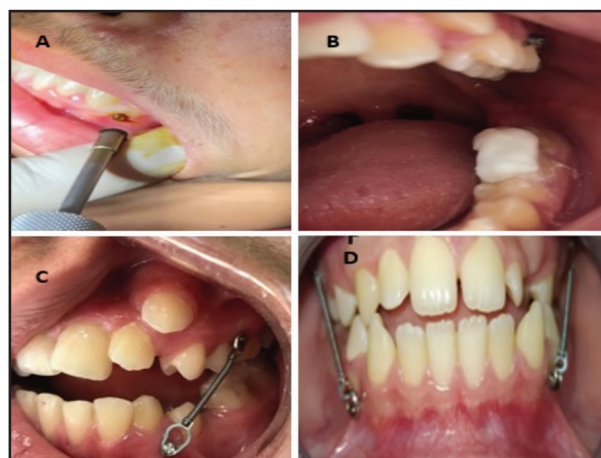

Figure (1) Steps of miniscrew placement and application of coil spring (A) Insertion of miniscrew in the alveolar bone. (B) Placement of fixed posterior bite plate. (C) Modified TAD coil spring placement. (D) Bilateral coil spring placement.

The miniscrew was initially inserted perpendicular to the alveolar bone, then, angulation was changed to 30–40° for the upper arch and 20– 60° for the lower arch. Insertion was done in a steady torque and constant rotation. After insertion, a periapical radiograph was taken to ensure the accuracy of miniscrew position. To eliminate occlusal interferences a fixed glass ionomer posterior bite plate was used which facilitate bite jumping.

Patients were instructed to oral hygiene program including rinsing their mouth with 0.12% chlorhexidine three time daily for one week and if needed, and brushing gently around miniscrews using soft tooth brush after each meal to avoid soft tissues inflammations.

### Force application:

A 9 mm TAD closed coil springs from nickel titanium were used to connect maxillary and mandibular miniscrews. The coil spring was modified through using readymade stainless-steel rings for more adaptation to miniscrews head. The force applied was 250g measured with force gauge. Occlusal interference and applied force were checked every visit. For six months, the appliances were used for at least 18-20 hours a day. By the end of that stage, the patient was being treated with fixed appliances.

## Statistical analysis

The IBM SPSS software package version 20.0 was used to analyze the data (IBM Corporation, Armonk, NY) The normality of the distribution was checked using the Kolmogorov-Smirnov test. Paired t-test and Z: Wilcoxon test were used to check the significance of the results at a 5% level.

## RESULTS

All data and measurement were carried out by the same radiology center, the same machine and the same technical for standardization

As shown in [Table 1], most of cephalometric values presented a significant improvement but there was no statistically significance.

**Table (1)** Pre and post-treatment cephalometric values for patients.

Cephalometric parameter	Pre treatment	Post treatment	Egyptian norm.	test	p
<b>Skeletal</b>					
<b>SNA (°)</b>	80.25 ± 4.95	82.25 ± 4.13	82±4	T=1.965	0.090
<b>SNB (°)</b>	80.63 ± 5.18	81.33 ± 4.17	79±4	T=0.751	0.457
<b>ANB(°)</b>	-0.1 (-1.6 – 1.5)	1.05 (-0.3 – 1.7)	3±4	Z=1.355	0.176
<b>Wits mm</b>	-16 (-18 – -8.5)	-13 (-17.5 – -11)	0-4 mm	Z=0.844	0.398
<b>SN-GoGn</b>	34.6 ± 6.36	34.88 ± 6.41	33	T=0.295	0.776
<b>FMA(°)</b>	27.88 ± 4.39	28.63 ± 4.78	25±3	t=0.704 Z=0.504	0.014*
<b>AFH/PFH (%)</b>	66.63 ± 8.88	67.81 ± 9.51	69±2	T=0.494	0.637
<b>Soft tissue</b>					
<b>S-L (mm)</b>	111.75 ± 20.46	112.38 ± 19.27	62	T=0.194	0.852
<b>S-E (mm)</b>	43.38 ± 7.01	45.38 ± 7.29	22	t=1.183	0.275
<b>Li-NsPog' (mm)</b>	8.15 (3.85 – 10.9)	8.85 (5.18 – 10.63)		Z=0.140	0.889
<b>Dentoalveolar parameter</b>					
<b>POR-DOP(°)</b>	9 (6.5 – 9.25)	7.5 (5.25 – 10)	9.3±3.8	Z=0.315	0.752
<b>Inter incial angle(°)</b>	114.5 ± 15.3	111.13 ± 13.31	125±5.8	t=1.752	0.123
<b>11-OP(°)</b>	27.5 (26.75 – 33)	32 (24.75 – 36.5)	14.5±3.5	Z=1.127	0.260
<b>Mand1-NB(°)</b>	32.85 ± 7.87	37.43 ± 8.42	22.0	t=3.420	0.011*
<b>Max1-NA(°)</b>	32.09 ± 9.2	30.53 ± 8.87	25.0	t=1.660	0.141
<b>U1-MeGo(°)</b>	7.5 (4 – 11)	7.5 (4.75 – 16.25)	1.4±3.8	Z=0.946	0.344

t: Paired t-test      Z: Wilcoxon test      p value for comparing between the studied groups      \*P < .05

SNA The angle formed between sella, nasion and point A

SNB The angle formed between sella, nasion and point B

AFH anterior facial height      PFH Posterior facial height      Li-Nspog lip protrusion      POR-DOP cant of occlusal plane (porion-orbital to Downs occlusal plane)      II inter incisal angle      Mand1-NB lower incisor to nasion and point B

ANB The angle formed between point A, nasion and point B

Wits appraisal Drawn perpendiculars from points A and B onto the occlusal plane and measured the distance between these two points

GoGn/SN The angle formed between mandibular and sella-nasion planes      1/OP upper incisor axis to occlusal plane

FMA The angle formed between the Frankfort horizontal and mandibular planes      Max1-NA maxillary incisor to nasion and A point

S-L The distance from upper lip to Steiner's S line      1/MeGo upper incisor axis to mandibular plane

S-E The distance from lower lip to Rickets esthetic line

The holdaway ratio measures the distance between the lower incisors and the bony jaw. As a result, the distance between the labial surface of the mandibular incisor and the N-B line, as well as the distance between the Pogonion and the N-B line, should be equal. Figure 2 bar chart showing statistically significant difference between pre and post-treatment measures regarding Holdaway ratio.

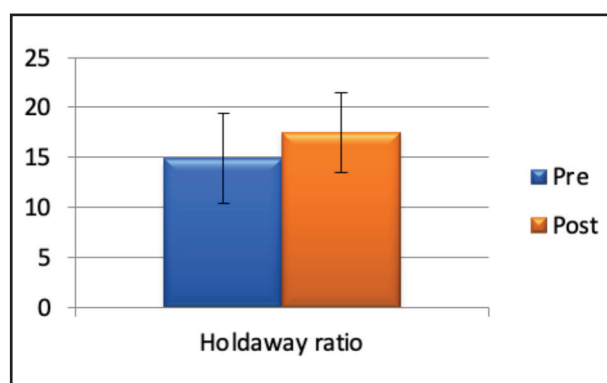


Figure (2) Bar chart for comparison between pre and post treatment measures as regard Holdaway ratio

## DISCUSSION

In Class III due to maxillary deficiency patients, using skeletal anchorage for orthopedic care has been shown to be a promising alternative as compared to conventional protocols<sup>(1-2)</sup>. The main consideration in our research was the ability of miniscrews to withstand orthopedic higher forces. During orthodontic treatment, miniplates are not completely stable, according to some authors, their failure about 7%. These failures are caused by tissue discomfort and infection, which cause peri-implant inflammation and bone loss, resulting in miniplate un stability<sup>(11,12)</sup>. According to a study,<sup>(13)</sup> 16.7% failure of miniscrews during treatment, which is a lower levy regarding the ease of installing the miniscrews and the lack of a surgery to place them.

In this current study, no infections were found. At the first visit after surgery, one patient complained of inflammation of lower lip referring to the miniscrew

head. That was quickly treated by covering the head of the miniscrews with orthodontic soft wax until the inflammation of the soft tissues healed entirely. Generally, performance percentage of the miniscrews anchorage in terms of stability was 90%. Four miniscrews in two separate patients displayed signs of mobility during orthodontic loading due to trauma. Miniscrews had to be removed and replaced in these situations.

Palatine plane rotation and mandible downward and backward rotation in maxillary protraction with teeth supported anchorage resulting in improvement of the skeletal relationship. Another consequence of mesial movement of the posterior teeth – particularly in mixed dentition and dental extrusion, inclination, and increase in vertical dimension was arch length loss<sup>(14-16)</sup>.

It is considered to conclude that the patient's compliance with this technique was greater than it would have been if the facemask had been used, resulting in a favorable psychosocial outcome. Patients may tolerate the force utilized for maxillary traction with miniscrews and an intermaxillary TAD coil spring for 18 hours per day better. The use of the facemask necessitates further cooperation from patients because it entails prejudice in the social lives of children.

When compared to miniplates, another significant aspect was the greater ease and lower degree of discomfort in the miniscrews placement process<sup>(17)</sup>. A previous study Miniscrews loaded with 50 g (100 percent stable) were found to be more stable than those loaded with 100 g. (94.4 percent stable). In an investigation, higher (100%) success was obtained for miniscrews loaded with 100 and 200 g than for the identical miniscrews loaded with 50 g. (77 percent)<sup>(18)</sup>. In another study<sup>(18)</sup>, all miniscrews survived and the miniscrews were completely stable. Inconsistent results like these point to interactions with other factors that may have contributed to the observed disparities in success rates. Previous research on the impact of various forces on miniscrews indicated that force



magnitudes had no effect on osseointegration<sup>(19,20)</sup>. Because the magnitudes of forces utilized in that investigation were likely within ideal force limitations, the results were unaffected.

In our study, forty miniscrews were inserted, four for each patient (6 females and 4 males) of mean age 12-15 years. All cases were undergone follow up for six months. There was a significant improvement in the facial profile. As shown in [Table 1], there was statistically significant difference between pre and post-treatment measures as regard II, Mand1-NB and Holdaway ratio as regard U1-Apog.

Further studies on this protocol are recommended for longer period with different force magnitudes.

## CONCLUSION

Intermaxillary miniscrews supported coil spring is a promising protocol for treatment of skeletal class III patients. Success depends on proper pre-surgical patient counseling and proper miniscrews placement.

## ACKNOWLEDGMENTS

I wish to thank all of our department members, nurses specially Prof. Samir Abdo, Dr Sara Elkabbany and all staff of Al-Azhar university.

## RECOMMENDATIONS

We recommended further investigation using combination miniscrews with fixed conventional orthodontic appliance.

## CONFLICTS OF INTEREST

The authors declare, no conflict of interest, no financial support.

## REFERENCES

1. Park H, Bayome M, Zahrowski J, Kook Y. Displacement and stress distribution by different bone-borne palatal expanders with facemask: A 3-dimensional finite element analysis. *Am J Orthod and Dentofac Orthop*. 2017;151:105-17.
2. Elnagar M, Elshourbagy E, Ghobashy S, Khedr M, Evans C. Comparative evaluation of 2 skeletally anchored maxillary protraction protocols, *Am J Orthod and Dentofac Orthop*. 2016;150: 751-62.
3. Zere E, Chaudhari P, Sharan J, Dhingra K, Tiwari N. Developing Class III malocclusions: challenges and solutions. *Clin Cosmet Investig Dent*. 2018;10: 99-116
4. Marie A Cornelis, Tepedino M, Vos Riis N, Niu X, Cattaneo P. Treatment effect of bone-anchored maxillary protraction in growing patients compared to controls: a systematic review with meta-analysis *Europ J Orthod*; 2021;43: 51-68.
5. Kakali L, Alharbi M, Pandis N, Gkantidis N, Kloukos D. Success of palatal implants or mini-screws placed median or paramedian for the reinforcement of anchorage during orthodontic treatment: a systematic review, *Europ J Orthod*; 2019;41: 9-20
6. Chen Y, Chang H, Huang C, Hung H, Lai E, Yao C. A retrospective analysis of the failure rate of three different orthodontic skeletal anchorage systems. *Clin Oral Imp. Res* 2017;768-75.
7. Singhal D, Ahuja A, Deepa D. Management of reactive tissue overgrowth due to the placement of orthodontic miniscrew implant: A case series. *J Adv Clin Res Insights* 2020;7: 63-6.
8. Cesura M., Ozturkb V., Afacanb B., Sirinc B, Alkand A. and Ozere T. Comparison of BALP, CTX-I, and IL-4 levels around miniscrew implants during orthodontic tooth movement between two different amounts of force. *Angle Orthod*. 2019;89:30-6
9. Yashwant A, Dilip S, Krishnaraj R, and Ravi K. Does Change in Thread Shape Influence the Pull Out Strength of Mini Implants? An In vitro Study *J Clin Diagn Res*. 2017;11:17-20.
10. Shipley T, Farouk K, and El-Bialy T. Effect of high-frequency vibration on orthodontic tooth movement and bone density *J Orthod Sci*. 2019;8: 8-15.
11. Lee R, Moon W, Hong W. Effects of monocortical and bicortical mini-implant anchorage on bone-borne palatal expansion using finite element analysis, *Am J Orthod and Dentofac Orthop*; 2017;151: 887-97.
12. Liu Y, Yang Z, Zhou J, Xiong P, Wang Q, Yang Y, et al. Comparison of Anchorage Efficiency of Orthodontic Mini-implant and Conventional Anchorage Reinforcement in Patients Requiring Maximum Orthodontic Anchorage: A Systematic Review and Meta-analysis, *Journal of Evidence Based Dental Practice*; 2020;20: 106-10.

13. Souza R, Neto J, Paiva J. Maxillary protraction with rapid maxillary expansion and facemask versus skeletal anchorage with mini-implants in Class III patients: A non-randomized clinical trial. *Prog Orthod* 2019;35; 20-35.
14. Lee S, Koh S, Chung D, Lee J, Lee S, Comparison of skeletal anchorage and tooth-borne maxillary protraction followed by fixed appliance in Class III malocclusion, *Europ J Orthod* ; 2020;42; 193–9.
15. Onem E, Yilmazb HN, Kucukkeles N. Comparison of the effects of rapid maxillary expansion and alternate rapid maxillary expansion and constriction protocols followed by facemask therapy. *Korean J Orthod* 2019;49;49-58.
16. Liu Y, Hou R, Jin H, Zhang X, Zuping W, Li Z et al, Relative effectiveness of facemask therapy with alternate maxillary expansion and constriction in the early treatment of Class III malocclusion, *Am J Orthod and Dentofac Orthop*; 2021,159;321-32.
17. Alharbi F, Almuzian M, Bearn D, Miniscrews failure rate in orthodontics: systematic review and meta-analysis, *Europ J of Orthod*; 2018,40;519–30
18. Dayeh A, Williams R, Trojan T, Claro W, Deformation of the zygomaticomaxillary and nasofrontal sutures during bone-anchored maxillary protraction and reverse-pull headgear treatments: An ex-vivo study, *Am J Orthod and Dentofac Orthoped*, 2019,156;745-57.
19. Chang C, Lin J , Roberts W. Failure rates for stainless steel versus titanium alloy infrazygomatic crest bone screws: A single-center, randomized double-blind clinical trial *Angle Orthod* ;2019;89; 40–6.
20. Oh H, Cha J, Yu H, Hwang C. Histomorphometric evaluation of the bone surrounding orthodontic miniscrews according to their adjacent root proximity. *Korean J Orthod* 2018;48;283-91.