

## Original article

# Alternating Combination Chemotherapy and Radiotherapy in Locoregionally Advanced Head and Neck Cancer

**Hanan Gamal-Eldin Mostafa, Mohamed Abdel Hakeem Mekkawy, Samir Shehata M. Eid, Hussein El-Weshahy and Ola Nabeeh Abdel-Fatah**

*Department of Clinical Oncology and Nuclear Medicine, Department of ENT Surgery, Faculty of Medicine, Assiut University*

**Background:** Alternating chemotherapy and radiotherapy is a minor variation of concurrent chemoradiation. This schedule has been tested in advanced head and neck cancer and has shown superiority over standard radiation in some randomized trials with only marginally greater toxicity. In this study the efficacy and toxicity of alternating chemotherapy and radiotherapy in advanced head and neck cancer was evaluated.

**Patients and methods:** The study was conducted between 2002 and 2005 at the Clinical Oncology Department of Assiut University Hospital, to explore the activity of the schedule of alternating chemotherapy and radiotherapy. Radiotherapy consisted of 60Gy, 2Gy/fraction, 5 fractions/week (weeks 2-3, 5-6, 8-9) alternated with four courses of chemotherapy consisted of IV vinblastine 6mg/m<sup>2</sup>. followed 6 hours later by IM bleomycin 30IU, day1, IV methotrexate 200mg day2, IV leucovorin rescue, day 3 (weeks 1, 4, 7, 10).

**Results:** Fifty patients with stage III & stage IVA unresectable head and neck cancer were included. Complete response was 72 %, partial response 18 %, stable disease 1 % and progressive disease 8%. Main grade 3-4 toxicities were: stomatitis 32 %, dysphagia 28 %, xerostomia 6 % and anemia 14 %. At a median follow-up of 38 months, 3-year overall survival and disease free survival were 32 % and 30 %, respectively. Prognostic factors significant for response and survival were ECOG performance status, pathological grade, anatomical site, node stage and disease stage.

**Conclusion:** Alternating chemotherapy and radiotherapy with vinblastine, methotrexate and bleomycin shows very promising activity and low toxicity in locally advanced head and neck cancer treatment.

**Key words:** alternating chemoradiotherapy, head and neck, squamous cell carcinoma, locally advanced

**Corresponding Author:** Hanan Gamal

**E-mail:** mostafahanan36@yahoo.com

Original  
article

## INTRODUCTION

Head and neck cancer (HNC) is the sixth most common cancer worldwide. Head and neck cancer can originate in the skin or soft tissue, in the upper aerodigestive tracts (oral cavity, oropharynx, hypopharynx, larynx, nasopharynx paranasal sinuses, salivary glands), or in the thyroid<sup>1</sup>. Demographic and geographic factors as well as exposure to different carcinogens (e.g. nicotine, alcohol, viruses) contribute to the differential incidence of these tumors<sup>2</sup>.

As a rule, early-stage (stage I and II) HNC should be managed with a single modality, while advanced tumors are managed with multimodality therapy. Advanced hypopharyngeal or laryngeal squamous cell carcinomas are preferentially managed by surgery followed by radiotherapy or concurrent chemoradiation as organ preservation<sup>3</sup>.

Rapidly alternating chemotherapy and radiotherapy (ACR) is a minor variation of concurrent

chemoradiation (CCR) aimed at minimizing toxicity. This scheduling allows uninterrupted treatment of the tumor, with radiotherapy administered during the pauses between cycles of chemotherapy<sup>4</sup>. One of the first randomized trials showing a significant survival advantage induced by chemoradiation in advanced (HNC) was one of rapidly alternating chemotherapy and radiotherapy<sup>5</sup>.

Decreasing chemoradiation induced toxicity is a major objective in (HNC). Chemoradiation has proven to be superior to radiotherapy alone, but treatment-related toxicities are higher, and an expert staff is required to deliver this complex treatment modality<sup>6,7</sup>.

The objective of the present study was to assess the efficacy of alternating chemoradiotherapy, treatment toxicity, survival and prognostic factors of patients with locally advanced head and neck cancer.

## PATIENS AND METHODS

### Selection of patients:

Patients were selected if they met the following criteria: histopathologically-proven squamous-cell carcinoma of the larynx or hypopharynx; stage III and IVA according to the American Joint Committee (AJCC) 2002 staging system, age <70, Eastern Cooperative Oncology Group (ECOG) performance status 0 or 1, no previous surgery, radiotherapy and/or chemotherapy, and written informed consent. All eligible patients were included in the study.

Pretreatment evaluation included complete history, physical and ENT examination, complete blood count, liver and kidney function tests, chest X-ray. Computerized tomography and/or sonogram were performed when indicated.

### Treatment:

Radiotherapy consisted of 60 Gy (two-dimensional treatment) delivered as a daily single dose of 2 Gy, five times a week (acceptable dose with ACR), during weeks 2-3, 5-6, and 8-9 (two-dimensions). Patients were treated with 6 MV photons. The primary site and upper-mid-neck nodes were treated with shrinking field technique with lateral parallel opposed photon fields (50Gy). The lower neck-supraclavicular regions were treated with an oppositional antero-posterior field (50 Gy). Areas of macroscopic disease were boosted for an additional 10 Gy at 2 Gy per fraction. The dose to the spinal cord was to be limited to 40 Gy.

Chemotherapy regimen consisted of vinblastine 6 mg/m<sup>2</sup> IV followed 6 hours later by bleomycin 30 IU IM day 1, methorexate 200mg IV day 2, leucovorin rescue 5 mg/m<sup>2</sup> IM every 6 hours day 3. Chemotherapy was given during weeks 1, 4, 7, 10.

### Evaluation of response and toxicity:

Response was assessed 6 weeks after the end of treatment by repeating the method for staging according to World Health Organization criteria. Toxicities were evaluated according to EORTC/RTOG toxicity criteria 1995 and National Cancer Institute (NCI) common toxicity criteria version 2.0, 1998.

### Statistical methods:

The primary end point of this study was complete response rate assessment. Response was assessed according to World Health Organization (WHO) criteria<sup>8</sup>. Secondary end points were overall survival and disease-free survival. Chi-square test was used to compare differences in distribution of frequencies among various groups of response. *P*-value 0.05 was considered significant. Overall survival and disease-free survival were calculated using Kaplan-Meier method<sup>9</sup>.

Disease-free survival was calculated from the time of treatment beginning until the time of disease progression at any site including the occurrence of metastases.

Overall survival was calculated from the time of treatment beginning until time of death or last follow-up.

## RESULTS

From December 2002 to July 2005 at Oncology Department in Assiut University Hospital, 50 patients with locoregionally advanced laryngeal and hypopharyngeal cancer entered the study. Sample size was estimated based on the prevalence of squamous cell carcinoma cases who attended the hospital. All patients were examined to sort out the eligible cases. All eligible cases were included in the study.

Table (1) shows the main patients characteristics.

Tumor and nodal staging is presented in Table (2).

Anatomical site and pathological tumor grading are presented in Table (3).

As regard response rate to treatment, thirty-six patients had a complete response (72%), nine patients had partial response (18%), one patient had stable disease (2%) and 4 patients had progressive disease (8%).

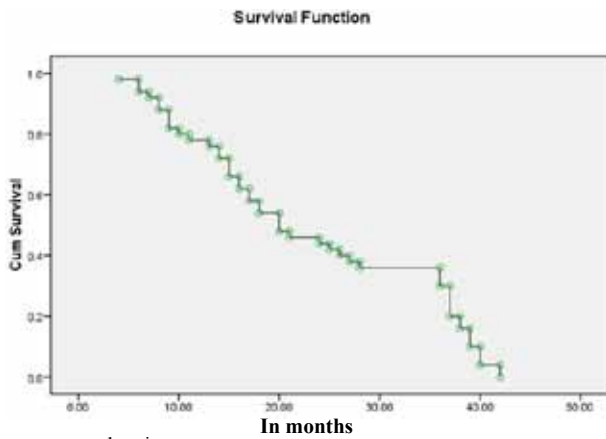
Table (4) shows the significant prognostic factors for response. The stage of the disease, nodal status and anatomical site were significant prognostic factors for response.

Table (5) shows the toxicity of radiotherapy and its frequency according to RTOG/EROTC toxicity criteria 1995.

Table (6) shows the grades of toxicity of chemotherapy and their frequency according to (NCI) grading of toxicity 1998.

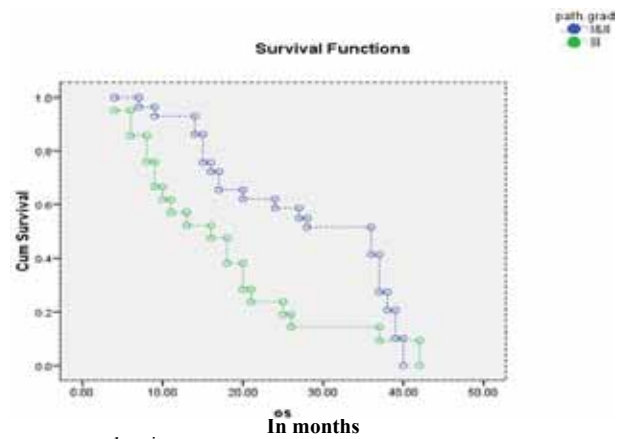
At a median follow-up of 38 months, nine patients (18%) had progression at the tumor site and in four of these patients a recurrence in the lymph nodes of the neck was also observed. Metastases were detected in seven patients (14%), three patients had metastasis in the lung and four in the bone. They were treated by systemic chemotherapy. Three-years overall survival (OS) and disease-free survival (DFS) were 32% and 30%, respectively figure (1, 2).

Prognostic factors for survival were performance status, anatomical site, nodal status, pathological grade and stage of the disease (Figures 3-7).



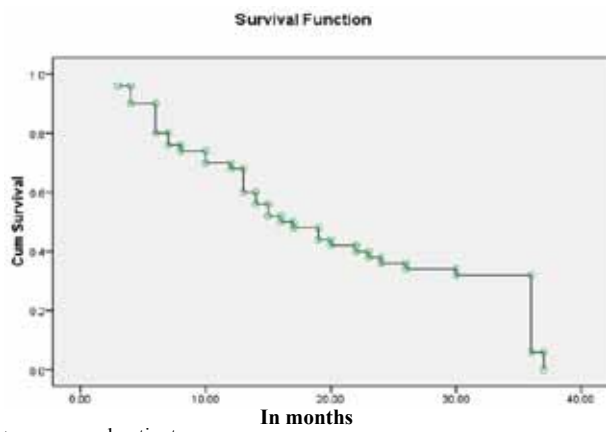
○ = censored patients

**Figure 1:** Overall survival (OS) of 50 patients with locally advanced head and neck cancer treated by alternating chemoradiotherapy. -95% confidence interval 13.076-26.924.



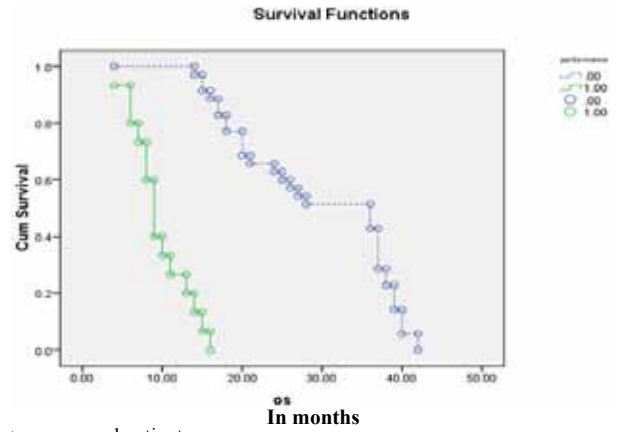
○ = censored patients

**Figure 4:** Pathological grade as a prognostic factor for survival of 50 patients with locally advanced head and neck cancer treated by alternating chemoradiotherapy (grade I& II vs III,  $P < .003$ )



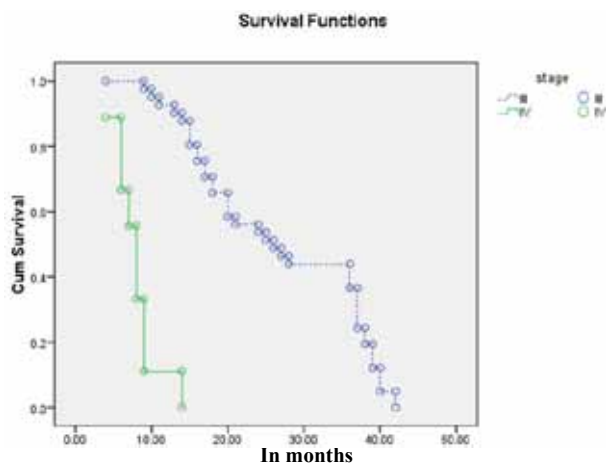
○ = censored patients

**Figure 2:** Disease free survival (dfs) of 50 patients with advanced head and neck cancer treated by alternating chemoradiotherapy. -95% confidence interval 10.225-21.775.



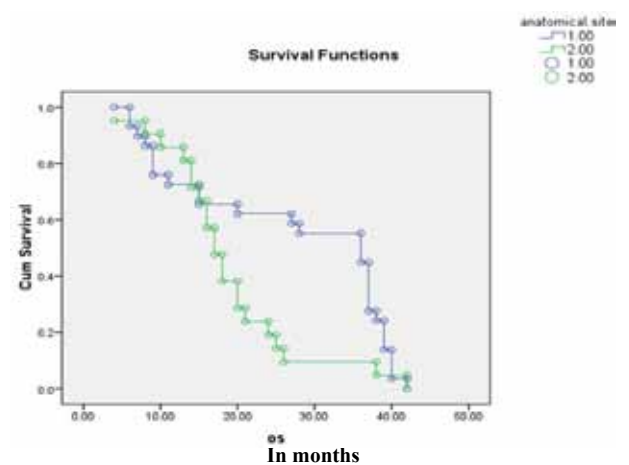
○ = censored patients

**Figure 5:** Performance status (ECOG) as a prognostic factor for survival of 50 patients with locally advanced head and neck cancer treated by alternating chemoradiotherapy (0 vs 1,  $P < .001$ ).



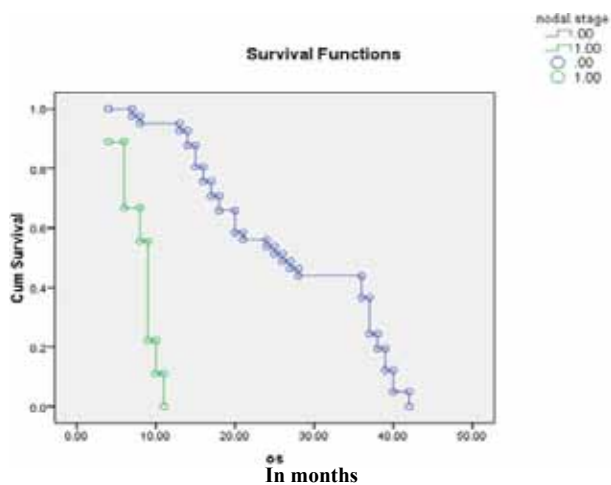
○ = censored patients

**Figure 3:** Stage of the disease as a prognostic factor for survival of 50 patients with locally advanced head and neck cancer treated by alternating chemoradiotherapy (stage III vs IV,  $P < .001$ ).



○ = censored patients

**Figure 6:** Anatomical site as a prognostic factor for survival of 50 patients with locally advanced head and neck cancer treated by alternating chemoradiotherapy (larynx vs hypopharynx,  $P < .023$ ).



○ = censored patients

**Figure 7:** Nodal state as a prognostic factor for survival of 50 patients with locally advanced head and neck cancer treated by alternating chemoradiotherapy (node -ve vs. node +ve,  $P < .001$ ).

**Table 1:** Patients Characteristics.

Patient character	Patient number (%)
<b>Age</b>	
≤40	11 (22%)
41-50	9 (18%)
51-60	10 (20%)
>60	20 (40%)
Mean age (range 40-60)	54.7 (standard deviation 13.94)
<b>Sex</b>	
Male	33 (66%)
Female	17 (34%)
<b>Performance Status (ECOG)</b>	
Grade (0)	35 (70%)
Grade (1)	15 (30%)
<b>Clinical Staging</b>	
Stage III	42 (84%)
Stage IVA	8 (16%)

ECOG: Eastern Cooperative Oncology Group

**Table 2:** Tumor (T) and node (N) Staging.

	T <sub>1</sub>	T <sub>2</sub>	T <sub>3</sub>	T <sub>4</sub>	Total
N <sub>0</sub>	-	-	36	5	41
N <sub>1</sub>	-	-	6	1	7
N <sub>2</sub>	-	-	-	2	2
Total	-	-	42	8	50

**Table 3:** Tumor Site and Histopathological Grading.

Endoscopic Site	Number (%)
<b>Larynx</b>	
Supraglottic	10(20%)
Transglottic	18(36%)
<b>Hypopharynx</b>	
Posterioricoid	11(22%)
Pharyngeal wall	2(4%)
Pyriiform sinus	9(18%)
<b>Nodal metastases</b>	
(-ve) lymph nodes enlargement	41(82%)
(+ve) lymph nodes enlargement	9(18%)
<b>Pathological grading</b>	
Grade1	12(24%)
Grade2	17(34%)
Grade3	21(42%)

(-ve): no lymph node enlargement

(+ve): lymph node enlarged

**Table 4:** Prognostic Factors for Response to Alternating Chemoradiotherapy.

Prognostic factors	CR(%)	PR(%)	SD(%)	PD(%)	P-V
Age					
<55y	19(76)	4(16)	-	2(8)	0.74
≥55y	17(68)	5(20)	1(4)	2(8)	
Performance state					
Grade 0	27(79)	5(15)	1(3)	1(3)	0.15
Grade 1	9(56)	4(25)	-	3(19)	
Anatomical site					
Laryngeal	23(82)	4(14)	1(4)	-	0.04
Hypopharyngeal	13(59)	5(23)	-	4(18)	
Cervical lymph node					
- Ve	34(83)	5(12)	-	2(5)	0.002
+ Ve	2(22)	4(45)	1(11)	2(22)	
Staging					
Stage III	34(81)	6(14)	-	2(5)	0.003
Stage IV A	2(25)	3(38)	1(12)	2(25)	
Grading					
Grade 1	10(84)	0	1(8)	1(8)	0.175
Grade 2	13(76)	4(24)	0	0	
Grade 3	13(62)	5(24)	0	3(14)	

CR: complete response

PR: partial response

SD: stable disease

PD: progressive disease

**Table 5:** RTOG EORTC Radiation Toxicity Among 50 Patients with Locally Advanced Head and Neck Cancer Treated by Alternating Chemo-radiotherapy.

Toxicity	Grade	No. (%)
Mucositis	G1	28(56)
	G2	17(34)
	G3	5(10)
Xerostomia	G1	21(42)
	G2	26(52)
	G3	3(6)
Dysphagia	G0	2(4)
	G1	16(32)
	G2	18(36)
	G3	14(28)
Stomatitis	G1	6(12)
	G2	28(56)
	G3	9(18)
	G4	7(14)
Dermatitis	G0	15(30)
	G1	28(56)
	G2	7(14)

## DISCUSSION

Alternating chemotherapy and radiotherapy has been tested in advanced head and neck cancer and has shown superiority over standard radiation in some randomized trials with only marginally greater toxicity<sup>10</sup>. The biological mechanisms of interaction between chemotherapy and radiotherapy include interactions at the molecular, cellular and tissue levels. At the molecular level, radiation and drugs cooperate to target DNA, by increasing DNA damage and interfering with DNA repair. At the cellular level, chemoradiation may induce cytotoxic cooperation. Radiosensitivity changes during the phases of the cell cycle. The S-phase is the most radioresistant, whereas S-phase cells are highly sensitive to several anticancer drugs. This is the reason why a greater cell kill is observed when proliferating cells are exposed to drugs and radiation in close temporal proximity<sup>11</sup>.

There is one additional mechanism of action that may be ascribed to ACR. The breaks between radiotherapy treatments (that result in tumor repopulation) are filled up with chemotherapy. Therefore, a cytotoxic mechanism of cooperation, exploiting tumor repopulation, may be at work in ACR<sup>12</sup>.

At the tissue level, cooperation between radiation and the chemotherapy drugs is the result of rapid tumor shrinkage and reoxygenation resulting from an improved blood supply. This effect could be related to a reduction in interstitial pressure<sup>13</sup>.

The present study design is similar to the original trials used vinblastine, bleomycin and methotrexate (VBM) and radiotherapy was delivered as a standard single daily fraction in an alternating schedule<sup>14</sup>. The present study shows a complete response (CR) 72%, disease-free survival (DFS) and overall survival (OS) at 3years, 32% and 30%, respectively. This is not in agreement with the results of Merlano *et al.*<sup>14</sup> who used the same schedule and reported CR 33%, DFS and OS at 4 years 12% and 22%, respectively. The difference may be due to the high percentage of patients with stage IV in his study.

The schema of VBM was replaced with the combination of cisplatin and fluorouracil in light of the accepted superiority of this regimen. Fluorouracil was added to cisplatin because of the supposed synergism between the two drugs. More over, it was delivered as an IV bolus to minimize mucosal toxicity, which is mainly induced by the continuous infusion of the drug. In this way, the overlapping mucosal toxicity between chemotherapy and radiotherapy is in theory reduced<sup>10</sup>.

Two studies used ACR schedule with the combination of cisplatin and fluorouracil. The first one done by

Merlano *et al.*<sup>5</sup> who compare ACR and radiotherapy alone, CR was achieved in 42%, 3years OS was 41% which were significantly higher than radiotherapy alone. The second study was done by Corvo *et al.*<sup>15</sup> who reported 3years OS 37% and DFS 35%. The lower OS and DFS in the present study compared with their results may be due to the high percentage of hypopharyngeal carcinoma 44%, high percentage of grade III carcinoma 42% and non-surgical management of locoregional recurrence in the present study.

Alternating chemoradiotherapy in locally advanced HNC, regardless of the chemotherapy regimens is more likely to be associated with complete response<sup>16</sup>. To increase the response of ACR induction chemotherapy was given before it as in the study done by Benasso *et al.*<sup>17</sup> who reported CR86.7%, PR13.3%, 3years DFS and OS, 64% and 83%, respectively.

An investigational program to explore a modified alternating regimen (cisplatin+ fluorouracil) was done by Benasso *et al.*<sup>18</sup> including gemcitabine given both with radiosensitizing and cytotoxic intent. Complete response was achieved in 72%, 3years OS and DFS was 43% and 39%, respectively. Data of locoregional control favorably compared with those from database of patients treated with alternating cisplatin-fluorouracil and radiation within controlled clinical trials (64% versus 40%).

Another trial done by Benasso *et al.*<sup>19</sup> who added gemcitabine to the alternating cisplatin-fluorouracil and reported that the addition of gemcitabine at low dose (50mg/m<sup>2</sup> on each Monday of radiotherapy) is feasible and very active. It may improve long-term outcomes despite an acceptable increase of acute mucosal toxicity.

The combination of chemotherapy and radiotherapy inevitably induces more toxic effects than each modality alone. Stomatitis is the major toxic effect of ACR and appears to be strictly related to the chosen drugs and scheduling. Merlano *et al.*<sup>14</sup> who used VBM schedule reported a grade III-IV stomatitis 31%. Corvo *et al.*<sup>15</sup> and Fuwa *et al.*<sup>20</sup> reported 33% and 31% grade III-IV stomatitis with cisplatin-fluorouracil regimen in ACR schedule, all these results are in agreement with the results of the present study.

The addition of gemcitabine to ACR schedule resulted in 81% of 47 treated patients to develop grade III-IV stomatitis which is much higher than the previous results. This can be explained by the use of gemcitabine as a radiosensitizer and cytotoxic drug. Another published phase II trial based on ACR done by Merlano *et al.*<sup>21</sup> who added paclitaxel to cisplatin-fluorouracil and grade III-IV stomatitis occurred in 81% of the 31 treated patients.

A direct comparison between ACR and concurrent chemoradiation (CCR) does not exist, but some studies reported a similar response in both schedules. A study done by Cohen *et al.*<sup>22</sup> who used fluorouracil+hydroxyurea with hyperfractionated radiotherapy, the other study done by Adelstein *et al.*<sup>23</sup> who used concurrent cisplatin-fluorouracil and conventional radiotherapy. Both studies show the same response to therapy as ACR.

As regard one-year DFS and OS in the present study which was 70% and 78%, respectively, it is comparable with the one-year DFS and OS of the study done by Montejo *et al.*<sup>24</sup> which was 73% and 73%, respectively on CCR, but the 2-years DFS and OS in his study was 73% and 65% which is higher than the present study this is may be due to the use of IMRT in his trial.

In a study done by Specenier *et al.*<sup>25</sup> who used CCR and reported a high percentage of non-hematological toxicity, and also Watkins *et al.*<sup>26</sup> reported a grade III mucositis, nausea and neutropenia, 61%, 27% and 81%, respectively which is higher than the present study. This suggests a more favorable toxicity profile of ACR.

As regard the prognostic factors for response to treatment with ACR in the present study, the anatomical site ( $P=0.04$ ), nodal stage ( $P=0.002$ ) and stage of the disease ( $P=0.003$ ) were significant prognostic factors. This is in agreement with the results reported by Benasso *et al.*<sup>16</sup> who revealed that the size of the primary tumor ( $P=0.004$ ), nodal involvement ( $P=0.02$ ) and performance status ( $P=0.009$ ) are prognostic variables affecting the probability of achieving a complete response.

Prognostic factors significant for survival in the present study were performance status, pathological grade, anatomical site, stage of the disease and nodal stage. This is in agreement with the results reported by Khademi *et al.*<sup>27</sup> according to their multivariate analysis of OS, patients under 40 years, node stage and stage of the disease were significant prognostic factors. Another study done by Vermorken *et al.*<sup>28</sup> revealed that tumor differentiation, ECOG performance status, weight loss and location of the primary were significant prognostic factors.

## CONCLUSION

Alternating chemotherapy and radiotherapy shows a promising activity and low toxicity in locally advanced head and neck cancer treatment. However, a randomized trials comparing alternating chemoradiation with concurrent chemoradiation are mandatory in order to definitely establish the role of these two different schedules of chemoradiation.

## REFERENCES

- Gil Z, Fliss DM. Contemporary management of head and neck cancers. *Israel Med. Assoc. J.* 2009;11(5):296-300.
- Nagler RM, Reznick AZ. Cigarette smoke effects on salivary antioxidants and oral cancer - Novel concepts. *Israel Med. Assoc. J.* 2004;6(11):691-4.
- Shah JP, Gil Z. Current concepts in management of oral cancer - Surgery. *Oral Oncol.* 2009;45(4-5):394-401.
- Haffty BG. Concurrent chemoradiation in the treatment of head and neck cancer. *Hematol. Oncol. Clin. North Am.* 1999;13(4):719-42.
- Merlano M, Vitale V, Rosso R, Benasso M, Corvo R, Cavallari M, *et al.* Treatment of advanced squamous-cell carcinoma of the head and neck with alternating chemotherapy and radiotherapy. *N. Engl. J. Med.* 1992;327(16):1115-21.
- Pignon JP, Bourhis J, Domenge C, Designé L. Chemotherapy added to locoregional treatment for head and neck squamous-cell carcinoma: Three meta-analyses of updated individual data. *Lancet* 2000; 355(9208):949-55.
- Merlano M, Marchetti G. Radiochemotherapy in head and neck cancer. *Cancer Treat. Rev.* 2003;29(4):291-6.
- Miller AB, Hoogstraten B, Staquet M, Winkler A. Reporting results of cancer treatment. *Cancer* 1981;47(1):207-14.
- Kaplan EL, Meier P. Non-parametric estimation for incomplete observation. *J. Am. Stat. Assoc.* 1958;53:457-81.
- Merlano M. Alternating chemotherapy and radiotherapy in locally advanced head and neck cancer: An alternative? *Oncologist* 2006;11(2):146-51.
- Hennequin C, Favaudon V. Biological basis for chemoradiotherapy interactions. *Eur. J. Cancer* 2002;38(2):223-30.
- Glynn Jones R, Sebag Montefiore D. Chemoradiation schedules - What radiotherapy? *Eur. J. Cancer* 2002;38(2):258-69.
- Koukourakis MI. Tumour angiogenesis and response to radiotherapy. *Anticancer Res.* 2001;21(6 B):4285-300.
- Merlano M, Corvo R, Margarino G, Benasso M, Rosso R, Sertoli MR, *et al.* Combined chemotherapy and radiation therapy in advanced inoperable squamous cell carcinoma of the head and neck. The final report of a randomized trial. *Cancer* 1991;67(4):915-21.
- Chua DTT, Sham JST, Wei WI, Ho WK, Au GKH. Alternating chemoradiotherapy versus partly accelerated radiotherapy in locally advanced squamous cell carcinoma of the head and neck: Results from a phase III randomized trial. *Cancer* 2001; 92(11):2856-67.
- Benasso M, Bonelli L, Numico G, Corvò R, Sanguineti G, Rosso R, *et al.* Treatment with cisplatin and fluorouracil alternating with radiation favourably affects prognosis of inoperable squamous cell carcinoma of the head and neck: Results of a multivariate analysis on 273 patients. *Ann. Oncol.* 1997;8(8):773-9.
- Benasso M, Sanguineti G, D'Amico M, Corvò R, Ricci I, Numico G, *et al.* Induction chemotherapy followed by alternating chemo-radiotherapy in stage IV undifferentiated nasopharyngeal carcinoma. *Br. J. Cancer* 2000;83(11):1437-42.

18. Benasso M, Corvò R, Ponzanelli A, Sanguineti G, Ricci I, Pallesstrini E, *et al.* Alternating gemcitabine and cisplatin with gemcitabine and radiation in stage IV squamous cell carcinoma of the head and neck. *Ann.Oncol.* 2004;15(4):646-52.
19. Benasso M, Vigo V, Bacigalupo A, Ponzanelli A, Marcenaro M, Corvò R, *et al.* A phase II trial of low-dose gemcitabine and radiation alternated to cisplatin and 5-fluorouracil: An active and manageable regimen for stage IV squamous cell carcinoma of the head and neck. *Radiother.Oncol.* 2008;89(1):44-50.
20. Fuwa N, Kano M, Toita T, Shikama N, Kodaira T, Matsumoto A, *et al.* Alternating chemoradiotherapy for nasopharyngeal cancer using cisplatin and 5-fluorouracil: A preliminary report of phase II study. *Radiother.Oncol.* 2001;61(3):257-60.
21. Merlano M, Russi EG, Numico G, Colantonio I, Garrone O, Pelissero A, *et al.* Paclitaxel, cisplatin, 5-fluorouracil and radiotherapy in the management of advanced squamous cell carcinoma of the head and neck. A phase II trial. *Radiother.Oncol.* 2005;75(2):193-6.
22. Cohen EEW, Haraf DJ, List MA, Kocherginsky M, Mittal BB, Rosen F, *et al.* High survival and organ function rates after primary chemoradiotherapy for intermediate-stage squamous cell carcinoma of the head and neck treated in a multicenter phase II trial. *J.Clin.Oncol.* 2006;24(21):3438-44.
23. Adelstein DJ, Saxton JP, Rybicki LA, Esclamado RM, Wood BG, Strome M, *et al.* Multiagent concurrent chemoradiotherapy for locoregionally advanced squamous cell head and neck cancer: Mature results from a single institution. *J.Clin.Oncol.* 2006;24(7):1064-71.
24. Montejo ME, Shrieve DC, Bentz BG, Hunt JP, Buchman LO, Agarwal N, *et al.* IMRT with simultaneous integrated boost and concurrent chemotherapy for locoregionally advanced squamous cell carcinoma of the head and neck. *Int.J.Radiat.Oncol.Biol.Phys.* 2011;81(5):e845-52.
25. Specenier PM, Van den Weyngaert D, Van Laer C, Weyler J, Van den Brande J, Huizing MT, *et al.* Phase II feasibility study of concurrent radiotherapy and gemcitabine in chemo-naïve patients with squamous cell carcinoma of the head and neck: Long-term follow up data. *Ann.Oncol.* 2007;18(11):1856-60.
26. Watkins JM, Zauls AJ, Wahlquist AH, Shirai K, Garrett Mayer E, Gillespie MB, *et al.* Low-dose weekly platinum-based chemoradiation for advanced head and neck cancer. *Laryngoscope* 2010;120(2):236-42.
27. Khademi B, Mahmoodi J, Omidvari S, Mohammadianpanah M. Treatment results of nasopharyngeal carcinoma: A 15-year single institutional experience. *J.Egypt.Natl.Cancer Inst.* 2006;18(2):147-55.
28. Vermorken JB, Specenier P. Optimal treatment for recurrent/metastatic head and neck cancer. *Ann.Oncol.* 2010;21(Suppl. 7):vii252-61.