

## The Role of Contrast-Enhanced Mammography in the Pre-Operative Assessment of Breast Cancer

SHERIHAN W.Y. GAREER, M.D.<sup>1</sup>; NADA E. ABBASS, M.Sc.<sup>2</sup>; ABEER A. EL SHARAWY, M.D.<sup>3</sup>; REHAB EL BADRY, M.D.<sup>3</sup>; REHAB EL SHEIKH, M.D.<sup>4</sup>; TAREK M. ABDEL-HAMID, M.D.<sup>5</sup> and ABDULLAH H. AHMED, M.D.<sup>6</sup>

*The Department of Radiodiagnosis, National Cancer Institute, Cairo University<sup>1</sup>, Radiodiagnosis Department, Om-Elmasreen General Hospital<sup>2</sup>, Department of Radiodiagnosis at NCI<sup>3</sup>, Radiology Department, Faculty of Medicine, MUST University<sup>4</sup>, Department of Radiodiagnosis Department, Faculty of Medicine (for Boys), Al-Azhar University<sup>5</sup> and Radiodiagnosis Department, Faculty of Medicine (for Girls), Al-Azhar University<sup>6</sup>*

### Abstract

**Background:** Accurate staging of breast cancer is vital in establishing a correct treatment plan. Contrast enhanced Spectral mammography (CESM), an established technique that can provide more information regarding the number and size of lesions, can help in deciding the surgical outcome.

**Aim of Study:** Examine the effectiveness of (CESM) in identifying multiple breast cancer lesion, whether multifocal or multicentric and assessing tumor size prior to treatment planning.

**Patients and Methods:** Prospective study done in both the National Cancer Institute and Al-Azhar University from 2021 to 2024 involving 200 female patients with solid breast masses classified as BI-RADS IV or V using conventional mammography and ultrasound. All patients underwent standard 2D mammography and CESM, with results compared to post-operative pathology reports which served as the gold standard.

**Results:** CESM demonstrated a higher accuracy than digital mammography in detecting other lesions with a respective value of 96.5% and 72.5%. it demonstrated.

- **Multiplicity Detection:** CESM identified multifocal lesions in 86 patients and multicentric lesions in 97, while pathology confirmed multifocal lesions in 87 and multicentric lesions in 93. CEM demonstrated higher accuracy (96.5%) compared to digital mammography (72.5%).
- **Tumor Size Assessment:** CESM showed 63% concordance with pathology, while digital mammography had only 34% concordance. CEM tended to slightly overestimate tumor size, whereas digital mammography often underestimated it.
- **T Staging:** CESM accurately staged 94% of cases, compared to 84% with digital mammography.

**Conclusion:** CESM significantly improves the detection of lesion multiplicity and provides more accurate tumor size measurements, making it a valuable tool for pre-operative evaluation and treatment planning in breast cancer.

**Key Words:** Contrast-enhanced spectral mammography – Breast cancer – Staging – Multifocality – Multicentricity.

### Introduction

**BREAST** cancer is the most frequently diagnosed cancer among women worldwide, with close to 2 million new cases and 685,000 deaths reported in 2020 [1]. In Egypt, breast cancer represents 38.8% of female cancers and 19.6% of all cancers, according to the National Cancer Institute (NCI) registry [2].

Contrast-enhanced mammography (CEM) is an advanced imaging technique that enhances the visualization of breast lesions by utilizing a contrast agent to highlight tumor neo-angiogenesis [3]. Studies have shown that CEM has a sensitivity ranging from 93% to 100% and a specificity of 63% to 88% in detecting malignant lesions [4]. It is particularly useful in evaluating dense breast tissue [5] and at present it is used as an adjunct tool to digital mammography in the work up of both breast symptoms and inconclusive findings, screening, being an alternative to MRI in high risk patients, and in both staging newly diagnosed breast cancer as well as assessing response to neoadjuvant chemotherapy [6].

This study focuses on the role of CEM in detecting multifocal and multicentric breast cancers and accurately measuring tumor size findings essential in formulating the suitable treatment strategy.

**Correspondence to:** Dr. Sherihan W.Y. Gareer,  
E-Mail: [sherihangareer@gmail.com](mailto:sherihangareer@gmail.com)

## Patients and Methods

**Study design:** This prospective study included 200 female patients aged 30–75 years with suspicious breast masses (BI-RADS IV and V) referred to the National Cancer Institute and Al-Azhar University Hospital. Ethical Approval was granted (IRB#2018122001).

**Inclusion criteria:** Patients with solid breast masses showing indistinct or spiculated margins, irregular shape, or suspicious microcalcifications on mammography or ultrasound.

**Exclusion criteria:** Patients with contraindications to mammography (pregnant patients) or contrast agents (e.g., renal insufficiency, contrast allergy).

### Imaging protocol:

- 1- Digital Mammography (DM): Standard 2D mammography was performed using a Senographe 2000 D system.
- 2- Contrast-Enhanced Spectral Mammography (CESM): Patients received an intravenous injection of iohexol (1.5ml/kg), followed by low-energy and high-energy imaging. Recombined images were generated to highlight areas of contrast uptake.
- 3- All images were revised by two radiologists: A junior with a three year experience and a senior radiologist with more than 10 years experience.

**Pathological assessment:** Post-operative pathology reports served as the gold standard for tumor size and multiplicity.

**Statistical analysis:** Data were analyzed using SPSS version 26. Diagnostic accuracy, sensitivity, specificity, and correlation coefficients were calculated [7,8].

## Results

This study included 200 patients; all of them had breast lesions on basic examination including digital mammogram followed by the 2D B mode ultrasound with further CESM imaging (contrast-enhanced spectral mammogram) done. Median age was 54.5 years with an age range from 35–75 years and a mean age of 54.8 years (SD=10).

### Histopathology Results:

- o 180 patients had malignant IDC pathology (90%).
- o 13/200 lesions were mixed IDC and ILC (6.5%).
- o 7/200 were ILC (3.5%).
- Surgical Procedures:
  - o The majority of patients underwent MRM: 150/200 (75%).
  - o 43/200 (21.5%) underwent CBS.
  - o 7/200 (3.5%) underwent lumpectomy.

### Detection of multiplicity:

To be defined as multifocal, two or more separate foci had to be in the same breast quadrant. Multicentric disease on the other hand was defined as the presence of two or more separate foci in the different quadrant of the same breast. When differentiation was difficult, tumors were considered multifocal if the distance was  $\leq 5$ cm and multicentric if the distance was  $> 5$ cm.

### Accuracy, Sensitivity, and Specificity:

The following values were calculated to assess accuracy, sensitivity, and specificity:

- True positive (TP): Cases correctly depicting multiplicity
- False positive (FP): Cases incorrectly depicting multiplicity.
- True negative (TN): Cases correctly depicting single lesions.
- False negative (FN): Cases incorrectly depicting single lesions.

CESM was able to show a higher sensitivity and specificity of 98.18% and 80% respectively, with overall accuracy of 96.7% when compared to post-operative pathology. This is in comparison to the 73.3% sensitivity, 66% specificity and 74% accuracy results achieved by digital mammography.

The CESM false positive cases were enhancing lesions of a benign pathology while positive negative results were attributed to bad positioning and posterior location.

### Lesion size:

The largest dimension of the lesion was measured in mm by each modality and compared to the largest dimension of the pathology specimen. When more than one lesions were present, the largest lesion was measured.

- CESM:
  - o 62% concordant (n=124).
  - o 30% overestimated (n=60).
  - o 8% underestimated (n=16).
- DM:
  - o 37% underestimated (n=74).
  - o 5% not detected (n=10).
  - o 25% overestimated (n=50).
  - o 33% concordant (n=66).

### Staging according to main lesion size:

The “T” staging was applied according to the UICC criteria (AJCC Cancer Staging Manual, 2017).

- CESM: Correct “T” staging was determined in 186 cases (93%) with a sensitivity of 91% and a specificity of 83%.

- DM: Correct “T” staging was determined in 170 cases (85%) with sensitivity 79% and specificity 62%.

*Conclusion:*

- CESM demonstrated superior accuracy (96.7%), sensitivity (98.18%), and specificity (80%) com-

pared to DM (73.3%, 74%, and 66.6%, respectively).

- CESM showed better correlation with pathology in terms of lesion size and staging.
- DM tended to underestimate lesion size and had a higher false-negative rate.

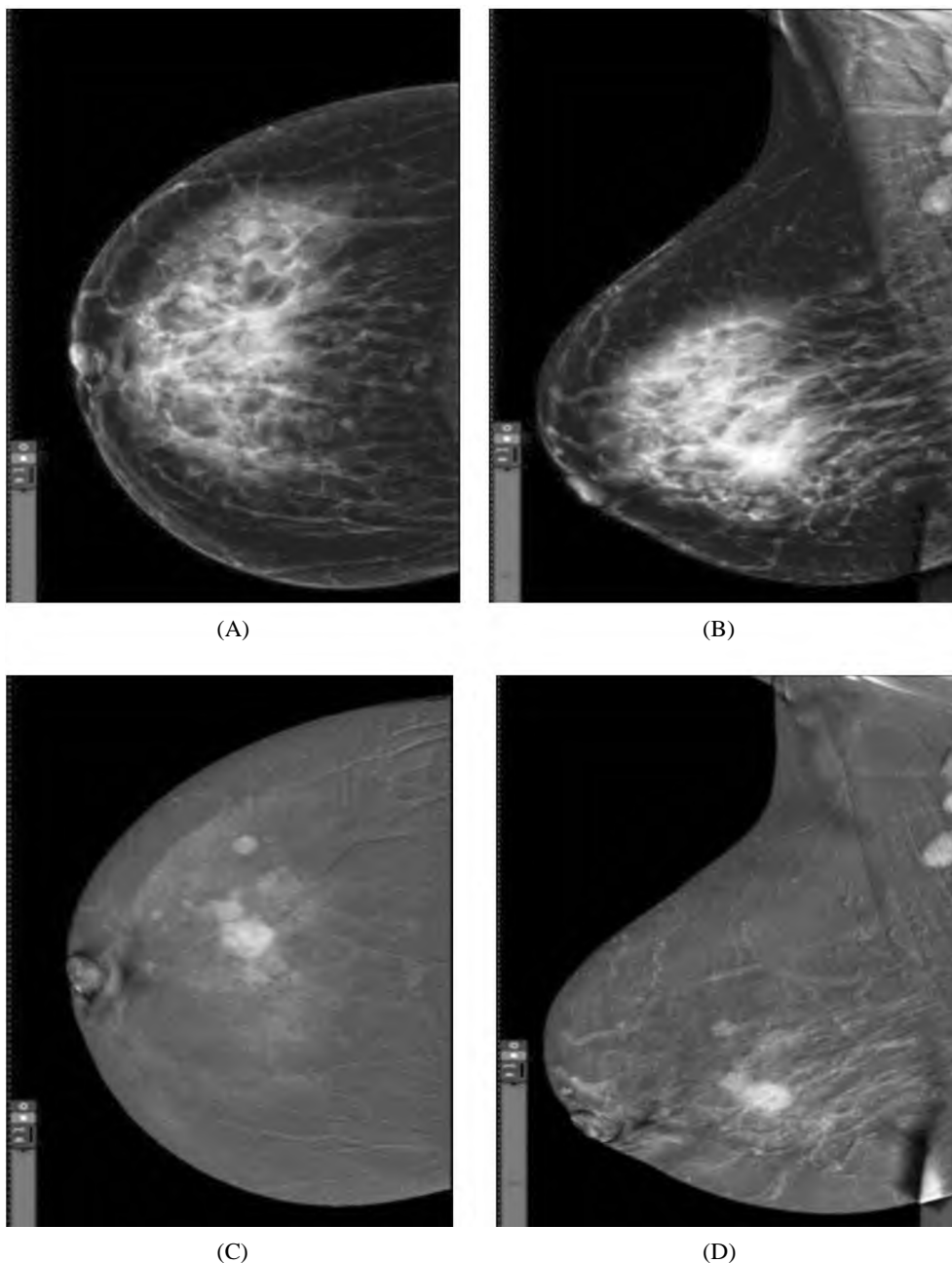


Fig. (1): A 40 years old female patient presented with right breast lump. ACR (B).

A: CC and MLO views of DM; showed a Right lower ill-defined lesion (right single mass) (BIRADS4) with maximum size 42x33mm

B: CC and MLO views of CESM; showed intense heterogeneously enhancing mass area occupying 63x55 mm at lower half & central retromammary region (right multi-centric) (BIRADS5).

Right MRM was done revealing (multi-centric) invasive ductal carcinoma with T3 staging.

Comment: CESM shows underlying lesions not seen on DM. CESM was accurate in diagnosis and “T” staging compared to post-operative pathology.

Fig. (2): A 55 years old female patient presented with bilateral lumps. ACR (D).

A: CC and MLO views of DM; showed:

- Right scattered central and inner clusters of pleomorphic microcalcification.
- Left Upper outer benign microcalcifications.
- Bilateral dilated duct system.

B: CC and MLO views of CESM; showed:

- Right scattered multiple lesions of heterogeneous enhancement; largest measured 55x45mm.
- Left upper outer irregular heterogeneous enhancement lesion measuring 15x12mm and lower inner non-mass enhancement.
- Bilateral multi-centric lesions (BI-RADS4c).

It was diagnosed as invasive ductal carcinoma.

Comment: CESM shows underlying lesions not seen on DM. CESM was accurate in diagnosis regarding size and multiplicity compared to post-operative pathology.

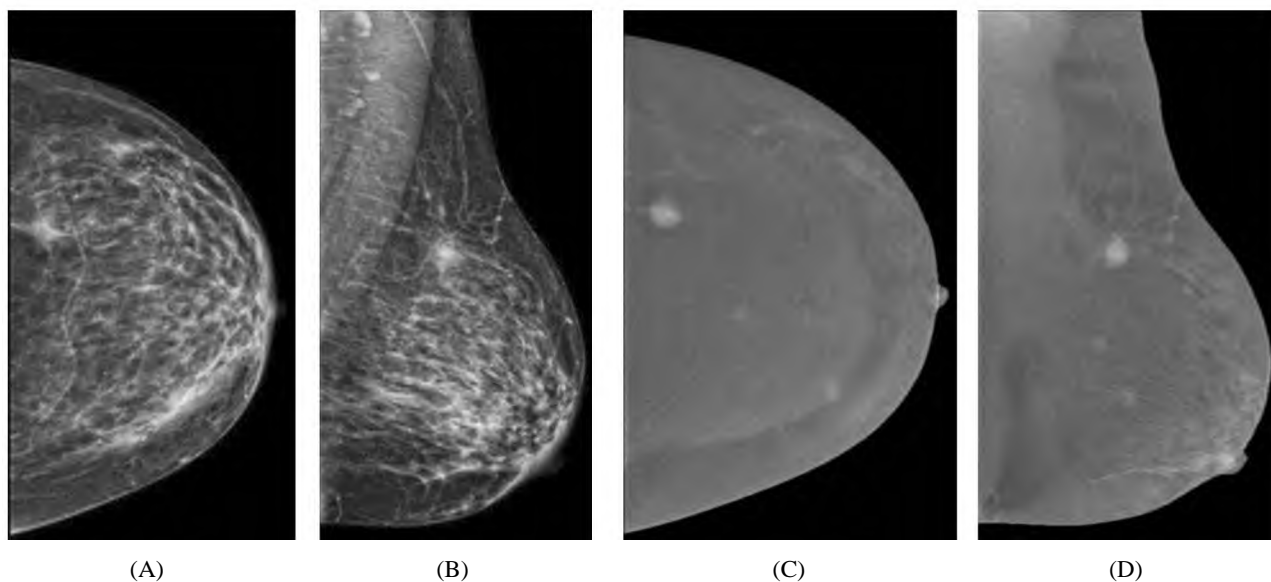
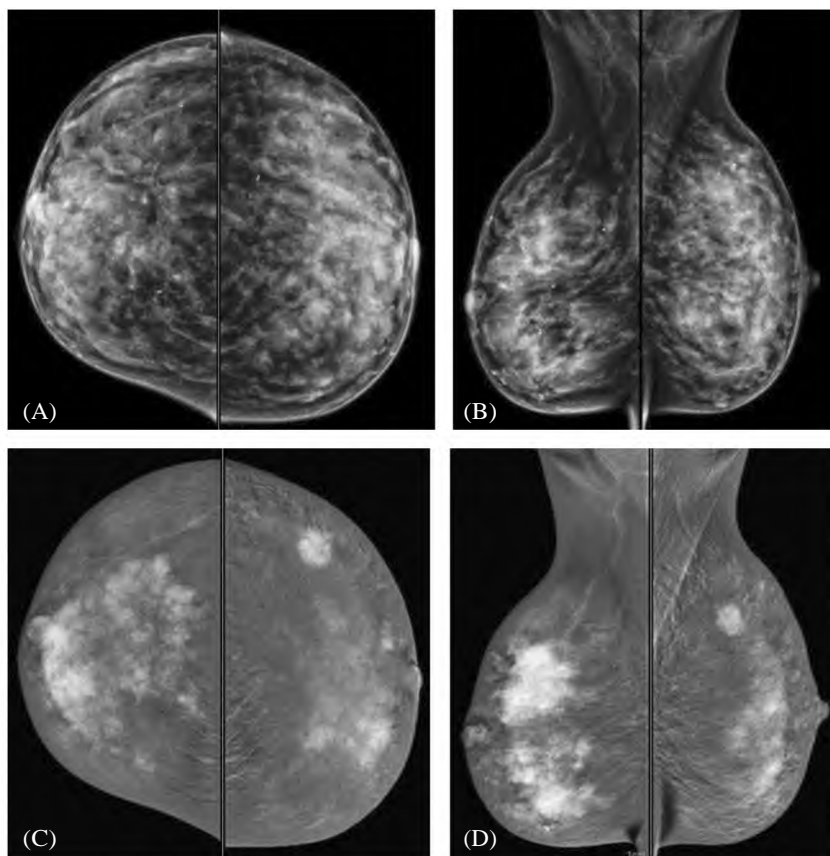


Fig. (3): A 49-year-old female patient presented with left breast lump. ACR (C).

A: CC and MLO views of DM; showed a left breast dense upper outer suspicious looking mass measuring 11x9mm (BIRADS 4C).

B: CC and MLO views of CESM; show left multicentric malignant looking enhancing mass lesion measuring 12x10mm. (BIRADS5). Two smaller enhancing lesions are detected.

Comment: CESM showed underlying lesions not seen on mammography. CESM was accurate diagnosis compared to post-operative pathology revealing "T1" multicentric invasive ductal carcinoma.

Table (1): Showing percentage of detection of multiplicity by mammography, CESM and post excision.

Modality	Patient Count	Percentage
<i>DM:</i>		
Single mass	33	16.7
Cluster of calcifications	17	8.3
Multifocal	73	36.7
Multicentric	67	33.3
Not detected	10	5
<i>CESM:</i>		
Single	17	8.4
Multifocal	87	43.3
Multicentricity	96	48.3
<i>Pathology:</i>		
Single	20	10
Multifocal	87	43.33
Multicentricity	93	46.67

Table (3): Breast cancer size (max. dimension) as detected by DM, CESM & post-operative pathology.

Modality	Mean	Median	SD	p-value	r
DM	17.2mm	15mm	11.2mm	0.034	0.6
CESM	23.6mm	25mm	9.3mm	0.006	0.9
Pathology	21.3mm	20mm	8.1mm	—	—

### Discussion

This study aimed to evaluate the diagnostic capabilities of contrast-enhanced spectral mammography (CESM) in comparison to digital mammography (DM) for identifying multiplicity and assessing tumor size. The results demonstrated that CESM achieved an accuracy of 96.7% in identifying multifocal and multicentric lesions, significantly surpassing the 73.3% accuracy of DM. Furthermore, CESM exhibited superior sensitivity (98%) and specificity (80%) compared to DM (74% and 66%, respectively). These findings are consistent with prior studies, such as Fallenberg et al. [9], who reported a 100% sensitivity for CESM in detecting multiple breast lesions, compared to 82.5% for DM. Similarly, Moustafa et al. [10] observed that CESM identified multifocal and multicentric lesions with a sensitivity of 100%, albeit with a slightly lower specificity of 97.3%.

A systemic review and a metanalysis of eight studies compromising 920 patients with 944 lesions, has also established the high ranking of CESM sensitivity [11]. Similarly, Sumkin et al. [12] and Xiang et al. [13] state that CESM is capable of providing physiological information that with similar diagnostic performance to that of MRI. Gouda et al., in their study found out that CESM can identify additional cancer cases with low-grade cancer or DCIS [14].

Table (2): Showing DM & CESM accuracy, sensitivity and specificity for the detection of the tumor multiplicity as compared to pathology.

Value	DM	CESM
True-positive	133	180
True-negative	13	13
False-positive	7	3
False-negative	47	3
Accuracy	73%	96.7%
Sensitivity	74%	98.1%
Specificity	66.6%	80%
Positive-predictive value	95%	98%
Negative-predictive value	22%	80%
False-positive rate	25.9%	1.8%
False-negative rate	33%	20%

Table (4): T staging of the cases by CESM & DM compared to post-operative pathology.

T Stage	Tumor Not Detected	T1	T2	T3	T4b
DM	10	67	97	10	16
CESM	0	33	123	27	17
Pathology	0	47	117	20	16

However, not all studies have reported such high detection rates for CESM. Jochelson et al. [15] found that CESM detected additional cancer foci in only 56% of cases, compared to 88% for MRI. This discrepancy might be attributed to disparities in study design, patient selection, or imaging procedures. Nevertheless, CESM remains a valuable substitute to MRI, particularly in areas with restricted resources or for patients with contraindications to MRI.

Accurate pre-operative assessment of tumor size is equally critical, as it directly influences surgical planning and the likelihood of achieving clear resection margins. Incomplete or marginal tumor resections often necessitate re-excision, underscoring the importance of precise imaging. In this study, CESM provided a more accurate prediction of tumor size, with 62% of cases concordant with pathological measurements, compared to only 33% for DM. CESM exhibited a tendency toward slight overestimation of tumor size (30% of cases), while DM frequently underestimated it (37% of cases). These results align with those of Bozzini et al. [16], Fallenberg et al. [17], and Lobbes et al. [18], who also reported strong correlations between CESM and pathological tumor size, nevertheless with a tendency toward slight overestimation.

In contrast, Helal et al. [19] noted that CESM occasionally underestimated tumor size, particularly

in cases of invasive lobular carcinoma (ILC), which often presents with diffuse growth patterns. Conversely, Luczyńska et al. [20] reported that both DM and CESM tended to overestimate lesion sizes compared to histopathology. These variations highlight the necessity of integrating imaging findings with clinical and pathological data to optimize treatment planning.

The study also evaluated the accuracy of CESM and DM in T staging, utilizing the UICC criteria (AJCC Cancer Staging Manual, 2017). CESM correctly staged 93% of cases, with a sensitivity of 91% and specificity of 83%, compared to 85% accuracy for DM (sensitivity 79%, specificity 62%). These findings are corroborated by Helal et al. [19], who reported that CESM accurately staged 79.6% of carcinomas, compared to 66.3% for DM. CESM's ability to assess tumor size, margins spiculations, and detect skin or deep muscular involvement renders it a reliable tool for T staging, particularly in early breast cancer (T1 and T2 stages).

#### Limitations of the Study:

*Despite its strengths, this study is subject to several limitations:*

- 1- Sample Size: The study included 200 patients, which, while informative, remains relatively small and impedes generalization of the findings.
- 2- Absence of MRI Comparison: The study did not compare CESM with MRI, which is widely regarded as the gold standard for preoperative breast imaging.
- 3- Technical Challenges: Suboptimal patient positioning or dense breast tissue occasionally compromised the effectiveness of CESM.
- 4- Exclusive Use of CESM: The study did not explore the combined use of DM with 2D ultrasound or CESM, which may have further enhanced diagnostic accuracy.

#### Future Directions:

*To manage these limitations, upcoming research should focus on:*

- 1- Larger Multicenter Studies: To verify the data and establish standardized protocols for CESM.
- 2- Comparison with MRI: To elucidate the relative strengths and weaknesses of CESM in diverse clinical scenarios.
- 3- Integration with Other Modalities: Combining CESM with tomosynthesis or ultrasound may further improve diagnostic accuracy.
- 4- Long-Term Follow-Up: To judge the bearing of CESM on surgical outcomes and long-term patient survival.

#### Conclusion:

Contrast-enhanced spectral mammography (CESM) has demonstrated significant efficacy in the pre-operative assessment of breast cancer, of-

fering superior accuracy in detecting multifocal and multicentric lesions and measuring tumor size compared to digital mammography. While not without limitations, CESM represents a valuable addition to the breast imaging armamentarium, particularly in settings where MRI is unavailable or contraindicated. Its ability to enhance T staging and guide treatment decisions underscores its potential to improve patient outcomes in breast cancer management. Further large-scale studies are warranted to validate these findings and optimize the clinical application of CESM.

#### Conflict of interest:

The authors declare that the research was conducted in the absence of any commercial or financial relationships that could be construed as a potential conflict of interest.

#### Ethics Approval and Consent to Participate:

The study was approved by the ethics committee of the Scientific Research Review Board of the Radiology Department, (Faculty of Medicine for Girls) Al-Azhar University.

Patients included had given informed consent to use their data in research studies.

#### Funding:

None.

*Data Availability Statement:* The data that support the findings of this study are available from the corresponding author upon reasonable request.

#### References

- 1- HYUNA SUNG, JACQUES FERLAY, REBECCA L., et al.: Global cancer statistics 2020: GLOBOCAN estimates of incidence and mortality worldwide for 36 cancers in 185 countries. *A cancer journal for clinicians*, 71: 209–249, 2021.
- 2- ABO-ELAZM O.M., BILAL D., GOUDA, et al.: M.Trends in Demographics and Reproductive Factors in Breast Cancer in Egypt: A Story of 25 Years. *IOSR Journal of Dental and Medical Sciences*, 17 (7): 63-69, 2018.
- 3- BHIMANI C., LI L., LIAO L., et al.: Contrast-enhanced Spectral Mammography: Modality-Specific Artifacts and Other Factors Which May Interfere with Image Quality. *Academic Radiology*, 24 (1): 89-94, 2017.
- 4- TARDIVEL A.M., BALLEYGUIER C., DUNANT A., et al.: Added Value of Contrast-Enhanced Spectral Mammography in Post screening Assessment. *Breast J.*, 22 (5): 520–528, 2016.
- 5- MOKHTAR O. and MAHMOUD S.: Can contrast enhanced mammography solve the problem of dense breast lesions? *The Egyptian Journal of Radiology and Nuclear Medicine*, 45 (3): 1043-1052, 2014.
- 6- NORI J., GILL M.K., VIGNOLI C., et al.: Artefacts in contrast enhanced digital mammography: How can they affect

- diagnostic image quality and confuse clinical diagnosis? *Insights Imaging* 11: (16), 2020.
- 7- JAMES J.J. and TENNANT S.L.: Contrast-enhanced spectral mammography (CESM). *Clinical Radiology*, 73 (8): 715-723, 2018.
- 8- CHEUNG Y.C., JUAN Y.H., LO Y.F., et al.: Preoperative assessment of contrast-enhanced spectral mammography of diagnosed breast cancers, 2020.
- 9- FALLENBERG E.M., DROMAIN C., DIEKMANN F., et al.: Contrast-enhanced spectral mammography versus MRI: Initial results in the detection of breast cancer and assessment of tumour size. *European Journal of Radiology*, 24 (1): 256–264, 2014.
- 10- MOUSTAFA A. FI, KAMAL E.F., HASSAN M.M., et al.: The added value of contrast enhanced spectral mammography in identification of multiplicity of suspicious lesions in dense breast. *The Egyptian Journal of Radiology and Nuclear Medicine*, 49 (1): 259–264, 2018.
- 11- TAGLIAFICO A.S., BIGNOTTI B., ROSSI F., et al.: Diagnostic performance of contrast-enhanced spectral mammography: Systematic review and meta-analysis. *Breast*, 28: 13-19, 2016.
- 12- SUMKIN J.H., BERG W.A., CARTER G.J., et al.: Diagnostic performance of MRI, molecular breast imaging, and contrast-enhanced mammography in women with newly diagnosed breast cancer. *Radiology*, 293: 531–40, 2019.
- 13- XIANG W., RAO H. and ZHOU L.: A meta-analysis of contrast-enhanced spectral mammography versus MRI in the diagnosis of breast cancer. *Thorac Cancer*, 11: 1423–32, 2020.
- 14- GOUDA W., YASIN R., ABO-HEDIBAH S., et al.: Contrast-enhanced mammography compared to MRI for the diagnosis of multifocal and multicentric breast cancer: Pre-operative evaluation. *Egypt J. Radiol. Nucl. Med.*, 56: 15 2025.
- 15- JOCHELSON M.S., DERSHAW D.D., SUNG J.S., et al.: Bilateral contrast-enhanced dual-energy digital mammography: Feasibility and comparison with conventional digital mammography and MR imaging in women with known breast carcinoma. *Radiology*, 266 (3): 743–751, 2013.
- 16- BOZZINI A., NICOSIA L., PRUNERI G., et al.: Clinical performance of contrast-enhanced spectral mammography in pre-surgical evaluation of breast malignant lesions in dense breasts: A single center study. *Breast Cancer Res . Treat.*, 184: 723–731, 2020.
- 17- FALLENBERG E.M., SCHMITZBERGER F.F., AMER H., et al.: Contrast-enhanced spectral mammography vs. mammography and MRI – clinical performance in a multi-reader evaluation *European Radiology*, 27: 2752–2764, 2017.
- 18- LOBBES M.B., LALJI U.C., NELEMANS P.J., et al.: The quality of tumor size assessment by contrast-enhanced spectral mammography and the benefit of additional breast MRI. *J Cancer*, 6 (2): 144–150, 2015.
- 19- HELAL M.H., MANSOUR S.M., ZAGLOL M., et al.: Staging of breast cancer and the advanced applications of digital mammogram: What the physician needs to know?. *The British Journal of Radiology*, 90 (1071): 20160717, 2017.
- 20- LUCZYŃSKA E., HEINZE-PALUCHOWSKA S., DYCZEK S., et al.: Contrast-enhanced spectral mammography: Comparison with conventional mammography and histopathology in 152 women. *Korean Journal of Radiology*, 15 (6): 689-696, 2014.

## الدور الاضافي لأشعة الماموجرام الرقمية بالصبغة فى التوجيه لخطه علاج اورام الثدي

هدفت هذه الدراسة إلى تقييم القدرات التشخيصية للماموجرافى الرقمية بالصبغة بالمقارنة مع الماموجرافى الرقمية فى تحديد التعددية وتقييم حجم الورم. أظهرت النتائج أن للماموجرافى الرقمية بالصبغة حققت دقة بنسبة ٩٦,٧٪ فى تحديد الآفات متعددة البؤر ومتعددة المراكز، متجاوزة بشكل كبير دقة الماموجرافى الرقمية التى بلغت ٧٣,٣٪. علاوة على ذلك، أظهرت للماموجرافى الرقمية بالصبغة حساسية أعلى (٩٨٪) وخصوصية (٨٠٪) مقارنة بالمماموجرافيا الرقمية (٧٤٪ و٦٦٪ على التوالى).

يعد التقييم الدقيق قبل الجراحة لحجم الورم أمراً بالغ الأهمية بنفس القدر، لأنه يؤثر بشكل مباشر على التخطيط الجراحي واحتمالية تحقيق هوامش استئصال واضحة. غالباً ما تتطلب عمليات استئصال الورم غير المكتملة أو الهامشية إعادة الاستئصال، مما يؤكد أهمية التصوير الدقيق. فى هذه الدراسة ، قدم CESM تنبؤاً أكثر دقة لحجم الورم، حيث تتوافق ٦٢٪ من الحالات مع القياسات المرضية، مقارنة بـ ٣٣٪ فقط لـ DM. أظهر CESM ميلاً نحو المبالغة الطفيفة فى تقدير حجم الورم (٣٠٪ من الحالات)، بينما قلل DM فى كثير من الأحيان من تقديره (٣٧٪ من الحالات).

قامت الدراسة أيضاً بتقييم دقة CESM و DM فى التدرج T ، باستخدام معايير UICC (دليل AJCC Cancer Staging Manual ، ٢٠١٧). قام CESM بتنظيم ٩٣٪ من الحالات بشكل صحيح، بحساسية ٩١٪ وخصوصية ٨٣٪ ، مقارنة بدقة ٨٥٪ للمرض (الحساسية ٧٩٪، الخصوصية ٦٢٪).

كما أظهر التصوير الماموجرافى الرقمية بالصبغة فعالية كبيرة فى تقييم سرطان الثدي قبل الجراحة، مما يوفر دقة فائقة فى الكشف عن الآفات متعددة البؤر ومتعددة المراكز وقياس حجم الورم مقارنة بالتصوير الشعاعى للثدى الرقمية. على الرغم من أنه لا يخلو من قيود، إلا أن CESM يمثل إضافة قيمة إلى تسليح تصوير الثدي، لا سيما فى الأماكن التى يكون فيها التصوير بالرنين المغناطيسى غير متاح. تؤكد قدرته على تعزيز التدرج على staging T وتوجيه قرارات العلاج وتحسين نتائج المرضى فى إدارة سرطان الثدي. هناك ما يبرر إجراء المزيد من الدراسات واسعة النطاق للتحقق من صحة هذه النتائج وتحسين التطبيق السريرى لـ CESM.