

Original article

Paclitaxel and Carboplatin Concurrent with Three-Dimensional Conformal Radiotherapy (3D-CRT) for Treatment of Locally Advanced Squamous Cell Carcinoma of Head and Neck (LA-SCCHN)

S. Abdelwahab¹, R. Ghali¹, M. Elbassiouny¹, A. Elsayed¹, A. Mahmoud² and H. Aly³

¹Department of Clinical Oncology, Ain Shams University, ²Department of Radiodiagnosis, Ain Shams University and ³Department of Otolaryngology, Al-Azhar University, Cairo, Egypt

Purpose: This study was conducted to evaluate the efficacy outcomes and toxicity of paclitaxel and carboplatin when given concurrently with 3DCRT for patients with squamous cell carcinoma of the head and neck (SCCHN).

Patients and Methods: A phase II study included 46 patients with locally advanced SCCHN seen between February 2009 and April 2012. Paclitaxel 40 mg/m² combined with carboplatin AUC 1 was administered IV weekly during external beam radiotherapy using 3DCRT for 7 weeks, treatment to the gross disease was administered at 2 Gy/fraction to 70 Gy, once each day, five days a week, and 50 Gy to sites of potential spread, including the uninvolved neck. Any involved cervical lymphadenopathy had been supplemented with electron beams 9-12 MeV up to 70 Gy.

Results: Median age was 59 years (range 34-78 years). Men were 33 (72%) patients; ECOG performance status was 0 in 16(35%) patients, and 1 in 20 (43%) patients. Oropharynx was the most common primary tumor site in this study which occurred in 16 (35%) patients. Thirteen (28%) patients had stage III; while 33 (72%) patients had stage IV. Mucositis was the commonest side effect which occurred in 23 (50%) patients as grade III/IV, followed by grade III/IV dermatitis in 9 (20%) patients. Neutropenia as a grade III/IV had occurred in 9 (20%) patients followed by grade III/IV anemia in 7 (15%) patients. ORR was 87% (95% CI, 75%-98%); where 28 (61%) patients had a CR, 12 (26%) patients had PR. After a median follow-up time of 29 months for surviving patients (range: 5-37 months), the median PFS was 14.5 months (95% CI, 9.5-17 months); and the 2- year PFS was 36% (95% CI, 29 - 42%), while the 3- year PFS was 14% (95% CI, 10 - 17 %). The median OS was 24 months (95% CI, 18 -29 months); the 2- year OS was 42% (95% CI, 33 - 49%) and the 3- year OS was 31% (95% CI, 24 - 38%).

Conclusion: Weekly paclitaxel and carboplatin administered with concurrent 3DCRT is considered to be an effective and safe treatment in locally advanced squamous cell carcinoma of head and neck

Key words: 3D-CRT, carboplatin, head and neck cancers, paclitaxel.

Corresponding Author: S Abdelwahab

E-mail: sherifok69@hotmail.com

Original article

INTRODUCTION

Squamous cell carcinoma of the head and neck (SCCHN) is the most common type of malignancies of the upper aerodigestive tract¹. The majority of patients with SCCHN region present with locally advanced (American Joint Committee on Cancer [AJCC] stage III or IV) disease². The treatment of patients with unresectable locally advanced SCCHN remains a challenge. Radiotherapy (RT) alone yields poor rates of locoregional tumor control and overall survival³. Concurrent chemotherapy and radiotherapy improves survival and organ preservation for patients with locally advanced SCCHN⁴⁻⁵. The advanced radiotherapy techniques have developed rapidly; conformal radiotherapy (CRT), accelerated schedules⁶ and intensity modulated radiotherapy (IMRT)⁷ have been used to

improve the therapeutic ratio between tumor control and normal tissue toxicity. During the past 2 decades, systemic chemotherapy has been extensively tested in the management of this disease, and many chemotherapeutic agents were found to be active¹. Radiotherapy concurrent with cisplatin remains the best studied regimen; however, more novel agents including taxanes, carboplatin, and targeted therapies such as cetuximab are also being studied⁸. Carboplatin, a DNA-damaging platinum agent, is a potent radiosensitizer as has been shown in a number of randomized clinical trials in locally advanced SCCHN⁹. Agents such as paclitaxel have demonstrated antitumor activity in head and neck cancers¹⁰. Paclitaxel promotes microtubular assembly and prevents microtubular depolymerization leading to synchronizing

cells at G2/M phase of the cell cycle during which cells are most susceptible to radiation¹¹. Combinations of paclitaxel with cisplatin or carboplatin have been shown to be effective in head and neck cancers¹². A study conducted by Suntharalingam and colleagues who used weekly carboplatin and paclitaxel given concurrently with definitive once-daily external beam radiotherapy reported that this regimen is well tolerated with improved survival¹³. Based on the above mentioned data, our present study was conducted to test the response (primary end point) and the safety of paclitaxel combined with carboplatin when given concurrently with 3D-CRT (secondary end point) for treating patients with locally advanced SCCHN (LA-SCCHN).

PATIENTS AND METHODS

Eligibility criteria:

Patients enrolled in this prospective phase II study had to fulfill the following eligibility criteria: (i) provide informed oral and/or written consent, (ii) have histologically or cytologically documented SCCHN, (iii) locally advanced nonmetastatic stage III/IV SCCHN according to AJCC stage classification 2010 (7th edition.), (iv) measurable disease, (v) age >18 years and <75 years, (vi) no previous treatment (neither chemotherapy nor radiotherapy), (vii) Eastern Cooperative Oncology Group (ECOG) performance status of ≤ 2 , (viii) adequate organ function in the form of leucocytic count $\geq 4.000/\text{mm}^3$, (ix) platelet count $\geq 100.000/\text{mm}^3$, (x) hemoglobin $>9 \text{ g/dl}$, (xi) serum creatinine $<1.4 \text{ mg/dl}$, (xii) creatinine clearance $\geq 50 \text{ ml/min}$, (xiii) serum bilirubin $\leq 1.5 \text{ mg/dl}$, (xiv) serum transaminase $<2 \times$ upper limit of normal (ULN). Exclusion criteria included: (i) active severe infection, (ii) active concomitant malignancy, (iii) Pregnant and/or lactating women were also excluded, (iv) pre-existing motor or sensory neurotoxicity \geq WHO grade 2, significant hearing impairment unless due to nasopharyngeal carcinoma (NPC), (v) surgery other than biopsy or tracheostomy was allowed as a salvage treatment for progressive or recurrent disease. Percutaneous endoscopic gastrostomy tube (PEGs) was placed in case of compromised nutritional status (significant weight loss due to dysphagia at time of presentation).

Evaluation and follow-up

Pretreatment evaluation must included the following: full medical history and physical examination, assessment of performance status. All patients had dental evaluation at baseline, complete blood cell count (CBC) with differential, liver function tests, kidney function tests and 24-h urine creatinine clearance. Baseline tumor measurements were required within 4 weeks before start of treatment as measured by computed tomography (CT), and/or magnetic resonance imaging (MRI) and

direct endoscopy. During the treatment period, patients underwent weekly physical examination and toxicity assessment. CBC and serum creatinine was performed weekly, while 24-h urine creatinine clearance had to be performed every 3 weeks. Assessment of tumor response by clinical examination and head and neck MRI and/or CT were performed 6-8 weeks after the completion of treatment. Positron emission tomography (PET. CT) was done in some cases to differentiate fibrosis from active residual disease. Endoscopy was done at 8-12 weeks after the end of concurrent chemo-radiotherapy for pathological confirmation of response. Patients had to be followed up by clinical examination every 2 months during the first year, every 3 months for the subsequent 2 years and every 6 months thereafter. Imaging tools using (CT and/or MRI) were done every 6 months or for patients developing symptoms or signs suggestive of disease recurrence. Surgical, endoscopic or ultrasound guided biopsy were performed to document disease recurrence. Tumor response was assessed according to Response Evaluation Criteria in Solid Tumors (RECIST) criteria. Toxicity from treatment was graded according to WHO and Radiation Therapy Oncology Group (RTOG) criteria. Clinically significant toxicity was defined as any grade 3 or 4 toxicity probably or definitely attributable to therapy.

Radiotherapy:

A Linear Accelerator with a multileaf collimator with 6 MV photons was used for delivery of treatment with 3D-CRT for all patients. Treatment was done in supine position with head immobilization using a thermoplastic head and neck mask. Contrast-enhanced CT images for treatment planning were obtained at 2-5 mm intervals from the vertex to below the carina. The CT data was loaded into the treatment planning system. The clinical target volume (CTV) and organs at risk (OaRs) were outlined on the axial images. Delineation of target volume was aided with a radiologist in difficult cases. A 10 mm expansion margin was applied to the CTV to obtain the planning target volume (PTV). The CT images were then transferred to Treatment Planning System, which allowed obtaining digitally reconstructed radiographs (DRRs). Treatment to the gross disease was administered at 2 Gy/fraction to 70 Gy, once each day, five days a week, and 50 Gy to sites of potential spread, including the uninvolved neck. Any involved cervical lymphadenopathy had been supplemented with electron beams 9-12 MeV up to total dose 70 Gy. The beam arrangements were determined depending on the anatomical features of the tumor and its relationship with surrounding structures. The maximum dose allowed to the optic pathways was limited to 50 Gy, 54 Gy to brain stem and 45 Gy to the spinal cord. Dose-volume histograms (DVHs) were calculated for the PTV and OaRs. Treatment interruptions were allowed for severe normal tissue reactions, such as grade ≥ 3 mucositis.

Chemotherapy:

Concurrent chemotherapy was administered once weekly with radiotherapy, the first dose was given on the same day or the day after starting radiotherapy. Antihistamine together with potent antiemetic (3mg Granisetron or 16 mg Ondansetron), 8-20 mg dexamethasone and ranitidine intravenous (IV) were given to the patients as premedication then infusion of paclitaxel 40 mg/m² I.V followed by carboplatin AUC1 I.V for 7 weeks. Total infusion time was 3 hours. Total 7 cycles were planned to be given for all patients. Dose reduction or discontinuation of chemotherapy was performed if any hematological grade 4 toxicity occurred. Colony-stimulating factors (CSFs) were not used routinely.

Statistics:

Survival data were estimated according to the Kaplan–Meier method¹⁴. Overall survival (OS) was defined as the interval from day one of treatment to either time of death or last visit. Progression-free survival (PFS) was calculated from day one of treatment to either death or diagnosis of recurrence (local or distant metastases) or last visit. Objective response rate (ORR) could be defined as the proportion of patients whose best response was either partial or complete response (PR + CR). The statistical analysis was carried out using GraphPad Prism 5.

RESULTS**Patient and tumor characteristics:**

A total of 46 patients with locally advanced SCCHN were entered in this phase II study between February 2009 and April 2012 using 3D-CRT with weekly paclitaxel and carboplatin. Baseline characteristics are summarized in Table (1). Men were 33 (72%); median age was 59 years (range 34-78 years). ECOG performance status was 0 in 16 patients (35%), and 1 in 20 patients (43%). Oropharynx was the most common primary tumor site in this study which occurred in 16 patients (35%), followed by hypopharynx which occurred in 9 patients (20%). Thirteen patients (28%) had stage III; while 33 patients (72%) had stage IV as shown in Table (2).

Patients received a median of 6 doses of chemotherapy over a median of 40 days. The mean dose of paclitaxel was 74 mg (range, 64–88mg); and 102 mg/week for carboplatin (range, 85–127 mg). Nineteen patients (41%) received all 7 cycles of chemotherapy at full doses with no interruption or delay. The mean radiation dose delivered to the patient was 68.6 Gy ranging from 66 to 70 Gy. The mean time of treatment was 7.6 weeks ranging from 6.6-8.2 weeks.

Toxicity:

Acute treatment-related toxicities are summarized in Table (3). Mucositis was the most common recorded side

effect which occurred in 23 patients (50%) as grade III/IV, followed by grade III/IV xerostomia which occurred in 15 patients (33%), then dermatitis which occurred in 9 patients (20%). A percutaneous endoscopic gastrostomy tube (PEGs) was placed to ensure adequate nutrition in 10 patients (22%). Among the hematologic toxicities neutropenia was the most common side effect which occurred as a grade III/IV in 9 patients (20%) followed by grade III/IV anemia which occurred in 7 patients (15%).

Response:

For the intention-to-treat (ITT) analysis, 46 patients were evaluated for efficacy. ORR was 87% (95% CI, 75%-98%); where 28 patients (61%) had a CR, 12 patients (26%) had PR, 2 patients (4%) SD and 4 patients (9%) had PD during therapy as depicted in Table (4). Of the four patients who had PD, one patient progressed in the primary site, one developed bone metastases and two patients had progressed with lung metastases.

Progression free survival and Overall survival:

With a median follow-up time of 29 months for surviving patients (range: 5-37 months), the median PFS was 14.5 months (95% CI, 9.5-17 months); and the 2-year PFS was 36% (95% CI, 29 - 42%), while the 3- year PFS was 14% (95% CI, 10 - 17 %) as shown in Fig. 1. The median OS was 24 months (95% CI, 18 -29 months); the 2- year OS was 42% (95% CI, 33 - 49%) and the 3- year OS was 31% (95% CI, 24 - 38%) as shown in Fig. 2. Twenty three patients out of the forty patients who achieved objective responses had recurred or progressed at a median of 10.5 months (range: 5– 15 months), and 14 patients out of the 28 patients who achieved CR had recurred at a median of 14 months (range: 7–19 months). One of two patients with SD progressed at 10 months and he underwent salvage surgery and was still alive and disease free at last follow-up, while the other patient has not progressed at last follow-up.

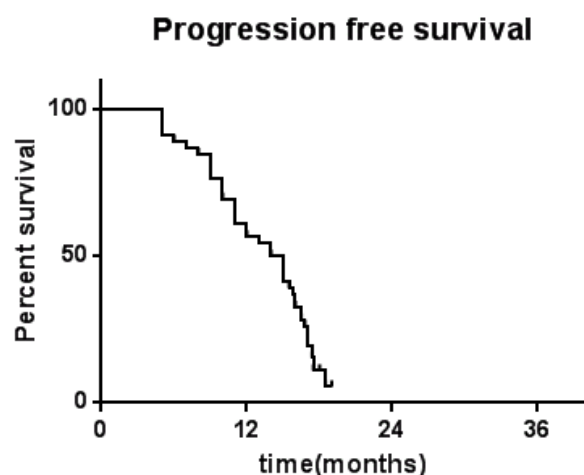


Fig. 1: Progression Free Survival

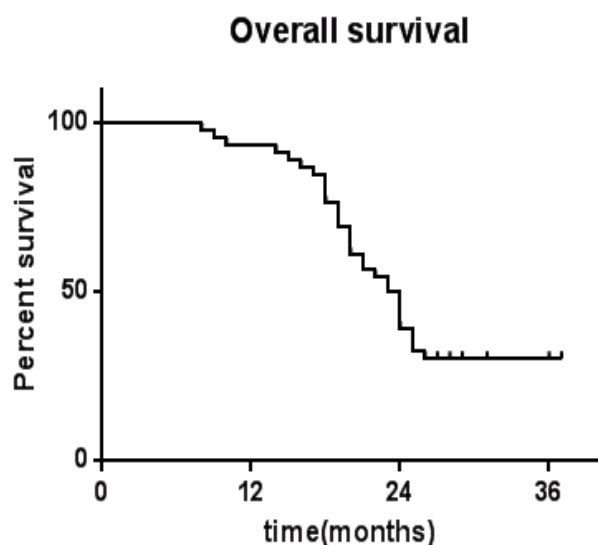


Fig. 2: Overall Survival.

Table 1: Patient and Tumor Characteristics (n=46)

Characteristic	n	%
Age, years (median, range)	59 (34-78)	
Sex		
Male	33	72
Female	13	28
ECOG PS		
0	16	35
1	20	43
2	10	22
Primary tumor site		
Oral cavity	7	15
Oropharynx	16	35
Hypopharynx	9	20
Nasopharynx	8	17
Larynx	6	13
AJCC Stage		
III	13	28
IV	33	72

Table 2: Primary tumor and nodal stages

	T1	T2	T3	T4	Total
N0	---	---	2 (4%)	9 (20%)	11 (24%)
N1	---	---	2 (4%)	5 (11%)	7 (15%)
N2	---	3 (7%)	2 (4%)	14 (30%)	19 (41%)
N3	---	3 (7%)	2 (4%)	4 (9%)	9 (20%)
Total	----	6(13%)	8 (17%)	32 (70%)	46 (100%)

Table 3: Acute treatment-related toxicity (n=46)

	Grade 0	Grade I	Grade II	Grade III	Grade IV
Hematologic					
Anemia	10 (22%)	22(48%)	7 (15%)	5 (11%)	2 (4%)
Neutropenia	12 (26%)	10 (22%)	12 (26%)	6 (13%)	6 (13%)
Thrombocytopenia	34 (74%)	3 (7%)	4 (9%)	4 (9%)	1 (2%)
Non-hematologic					
Mucositis	0	11 (24%)	12 (26%)	21 (46%)	2 (4%)
Dermatitis	0	24 (52%)	13 (28%)	8 (17%)	1 (2%)
Xerostomia	0	20 (43%)	11 (24%)	9 (20%)	6(13%)
Nausea/Vomiting	25 (54%)	13 (28%)	6 (13%)	1 (2%)	1(2%)
Neurologic	20 (43%)	21(46%)	4 (9%)	1 (2%)	0
Renal	43 (93%)	2 (4%)	1 (2%)	0	0
Alopecia	6 (13%)	19 (41%)	21 (46%)	0	0
Fatigue	8 (17%)	28 (61%)	4 (9%)	3 (7%)	3 (7%)
Weight loss	16 (35%)	20 (43%)	4 (9%)	6 (13%)	0

Table 4: Objective tumor response rates

Best Objective Response	No.	Percentage
Objective response rate	40	87
Complete response	28	61
Partial response	12	26
Stable disease	2	4
Progressive disease	4	9

DISCUSSION

Head and neck tumors and specifically SCCHNs are remarkably sensitive to many chemotherapeutic agents such as 5-fluorouracil, cisplatin, carboplatin, and taxanes. A meta-analysis by Pignon *et al.* (2000) suggested a small but significant absolute survival benefit with concurrent chemotherapy and radiation¹⁵. Randomized trials in locally advanced head and neck cancer have consistently shown a survival benefit beside better locoregional control with the use of concurrent radiotherapy and platinum-based chemotherapy¹⁶. More recently, paclitaxel and carboplatin have been demonstrated to have good radiosensitizing properties and have favorable activity in the treatment of locally advanced disease. Our study represents a phase II prospective study of treatment of locally advanced head and neck cancers using 3DCRT with concurrent weekly paclitaxel and carboplatin.

In the present study the median age at diagnosis was 59 years (range 34-78 years), compared to a study conducted by Semrau *et al.* (2011) which showed that median age was 55.6 years (range: 34–76 years)¹⁷. This was compared to a similar study included 30 patients with locally advanced nasopharyngeal cancer and median age was 54 years (range 29–69)¹⁸. We reported in the current study that oropharynx was the most common primary tumor site in 16 patients (35%), followed by hypopharynx which occurred in 9 patients (20%), compared to a study conducted by Agarwala and co-workers which included 55 patients with locally advanced head and neck cancers, where oropharynx was the second commonest site for primary tumor which occurred in 15 patients (27%) after base of tongue which occurred in 19 patients (34%)¹⁹. The present study showed that 13 patients (28%) had stage III and 33 patients (72%) had stage IV which is exactly similar to 12 patients (28%) with stage III and 31 patients (72 %) with stage IV in the study included 43 patients with locally advanced SCCHN done by Chougule and his colleagues²⁰.

The use of concurrent weekly paclitaxel and carboplatin with 3DCRT in the present study was well tolerated and associated with mucositis that had occurred in 23 patients (50%) as grade III/IV, followed by grade III/

IV xerostomia which occurred in 15 patients (33%), then followed by grade III/IV dermatitis which had occurred in 9 patients (20%); while Agarwala *et al.*¹⁹ in their study reported that grade III/IV mucositis had occurred in only 30% % and that grade III/IV dermatitis and xerostomia had occurred in 11% of their patients; while Chougule *et al.*²⁰ reported a significant higher toxicities in terms of grade III/IV mucositis which had occurred in 90% of the enrolled patients and grade III/IV dermatitis in 22% of the studied patients, but did not comment on xerostomia; these higher incidence of toxicities may be attributed to the use of 60mg/m² paclitaxel in addition to the use of 2D radiotherapy. Neutropenia was the commonest hematologic side effect which occurred as a grade III/IV in 26% of our enrolled patients followed by grade III/IV anemia which occurred in 7 patients (15%) while Chougule and colleagues²⁰ had reported that grade III/IV neutropenia had occurred in 12 % of the studied patients while Agarwala *et al.*¹⁹ reported that grade III/IV anemia had occurred in only 2% of patients and that grade III/IV anemia had occurred in 6% of the included patients.

Our present study showed that ORR was 87% (95% CI, 75%-98%); where 28 patients (61%) had a CR, 12 (26%) patients had PR, 2 patients (4%) had SD and 4 patients (9%) had PD, these findings are better than that reported by Agarwala *et al.*¹⁹ who reported that ORR was 80% (95% CI, 66 –90%), 26 out of the 50 (52%) patients enrolled in their study had attained CR, 14 (28%) patients had PR, 3(6%) patients had SD and 7 (14%) patients had PD. While Chougule and his co-workers²⁰ had reported a more encouraging results than our findings; where, they showed that ORR was 91%, 65% of the 43 patients had a CR, 26% patients had PR and 4% patients had PD. We completely agree with Chougule and his colleagues who stated that the weekly regimen of paclitaxel and carboplatin is one of the outpatient basis regimens, an extremely attractive schedule from the standpoint of ease of delivery, patient compliance, and cost-effectiveness. Together with the real findings of lower rates of major toxicities such as neuropathy, nephropathy, nausea/vomiting, and cytopenias than those associated with cisplatin-fluorouracil chemoradiotherapy.

After a median follow-up time of 29 months (range: 5-37 months), we reported that the median PFS was 14.5 months (95% CI, 9.5-17 months); and the 2- and the 3- year PFS was 36% and 14% respectively; while we reported that the median OS was 24 months (95% CI, 18 -29 months). The 2 - and 3 - year OS was 42% and 31% respectively, while Agarwala *et al.*¹⁹ reported that after a median follow time of 69 months, the median PFS was 16 months (95%CI 7- 24 months) and the 3- year PFS was 36% (95% CI, 23 - 49%); the median OS was 31 months (95% CI 15 - 44 months) and The 3- year OS was 45% (95% CI, 31%–57%). While Semrau *et al.* 17 reported

that the 2- year PFS 41% (95% CI: 35.3–46.7) and that the 2- year OS was 46.3% (95% CI: 40.5–52.1%).

Conclusion: We conclude that weekly paclitaxel and carboplatin administered with concurrent 3DCRT is tolerated and highly active in locally advanced squamous cell carcinoma of head and neck in terms of ORR, PFS and OS.

Conflict of interest statement: All authors disclose any financial and personal relationships with people or organizations that could influence their work.

REFERENCES

- Robert I, Haddad MD, and Dong M, Shin MD. Recent Advances in Head and Neck Cancer. *N.Engl.J.Med.* 2008;359:1143-54.
- U.S. Cancer Statistics Working Group. United States Cancer Statistics: 2002 Incidence and Mortality. 2002US Department of Health and Human Services, Centers for Disease Control and Prevention and National Cancer Institute, Atlanta.
- Forastiere A, Koch W, Trotti A, Sidransky D. Head and Neck Cancer. *N.Engl.J.Med.* 2001;345:1890-900.
- Forastiere AA, Goepfert H, Maor M, Pajak TF, Weber R, Morrison W, *et al.* Concurrent chemotherapy and radiotherapy for organ preservation in advanced laryngeal cancer. *N.Engl.J.Med.* 2003;349(22):2091-8.
- Jeremic B, Shibamoto Y, Milicic B, Nikolic N, Dagovic A, Aleksandrovic J, *et al.* Hyperfractionated radiation therapy with or without concurrent low-dose daily cisplatin in locally advanced squamous cell carcinoma of the head and neck: A prospective randomized trial. *J.Clin.Oncol.* 2000;18(7):1458-64.
- Bourhis J, Overgaard J, Audry H, Ang KK, Saunders M, Bernier J, *et al.* Hyperfractionated or accelerated radiotherapy in head and neck cancer: A meta-analysis. *Lancet* 2006;368(9538):843-54.
- Lee N, Puri DR, Blanco AI, Chao KS. Intensity-modulated radiation therapy in head and neck cancers: An update. *Head Neck* 2007;29(4):387-400.
- Saba NF, Edelman S, Tighiouart M, Gaultney J, Davis LW, Khuri FR, *et al.* Concurrent chemotherapy with intensity-modulated radiation therapy for locally advanced squamous cell carcinoma of the larynx and oropharynx: A retrospective single-institution analysis. *Head Neck* 2009;31(11):1447-55.
- Fountzilas G, Ciuleanu E, Dafni U, Plataniotis G, Kalogera-Fountzila A, Samantas E, *et al.* Concomitant radiochemotherapy vs radiotherapy alone in patients with head and neck cancer: A Hellenic Cooperative Oncology Group Phase III Study. *Med.Oncol.* 2004;21(2):95-107.
- Forastiere AA, Neuberger D, Taylor SG4, DeConti R, Adams G. Phase II evaluation of Taxol in advanced head and neck cancer: An Eastern Cooperative Oncology group trial. *J.Natl.Cancer Inst.Monogr.* 1993(15):181-4.
- Schiff PB, Fant J, Horwitz SB. Promotion of microtubule assembly in vitro by taxol. *Nature* 1979;277(5698):665-7.
- Hitt R, Paz-Ares L, Hidalgo M, Colomer R, Brandariz A, Peña M, *et al.* Phase I/II study of paclitaxel/cisplatin as first-line therapy for locally advanced head and neck cancer. *Semin.Oncol.* 1997;24(6 Suppl 19):S19-24.
- Suntharalingam M, Haas ML, Conley BA, Egorin MJ, Levy S, Sivasailam S, *et al.* The use of carboplatin and paclitaxel with daily radiotherapy in patients with locally advanced squamous cell carcinomas of the head and neck. *Int.J.Radiat.Oncol.Biol.Phys.* 2000;47(1):49-56.
- Kaplan EL, Meier P. Nonparametric estimation from incomplete observations. *J.Am.Stat.Assoc.* 1958;53(282):457-81.
- Pignon JP, Bourhis J, Domenge C, Designé L. Chemotherapy added to locoregional treatment for head and neck squamous-cell carcinoma: three meta-analyses of updated individual data. MACH-NC Collaborative Group. Meta-Analysis of Chemotherapy on Head and Neck Cancer. *Lancet* 2000;355(9208):949-55.
- Denis F, Garaud P, Bardet E, Alfonsi M, Sire C, Germain T, *et al.* Final results of the 94-01 French Head and Neck Oncology and Radiotherapy Group randomized trial comparing radiotherapy alone with concomitant radiochemotherapy in advanced-stage oropharynx carcinoma. *J.Clin.Oncol.* 2004;22(1):69-76.
- Semrau R, Temming S, Preuss SF, Klubmann JP, Guntinas-Lichius O, Müller RP. Definitive radiochemotherapy of advanced head and neck cancer with carboplatin and paclitaxel: A phase II study. *Strahlenther.Onkol.* 2011;187(10):645-50.
- Airoldi M, Gabriele P, Gabriele AM, Garzaro M, Raimondo L, Pedani F, *et al.* Induction chemotherapy with carboplatin and taxol followed by radiotherapy and concurrent weekly carboplatin + taxol in locally advanced nasopharyngeal carcinoma. *Cancer Chemother.Pharmacol.* 2011;67(5):1027-34.
- Agarwala SS, Cano E, Heron DE, Johnson J, Myers E, Sandulache V, *et al.* Long-term outcomes with concurrent carboplatin, paclitaxel and radiation therapy for locally advanced, inoperable head and neck cancer. *Ann.Oncol.* 2007;18(7):1224-9.
- Chougule PB, Akhtar MS, Rathore R, Koness J, McRae R, Nigri P, *et al.* Concurrent chemoradiotherapy with weekly paclitaxel and carboplatin for locally advanced head and neck cancer: Long-term follow-up of a Brown University Oncology Group Phase II Study (HN-53). *Head Neck* 2008;30(3):289-96.