
AN UNUSUAL CAUSE OF DYSPHAGIA: A CASE REPORT

Aba Ankomaba Folson¹, Francis Essilfie², Dennis Brempong², Ernest Sowada²

¹Department of Medicine and Therapeutics, School of Medicine, University of Health and Allied Sciences, PMB 31, Ho, Volta Region

²Ho Teaching Hospital PMB 31, Ho, Volta Region

Corresponding author: Dr Aba Folson.

Email: afolson@uhas.edu.gh.

Tel: 0262360360

Doi: [10.21608/ajgh.2025.391272.1083](https://doi.org/10.21608/ajgh.2025.391272.1083).

Submit Date: 08-06-2025.

Revision date: 17-09-2025.

Accept Date: 04-10-2025.

ABSTRACT

Aims: To report an unusual case of dysphagia in an elderly patient caused by an anterior cervical osteophyte, and to highlight the importance of including plain cervical radiography in the diagnostic work-up of dysphagia, particularly in low-resource settings where advanced imaging may not always be available.

Patient and Methods: We reviewed the clinical presentation, investigations, management, and outcome of a 63-year-old male who presented with a two-year history of progressive dysphagia, hoarseness of voice, significant weight loss, and recent-onset jaundice. A detailed history, physical examination, laboratory investigations, imaging studies (including plain radiographs, ultrasound, and CT scans), and response to conservative management were documented.

Results: Initial endoscopy and laryngoscopy were unremarkable. The patient's condition worsened, progressing to dysphagia for liquids and saliva retention. Laboratory results revealed severe anemia and deranged liver function tests. Abdominal ultrasound suggested hepatomegaly. A lateral neck radiograph and CT scan showed a prominent anterior cervical osteophyte at the C5 vertebra, confirming the structural cause of dysphagia. He was managed conservatively with fluids, antibiotics for concurrent pneumonia, blood transfusion, and supportive care, leading to clinical improvement. His liver function tests improved after he discontinued the herbal medications. The patient was subsequently referred for neurosurgical evaluation for definitive management of the osteophyte.

Conclusion: Cervical osteophytes, although common in older people, rarely present with dysphagia. This case emphasizes the need to consider cervical osteophyte as a differential diagnosis of dysphagia in elderly patients. Plain cervical radiographs should be incorporated early in the diagnostic algorithm in resource-limited settings to facilitate timely detection and appropriate management.

Keywords: Dysphagia, cervical osteophyte, anterior cervical spine, progressive dysphagia, laryngeal examination, structural obstruction, endoscopy, degenerative spine disease, C5 vertebra, anterior cervical spine

INTRODUCTION

Dysphagia is defined as the subjective sensation of difficulty or abnormality of swallowing. It may be due to a structural or functional abnormality that interferes with the passage of solids or liquids from the oral cavity to the stomach. Dysphagia is common among older people. Prevalence of 15% and 22% reported in community-based studies (1; 2). Dysphagia is classified as oropharyngeal dysphagia and esophageal dysphagia. In adults, esophageal dysphagia due to structural obstruction is commonly caused by esophageal stricture, head and neck cancers, esophageal webs, and esophageal carcinoma (3).

In this case report, we describe a case of dysphagia in a 63-year-old man caused by an osteophyte from the C5 cervical vertebrae, and emphasize the role of plain X-ray images in the investigation of dysphagia in older people, especially in resource-constrained settings.

CASE SUMMARY

A 63-year-old male not known to have any chronic illness presented to the Ho Teaching Hospital with a 2-year history of progressive dysphagia and jaundice of four days duration. The patient had been seen in the facility two years prior when he presented with a five-day history of dysphagia to solids. Initial investigations, including upper GI endoscopy and indirect laryngoscopy, showed no abnormalities such as tumors, Barrett's esophagus, or esophageal web. He defaulted on review when requested to do a barium swallow. The dysphagia had progressively worsened to involve liquids, and he could not swallow his saliva. (he carried a container for his saliva.) He had lost significant weight, had hoarseness of voice, but had no odynophagia, no halitosis, no chest pain, no hematemesis, no melena. He was symptomatic of anemia. Four days before presentation, the patient noticed yellowing of his eyes with right hypochondriac pain and cola-like urine, but no pruritus or pale stools. He admitted to taking unknown oral herbal medications for about a month before presentation. He also had a cough productive of yellowish sputum, accompanied by fever and malaise. He had no notable cardiovascular or neurological symptoms. The past medical history was not significant, with no history of gastroesophageal reflux disease, no stroke, no previous intake of corrosive substances, or family history of esophageal cancer. He had no history of smoking or alcohol intake.

Physical Examination

Patient was chronically ill, looking cachectic, severely jaundiced, moderately pale, and severely dehydrated. Breath sound intensity was reduced bilaterally at the lung bases, with coarse crepitations in the left lower lung zone suggestive of a possible aspiration pneumonitis. There was right hypochondrial tenderness, but no rebound tenderness; the liver was palpable, with a span of 15.1 cm along the mid-clavicular line, and had a sharp edge and smooth surface.

Vitals on presentation: SpO₂ was 98% on room air, with a respiratory rate of 20 cycles per minute, blood pressure of 93/55 mmHg, a heart rate of 82 beats per minute, a temperature of 36.6 °C, and a random blood sugar of 8.8 mmol/L. Cardiovascular and neurological examinations were unremarkable.

Investigations

Table 1. *Investigations of the patient*

Full blood count	Liver function tests	Liver function tests (Before discharge)	Renal function tests
Wbc: 21.87×10^3 /uL (2.5 - 8.5)	Albumin - 32.94 g/L (35.00 - 52.00)	Albumin - 27.27g/L (35.00 - 52.00)	Creatinine - 106.42 umol/L (53.00 - 115.00)
Neutrophil count: 18.74 10^3 /uL 2.00 - 7.50	ALP - 1324.8 (42 - 207)	ALP - 620.6 U/I (42 - 207)	Urea - 10.11 (2.10 - 7.10)
Hb: 7.2 g/dL (13.0 - 18.0)	GGT - 487.4 U/I 9.0 - 36.0	GGT - 385.9U/I (9.0 - 36.0)	Sodium - 134 mmol/L (135-145)
Mean Corpuscular Vol (MCV) - 85.9 FL	ALT - 78.1 U/I (10 - 50)	ALT - 57.2 U/I (10 - 50)	Potassium - 5.3 mmol/L (3.5 - 5.0)
Mean Corpuscular Hb. (MCH) - 29.0 pg.	AST - 173.7 U/L (5 - 34)	AST - 85.2 U/L (5 - 34)	Chloride - 95 mmol/L (97-107)
Platelet - 421.0×10^3 /uL (150.0 - 450.0)	Total bilirubin - 222.5 umol/L (3.4 - 21.0)	Total bilirubin - 95.2 umol/L (3.4 - 21.0)	EGFR: 67.7 ml/min/1.73m ²
	Direct bilirubin - 131.96 umol/L (0.00 - 10.00)		
	Indirect bilirubin - 90.1 umol/L		
	Total Protein - 85.1 (62.00 - 85.00)		

Hepatitis C screening and HBsAg were both negative.

Urinalysis revealed severe urobilinogen and bilirubinuria, which persisted in subsequent urine assessments. Both urine and blood culture and sensitivity tests showed no organism growth, but suggested possible hemolysis due to the use of herbal medication.

An abdominopelvic ultrasound scan showed an enlarged echogenic liver. No focal mass or diffuse disease was observed. The spleen and kidneys appeared normal sonographically and were of normal size. MRCP and IHBRD were considered for further evaluation of jaundice, but were not done due to unavailability.

An indirect laryngoscopy was unremarkable. Due to the elevated white blood cell count with a differential neutrophilia, a CT scan of the chest was considered to rule out pneumonia; however,

due to a lack of funds, it was not done. Barium swallow was unsuccessful; thus, a lateral neck x-ray was done, and this showed a prominent anterior cervical osteophyte on the C5 vertebra.

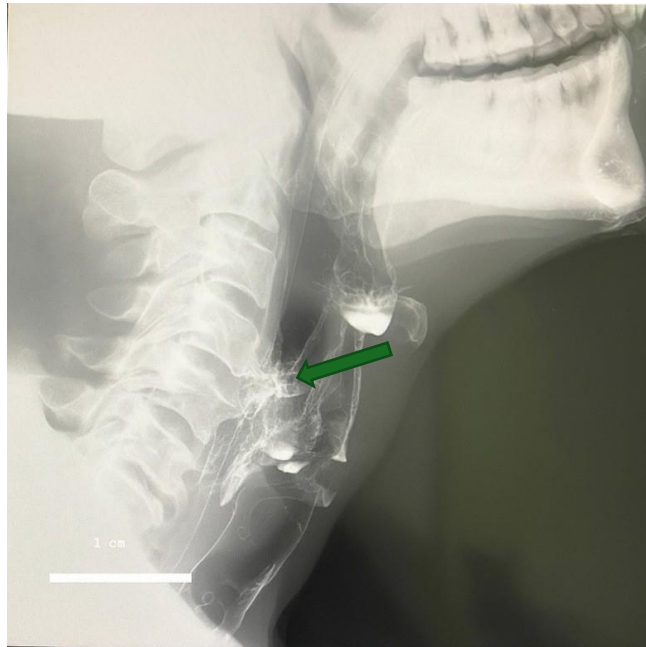


Fig 1. A lateral neck x-ray showed a prominent anterior cervical osteophyte on the C5 vertebra

MANAGEMENT

A clinical diagnosis of dysphagia secondary to cervical osteophyte (C5), complicated by severe normocytic normochromic anemia and aspiration pneumonia, as well as a drug-induced liver injury (herbal medication use), was made.

The patient was managed with IV crystalloids, including dextrose saline and normal saline, and fed via nasogastric tube. The sepsis was managed with IV ceftriaxone. He was transfused with two units of packed red cells.

After 7 days of management, the pneumonia resolved, the jaundice improved, and the repeat liver function test showed marked improvement. Subsequent liver function tests showed improved levels of GGT, ALT, AST, and total bilirubin.

He was referred for neurosurgical management at another teaching facility; however, the patient refused to have surgery for unspecified personal reasons.

DISCUSSION

Anterior cervical osteophyte is a common degenerative disease of the cervical vertebrae. It is common among older people. It is reported to affect 20% to 30% of the population over 60 years. (4). They are usually asymptomatic and are detected incidentally, but occasionally progress to cause dysphagia and upper airway obstruction. Dysphagia, on the other hand, is also common among older people. The incidence is estimated to be 15 to 20% (1; 2). It is commonly caused by stroke, esophageal stricture, head and neck cancers, esophageal webs, and esophageal carcinoma (3).

The occurrence of dysphagia due to cervical osteophyte is uncommon. The incidence of dysphagia due to cervical osteophyte is unknown. However, it is reported to occur in 17% to 28% of patients with osteophytes and is most commonly seen in men aged 60 and older (5). The workup for dysphagia is primarily tailored to the type and the suspected cause. For dysphagia of a structural cause, routine investigations include esophagoscopy and barium swallow. In this case, the barium swallow was not successful because the patient was unable to swallow the barium contrast material. An osteophyte can be seen as an indentation on the wall of the esophagus during endoscopy, but it can easily be missed. In the early stages, endoscopy will usually be routine, as in our case. On barium swallow, osteophytes cause smooth extrinsic indentation in the esophagus at the level of the osteophyte formation. Subsequently, plain lateral radiographs and CT scans are needed to demonstrate the formation, degree of compression, and extent of the osteophytes. In older people, a plain cervical radiograph as part of the initial investigation, especially in low-resource settings, may help detect an osteophyte that causes dysphagia. Diagnosis can be further confirmed with a CT scan, which provides a clear definition of the bony anatomy. Magnetic resonance imaging (MRI) is also considered in patients with associated dyspnea and dysphonia. This helps identify soft tissue damage, perforations, or superinfection.

Aspiration is a common complication of dysphagia and a significant cause of morbidity and mortality. Osteophytes at the C3-C4 and C4-C5 levels are commonly associated with aspiration during swallowing, resulting from the restriction of epiglottic closure. This is reportedly more common in patients with an anterior cervical osteophyte at higher cervical spine levels.(2). Osteophytes can also cause dysphonia by impinging upon the vocal cords and associated nerves

involved in voice production, thus leading to hoarseness in voice as occurred in this patient.(4). Jaundice is not a documented presentation of dysphagia. Its occurrence is usually due to the underlying cause or a concurrent pathology.(5) . In this patient, the jaundice was due to the drug-induced liver injury caused by the herbal medication and improved with supportive management.

Management of anterior cervical osteophytes can be conservative or surgical, with surgery required for severe cases of dysphagia (6) . Consideration to include a cervical x-ray in the initial workup for dysphagia in older people may lead to early detection of severe cervical osteophytosis and contribute to earlier detection of this unusual cause of dysphagia.

CONCLUSION

Cervical osteophytes should be considered among the possible causes of dysphagia among older people. An initial plain cervical radiograph in a low-resource setting can rule in the diagnosis, leading to early diagnosis and better management outcomes.

Footnotes.

Sara Salem (lecturer of internal medicine, gastroenterology, and hepatology unit), Ahmed al agrodey (Professor of internal medicine, gastroenterology, and hepatology unit.) were peer reviewers.

E- Editor: Salem Youssef Mohamed, Osama Ahmed Khalil, Amany Mohammed.

Copyright ©. This open-access article is distributed under the Creative Commons Attribution License (CC BY). It may be used, distributed, or reproduced in other forums, provided the original author(s) and the copyright owner(s) are credited. The original publication in this journal must be cited according to accepted academic practice.

Disclaimer: The authors' claims in this article are solely their own and do not necessarily represent their affiliated organizations or those of the publisher, the editors, or the reviewers. Any product evaluated in this article or its manufacturer's claim is not guaranteed or endorsed by the publisher.

Ethics approval

The patient was informed of the intention to publish this case, and consent was obtained.

Data and materials availability: The datasets used and/or analyzed during the current study are available from the corresponding author on reasonable request.

Competing interests: The authors declare that they have no competing interests.

Funding: This study had no funding from any source.

This work was conducted in accordance with the CARE guidelines.

Authors' contributions:

Francis Essilfie: Supervision of patient management, literature search, drafting of manuscript

Dennis Brempong: Literature search, review of manuscript

Ernest Sowada: Patient care and management, which included carrying out requested investigations and carrying out treatment plans

Aba Ankomaba Folson: Overall supervision of patient management, conceptualization of the idea, and review of the manuscript

All authors approved the final version of the manuscript.

Acknowledgments: Not applicable.

References

1. *Janzon L, Lindgren S, Robbins J. Prevalence of swallowing complaints and clinical findings among 50–79-year-old men and women in an urban population. Dysphagia. 1991;6:187–192. <https://doi.org/10.1007/BF02493524>.*
2. *Madhavan A, Lagorio LA, Crary MA, et al. Prevalence of and risk factors for dysphagia in the community-dwelling elderly: A systematic review. J Nutr Health Aging. 2016;20(8):806–815. <https://doi.org/10.1007/s12603-016-0712-3>.*
3. *Dylan F, Altman KW. Causes of dysphagia among different age groups. Otolaryngol Clin North Am. 2013;46:956–987.*

-
4. **Ney DM, Weiss JM, Kind AJ, et al. Senescent swallowing: impact, strategies, and interventions. *Nutr Clin Pract.* 2009.**
 5. **Emuynck K, Van Calenbergh F, Goffin J. Upper airway obstruction caused by a cervical osteophyte. *Chest.* 1995;108:283–284.**
 6. **Faruqi S, Thirumaran M, Blaxill P. An osseous cause of dysphagia. *Med J Aust.* 2008;188:671. doi:10.5694/j.1326-5377.2008.tb01829.x.**