

## OZONE ADMINISTRATION AMELIORATES DIFFERENT CHEMICALLY INDUCED HEPATO-RENAL CHRONIC TOXICITY IN RATS : A HISTOPATHOLOGICAL STUDY

BY

Samia A. Hassan; Ibrahim M. El-Shawaf\*;  
Azza El-Ghazaly and Somaia M. El-Azab

Departments of Forensic Medicine and Clinical Toxicology and \*Pathology,  
Faculty of Medicine, Mansoura University, Egypt

### ABSTRACT

The present work was an *in vivo* experimental study to investigate the toxic effects of different poisons on the histopathological picture of both the liver and kidney. Also the influence of repeated administration of ozone in atoxic doses on the progress of such toxicity was evaluated. The investigation was carried on 190 male albino rats (BW: 250-300 g). They were subdivided into four groups as follow: Group (A) composed of 65 animals. They received by oral intake of 1/20 LD50 of cadmium chloride (17.6 mg/kg BW). Group B comprised 65 animals which received 80 mg/kg BW. daily by oral administration of an organophosphorous (diazinon) (1/20LD50). Group C comprised 45 animals which received intraperitoneal injection of phenobarbitone (100 mg/kg) daily. One third of animals in groups 1, 2 and 4 received the respective chemical only for 60 days. The second third received the same chemical for 60 days but during the last 10 days of the experiment, oxygen-ozone mixture as an adjuvant measure was taken while the remaining third received the toxic chemical for 60 days with addition of nitrogen intake in the last 10 days of the experiment. Group E (which acted as a normal control group) comprised 15 albino-rats which received the placebo substance (inert nitrogen) for two months. Marked histopathological changes in the liver and kidney of the experimental animals were noted due to cadmium chloride administration. Treatment of the cadmium intoxicated rats with oxygen-ozone mixture by daily intraperitoneal injection of 40 ul ozone in 1 ml oxygen during the last 10 days, showed marked improvement of the histopathological alterations in both liver and kidney. Moreover, marked histopathological alterations of liver and kidney of the motivated animals were noted after diazinon administration. Treatment of the animals with oxygen-ozone mixture by intraperitoneal injection during the last 10 days showed favorable quantitative and qualitative reduction of the pathological changes in both liver and kidney. In the 3rd group of the study, histopathological changes affecting both liver and kidney of the experimental animals were found after phenobarbitone administration. Treatment of rats exposed to overdose of phenobarbitone with oxygen-ozone mixture by intraperitoneal injection during the last 10 days resulted in moderate improvement of the histopathological alterations affecting liver and kidney. The 3 poisons used (cadmi-

um chloride, diazinon and phenobarbitone) have a pronounced experimental toxic effects, sometimes producing necrotic injury of the rats' liver and kidneys. These changes may be due to oxidative stress. Ozone administration ameliorated the toxicity in these animals by any of the nominated chemicals. Precautionary measures must be followed to protect the exposed workers as well as the general population from environmental contamination by any of these chemicals. Moreover, periodical screening and proper management are advised if any toxic manifestation appeared.

*Key words* : Intraperitoneal, Cadmium chloride.

## INTRODUCTION

Organic and inorganic chemicals can be found in drinking water and ingested food as thousands of pesticides in the soil and of toxins in the atmosphere are detected. Moreover, population may be capable of the metabolism and elimination of many medical drugs (Hayes, 1993).

Ozone, an allotropic form of oxygen, is a molecule containing a large excess of energy which makes it a useful or an adjunct measure in certain conditions. The ability of ozone to destroy toxic industrial chemical impurities and to inactivate bacterial contaminants has made it an attractive protective and even therapeutic regimen (Barceloux et al., 2001).

Repeated administration of cadmium chloride produced histopathological malchanges in both the liver (Milnerowicz and Madej, 1999; Habeebu et al., 2000) and kidney (Hughes et al., 2000). Such changes were significantly decreased after oxygen-ozone mixture administration (Kuryszko

et al., 1995; Milnerowicz and Madej, 1999). On the contrary, Laszezyca et al., (1996) did not agree with gaining such beneficial effects by ozone.

Many authors (Hebert et al., 2000; Handy et al., 2002) reported that chronic diazinon (an organophosphorous compound) exposure caused many organ pathologies while ozone administration in atoxic doses was able to reduce the deleterious effects of diazinon (Bachowski et al., 1998).

Sarraf et al. (1997) found that barbiturates induced centrilobular hepatic necrosis in experimental animals. Ozone can attenuate barbiturate toxicity through an anti oxidative stress action (Al-Dalain et al., 2001; Kinoshita et al., 2002).

Subsequently, ozone has been used as a therapeutical agent for treatment of different, apparently non related diseases and beneficial effects have been observed in some cerebrovascular or cardiac ischaemia, chronic ulcers, arteriosclerosis oblite-

rans, retinitis pigmentosa, humoral immunity deficiency or hepatic steatosis cases (Leon et al., 1998). So, it appears correct to use ozone therapy when orthodox medicals failed to be effective. However, the prejudicial view that this alternative therapy cures every thing must be dispelled (Bocci, 1999). In turn, the effect of ozone on chronic toxicity with CdCl<sub>2</sub>, organophosphorous, and barbiturate compounds is still in need of comprehensive study. Ozone administration in such disastrous affections is a new line of therapy, the value of which is not yet well estimated.

#### **Aim of the research:**

The purpose of the present study was to evaluate the role and effectiveness of ozone in protecting rats intoxicated with different chemical poisons such as: nephrotoxic poison (CdCl<sub>2</sub>), neurotoxic poison (diazinon) and CNS toxic drug (phenobarbitone).

### **MATERIAL AND METHODS**

#### **1. Toxic agents :**

- i. Cadmium chloride (CdCl<sub>2</sub>) pure crystalline form which contains 61.32% cadmium and 38.68% chloride (Perroux SA Macon).
- ii. Organophosphorous insecticide, (diazinon), used as 90% conc. (CIBA-GEIGY-AG, Egypt).

- iii. Phenobarbitone (sominaletta ampoules 1 ml), each contains 40 mg phenobarbital sodium (Alexandria Co. pharmaceutical and chemical ind.).

#### **2. Apparatus :**

- i. Ozone generator (HUMAZON-PM unit) from which an oxygen-ozone mixture was obtained which contained 40 ul of ozone per milliliter oxygen (HUMARES GmbH D76356 Weingarten-Karlsruhe).
- ii. Nitrogen cylinder (MESSER GASES DEKHEILA, ALEX.) from which inert nitrogen gas was obtained through a vacuum syringe to be used as placebo (Miller et al., 2000).

#### **3. Animals**

One hundred and ninety male albino rats weighing 250-300 g were included in this study. They were fed on the ordinary food and housed under ordinary room temperature (28-35°C).

#### **Experimental study:**

Group A composed of 65 rats. Of them, two subgroups were used to determine the suitable dose of cadmium chloride for experimental use. Each animal of the first subgroup (10 animals) was given cadmium chloride orally through a gavage needle in a dose of 1/10 LD<sub>50</sub> every day (oral LD<sub>50</sub> for CdCl<sub>2</sub> in rats is 88 mg/kg body

weight) (Christensen et al., 1970). These animals died within 17 days (3 animals died in the 14th day, 2 in the 16th and the remaining five rats died in the 17th day). In the 2nd subgroup of rats (10 animals), each animal was given by the same route 1/20 LD50 dose of CdCl<sub>2</sub>. They presented only body weight reduction and maintained life well over the period of the experiment (two months). Consequently, this latter dose was considered as suitable dose for chronic cadmium toxicity.

The remaining 45 rats were divided into 3 subgroups, each comprised 15 animals. They received CdCl<sub>2</sub> orally in the 1/20 LD50 dose for sixty days. The first subgroup received this chemical only throughout the course. The second subgroup received the chemical for 60 days but during the last 10 days of the experiment, they received beside CdCl<sub>2</sub>, oxygen-ozone mixture as intraperitoneal injection, at a daily dose of 1 ml which contained 40 ul of ozone per millilitre oxygen (Kuryszko et al., 1995). While during the CdCl<sub>2</sub> course, the 3rd subgroup received in the last 10 days the placebo in the form of intraperitoneal injection of inert nitrogen gas (1.0 ml I.P). At the end of the experiment, rats in each subgroup were sacrificed and their livers and kidneys were histopathologically examined (H & E and fatty stains).

Group B consisted of 65 animals. Of them, 10 rats were isolated to estimate the

suitable dose of diazinon (organophosphorous insecticide). The animals were given diazinon orally through a gavage needle in a dose of (1/10 LD50) every day (the LD50 of diazinon in rats is 400 mg/kg body weight) (Worthing and Hence, 1991). These animals died after 9-12 days (3 rats died on the 9th day, 2 rats on the 10th day and the remaining 5 rats died on the 12th day). Another 10 animals were given 1/20 LD50 dose for 60 days. They suffered only weakness and loss of body weight.

The 1/20 LD50 dose of diazinon was given to the remaining 45 rats every day for 2 months. These latter animals were subdivided into 3 equal subgroups. The 1st subgroup continued the diazinon all through the course only. The 2nd subgroup was treated with oxygen-ozone mixture as intraperitoneal injection during the last 10 days of the experiment, at a daily dose of 1 ml which contained 40 ul of ozone per millilitre oxygen (Kuryszko et al., 1995). The 3rd subgroup received I.P 1.0 ml placebo as inert nitrogen for 10 days. At the end of the experiment, rats in each subgroup were sacrificed and their livers and kidneys were histopathologically examined (H&E and fatty stains).

Group C comprised 45 animals that were divided into 3 subgroups. All these animals were given phenobarbitone by daily intraperitoneal injection of 100 mg/kg for 2 months (Dingemanse et al., 1990).

Of the whole series, 15 rats were given the drug only, the second subgroup. were treated with oxygen-ozone mixture as intraperitoneal injection during the last 10 days of the experiment, at a daily dose of 1 ml which contained 40 ul of ozone per millilitre (Kuryszko et al., 1995), while the 3rd subgroup received placebo in the form of inert nitrogen by intraperitoneal injection of 1.0 ml during the last 10 days of the experiment. At the end of the experiment, the rats were sacrificed and their livers and kidneys were histopathologically examined (H&E and fatty stains).

Group D this group was composed of 15 rats. They served as a healthy reference (control) group. All of them received the inert nitrogen only in the same dose and route used in other groups.

## RESULTS

### Cadmium Intoxication :

Histopathological findings of the liver of rats received cadmium chloride (CdCl<sub>2</sub>) and placebo (inert nitrogen) (Fig. 1):

- (1) Lymphocytic infiltration of the portal tracts occurred 83%, whereas, thickening of blood vessels with hyperplastic lining occurred in 75%.
- (2) Hepatocyte degenerative cloudy swelling appeared in 100%, hepatocyte/hyperplasia occurred in 72%, whereas focal necrosis appeared in 90% and apoptosis in 25%.

- (3) Kupffer cell hyperplasia occurred in 85%.

Histopathological findings of the liver of rats received cadmium chloride (CdCl<sub>2</sub>) and oxygen-ozone mixture (Fig. 2):

- (1) Mild lymphocytic infiltration in the portal system occurred only in 46%.
- (2) Mild degenerative cloudy swelling of hepatocytes appeared in only 70%, mild hepatocyte hyperplasia in 32%, whereas focal necrosis and apoptosis did not appear in any of the rats.
- (3) Kupffer cell hyperplasia occurred in only 45% of rats with mild severity.

Histopathological findings of the kidney of rats received cadmium chloride (CdCl<sub>2</sub>) and placebo (inert nitrogen) (Fig. 3):

- (1) Proximal convoluted tubules showed degenerative cloudy swelling in 82%.
- (2) Interstitial lymphocytic infiltration appeared in 40%.
- (3) Casts inside the tubules occurred in 30%.

Histopathological findings of the kidney of rats received cadmium chloride (CdCl<sub>2</sub>) and oxygen-ozone mixture (Fig. 4):

- (1) Mild degenerative cloudy swelling appeared in only 50%.

- (2) No lymphocytic infiltration or casts was detected inside the tubules.

#### **Diazinon Intoxication :**

Histopathological findings of the liver of rats received diazinon and placebo (inert nitrogen):

- (1) The portal tract showed lymphocytic infiltration occurred in 40%. Degeneration occurred in 100% in the form of macro vesicular steatosis and micro vesicular steatosis.
- (2) Necrotic hepatocytes in the form of small multiple random foci (focal necrosis) appeared in 72%.
- (3) Hepatocyte hyperplasia was noticed in 60%.

Histopathological finding of liver of rats received diazinon and oxygen-ozone mixture (Fig. 6):

- (1) Mild lymphocytic infiltration in the portal tracts occurred in 25%.
- (2) Mild micro and macro vesicular steatosis were observed in 76%.
- (3) Necrosis and hepatocyte hyperplasia did not appear in any of the rats.

Histopathological findings of the kidney of rats received diazinon and placebo (inert nitrogen):

- (1) The collecting tubules showed thickening of its lining occurred in 30% of rats.
- (2) The proximal tubules, degenerative changes in the form of cloudy swelling

ing appeared in 84%.

- (3) Casts inside the tubules occurred in 32%.

Histopathological findings of the kidney of rats received diazinon and treated with oxygen-ozone mixture (Fig. 6):

- (1) The collecting tubules appeared normal.
- (2) The proximal tubules showed moderate degenerative cloudy swelling in 58% of rats with absence of casts.

#### **Phenobarbitone Intoxication**

Histopathological findings of the liver of rats received phenobarbitone and placebo (inert nitrogen):

- (1) In the hepatocyte degeneration changes in the form of cloudy swelling and vascular degeneration appeared in 100%.
- (2) Micro vesicular steatosis occurred in 78%.
- (3) Focal necrosis of hepatocytes appeared in 81%.
- (4) Hepatocyte hyperplasia occurred in 70%.

Histopathological findings of the liver of rats received phenobarbitone and oxygen-ozone mixture:

- (1) Moderate degenerative cloudy swelling was noticed in 60%.
- (2) Moderate necrosis appeared in 3.5%.
- (3) Hepatocyte swelling did not appear in any of the rats.

Histopathological findings of the kidney of rats received phenobarbiton and placebo (Fig. 7):

- (1) The proximal tubules showed degenerative cloudy swelling in 75%.
- (2) Casts inside the tubules appeared in 25%.

Histopathological findings of the kidney of rats received phenobarbitone and oxygen-ozone mixture (Fig. 8):

- (1) Moderate degenerative cloudy swelling of the proximal tubules occurred in 55%.
- (2) Casts inside the tubules observed in 15%.

#### DISCUSSION

Cadmium is a nonessential trace metal. It is toxic in low dosage, has long biological half life (10-30 years) and low rate of excretion, being stored predominantly in soft tissues. It is capable of producing acute and chronic poisoning in humans and animals. It may exert deleterious effects on liver, kidney, lung, ovaries and testis (Jones and Cherian, 1990) and induces oxidative stress (Bagchi et al., 1997).

El-Maraghy et al., (2001) observed in experimental animals that liver function was affected by cadmium at all dose regimens, whereas, kidney function was affected after administration of the very high dose of cadmium.

In the present study, the histopathological findings of the liver and kidney after cadmium intoxication, showed marked changes compared to normal control.

In the hepatic portal tract, there is lymphocytic infiltration affecting 83% of rats, thickening of blood vessels with hyperplastic lining in 75% of rats. At the same time, hepatocytes showed a degenerative cloudy swelling in 100% focal necrosis in 90%, apoptosis in 25% and Kupffer cell hyperplasia in 8% of rats.

In the kidney, the proximal convoluted tubules showed degenerative cloudy swelling in 82%, interstitial lymphocytic infiltration in 40%, and casts inside the tubules in 30% of rats.

The results of the present study are in agreement with results obtained by Habeebu et al., (2000) who stated that repeated administration of CdCl<sub>2</sub> produced liver injury in the form of chronic inflammation in the parenchyme, portal tracts and around central veins. Higher doses produced granulomatous proliferating nodules in liver parenchyme. Apoptosis and mitosis occurred concomitantly in liver following Cd exposure.

Also, histopathological changes of the kidney was investigated by Bompert et al., (1999) who found that cadmium nephrotoxicity characterised by tubular proximal

damage and a wide spread vesiculation of tubular cells. Moreover, Hughes et al., (2000) reported that chronic administration of cadmium in experimental animals induced inflammation of renal interstitium and degenerative tubular changes.

There are many explanations for the pathogenesis of cadmium toxicity. Buzard and Kasprzak, (2000) reported that toxic doses of cadmium were capable of disturbing the natural oxidation/reduction balance in cells and affects cellular antioxidant systems.

Patra et al. (1999) stated that daily administration of cadmium to rats for 3 months enhanced lipid peroxidation and inhibit superoxide dismutase activity in liver, kidney and testis. Inhibition of superoxide dismutase in these organs suggested a role of free radicals in causing cellular damage with long-term exposure to cadmium.

While Milnerowicz and Madej, (1999) reported that chronic exposure to cadmium resulted in its accumulation in the liver, where it forms complexes with high and low molecular mass proteins in the liver, which in turn, were transported to the kidneys in the form of Cd-metallothionein complex (Cd-MT), leading to kidney damage. Cd-MT is much more toxic to the kidneys than free cadmium ions.

In the present study, treatment of the cadmium intoxicated rats with oxygen-ozone mixture as intraperitoneal injection during the last 10 days of the experiment, at a daily dose of 1 ml showed improved histopathological features of both the liver and kidney. Subsequently these changes were similar to those received placebo only.

In the liver, the portal tract showed lymphocytic infiltration in 46% of rats. Meanwhile in the hepatocytes, mild degenerative cloudy swelling appeared in 70% of rats, mild hepatocyte hyperplasia in 32% of rats, whereas focal necrosis and apoptosis did not appear in any of these rats. At the same time, Kupffer cell hyperplasia occurred in 45% of rats. In the kidney, mild degenerative cloudy swelling appeared in 50% of rats, without lymphocytic infiltration or casts inside the tubules.

The present study results proved the good role of oxygen-ozone mixture in protection of rats' organs against cadmium toxicity. Madej et al., (1994) showed that oxygen-ozone injections protected animals intoxicated by cadmium. It inhibited increase of free radicals reaction (FR) and stabilized the activity of superoxide dismutase, glutathione s-transferase, and catalase in rats intoxicated with cadmium. Kuryszko et al., (1995) stated that hepatocytes in rats poisoned with cadmium and



treated with oxygen-ozone mixture displayed a much lesser damage than that found at rats which did not receive treatment with ozone. Also, Laszczyca et al., (1996) found that parenteral ozone treatment of cadmium intoxicated animals, were related to the activities of FR in the liver, kidney, and brain of these animals. Milnerowicz and Madej, (1999) reported that intraperitoneal injection of oxygen-ozone mixture decreased cadmium accumulation in the liver, kidney, and pancreas. The best results of oxygen-ozone mixture infusion were observed in the liver.

#### Group B:

Organophosphorous insecticides are highly toxic chemicals that exert their effects in both insects and mammals by inhibiting acetyl cholinesterase (AChE) in the nervous system with subsequent accumulation of toxic levels of acetyl choline and oxidative damage to lipid (malondialdehyde) and DNA (Bachowski et al., 1998; Hebert et al., 2000).

In the present work, the results of oral administration of (1/20 LD50) dose of organophosphorous (diazinon) for 2 months to male albino rats showed noxious changes of liver and kidney in comparison to placebo control group. So, the liver after diazinon intoxication showed lymphocytic infiltration in 40% of rats, degenerative changes in 40% of rats in the form of macrovascular steatosis, and microvesicular

steatosis. Necrotic hepatocytes in the form of small multiple random foci (focal necrosis) appeared in 72% of rats. Whereas hepatocyte hyperplasia occurred in 60% of rats. At the same time, in the renal collecting tubules, there was a swelling of their lining occurred in 30% of rats. In the proximal tubules, degenerative changes in the form of cloudy swelling appeared in 84% of rats. However, casts inside the tubules occurred in only 32% of rats.

There is no doubt that diazinon, like other organophosphorous poisons exerts its toxic effects through inhibition of cholinesterase activity (Ceron et al., 1996; Hamm et al., 1998). In this respect, Hebert et al., (2000) and Handy et al., (2002) reported that chronic diazinon exposure caused organ pathologies due to deleterious effects on metabolism with oxidative stress.

In the present study, treatment of diazinon intoxicated rats with oxygen-ozone mixture as intraperitoneal injection during the last 10 days of the experiment at a daily dose of 1 ml; showed that in the hepatic portal tract, mild lymphocytic infiltration occurred in 25% of rats. At the same time, mild micro and macrovesicular steatosis were observed in 76% of rats. Whereas, hepatocyte necrosis and hyperplasia did not appear in any of the rats. Simultaneously, the renal collecting tubules appeared normal. However, the proximal

tubules showed moderate degenerative cloudy swelling in only 58% of rats with absence of casts.

The present study confirmed that repeated administration of ozone in atoxic doses was able to reduce the deleterious effects of organophosphorus (diazinon) in experimental animals (Pareta et al., 1999).

On the basis of oxidant properties of O<sub>3</sub> and the possibility that specific cell sensors are activated by lipid oxidation products which may upregulate the antioxidant system, O<sub>3</sub> may induce an adaptation to oxidative stress. Moreover, not only O<sub>3</sub> could induce tolerance to itself but it could prepare the host to face physiopathological conditions mediated by reactive oxygen species.

#### Groups C:

Barbiturates are implicated frequently in self-poisonings and overdoses and are responsible for the majority of all suicides. The damaging effects of overdose of barbiturate (phenobarbitone) have been reported to be due to oxidative stress (Kinoshita et al., 2002).

In the present work, histopathological examination of the liver of barbiturate poisoned rats showed in the hepatocytes, degenerative changes in the form of cloudy swelling and vacular degeneration in 100%. Microvesicular steatosis occurred in

78%. Focal necrosis of hepatocytes appeared in 81%, while hepatocytic hyperplasia occurred in 70%. On the other hand, in the renal proximal tubules, degenerative cloudy swelling occurred in 75%, however, the casts inside the tubules occurred in 25%.

These results coincide with the results obtained by Muller et al., (2000) and Sarraf et al., (1997). They stated that centrilobular hepatocyte necrosis and hyperplasia have been observed in experimental animals treated with overdose of phenobarbitone for a long time.

The damaging effects of overdose of phenobarbitone have been explained to be due to generation of oxidative stress (Hodges et al., 2000; Kinoshita et al., 2002).

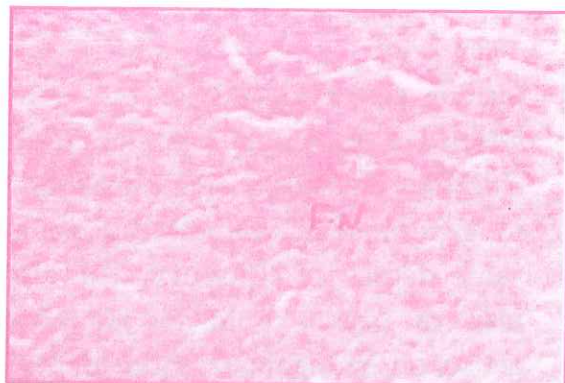
In the present work, treatment of rats exposed to overdose of phenobarbitone, with oxygen-ozone mixture as intraperitoneal injection during the last 10 days of the experiment at a daily dose of 1 ml, resulted in moderate hepatic degenerative cloudy swelling in 60% while necrosis appeared in 58%. At the same time, moderate renal degenerative cloudy swelling of the proximal tubules occurred in 55% while casts inside the tubules were noted in only 15%.

Phenobarbitone exerts its toxic actions through induction of oxidative stress

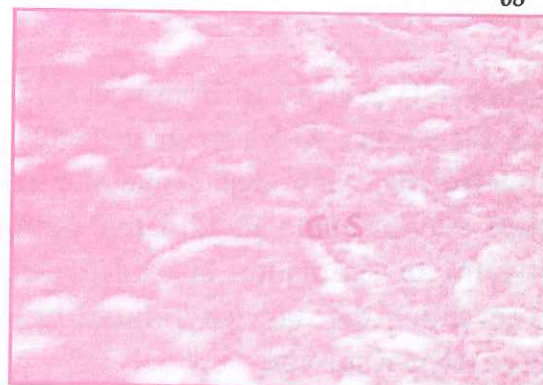
(Kinoshita et al., 2002; Hodges et al., 2000). In this respect, Al-Dalain et al., (2001) postulated that controlled ozone administration may promote an oxidative preconditioning or adaptation to oxidative stress, preventing the damage induced by reactive oxygen species.

From the above results, ozone was ef-

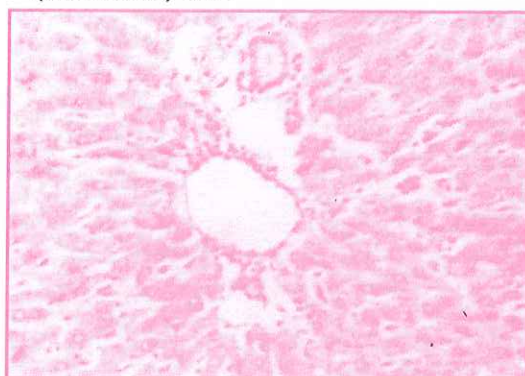
fective agent to reduce the damaging effects of previous 3 toxins (cadmium chloride, diazinon and phenobarbitone) in experimental animals but not at the same degree of efficiency. The effectiveness of ozone could be related to its action on endogenous antioxidants - pro-oxidants balance in favour of antioxidants.



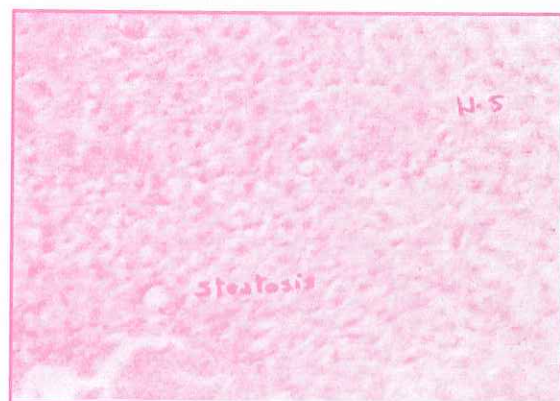**Fig. 1 :** A photomicrograph of the liver of rats received CdCl<sub>2</sub> showing massive lymphocytic infiltration, cloudy swelling and necrotic hepatocytes in the form of large foci (F.N) (H&E stain) 200.



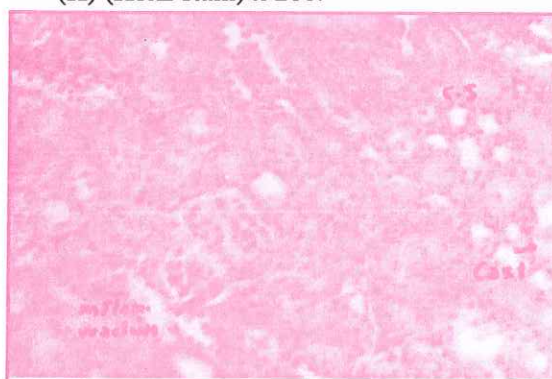
**Fig. 4 :** A photomicrograph of the kidney of rats received CdCl<sub>2</sub> and treated with oxygen-ozone mixture showing mild cloudy swelling (C.S) (H&E stain) X 200.



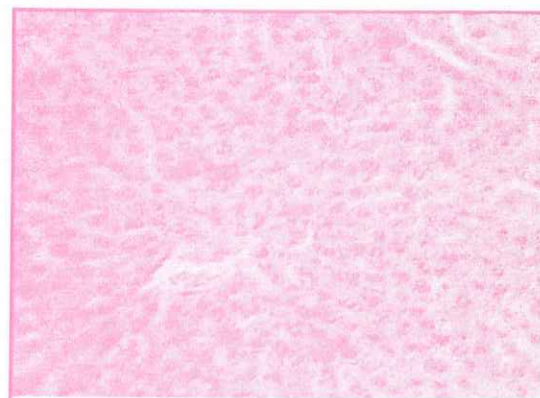
**Fig. 2 :** A photomicrograph of the liver of rats received CdCl<sub>2</sub> and treated with oxygen-ozone mixture showing mild lymphocytic infiltration (LA), mild Kupffer cell swelling (K) (H&E stain) x 200.



**Fig. 5 :** A photomicrograph of the liver of rats received diazinon showing micro vesicular steatosis, hepatocyte hyperplasia (H.S) (H&E stain) x 200.



**Fig. 3 :** A photomicrograph of the kidney of rats received CdCl<sub>2</sub> showing cloudy swelling (C.S), interstitial inflammatory reaction, and casts inside the tubules (H&E stain) x 200.



**Fig. 6 :** A photomicrograph of the liver of rats received diazinon and treated with oxygen-ozone mixture showing mild cloudy swelling (H&E stain) x 200.

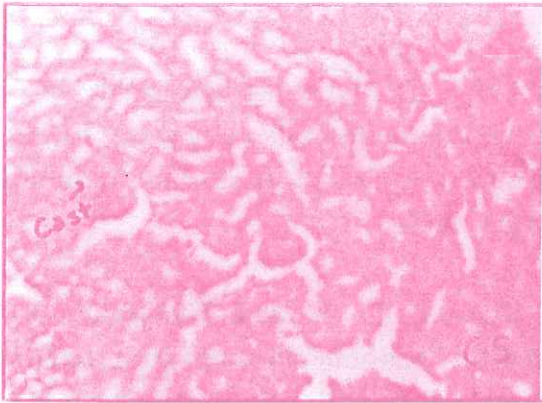


Fig. 7 : A photomicrograph of the kidney of rats received diazinon showing cloudy swelling (C.S) and casts inside the tubules (H&E stain) x 200.




Fig. 10 : A photomicrograph of the liver of rats received phenobarbitone and treated with oxygen-ozone mixture showing mild cloudy swelling (C.S) (H&E stain) x 200.

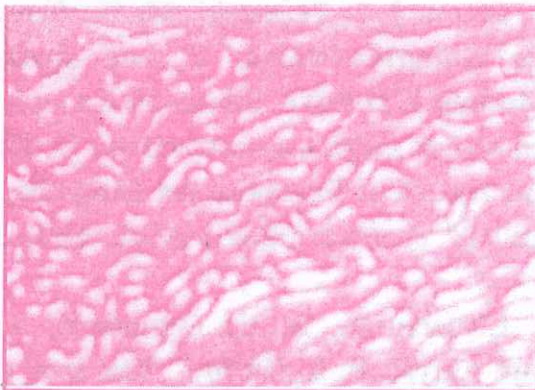


Fig. 8 : A photomicrograph of the kidney of rats received diazinon and treated with oxygen-ozone mixture showing mild cloudy swelling (C.S) (H&E stain) x 200.

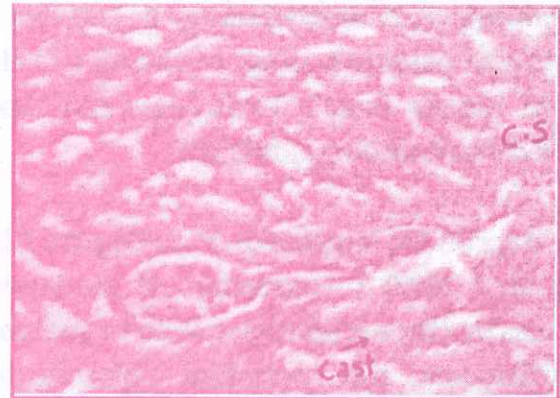


Fig. 11 : A photomicrograph of the kidney of rats received phenobarbitone showing cloudy swelling (C.S), and casts inside the tubules (H&E stain) x 200.

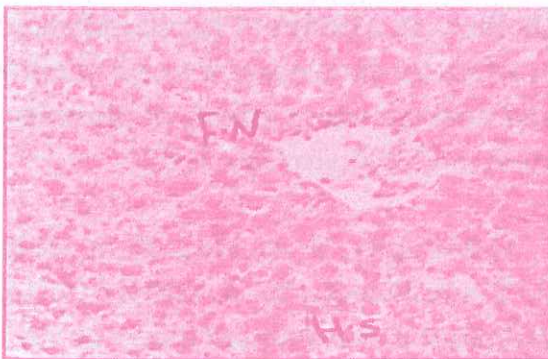

Fig. 9 : A photomicrograph of the liver of rats received phenobarbitone showing focal necrosis (F.N), hepatocyte hyperpalsia (H.S) (H&E stain) x 200.

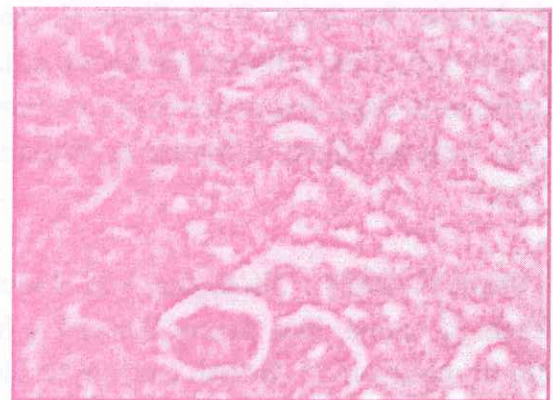


Fig. 12 : A photomicrograph of the kidney of rats received phenobarbitone and treated with oxygen-ozone mixture showing mild cloudy swelling (C.S) (H&E stain) x 200.

## REFERENCES

- Al-Dalain, S. M.; Martinez, G.; Candelario-Jalil, E; Menendez, S.; Re, L; Giuliani, A. and Leon, O. S. (2001) : "Ozone treatment reduces markers of oxidative and endothelial damage in an experimental diabetes model in rats". *Pharmacol. Res.*, 44 (5): 391.
- Bachowski, S.; Xu, Y.; Stevenson, E. D.; Walborg, F. E. and Klannig, E. J. (1998) : "Role of oxidative stress in selective Dieldrin mouse liver". *Toxicology and Applied Pharmacology*, 150: 301.
- Bagchi, D.; Vuchetich, P. J.; Bagchi, M.; et al. ( 1997) : "Induction of oxidative stress by chronic administration of sodium dichromate and cadmium chloride to rats". *Free Radic. Biol. Med.*, 22(3) : 471.
- Barceloux D. G. (2001) : Halogenated Solvents, Trichloroethylene and Methylenechloride. In: John B; Sullivan J. and Krieger GR, Eds. *Clinical Environmental Health and Toxic Exposure*. 2nd Ed., New York. London Cott, Williams & Wilkins, P.733.
- Bocci V. (1999) : "Biological and clinical effects of ozone. Has ozone therapy a future in medicine ?". *British Journal of Biomedical Science*, 56:270.
- Bompert, G.; Orfila, C. and Manuel, Y. (1999) : "Cisplatin nephrotoxicity in cadmium-pretreated rats-enzymatic, functional and morphological studies". *Nephrou.*, 58 (1): 68-74.
- Buzard, G. S. and Kasprzak, K. S. (2000) : "Possible roles of nitric oxide and redox cell signaling in metal-induced toxicity and careinogenesis: a review". *J Environ Pathol Toxicol Oncol.*, 19 (3): 179.
- Ceron, J. J.; Ferrando, M. D.; Sancho, E.; Gutierrez-Panizo, C. and Andreu-Moliner E. (1996) : "Effects of diazinon exposure on cholinesterase activity in different tissues of European eel (*Anguilla anguilla*)". *Ecotoxicol Environ Saf.*, 35(3): 222.
- Christensen, H. E.; Luginbyhi, T. T. and Carrol, B. S. (1970) : "The toxic substance list. U.S. department of Health, Education and Welfare, Rockville, Maryland, P. 170.
- Dingemane, J.; Hameter, B. M. and Danhof, M. (1990) : "Pharmacodynamics of tolerance development to the anesthetic and anticonvulsant effects of phenobarbital in rats". *J Pharm Sci.*, 3: 207.
- El-Maraghy, S. A., Gad, M. Z., Fahim, A. T. and Hamdy, M. A. (2001) : "Effect of cadmium and aluminum intake on the antioxidant status and lipid peroxidation in rat tissues. *J Biochem Mol Toxicol.*, 15 (4): 207.

- Habeebu, S. S.; Liu, Y.; Liu, Y. and Klaassen C. D. (2000) : "Metallothionein-null mice are more sensitive than wild-type mice to liver injury induced by repeated exposure to cadmium". *Toxicol Sci.*, 55 (1): 223.
- Hamm, J. T.; Wilson, B. W. and Hinton, D. E. (1998) : "Organophosphate-induced acetylcholinesterase inhibition and embryonic retinal cell necrosis in vivo in the teleost (*Oryzias latipes*)". *Neurotoxicology*, 19 (6): 853.
- Handy, R. D.; Abd-E1-Samei, H. A.; Bayomy, M. F.; Mahran, A. M.; Abdeen, A. M. and El-Elaimy, H. A. (2002) : "Chronic diazinon exposure: pathologies of spleen, thymus, blood cells, and lymph nodes are modulated by dietary protein or lipid in the mouse". *Toxicology*, 172(1): 13.
- Hayes, A. W. (1993) : "A review of biological effects and their role in human diseases". *Clinical Toxicol.*, 17.
- Hebert, V. R.; Hoonhout, C. and Miller, G. C. (2000) : "Reactivity of certain organophosphorus insecticides toward hydroxyl radicals at elevated air temperatures". *J. Agric Food Chem.*, 48 (5): 1922.
- Hodges, N. J.; Orton, T. C.; Strain, A. J.; et al.; (2000) : "Potentiation of epidermal growth factor-induced DNA synthesis in rat hepatocytes by phenobarbitone: possible involvement of oxidative stress and kinase activation". *Carcinogenesis*, 21 (11): 2041.
- Hughes, M. R.; Smits, J. E.; Elliott, J. E. and Bennett, D. C. (2000) : "Morphological and pathological effects of cadmium ingestion on Pekin ducks exposed to saline". *J. Toxicol. Environ Health A.*, 61 (7): 591.
- Jones, M. M. and Cherian, M. G. (1990) : "The search for chelate antagonists for chronic cadmium intoxication". *Toxicology*, 62: 1.
- Kinoshita, A.; Wanibuchi, H.; Imaoka, S.; et. al. (2002) : "Formation of 8-hydroxydeoxyguanosine and cell-cycle arrest in the rat liver via generation of oxidative stress by phenobarbital: association with expression profiles of p21(WAF1/Cip1), cyclin D1 and Ogg1". *Carcinogenesis*, 23 (2): 341.
- Kuryszek, J.; Madej, A. J. and Made, P. (1995) : "Ultrastructural studies on organs of cadmium-poisoned rats treated with oxygen-ozone mixture". *Archivum Veterinarium Polonicum*, 35/1-2; 109.
- Laszczyca, P.; Ewakawka, S.; Witas, I.; Dolezga, B.; Falkus, B.; Mekail, A.; Ziolkowska, B.; Madej, P. and MiGula, P. (1996) : "Lipid peroxidation and activity of

antioxidative enzymes in the rat model of ozone therapy". *Materia Medicapolona*, 28 (4): 155.

Leon, O. S.; Menendez, S.; Merino, N.; Castillo, R.; Sam, S.; Perez, L.; Criz, E. and Bocci, V. (1998) : "Ozone oxidative preconditioning: a protection against cellular damage by free radicals". *Mediators of Inflammation*; 7: 289.

Madej, Madej P. and Klimentowski S. (1994) : "The level of free radicals and the activity of their enzymatic scavengers (SOD, CAT) in the organs of the rats, intoxicated with cadmium and exposed to the action of oxygen-ozone mixture. II Ogolnopolski Kongres Pol. Tow". *Ozonoterapii Osiagniecia Ozonoterapii W Medycynie Polskiej*. Katowice, 61.

Milnerowicz, H. and Madej, J. A. (1999) : "Immunohistochemical localization metallothionen in tissues of rats intoxicated by cadmium acetate and subjected to intraperitoneal injections of oxygen or oxygen-ozone mixture". *Polish Journal of Veterinary Sciences*, 2 (1): 5.

Muller, P. B.; Taboada, J.; Hosgood, G.; Partington, B. P.; VanSteenhouse, J. L.;

Taylor, H. W. and Wolfsheimer, K. J. (2000) : "Effect of long-term phenobarbital treatment on the liver in dogs". *J. Vet. Intern. Med.*, 14 (2): 165-71.

Patra, R. C.; Swarup, D. and Senapati S. K. (1999) : "Effects of cadmium on lipid peroxides and superoxide dismutase in hepatic, renal and testicular tissue of rats". *Vet. Hum. Toxicol.*, 41 (2): 65.

Peralta, C.; Leon, O. S.; Xaus, C.; Prats, N.; Jalil, E. C.; Planell, E. S.; Puig-Parellada, P.; Gelpi, E. and Rosello-Catafau, J. (1999) : "Protective effect of ozone treatment on the injury associated with hepatic ischemia-reperfusion: antioxidant-prooxidant balance". *Free Radic Res.*, 31 (3): 191.

Sarraf, C. E.; Horgan, M.; Edwards, R. I.; et al. (1997) : "Reversal of phenobarbital-induced hyperplasia and hypertrophy in the livers of lpr mice". *Int. J. Exp. Pathol.*, 78 (1): 49.

Worthing, C. R. and Hance, R. J. (1991) : *The pesticide Manual : A world compendium*. 9th edition, British Group Production Council, Survey, P. 248.



## دراسة قيمة الأوزون في علاج بعض حالات التسمم الكيميائية المختلفة : دراسة هستوباثولوجية

المشتركون في البحث

أ. د. ساميه أحمد محمد                      أ. د. إيهاب محمد الشواف\*  
د. عزة النزالى                              د. سميه محمد العزب

من أقسام الطب الشرعى والسموم الإكلينيكية ، والباثولوجيا\*

كلية الطب - جامعة المنصورة

الهدف : إستهدف هذا البحث دراسة تأثير التعرض لكل من الكادميوم، المبيد الحشرى الفسفورى العضوى (ديازينون) والفينوباربيتال في الفأر المعملى الأبيض وتأثير العلاج بالأوزون على الآثار الهستوباثولوجية الناجمة عن تناول هذه الكيماويات السامة.

المنهج : إستعمل عدد من ذكور الفئران وتم تقسيمها إلى المجموعات الآتية :

المجموعة الأولى : تضم ٤٥ فأراً أعطيت كلوريد الكادميوم عن طريق الفم  $1/20$  من الجرعة النصف مميتة منها ١٥ فأراً أعطيت المركب الكيماوى لمدة ٦٠ يوماً بينما ١٥ فأراً تم إعطاؤها بالحقن اليريتونى ٤٠ ميكروجرام أوزون في ١م<sup>٣</sup> أكسجين في العشرة أيام الأخيرة بينما ١٥ فأراً تم إعطاؤها بالحقن اليريتونى ١م مكعب غاز النيتروجين الحامل في العشرة أيام الأخيرة أيضاً مع إستمرار إعطاء المادة السامة المحددة في كلتا الحالتين.

المجموعة الثانية : تضم ٤٥ فأراً أعطيت المبيد الحشرى الفسفورى (ديازينون) بالفم  $1/20$  من الجرعة النصف مميتة منها ١٥ فأراً أعطيت المركب الكيماوى فقط لمدة ٦٠ يوماً كاملة بينما ١٥ فأراً أعطيت في العشرة أيام الأخيرة مخلوط الأوزون والأكسجين وآخر ١٥ فأراً أعطيت غاز النيتروجين الحامل مع عدم توقف الديازينون في العشرة أيام الأخيرة.

المجموعة الثالثة : تضم ٤٥ فأراً تم إعطاؤها مركب الفينوباربيتال ١٠٠ ملليجرام/ كجم عن طريق الحقن في اليريتون ثلاث هذه الفئران أعطى المركب الكيماوى لمدة ٦٠ يوماً كاملة دون إضافات بينما الثلث الثانى أعطى مخلوط أوزون - أكسجين والثلث الأخير من الفئران أعطى غاز النيتروجين في العشرة أيام الأخيرة دون وقف المادة السمية الأصلية.

وفى نهاية البحث تم ذبح الحيوانات وتشريحها واستخراج الكبد والكلى لفحص التغيرات الهستوباثولوجية نتيجة المادة السمية المعطاه فقط

و بعد العلاج بالأوزون أو النتروجين فى العشرة أيام الأخيرة من كل مرة تعاطى المادة السمية ( ٦٠ يوماً).

**النتائج :** أثبت الفحص الهستوباثولوجى فاعلية غاز الأوزون فى تقليل الآثار الضارة الناجمة عن السموم المختلفة فى كل من الكبد والكلى  
يتضح ذلك كما يلى :

١- مجموعة الكادميوم بعد العلاج بالأوزون ظهر إرتشاح بالخلايا الليمفية فى الكبد وفى الخلايا الكبدية نفسها ولقد وجد تورم غيمى وتكثر نسيجى بسيط فى الخلايا مع فرط نمو فى خلايا النسيجية بينما لم يظهر التتركز البؤرى فى أى من الفئران، بفحص الكللى لم يظهر إرتشاح بالخلايا الليمفية أو الكتل الليمفية فى أى من الفئران.

٢- مجموعة الديازينون بعد العلاج بالأوزون : وجد إرتشاح بسيط بالخلايا الليمفية الكبدية وفى خلايا الكبد نفسها كما وجد إعتلال بسيط فى الغدد الدهنية فى صورة حويصلات كبيرة وصغيرة فى حين لم يظهر التتركز البؤرى أو فرط النمو النسيجى للخلايا فى أى من الفئران، بالنسبة للكلى ظهرت الأنبيبات الجامعة فى صورة طبيعية بينما بفحص القنيات الملتفة وجد تورم غيمى مع إختفاء الكتل الليمفية.

٣- مجموعة الفينوياريتال بعد العلاج بالأوزون : ظهر التورم الغيمى كما ظهر التتركز البؤرى بصورة أقل بينما لم يظهر فرط النمو النسيجى للخلايا فى أى من الفئران، وبالنسبة للكلى وجد تورم غيمى فى خلايا الأنبيبات الملتفة للكلى من الفئران كما لوحظ وجود كتل ليفية.

**الاستنتاج :** على ضوء هذه النتائج يمكن أن نستنتج أن الأوزون له فاعلية فى حماية الجسم والأعضاء الداخلية (الكبد والكلى) من التأثير الضار لكل من الكادميوم، الديازينون والفينوياريتال مع إختلاف درجة الاستجابة لكل من هذه السموم فالكادميوم كان أكثرهم إستجابة للعلاج بالأوزون يليه الديازينون بينما كان الفينوياريتال أقلهم إستجابة للعلاج بالأوزون.