

## **POSSIBLE PROTECTIVE ROLE OF GRAPE SEED PROANTHOCYANIDIN ON FLUORIDE INDUCED TESTICULAR TOXICITY IN ADULT AND YOUNG ALBINO RATS**

*BY*

*Mona El-Demerdash, Amal M. Abd El khalik,  
Sahar A. Abou El Magd\*and Amal F. Gharib\*\**

*Departments of Forensic Medicine and Clinical Toxicology, Community, Environmental and Occupational Medicine\*  
and Medical Biochemistry\*\*, Faculty of Medicine, Zagazig University, Egypt*

### **ABSTRACT**

*Increasing infertility, has become a serious issue. Sodium fluoride (NaF) is a wide spread natural pollutant and large number of the world population is exposed to high doses of fluoride. Grape seed proanthocyanidins (GSP), exerts a novel spectrum of biological, pharmacological, and therapeutic properties against oxidative stress , so it was of special concern to investigate the role of the naturally occurring antioxidant GSP on effect of fluoride on male reproduction . The study included 72 male rats, 36 adult and 36 young rats were divided into six groups (n =12, 6 adult & 6 young ). Group I: negative control. Group II: was given distilled water. Group III: was given GSP 75 mg / kg. Group IV: was given NaF 18 mg / kg. Group V: was given NaF 18 mg /kg and GSP 75 mg /kg. Group VI: was given NaF 18 mg /kg then it was stopped and rats were examined 30 days after its discontinuation. All treatments were given daily by oral gavage for 30 days. At the end of experimental and follow up periods, serum levels of testosterone, follicle stimulating (FSH) and Luteinizing (LH) hormones in addition to serum levels of malondialdehyde (MDA) and plasma nitrite were determined. Absolute and relative testes weights and histopathological examination of testes of all rats also performed. The results revealed that, fluoride induced significant decrease in plasma testosterone, FSH and LH levels in adult rats and non significant change of these hormones in young rats as compared to control groups. It also induced significant increase in serum MDA and nitrite levels in adult and young rats as compared to control groups. Absolute and relative testes weights of the adult and young rats of NaF group were significantly reduced compared to control groups. Section of adult rats testes of NaF treated group revealed arrest of spermatogenesis, sloughing of spermatogenic cells and disorganization of the epithelial lining of seminiferous tubules. While, testes of young rats revealed total spermatogenic atrophy and degeneration with thickening of the basement membrane of seminiferous tubules and interstitial fibrosis. Co-administration of NaF and GSP showed significant increase of plasma testosterone, FSH and LH levels in adult rats and decrease in serum MDA and nitrite levels compared to NaF alone or follow up group in adult and young rats. Also,*

nearly normal testicular weights and structure were recorded in NaF and GSP group. Follow up group of adult and young rats showed slight reversibility of NaF toxicity. It was concluded that short term administration of fluoride induced testicular toxicity, and lipid peroxidation which may be a molecular mechanism involved in fluoride induced toxicity in both adult and young rats. Furthermore, these effects was reversed by the use of antioxidant grape seed proanthocyanidins combination. It is recommended to use dietary antioxidant supplements for amelioration of toxic manifestations of fluoride in exposed population.

## INTRODUCTION

Fluoride is found in the atmosphere, water, soil, coal, food, dental and industrial uses (Matsui et al., 2007).

Fluoride is a naturally occurring toxic mineral present in drinking water. Fluorspar, Cryolite and Fluorapatite are the naturally occurring minerals, from which fluoride finds its path to ground water through infiltration (Shailaja and Johnson, 2007).

In the human population, increasing fluoride intake may arise from fluoridation of water, dental caries prevention, paediatric supplements (Hortova et al., 2007).

Universal use of fluorine compounds in dentistry, as well as industrial and civilization-related exposures may produce undesirable effects of fluorine action. The effects of fluoride ions depend on the dose and exposure time. Some may be positive, in caries prevention, while others are harmful when optimal prophylactic or

therapeutic doses have been surpassed (Dabrowska et al., 2006a).

Effect of fluorides on various metabolic levels in hard and soft tissues, namely respiration as well as carbohydrate, protein, enzymatic and vascular metabolism, can disturb detoxication of fluorine compounds administered orally (Dabrowska et al., 2006b).

High concentration of fluorine is noxious to the health of humans and animals (Shanthakumari et al., 2007).

Fluoride is an essential trace element that has protective effects against bone mineral loss. However, it becomes toxic at higher doses and induces some adverse effects on a number of physiological functions, including reproduction (Guney et al., 2007).

Fluorosis caused by long-term intake of high fluoride levels is characterized by clinical bone, tooth and soft tissues manifestations. Young children are at risk of fluorosis if they regularly swallow large

amounts of toothpaste. So, children under age 2 years should brush without toothpaste and those between ages 2-5 should be given toothpaste no larger than a pea (Kao et al., 2004).

Although fluorosis is irreversible it could be prevented by appropriate and timely interventions through the understanding of the process at biochemical and molecular levels. Increased production of reactive oxygen forms and lipid peroxidation are considered to play an important role in the pathogenesis of chronic fluoride toxicity (Gavriliuk et al., 2007).

Joshi et al. (2004) reported that toxic metal ions have been implicated in the generation of reactive oxygen species (ROS) and nitric oxide (NO) and plant flavonoids could protect against oxidative damage.

In recent years, a considerable emphasis has been focused on the importance of the naturally available botanicals that can be consumed in an individual's everyday diet because of their antioxidant and anti-inflammatory properties (Nandakumar et al., 2008).

Also, antioxidants from plants were known to reduce the oxidative stress by scavenging free radicals, chelating metal ions and reducing inflammation (Datla et al., 2007).

Flavonoids are important secondary metabolites in many fruits, hydroxylated flavonols and proanthocyanidins are accumulated in grapes (Bogs et al., 2006).

Grape seed extract (GSE) is a commonly available dietary supplement taken for the anti-oxidant activity that's attributed to its proanthocyanidin content (Kim et al., 2006).

The aim of the present work was to investigate the protective role of the naturally occurring GSP on the toxic effect of fluoride on the testes of adult and young rats.

## MATERIAL AND METHODS

### Material :

#### 1- Drugs

**Sodium fluoride (NaF):** It is supplied by Sigma Chemical Co. (USA), for pharmaceutical-chemical Industries in the form of white crystalline powder. Sodium fluoride was used as the source of fluoride. It was given in a dose of 1/10 of LD50 of NaF (18 mg / kg ).

N.B. LD50 of NaF orally in rats = 0.18 gm/kg (Budavari et al., 2001).

**Grape seeds proanthocyanidin (GSP):** Noxy life capsules is produced by The Arab Co. under licence of Nulife international U.S.A. It was given in a dose of 75 mg / kg (Devi et al., 2006).

Distilled water was always used to prepare the sodium fluoride and GSP solutions.

**Animal design:**

The study was conducted on 72 male albino rats. Thirty six adult rats (2-4 month) (Krüger et al., 2006), having body weight  $150 \pm 10$  g and 36 young rats (28 days) (Boroushaki, 2003), their weights ranged from 60 - 70 gm each. The rats were obtained from the breeding animal house, faculty of medicine, Zagazig University. All rats were housed under similar conditions. They were acclimated in the animal facility for 3-5 days before use. The rats were fed commercial rodent pellets and given water ad libitum throughout the experiment.

The rats were divided into numerically six equal groups, each of 12 rats:

Each group involved 6 adult rats and 6 young rats.

Dosing for all test compounds was delivered by oral intubation in 1 ml distilled water.

**Group 1 (Negative control):**

The animals of this group didn't receive any medication and were used to determine the basic values of the tested parameters.

**Group 2 (Distilled water group):**

The rats in this group was given two ml

distilled water by gastric gavage, which is the vehicle of sodium fluoride and GSP.

**Group 3 ( GSP group):**

The rats in this group was given GSP 75 mg/kg dissolved in distilled water by gastric gavage for 30 days.

**Group 4 ( NaF group):**

The rats of this group received NaF (18 mg/kg) dissolved in distilled water by gastric gavage daily for 30 days.

**Group 5 ( NaF and GSP group):**

The rats of this group was given NaF (18 mg/kg) and GSP 75 mg/ kg dissolved in distilled water by gastric gavage daily for 30 days.

**Group 6 (Follow up group):**

The rats of this group received NaF (18 mg/kg) dissolved in distilled water by gastric gavage daily for 30 days then it was stopped. Rats were examined 30 days after its discontinuation.

**Methods:**

**1- Body weight :**

At the end of the experimental period and follow up period, the rats of all control and tested groups were weighed and their weights were recorded.

**2- Biochemical study:**

After light anesthesia with ether inhalation, the blood was collected from the

retro-orbital plexus in a test tube and left to clot then centrifuged. After centrifugation at 3000 rpm for 15 minutes the clear sera were separated for determination of serum levels of testosterone hormone, follicle stimulating hormone (FSH) and Luteinizing hormone (LH) by method of Teitz (1995).

Also serum malondialdehyde (MDA) level was measured based on the reaction of thiobarbituric acid with MDA according to the method of Cheng et al. (1984) and plasma nitrite as an indicator of NO production was determined by using Griess reagent according to the method of Torre et al. (1996).

### 3- Testes weight:

After taking the blood samples rats were sacrificed and both testes of each rat were excised and grossly inspected and then were weighed and the mean weight of both testes was estimated also the weight was recorded in relation to the body weight (relative testes weight) for all studied groups.

### 4- Histopathological study:

The testes were fixed in Bouin's fixative for 24 hours. Then the specimens were processed for preparation of 5µm thickness paraffin sections which were stained with Hematoxylin and Eosin (H & E) stain (Horobin and Bancroft, 1998) and examined under light microscope for histopath-

ological changes.

### Statistical analysis:

All the grouped data were statistically evaluated with SPSS, version 10 software (Norusis, 1997). Testing methods included one-way analysis of variance (ANOVA) for comparisons between more than two groups followed by least significant difference (LSD) test for comparison between two groups. P-values of  $\leq 0.05$  were considered to indicate statistical significance. All the results were expressed as mean  $\pm$  S.D.

## RESULTS

No statistically significant changes were observed in the studied parameters between negative control (group 1), distilled water (group 2) and GSP extract (group 3) of both adult and young rats (Tables 1&2).

### Body weight:

There was no significant alteration in body weight gain across the experiment in all tested groups of both adult and young rats (Tables 1&2).

### Biochemical results:

Plasma testosterone, FSH and LH levels were decreased significantly in fluoride treated group of adult rats. While co-administration of GSP to fluoride treated rats showed significant increase of plasma

testosterone, FSH and LH levels but not to control levels. Follow up group of adult rats showed non significant increase of testosterone, FSH and LH levels compared to fluoride treated group (Table 1). Plasma testosterone, FSH and LH levels were nearly similar to control levels in either NaF, NaF and GSP or follow up group of young rats (Table 2). Serum MDA and nitrite levels (indicator of NO production) were significantly elevated in NaF treated group and follow up group compared to control groups. While combined NaF and GSP extract administration showed that serum MDA and nitrite levels were non significantly differ from the control values (Tables 1&2).

#### Testes weight:

Both absolute and relative testes weight of the rats of NaF and follow up groups of adult and young rats were significantly reduced compared to control groups, however in combined NaF and GSP extract group of adult and young rats they were near control levels (Tables 1 & 2).

#### Histopathological results of the testes:

Microscopic examination of sections of the testes of control rats (both negative and positive groups) revealed normal structure of the testis. Adult rat's testis is formed of seminiferous tubules with active spermatogenesis with interstitial tissue between tubules containing Leydig

cells (testosterone secreting cells). Each tubule is lined by cells formed of Sertoli cells and various stages of spermatogenic cells up to mature sperms and is surrounded by thin membrane (Plate 1, Figure 1). Young rat's testis is formed of seminiferous tubules which lined with Sertoli cells and spermatogonia only with the absence of Leydig cells and active spermatogenesis (Plate 2, Figure 1).

Section of adult rat's testis of NaF treated group revealed arrest of spermatogenesis and seminiferous tubules lined with 1ry and 2ry spermatocytes only with fibrous thickening of the wall of tubules. Also most of seminiferous tubules showed degeneration, sloughing of spermatogenic cells and disorganization of the epithelial lining (Plate 1, Figure 2). While adult rat's testis of combined NaF and GSP extract treated group revealed nearly normal testicular structure (Plate 1, Figure 3). After 30 days of NaF discontinuation, testis of adult rats showed arrest of spermatogenesis of most of the seminiferous tubules and one of the seminiferous tubules showed few spermatozoa (Plate 1, Figure 4). Young rat's testis after NaF treatment revealed that seminiferous tubules showed total spermatogenic atrophy and degeneration with thickening of the basement membrane of tubules and interstitial fibrosis (Plate 2, Figure 2). The same picture was seen after 30 days of NaF discontinuation (follow up) with

slight improvement (Plate 2, Figure 4). While combined NaF and GSP extract treated group revealed nearly normal testicular structure (Plate 2, Figure 3).

### DISCUSSION

The human population is being exposed to an enormous variety of factors contributing to growing infertility. One of the potential candidates to affect fertility is fluoride ion (Hortova et al., 2007). Fluoride ion is protoplasmic poison and only a small amount can be tolerated by any living cell and known to cause several biochemical alterations (Chatterjea and Shinde, 2002).

The results of the present study revealed that NaF administration to both adult and young rats induced testicular damage, which represented in adult rats group by decrease in plasma testosterone level, this may be due to low levels of plasma FSH and LH hormones observed in this study, since both hormones are important regulators of testicular androgenesis. These findings are consistent with previous reports (Ghosh et al., 2002; Sarkar et al., 2006; Reddy et al., 2007).

The hormonal affection was obvious in adult rats, while in young rats the hormonal levels were nearly similar in both treated and control groups but were lower than the levels of adult rats. This hormo-

nal affection explained by Mayne (1996), who reported that during childhood the rate of secretion of gonadotrophins (FSH & LH) from anterior pituitary gland is low. As puberty approaches, the amplitude and frequency of FSH and LH increase. Furthermore, Bhagavan (2002) reported that at puberty, testosterone hormone produced by testicular interstitial Leydig cells under LH stimulation, and assists FSH to bring about spermatogenesis in the seminiferous tubules. Also, before puberty Leydig cells and active spermatogenesis are absent (Berne et al., 2004).

Moreover, the present study showed that NaF administration resulted in significant increase in serum MDA and nitrite levels in the group of adult and young rats treated with NaF. These result suggest that fluoride induced increase in the activity of ROS, which indicates oxidative stress. These findings are consistent with the results of other investigators (Shivarajashankara and Shivashankara, 2002; Shanthakumari et al., 2004)

The increased serum nitrite level induced by NaF administration, which indicates increased NO production is supported by the results of Oguro et al. (2003), they reported that NaF intoxication increased cellular production of NO in rats and in vitro studies. Furthermore, Kawase et al. (1996) postulated that NaF increased

NO production due to increased expression of inducible nitric oxide synthase.

Also, the results of Shivarajashankara et al. (2003) revealed that long-term high-fluoride intake at the early developing stages of life enhances oxidative stress in the blood, thereby disturbing the antioxidant defense of rats. They suggested that increased oxidative stress could be one of the mediating factors in the pathogenesis of toxic manifestations of fluoride in young rats.

Reactive oxygen species (ROS) are implicated as important pathologic mediators in many disorders. Increased generation of ROS and enhanced lipid peroxidation are considered responsible for the toxicity of a wide range of compounds (Vani and Reddy, 2000).

The results of the present study suggested that lipid peroxidation and oxidative stress could be one of the mediating factors in the pathogenesis of reproductive toxicity induced by fluoride.

The mechanisms by which fluoride causes its deleterious effects have not been exactly determined yet. However a variety of mechanisms have been proposed to explain fluoride-induced toxicity, including oxidative stress. Oxidative stress has been observed in soft tissues such as the liver, kidney, brain, and testes in animals (Mittal

and Flora, 2007), and in people living in areas of endemic fluorosis (Shivarajashankara et al., 2001).

Also, oxidative stress as an important component to the mechanism of fluoride toxicity was reported by Shivarajashankara and Shivashankara (2002), Guo et al. (2003) and Guney et al. (2004).

Moreover, Wang et al. (2000) attributed the pathogenesis of chronic fluorosis and functional disorders of cells and organs to modification of membrane lipids, and lipid peroxidation. While, Guan et al. (1998) suggested that excessive amounts of fluoride can influence the metabolism in different organs.

Furthermore, the results revealed reduction in both relative and absolute testes weight in both adult and young rats which may be due to the atrophic and fibrotic changes that noticed by microscopic examination of testes. Also adult rat's testis revealed arrest of spermatogenesis which could be correlated with the hormonal changes. Histopathologic changes in the testes of adult rats were also observed by Sprando et al. (1998) and Krasowska et al. (2004).

Co-administration of NaF and GSP to both adult and young rats induced significant recovery which was noticed in the increase in the hormonal levels in adult



rats and decrease in LPO products MDA and NO in adult and young rats. Also, histopathological changes of the testes were restored nearly to control findings in both adult and young rats .

El-Ashmawy et al. (2007) reported that natural dietary antioxidants are extensively studied for their ability to protect cells from miscellaneous damages and grape seed extract is a potent antioxidant and useful herbal remedy, especially for controlling oxidative damages. It resulted in minimizing the hazardous effects of ethanol toxicity on male fertility.

Also, Devi et al. (2006) found that intake of proanthocyanidin which is a naturally occurring antioxidant from grape seed extract in moderately low quantity is effective in up-regulating the antioxidant defense mechanism by attenuating LPO. Moreover, Sehirli et al. (2008), reported that GSE could reduce organ injury through its ability to balance the oxidant-antioxidant status, and to regulate the release of inflammatory mediators.

However, upon withdrawal of NaF administration, partial recovery was achieved in the testes of adult and young rats and non significant recovery of the hormonal affection , indicated that the deleterious effect of fluoride on the testes may be irreversible .

Gavriliuk et al. (2007), found that fluoride induced testicular toxicity may be irreversible, but it could be prevented by appropriate and timely interventions through the understanding of the process at biochemical and molecular levels.

The results of the present study suggested that reproduction toxicity induced by fluoride may be direct effect on testicular tissue, indirect effect of fluoride on testis by the modulation of pituitary-testicular axis or oxidative stress imposed by fluoride in testicular tissue and free radical generation during oxidative stress .

### **CONCLUSION**

From the results of the present study it is concluded that short term administration of fluoride induced reproductive toxicity and lipid peroxidation which may be a molecular mechanism involved in fluoride induced toxicity in both adult and young rats. Furthermore, these effects were reversed by the use of antioxidant GSP combination. So, it is recommended to use dietary antioxidant supplements for amelioration of toxic manifestations in exposed population. Also, presence of fluoride in the environment and drinking water should be monitored regularly.

ACKNOWLEDGEMENT

Great thanks for Dr. Hala Elwey, lectur-

er of histology, Faculty of Medicine, Zaga-  
zig University for her effort in the histo-  
pathological examination.

Table (1): Effects on the tested parameters in negative control, distilled water, GSP, NaF, NaF & GSP and follow up groups of adult rats.

Parameters	Groups (n=6) Negative Control	Distilled water	GSP	NaF	NaF & GSP	Follow up	P
Body weight (gm)	150 ±50	151±60	148±40	145±50	150 ±50	149±50	>0.05
Mean testes weight (gm)	1.730±0.5	1.720±0.5	1.645±0.4	1.162±0.3 a	1.612 ±0.54 a	1.350±0.45abc	<0.001
Relative testes weight (gm/B.W)	1.2±0.2	1.1±0.1	1.2±0.2	0.8±0.2	1.0±0.1	0.9±0.1	<0.001
Testosterone (ng/ml)	1.79±0.3	1.77±0.3	1.85±0.6	0.95 ±0.27a	1.72 ±0.6 ab	1.122±0.5 abc	<0.001
FSH (µIU/ml)	3.25±1.5	3.27±1.5	3.15±1.3	1.25 ±0.54 a	1.75 ±0.6 ab	2.54 ±0.9 abc	<0.001
LH (µIU/ml)	18.41±6.1	18.2±6.0	18.35±6.0	12.6a±4.0	15.3±5.4 ab	13.5 ±5.0 ac	<0.001
Malondialdehyde (nmol/l)	3.56±1.5	3.66±1.5	2.35±1.2	9.45 ±4.0 a	5.31 ±2.0 ab	7.12±3.0 abc	<0.001
Nitrite(NO) (nmol/l)	13.95±7.0	14.75±8.0	13.75±7.0	28.12 ±9.0 a	16.22 ±6.0 ab	15.56±5.0 ab	<0.001

Values are expressed as mean ± S.D.  
Values are statistically significant at (P ≤ 0.05).

a = significant compared with control groups .  
b = significant compared with NaF treated group .  
c = significant compared with NaF & GSP treated group.

Table (2): Effects on the tested parameters in negative control, distilled water, GSP, NaF, NaF & GSP and follow up groups of young rats.

Parameters	Groups (n=6) Negative Control	Distilled water	GSP	NaF	NaF & GSP	Follow up	P
Body weight (gm)	70±10	70±11	67±13	65 a±12	67±13	65±10	> 0.05
Mean testes weight (gm)	0.450±0.05	0.520±0.04	0.520±0.04	0.125 ±0.02a	0.415±0.04ab	0.220abc±0.02	<0.001
Relative testes weight (gm/B.W)	0.64±1.3	0.74±1.4	0.64±1.3	0.19±0.6a	0.62 ±1.1ab	0.34 abc±0.5	< 0.001
Testosterone (ng/ml)	0.234±0.05	0.256±0.04	0.256±0.04	0.345 ±0.07a	0.358±0.08a	0.856 ±0.15abc	<0.001
FSH (µIU/ml)	0.521±0.15	0.521±0.15	0.495±0.14	0.451±0.2	0.612±0.3	0.535±0.2	> 0.05
LH (µIU/ml)	2.14±1.1	2.12±1.1	2.28±1.2	3.41 ±1.3a	2.45±1.2	2.85±1.5	> 0.05
Malondialdehyde (nmol/l)	2.58±1.4	2.56±1.4	2.17±1.1	8.42 ±3.0a	5.13 ±2.0ab	6.15 ±2.0abc	<0.001
Nitrite (NO) (nmol/l)	12.25±6.1	12.21±6.1	10.13±5.1	20.25 ±9.0a	14.56ab ±8.0	15.24 ±7.0abc	<0.001

Values are expressed as mean ± S.D.  
Values are statistically significant at (P ≤ 0.05).

a = significant compared with control groups .  
b = significant compared with NaF treated group .  
c = significant compared with NaF & GSP treated group.

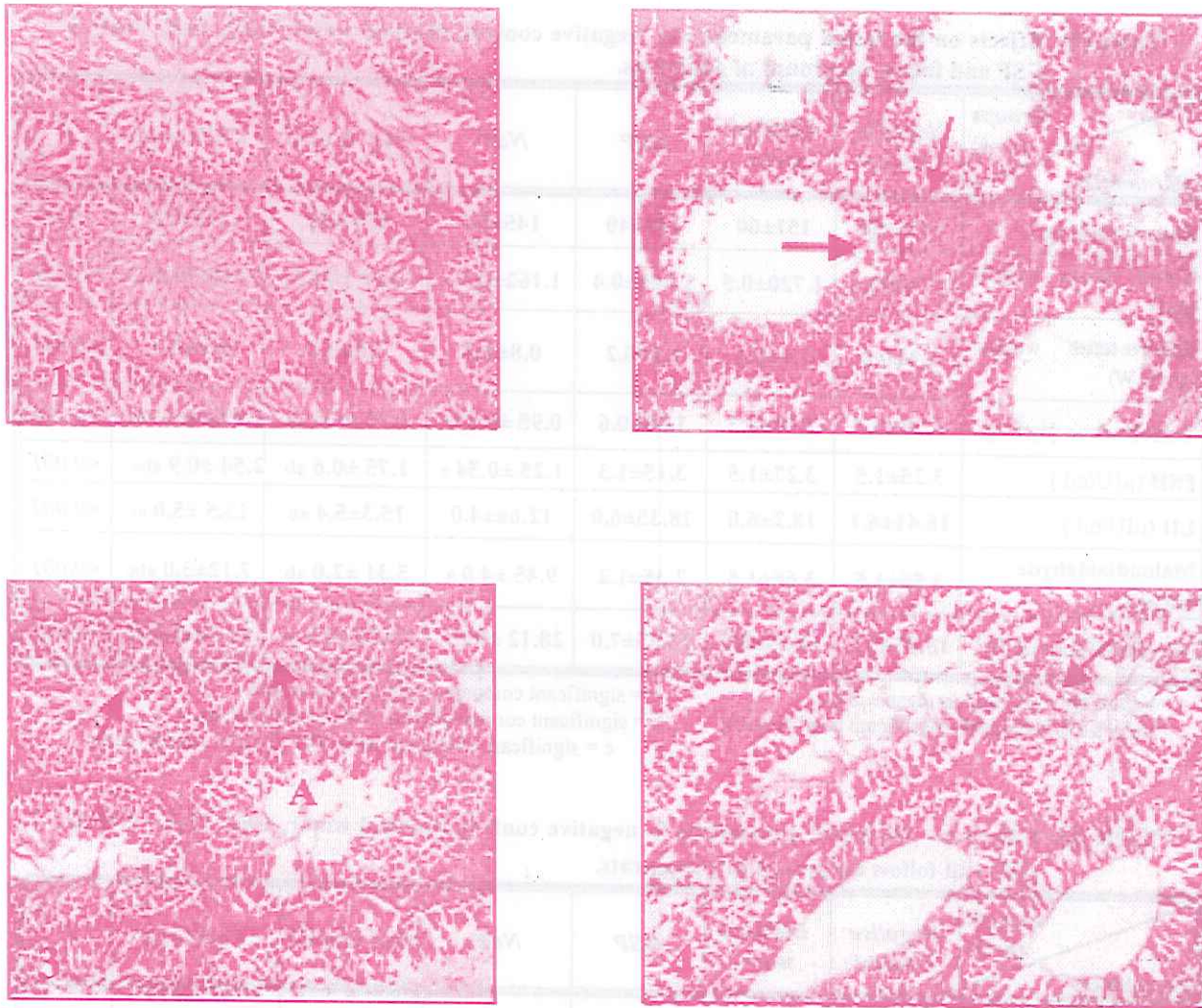
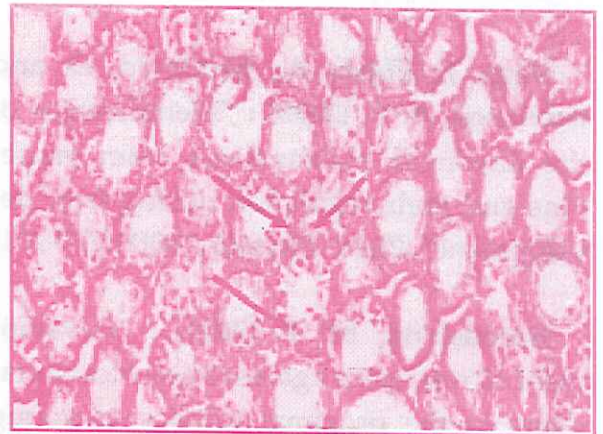
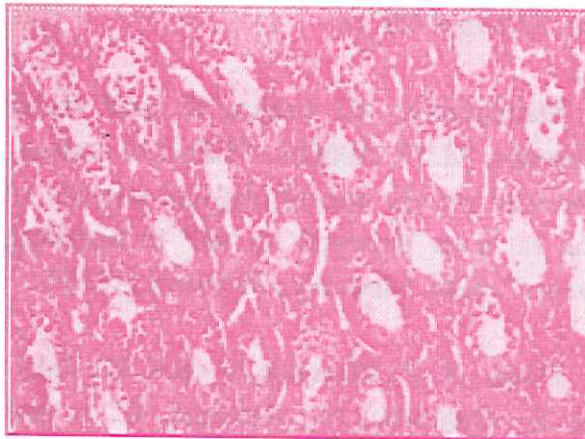
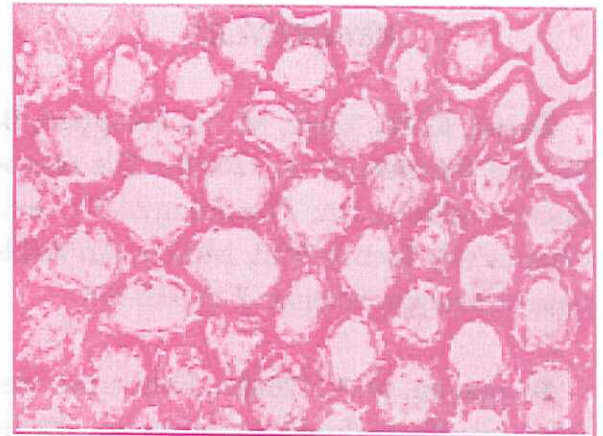
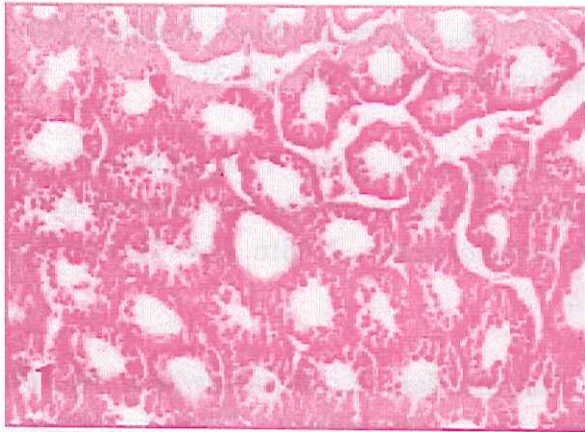

Plate (I) : Photomicrographs of sections of testes of adult rats showing :

- Fig. (1) : Normal seminiferous tubules with active spermatogenesis (control group).  
(H&E x200)
- Fig. (2) : Arrest of spermatogenesis and seminiferous tubules lined with 1ry and 2ry spermatocytes only (→) with fibrous thickening of the wall of tubules ( F ) (NaF group). (H&E x200)
- Fig. (3) : Incomplete spermatogenic arrest, some tubules show active spermatogenesis (→) and others show arrest of spermatogenesis (A) (NaF&GSP group).  
(H&E x200)
- Fig. (4) : Arrest of spermatogenesis and one seminiferous tubules show few spermatozoa (→)( follow up group ). (H&E x200)





**Plate (2) :** Photomicrographs of sections of testes of young rats showing:

**Fig. (1):** Normal seminiferous tubules lined with sertoli cells and spermatogonia only, there is no Leydig cells and no active spermatogenesis (control group).

(H&E x200)

**Fig. (2):** Early atrophic changes of the seminiferous tubules (NaF group). (H&E x200)

**Fig. (3):** Nearly normal seminiferous tubules with slight distortion (NaF& GSP group).

(H&E x200)

**Fig. (4):** Atrophic changes of most of the seminiferous tubules few tubules are lined with sertoli cells only (→) ( follow up group ). (H&E x200)

## REFERENCES

- Berne, R. M.; Levy, M. N.; Koeppen, B. M. and Stanton, B. A. (2004) : The reproductive glands. In: Physiology. 5<sup>th</sup> ed., Chapter 46, Section VIII, Mosby, An Affiliate of Elsevier Science. P.P. 932-935.
- Bhagavan, N. V. (2002) : Endocrine metabolism. Reproductive system. In: Medical Biochemistry. 4<sup>th</sup> ed., chapter 34, Harcourt Academic Press., San Diego San Francisco and New York, P.P. 781-790.
- Bogs, J.; Ebadi, A.; McDavid, D. and Robinson, S. P. (2006) : "Identification of the flavonoid hydroxylases from grapevine and their regulation during fruit development". *Plant Physiol.*, 140(1):279-291.
- Borouhaki, M. T. (2003) : "Development of resistance against hexachlorobutadiene in the proximal tubules of young male rat". *Comp. Biochem. Physiol. C Toxicol. Pharmacol.*, 136(4):367-375.
- Budavari, S.; O'Neill, M. J.; Smith, A. and Heckelman, P. E. (2001) : Sodium fluoride. In: The Merck Index, An Encyclopedia of Chemicals, Drugs and Biologicals. 13<sup>th</sup> edition, Merck Research Laboratories Division of MERCK CO; INC. P.P.1540-1541.
- Chatterjea, M. N. and Shinde, R. (2002) : Text Book of Medical Biochemistry. 5<sup>th</sup> ed., Jaypee Brothers, Medical Publishers Ltd., New Delhi, P. 317.
- Cheng, S. Z.; Jing, Y. Y. and Li, C. C. (1984) : Three methods for determination of lipid peroxides. *J. Clin. Lab. Techn.*, 2:8-10.
- Dabrowska, E.; Balunowska, M. D. and Letko, R. (2006a) : "Histoenzymatic study of the liver and submandibular gland of rats exposed to sodium fluoride in drinking water". *Ann. Acad. Med. Stetin.*, 52 Suppl 1:9-15.
- Dabrowska, E.; Letko, R. and Balunowska, M. D. (2006b) : "Effect of sodium fluoride on the morphological picture of the rat liver exposed to NaF in drinking water". *Adv. Med. Sci.*, 51 Suppl 1:91-95.
- Datla, K. P.; Zbarsky, V.; Rai, D.; Parkar, S.; Osakabe, N.; Aruoma, O. I. and Dexter, D. T. (2007) : "Short-term supplementation with plant extracts rich in flavonoids protect nigrostriatal dopaminergic neurons in a rat model of Parkinson's disease". *J. Am. Coll. Nutr.*, 26(4):341-349.
- Devi, A.; Jolitha, A. B. and Ishii, N. (2006) : "Grape seed proanthocyanidin extract (GSPE) and antioxidant defense in the brain of adult rats". *Med. Sci. Monit.*, 12(4):124-129.
- El-Ashmawy, I. M.; Saleh, A. and

**Salama, O. M. (2007) :** "Effects of marjoram volatile oil and grape seed extract on ethanol toxicity in male rats". *Basic Clin. Pharmacol. Toxicol.*,101(5):320-7.

**Gavriliuk, L. A.; Stepko, E. A.; Spinei, Iu. G.; Vartchan, A. I. and Lysyi, L. T. (2007) :** "Impact of antioxidative therapy on the activity of salivary glutathione-dependent enzymes in patients with fluorosis". *Klin. Lab. Daign.*, 22(1): 35-37.

**Ghosh, D.; Das Sarkar, S.; Maiti, R.; Jana, D. and Das, U. B. (2002) :** "Testicular toxicity in sodium fluoride treated rats: association with oxidative stress". *Reprod. Toxicol.* ,16(4):385-390.

**Guan, Z. Z.; Wang, Y. N.; Xiao, K. Q.; Dai, D. Y.; Chen, Y. H.; Liu, J. L.; Sinderlar, P. and Dallner, G. (1998) :** "Influence of chronic fluorosis on membrane lipids in rat brain. *Neurotoxicol". Teratol.*, 20 : 537-542.

**Guney, M.; Oral, B.; Demirin, H.; Karahan, N.; Mungan, T. and Delibas, N. (2007) :** "Protective effects of vitamins C and E against endometrial damage and oxidative stress in fluoride intoxication". *Clin. Exp. Pharmacol. Physiol.*, 34 (5-6): 467-474.

**Guney, M.; Oral, B.; Take, G.; Giray, S. G. and Mungan, T. (2004) :** "Effect of fluoride intoxication on endometrial apoptosis

and lipid peroxidation in rats: Role of vitamins E and C". *Toxicology*, 204 (2-3):219-228.

**Guo, X. Y.; Sun, G. F. and Sun, Y. C. (2003) :** "Oxidative stress from fluoride-induced hepatotoxicity in rats". *Fluoride*, 36 (1) : 25-9.

**Horobin, R. W. and Bancroft, J. D. (1998) :** Hematoxylin and Eosin as an oversight stain In: *Trouble Shooting Histology Stains*. 1<sup>st</sup> ed., Chapter (22), Churchill living stone, Pearson Professional Limited press, New York, London and Madrid, P. P.88 - 93.

**Hortova, K. D.; Sanddera, M.; Jursova, M.; Vasinova, J. and Peknicova, J. (2007) :** "The influence of fluorides on mouse sperm capacitation". *Animal Reproduction Science* ,7:15.

**Joshi, S.; Hasan, S. K.; Chandara, R. Husain, M. M. and Srivastava, R. C. (2004) :** "Scavenging action of zinc and green tea polyphenol on cisplatin and nickel induced nitric oxide generation and lipid peroxidation in rats". *Biomed. Environ. Sci.*, 17(4): 402-9.

**Kao, W. F.; Deng, J. F. and Chiang, S. C. (2004) :** "A simple, safe and efficient way to treat severe fluoride poisoning - oral calcium or magnesium". *J. Toxicol. Clin. Toxicol.*, 42(1):33-40.

- Kawase, T.; Oguro, A.; Orikasa, M. and Burns, D. M. (1996) : "Characteristics of NaF-induced differentiation of HL-60 cells". *J. Bone Miner. Res.*,11 (11):1676-87.
- Kim, H.; Deshane, J.; Barnes, S. and Meleth, S. (2006) : "Proteomics analysis of the actions of grape seed extract in rat brain: technological and biological implications for the study of the actions of psychoactive compounds". *Life Sci.*, 78 (18) : 2060-5.
- Krasowska, A.; Wlostowski, T. and Bonda, E. (2004) : "Zinc protection from fluoride-induced testicular injury in the bank vole (*Clethrionomys glareolus*)". *Toxicol. Lett.*,147(3):229-35.
- Kruger, K.; Binding, N.; Straub, H. and Musshoff, U. (2006) : "Effects of arsenite on long-term potentiation in hippocampal slices from young and adult rats". *Toxicol. Lett.*,165(2):167-73.
- Matsui, H.; Morimoto, M.; Horimoto, K. and Nishimura, Y. (2007): "Some characteristics of fluoride-induced cell death in rat thymocytes: cytotoxicity of sodium fluoride". *Toxicol. In Vitro.*,21(6):1113-20.
- Mayne, P. D. (1996) : Disorders of gonadal function in males. In: *Clinical Chemistry in Diagnosis and Treatment* sixth edition.; Ch.7, Arnold Co. London, Sydney and Auckland, P.P. 135 - 6.
- Mittal, M. and Flora, S. J. (2007) : "Vitamin E supplementation protects oxidative stress during arsenic and fluoride antagonism in male mice". *Drug Chem. Toxicol.*, 3 : 263-81.
- Nandakumar, V.; Singh, T. and Katiyar, S. K. (2008) : "Multi-targeted prevention and therapy of cancer by proanthocyanidins". *Cancer Lett.* [Epub ahead of print].
- Norusis, M. (1997) : *Statistical Package For Social Science (SPSS) base 8.0 for windows User's Guide*. Chicago, IL: SPSS.
- Oguro, A.; Kawase, T. and Orikasa, M. (2003) : "NaF induces early differentiation of murine bone marrow cells along the granulocytic pathway but not the monocytic or preosteoclastic pathway in vitro". *In Vitro Cell Dev. Biol. Anim.*, 39 (5-6):243-8.
- Reddy, P. S.; Pushpalatha, T. and Reddy, P. S. (2007) : "Suppression of male reproduction in rats after exposure to sodium fluoride during early stages of development". *Naturwissenschaften.*, 94 (7) : 607-11.
- Sarkar, S. D.; Maiti, R. and Ghosh, D. (2006) : "Management of fluoride induced testicular disorders by calcium and vitamin-E co-administration in the albino rat". *Reprod. Toxicol.*, 22(4):606-12.



- Sehirli, O.; Ozel, Y.; Dulundu, E.; Topaloglu, U.; Ercan, F. and Sener, G. (2008) : "Grape seed extract treatment reduces hepatic ischemia-reperfusion injury in rats". *Phytother. Res.*,22(1):43-48.
- Shailaja, K. and Johnson, M. E. (2007) : "Fluorides in ground water and its impact on health". *J. Environ. Biol.*, 28 (2):331-332.
- Shanthakumari, D.; Srinivasalu, S. and Subramanian, S. (2004) : "Effect of fluoride intoxication on lipid peroxidation and antioxidant status in experimental rats". *Toxicology*, 204.; 219-228.
- Shanthakumari, D.; Srinivasalu, S. and Subramanian, S. (2007) : "Effect of fluoride intoxication on the levels of intestinal antioxidants studied in rats". *Methods Find. Exp. Clin. Pharmacol.*,29(2):93-99.
- Shivarajashankara, Y. M. and Shivashankara, A. R. (2002) : "Brain lipid peroxidation and antioxidant systems of young rats in chronic fluoride intoxication". *Fluoride*, 35 (3): 197-203.
- Shivarajashankara, Y. M.; Shivashankara, A. R.; Gopalakrishna, B. P. and Rao, S. H. (2001) : "Oxidative stress in children with endemic skeletal fluorosis". *Fluoride*, 34 : 108-113.
- Shivarajashankara, Y. M.; Shivashankara, A. R.; Bhat, P. G. and Rao, S. H. (2003) : "Lipid peroxidation and antioxidant systems in the blood of young rats subjected to chronic fluoride toxicity". *Indian J. Exp. Biol.*,41(8):857-860.
- Sprando, R. L.; Collins, T. F.; Black, T.; Olejnik, N. and Rorie, J. (1998) : "Testing the potential of sodium fluoride to affect spermatogenesis : a morphometric study". *Food. Chem. Toxicol.*, 36 (12) : 1117-1124.
- Teitz, N. W. (1995) : *Clinical Guide to Laboratory Tests*. 3rd ed., Philadelphia, W.B. Saunders Co., P. 578.
- Torre, D.; Ferrario, G.; Speranza, F.; Orani, A.; Fiori, G. P. and Zeroli, C. (1996) : "Serum concentrations of nitrite in patients with HIV-1 infection". *J. Clin. Pathol.*, 19:574-576.
- Vani, M. L. and Reddy, K. P. (2000) : "Effects of fluoride accumulation on some enzymes of brain and gastrocnemius muscle of mice". *Fluoride*, 33 :17-27.
- Wang, Y. N.; Xiao, K. Q.; Liu, J. L.; Dallner, G. and Guan, Z. Z. (2000) : "Effect of long term fluoride exposure on lipid composition in rat liver". *Toxicology*, 146 : 161-169.

## إحتمالية الدور الوقائي لخلصة بذرة الجريب على سمية الفلوريد على الخصية فى الجرذان البيضاء البالغة والصغيرة

المشركون فى البحث

د. أمل محمد عبدالخالق

د. هنس الدهوداش إبراهيم

د. أمل فتحى غويب\*\*

د. سحر أبوالمجد أبوالمجد\*

من أقسام الطب الشرعى والسوموم الإكلينيكية، طب المجتمع والبيئة وطب الصناعات\* والكيمياء الحيوية الطبية\*\*

كلية الطب البشرى - جامعة الزقازيق

يعتبر الفلوريد من العناصر واسعة الانتشار فى الطبيعة ويتعرض عدد كبير من سكان العالم إلى نسبة عالية منه وتؤثر على مختلف أجهزة الجسم والعمليات الحيوية، استهدف هذا البحث دراسة التأثير السام لعنصر الفلوريد على الخصية وتقييم الدور الوقائى لخلصة بذور الجريب فى الحماية من هذا التأثير فى جرذان التجارب البيضاء البالغة والصغيرة.

اشتمل البحث على ٧٢ جرذ (٣٦ جرذ بالغ، ٣٦ جرذ صغير)، تم تقسيمهم إلى ٦ مجموعات متساوية، ١٢ جرذ فى كل مجموعة (٦ جرذان بالغة و٦ جرذان صغيرة) على النحو التالى :

- ١- المجموعة الأولى : مجموعة ضابطة سالية لم يتم حقنها بأى مادة لقياس المؤشرات الأساسية ويتم ذبحها بعد ٣٠ يوم من بداية التجربة.
  - ٢- المجموعة الثانية : مجموعة ضابطة إيجابية وتم حقنها بالماء المقطر عن طريق الفم يومياً لمدة ٣٠ يوم ثم تذبج .
  - ٣- المجموعة الثالثة : مجموعة تم حقنها لخلصة بذور الجريب ٧٥مجم/كجم مذاب فى الماء المقطر عن طريق الفم يومياً لمدة ٣٠ يوم ثم تذبج.
  - ٤- المجموعة الرابعة : مجموعة تم حقنها عنصر الفلوريد (١٨مجم/كجم من وزن الجسم) مذاب فى الماء المقطر عن طريق الفم يومياً لمدة ٣٠ يوم ثم تذبج.
  - ٥- المجموعة الخامسة : مجموعة تم حقنها عنصر الفلوريد (١٨مجم/كجم من وزن الجسم) مذاب فى الماء المقطر وخلصه بذور الجريب ٧٥مجم/كجم عن طريق الفم يومياً لمدة ٣٠ يوم ثم تذبج.
  - ٦- المجموعة السادسة : مجموعة تم حقنها عنصر الفلوريد (١٨مجم/كجم من وزن الجسم) مذاب فى الماء المقطر عن طريق الفم يومياً لمدة ٣٠ يوم ثم تترك بدون علاج لمدة ٣٠ يوم للمتابعة ثم تذبج.
- تم أخذ عينات الدم من الجرذان فى كل مجموعة عند نهاية المدة المقررة لإجراء الدراسة الكيميائية، كما تم وزن الجرذان ووزن الخصيتين لكل الجرذان وأخذ متوسط الوزن وتعيين الوزن النسبى مقارنة بوزن الجسم، كما تم إعداد الخصية لإجراء الدراسة الهستوباثولوجية بالميكروسكوب الضوئى.

وقد أوضحت الدراسة أن عنصر الفلوريد له تأثير سام بالغ على الخصية في الجرذان البالغة والصغيرة، ظهر بصورة واضحة في نقص ذو دلالة إحصائية معنوية في نسبة هرمونات التستوستيرون، (إف إس أتش) و(إل أتش) في الدم، وهذا التغيير في نسبة الهرمونات كان واضحاً في مجموعة الجرذان البالغة ولم يكن هناك تغيير في نسبة هذه الهرمونات في مجموعة الجرذان الصغيرة مقارنة بالمجموعات الضابطة، كما أظهر نقص ذو دلالة إحصائية معنوية في متوسط الوزن والوزن النسبي للخصيتين في الجرذان البالغة والصغيرة، وكانت التغيرات الهستوباثولوجية في نسيج الخصية في صورة توقف في مرحلة تكوين الحيوانات المنوية في الجرذان البالغة وأيضاً موت وضمور وتليف خلايا الخصية كان أكثر وضوحاً في مجموعة الجرذان الصغيرة أحدث زيادة ذات دلالة إحصائية في نسبة مالونداي الدهيد والنترات في مصصل الدم كمؤشر لتأثيره الخطر في أكسدة الدهون وزيادة شوارد الأكسجين الجامحة ونقص نشاط موانع الأكسدة، وأظهرت النتائج أن إعطاء خلاصة بذور الجريب مع مركب فلوريد الصوديوم قد أحدث تأثيراً وقائياً من التغيرات الناتجة عن التعرض لمركب فلوريد الصوديوم، وبالنسبة لمجموعة المتابعة فقد ظهر تحسن طفيف في التغيرات الناتجة عن التعرض لمركب فلوريد الصوديوم، وذلك في الجرذان الكبيرة والجرذان الصغيرة، من النتائج السابقة نستنتج أن عنصر الفلوريد له تأثير سام على نسيج الخصية في الجرذان البالغة والصغيرة وكان أكثر وضوحاً في مجموعة الجرذان الصغيرة، وإيقافه أدى إلى تحسن طفيف في نسبة الهرمونات في الجرذان الكبيرة ونسيج الخصية في الجرذان الكبيرة والصغيرة وأن إعطاء خلاصة بذور الجريب قد أظهر تأثيراً وقائياً ملحوظاً، لذلك ينصح بإعطاء مضادات الأكسدة للأطفال والكبار الذين يتعرضون لنسبة عالية من الفلوريد ومراقبة نسبة الفلوريد في المياه في المناطق المحتوية على نسبة عالية منه.

تاریخچه و پیشینه پژوهش در زمینه آموزش و یادگیری در محیط های دیجیتال، با توجه به تغییرات سریع در فناوری های دیجیتال و نیاز به به روز رسانی روش های تدریس و یادگیری، این پژوهش به بررسی روش های نوین آموزشی و تاثیر آنها بر یادگیری و انگیزه دانش آموزان می پردازد. در این راستا، روش های مبتنی بر فناوری های دیجیتال مانند یادگیری مجازی، یادگیری ترکیبی و یادگیری شخصی سازی شده، به عنوان روش های نوین آموزشی مورد بررسی قرار گرفته اند. همچنین، تاثیر این روش ها بر یادگیری و انگیزه دانش آموزان نیز مورد بررسی قرار گرفته است. در این پژوهش، از روش های آماری و کیفی برای جمع آوری و تحلیل داده ها استفاده شده است. نتایج این پژوهش نشان می دهد که روش های نوین آموزشی می توانند به بهبود یادگیری و انگیزه دانش آموزان منجر شوند. همچنین، استفاده از روش های نوین آموزشی می تواند به کاهش هزینه های آموزشی و افزایش دسترسی به آموزش منجر شود. این پژوهش می تواند به معلمان و مدیران آموزشی در تصمیم گیری های خود در زمینه روش های تدریس و یادگیری کمک کند.