

Delayed Massive Lower Gastrointestinal Bleeding Secondary to Suprapubic Cystostomy, A Case Report of Very Rare Complication

Bashaer Abdullh Al Jalal¹

College of Medicine, King Faisal University, Al Ahsa, Saudi Arabia

ABSTRACT

Introduction: Suprapubic cystostomy is a common procedure in urology.

Bowel perforation is the most serious and rare complication. This report highlights the first published case of massive lower gastrointestinal bleeding as a complication secondary to suprapubic cystostomy.

Case presentation: A sixty-seven-year-old patient with benign prostate hyperplasia had a suprapubic catheter inserted under spinal anesthesia, during concurrent cystoscopy. It was functioning well after insertion. Twelve days later, he developed massive hematochezia. On examination, he was hemodynamically stable. There was a demonstrable right lower abdominal tenderness and the digital rectal examination revealed dark red blood. The suprapubic cystostomy was draining clear urine without leakage. Investigations revealed a hemoglobin 6 g/dL and normal INR. Two units of packed red blood cells were given. A colonoscopy showed a normal colon with blood coming from above the ileocecal valve area. Upper endoscopy was normal. A red blood cell scan revealed active bleeding at the terminal ileum. A computerized tomography scan of the abdomen with IV contrast showed that the suprapubic catheter had passed into terminal ileum causing active bleeding. Exploratory laparotomy confirmed the presence of suprapubic catheter passing to the terminal ileum. The suprapubic catheter was removed, the unhealthy bowel resected, and anastomosis performed with no immediate post-operative complications.

Conclusion: This case determines the importance of keeping careful watch for possible bowel injury after cystostomy and should be considered a rare complication and cause of lower gastrointestinal bleeding.

Keywords: Suprapubic cystostomy; Lower gastrointestinal bleeding; Rare complication.

INTRODUCTION

Suprapubic cystostomy is a common procedure in urology. It is implied for acute urinary retention which is not treated with urethral catheterization and in the long-term management of bladder outflow obstruction and neuropathic bladders¹.

The suprapubic catheter can be placed either through a punch trocar or by using other safer techniques². Although the SPC is a safe procedure with known complications such as site infection, bleeding, catheter blockade, malpositioning, dislodgment, or bowel injury².

Bowel perforation is rare and the most serious complication with an incidence rate of 2.4 to 2.7%¹.

Terminal ileum perforation associated with lower gastrointestinal bleeding has not been reported.

We present a case of terminal ileum injury and delayed severe lower gastrointestinal bleeding following suprapubic cystostomy.

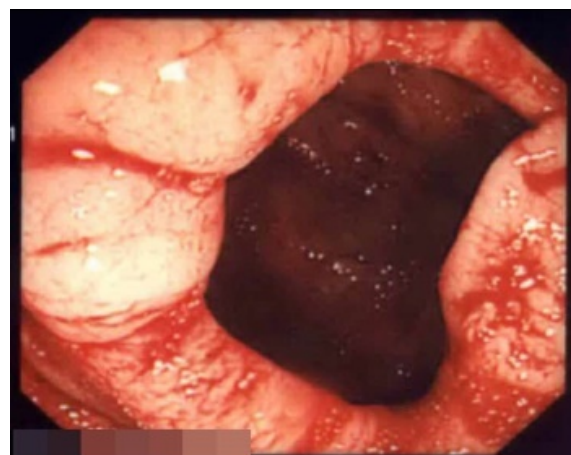CASE PRESENTATION

A sixty-seven-year-old patient with benign prostate hyperplasia had a suprapubic catheter inserted because of the failure of prostate stent. The percutaneous suprapubic catheter was inserted under spinal anesthesia, during concurrent cystoscopy; they did not note any intravesical pathology. The patient had no history of gastrointestinal or urological disease and had not undergone previous abdominal surgery. The suprapubic cystostomy was functioning well after

insertion. He was observed for one-day post-procedure and he was well.

Twelve days later, he developed massive hematochezia. On physical examination, the patient was afebrile, his heart rate was 102 per minute, and his blood pressure was 162/62 mmHg. There was a right lower abdominal tenderness but without guarding. The digital rectal examination showed dark red blood. The suprapubic cystostomy was draining clear urine without leakage. Investigations revealed a hemoglobin 6 g/dL (normal range 12-15.5 g/dL, it reduced from 8 g/dL four days previously) and a normal INR. Two units of fresh packed red blood cells were given.

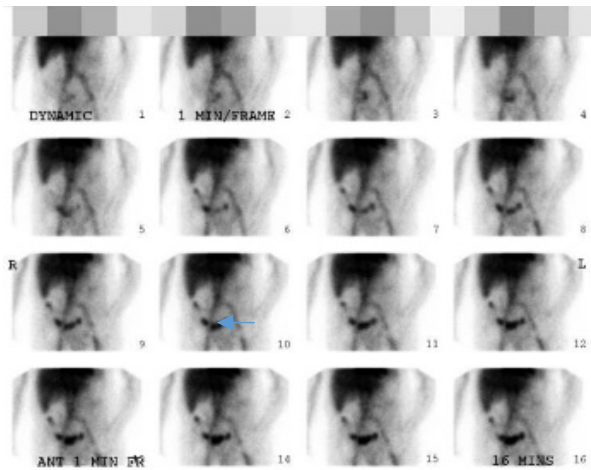
A colonoscopy showed normal colon with blood coming from above the ileocecal valve area.



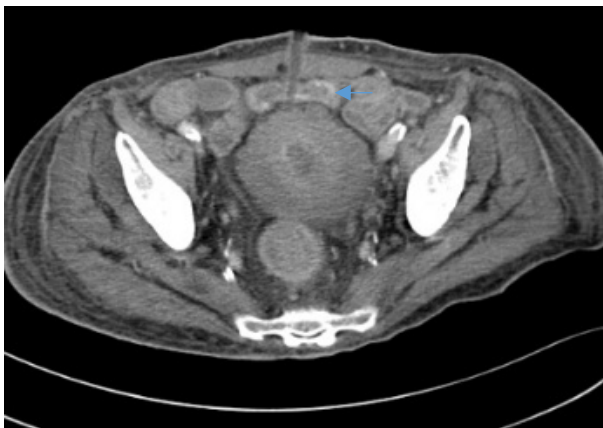
This article is an open access article distributed under the terms and conditions of the Creative Commons Attribution (CC BY-SA) license (<http://creativecommons.org/licenses/by/4.0/>)

Upper endoscopy was normal.

A red blood cell scan revealed active bleeding at the terminal ileum.



An abdomen computerized tomography scan with IV contrast revealed that the suprapubic catheter had passed into terminal ileum causing active bleeding in a short segment within its lumen.



Exploratory laparotomy confirmed the presence of suprapubic catheter passing to the terminal ileum. Proximal to the catheter, the small intestine looked healthy however at the catheter site and the terminal ileum was found full of blood till the ileocecal valve. The suprapubic catheter was removed, the unhealthy bowel resected, and anastomosis performed with no immediate post-operative complications.

DISCUSSION

Suprapubic cystostomy using a punch trocar, with localization of the bladder by palpation, the technique is usually safe when done in a well-distended bladder to a minimum of 300 ml of urine. There are safer techniques described for complicated cases, like using the Seldinger technique with a peel-away sheath introducer or image guidance using ultrasonography especially if there is a surgical

history of the lower abdomen, a non-palpable bladder, or obese to exclude bowel loops².

In our case, they used a punch trocar with minimal bladder distention and the catheter pierced of bowel contents en-route to the bladder during insertion, in effect 'sandwiching' viscera between abdominal wall and bladder and leading to bowel perforation and lower gastrointestinal bleeding presentation may attribute this occurrence to a high level of catheter insertion when the bowel may be present in the anterior of the bladder.

To the best of our knowledge, this exact mechanism of injury is not known before³⁻⁷.

CONCLUSION

This case demonstrates the importance of keeping a careful watch for possible bowel injury after cystostomy and should be considered as a rare complication and cause of lower gastrointestinal bleeding.

The risk of bowel damage and lower gastrointestinal bleeding can be reduced by warranting adequate bladder distension and the use of ultrasonography to exclude bowel loops along the anticipated catheter track during suprapubic catheter insertion.

ACKNOWLEDGMENTS

I would like to extend my sincerest thanks and appreciation to Dr. Ahmed Al Akwa senior researcher and consultant gastroenterology who helped me accomplish this case report.

REFERENCES

1. Ahluwalia RS, Johal N, Kouriefs C, Kooiman G, Montgomery BSI, and Plail RO *et al.* (2006): The surgical risk of suprapubic catheter insertion and long-term sequelae. *Ann R Coll Surg Engl.*, 88(2): 210-213
2. Harrison SC, Lawrence WT, Morley R, Pearce I, Taylor J (2011): British Association of Urological Surgeons' suprapubic catheter practice guidelines. *BJU Int.*, 107(1):77-85
3. Witham MD, Martindale AD (2002): Occult transfixation of the sigmoid colon by a suprapubic catheter. *Age Ageing*, 31:407-408
4. Ahmed SJ, Mehta A, Rimington P (2004): Delayed bowel perforation following suprapubic catheter insertion. *BMC Urol.*, 4:16
5. Wu CC, Su CT, Lin AC (2007): Terminal ileum perforation from a misplaced percutaneous suprapubic cystostomy. *European Journal of Emergency Medicine*, 14:92-93
6. Jackson BL, Leeder PC, Williams JH (2010): Delayed Presentation of Small Bowel Injury During Suprapubic Catheterisation. *JSCR.*, 2:2
7. Rajmohan R, Aguilar-Davidov B, Tokas T, Rassweiler J, Gözen AS (2013): Iatrogenic direct rectal injury: An unusual complication during suprapubic cystostomy (SPC) insertion and its laparoscopic management. *Archivio Italiano di Urologia e Andrologia*, 85:10-103