



Evaluation of Anchorage Loss during Canine Retraction Using Micro-Implant as Temporary Anchorage Device (A Split-Mouth Comparative study)

Nagwa A. Abou-Elmaaty ^{1*}, Samir A. Ibrahim ², Maha M. Mohamed ³

Codex : 58/20.07

azhardentj@azhar.edu.eg

http://adjg.journals.ekb.eg

DOI: 10.21608/adjg.2020.13240.1156

Pediatric Dentistry & Orthodontics
(Pediatric Dentistry, Orthodontics)

ABSTRACT

Purpose: Anchorage control is considered a keystone for successful orthodontic treatment so this study was to compare and measure the amount of anchorage loss during canine retraction by using micro-implant as a temporary anchorage device. **Material and methods:** A sample of 10 patients with an age range from 13 to 18 years, requiring extraction of first premolars was selected for this study. A randomized split-mouth study design was used. A nickel titanium closed-coil spring was used for canine retraction on micro-implants placed distal to the upper first permanent molar. In the right side upper first permanent molar was tied back to micro-implant using ligature wire. Amount of anchorage loss was measured by three dimension digital scanner. **Results:** there was non-significant anchorage loss when using micro-implant as a temporary anchorage device, and was no significantly different from right and left side. **Conclusion:** There was non-significant anchorage loss when using micro-implant, and the anchorage loss, molar and canine rotation, distance of canine distalization between the right side (tie back) side and the left side was insignificantly different.

INTRODUCTION

The term anchorage, in its orthodontic application, is defined in an unusual way: the definition as resistance to unwanted tooth movement includes a statement of what the dentist desires.

KEYWORDS

*Anchorage Loss, Micro-Implant,
Canine Retraction.*

- Paper extracted from Master thesis titled " Evaluation of Anchorage Loss during Canine Retraction Using Micro-Implant as Temporary Anchorage Device (A Split-Mouth Comparative study) ".

1. BDS 2012, Faculty of Oral and Dental Medicine. Al-Azhar University, Cairo, Egypt.

2. Professor of Orthodontics, Orthodontic department, Faculty of Dental Medicine for Girls, Al-Azhar University, Cairo, Egypt.

3. Lecturer of Orthodontics, Orthodontic department - Faculty of Dental Medicine for Girls, Al-Azhar University, Cairo, Egypt.

* Corresponding author email: nagwaahmed1990@gmail.com

The usage, though unusual, is clearest when presented this way. The dentist or orthodontist always constructs an appliance to produce certain desired tooth movements. For every (desired) action, there is an equal and opposite reaction. Inevitably, reaction force can move other teeth as well if the appliance contacts them. Anchorage, then is the resistance to reaction forces that is provided usually by other teeth, occasionally by the palate, sometimes by the head or neck (via extraoral force), and more and more often by anchors screwed to the jaws ⁽¹⁾.

In planning orthodontic therapy, it is simply not possible to consider only the teeth whose movement is desired. Reciprocal effects throughout the dental arch must be carefully analyzed, evaluated, and controlled. An important aspect of treatment is maximizing the tooth movement that is desired, while minimizing undesirable side effects ⁽¹⁾.

Anchorage is resistance against undesired tooth movement. In modern orthodontic, anchorage loss can be a significant complication during treatment, therefore, anchorage control is an important issue that needs to be addressed right from the leveling stage. Uncontrolled tipping is the easiest tooth movement to accomplish with orthodontic appliances, whereas tooth movement is the most difficult and complicated. The concept of anchorage preparation has been used for several years in the Tweed technique to reinforce anchorage through anchorage bends before anterior retraction. In those cases where in anchorage bends are not sufficient, the anchorage teeth must be actively reinforced with auxiliaries ⁽²⁾.

According to treatment plane anchorage classified to minimum, moderate or maximum. Maximum anchorage require when treatment objective need no anchorage loss. Anchorage loss is the reciprocal reaction of the anchor unit that can obstruct the success of orthodontic treatment by complicating anteroposterior correction ⁽³⁾. This anchorage reinforcement can be achieved in several ways .intra-

oral methods, increasing the number of teeth, Nance appliance, uprighting springs, sliding jig, cortical bone anchorage, transpalatal arch, lip bumper, extraoral appliance, cervical headgear, highpull headgear, temporary anchorage device ⁽²⁾.

The introduction of implants in dentistry was in 1969 led to possibility of developing anchorage system that could use during orthodontics and remain stationary because of implants osseointegration.

The first report regarding the use of implants in conjunction with orthodontic therapy was published in 1970 ⁽⁶⁾. It advocated of endosseous blade implants as space maintainers to avoid drifting of the teeth and as posterior anchorage in patients with posterior edentulous areas. He also reported the first clinical application of mandibular implants to support class II mechanics through class II elastics ⁽⁴⁾.

Orthodontists used bone screws as skeletal anchorage placed in the anterior nasal spine of the patients who need intrusion and torque control of the maxillary incisor. Kanomi⁷ described a micro-implant specifically designed to be used as direct anchorage for orthodontic purposes. Costa ⁸ introduced the first micro-implant that could be used as direct or indirect anchorage because it incorporated a bracket configuration in the design of its head ⁽⁵⁾.

Thus, the aim of present study was to measure and compare the amount of anchorage loss during canine retraction using micro-implant as a temporary anchorage device with and without tie back of the upper permanent first molar.

SUBJECT AND METHODS

Study population: This study was performed on 10 subjects with an age ranged from 13 to 18 years (average 15.5±1.7 years) the subjects were selected and treated at the out-patient clinic of the Orthodontic Department, Faculty of Dental Medicine for girls, Al-Azhar University Girls' Branch.

The criteria for subject selection were as following:

1. Patients in need to extract both maxillary first premolars.
2. Patients exhibiting Class II division I or with bi-maxillary protrusion.
3. Full retraction of the maxillary canines and maximum anchorage needed as a part of the orthodontic treatment plan.
4. All permanent teeth other than the third molars were present and fully erupted in both arches.
5. Patients should have good oral hygiene.
6. Medically compromised patients were excluded.
7. Patients under medical treatment that affect the rate of orthodontic tooth movement were excluded.

METHODS:

The aim and methods of the study was explained to the patient and consents were signed by all willing participants before being enrolled in the study.

The following records had been taken for each patient:

1. Extra-oral photographs.
2. Intra-oral photographs.
3. Orthodontic study model.
4. Panoramic Radiographs.
5. Lateral cephalometric Radiograph.

Extraction of the upper first premolars followed by placement of fixed orthodontic appliance.

1. Leveling and alignment.
 2. Micro-implant as anchorage units was placed distal to maxillary permanent first molar.
 3. The study was designed as a controlled clinical study that employed the split-mouth technique.
- 4. All subjects submitted in this study (after the end of study period); will complete routine orthodontic treatment.
 - Prior to the onset of the orthodontic treatment, patient were given instructions as oral hygiene instructions to ensure optimal meticulous plaque control and to maintain the good oral hygiene including the regular use of tooth brush.
 - Both the maxillary right and the left first premolars were extracted. A period of about 12-20 weeks was maintained after extraction (this period for leveling and alignment) before canine retraction was performed. This allowed alveolar bone consolidation at the extraction sites.
 - After the separation phase, molar bands with buccal tube (0.022"× 0.028") were selected for the right and left maxillary first molars.
 - In all patients, for the upper arches were fitted by an orthodontic appliance constructed with brackets (0.022"×0.028") slot.
 - Brackets were bonded with light cure composite cured by LEDlight curing unit from gingival and occlusal directions for optimum curing.
 - Micro-implant placed distal to the upper first permanent molar.
 - Upper permanent first molar will be tied back to micro-implant using ligature wire on one side only.(right side)
 - Two crimpable posts were inserted through the "0.016× 0.022" stainless steel arch wire between the canine and four anterior on both side.
 - NiTi coil spring were inserted between the screw and the crimpable posts for retraction in each side in both jaws. The brackets were bonded from the right second premolar to the left second premolar except the maxillary right and left first premolars which were extracted. Brackets ligated with elastomeric O-rings.

For leveling and alignment arch wires of 0.012 NiTi followed by 0.014 NiTi and 0.016 NiTi. Then arch wire of 0.016 and 0.018 stainless steel was used for completion of leveling and alignment.

Prior to the canine retraction phase, micro-implant inserted between the maxillary first molar and maxillary second molar on both sides under local anesthesia with screw driver.

On one side of the upper arch maxillary first molar was tie back to the head of the micro-implant by 0,009 ligature wire.

Measurement

* Cast scanning

The occlusal surface of the study cast of each patient was scanned⁽⁹⁾ by three dimension “open technologies” digital scanner and meagerments done “by maestro studio” program. The reference points⁽¹⁰⁾, (fig.1) which are the intersection of aho- rizontal and verticle line, were marked on the cast.

Reference points:

1. Most labial point on the upper central incisor.
2. The incisal papillae.
3. Mesial point of the canine.
4. The canine cusp tip.
5. Distal point of the canine.
6. The upper most point of the 3rd palatal rugae.
7. The midpoint of the line joining buccal and palatal cusp tips of upper 2nd premolar.
8. Tip of the mesiopalatal cusp of the upper first molar.
9. Tip of the disto buccal cusp of the upper first molar.

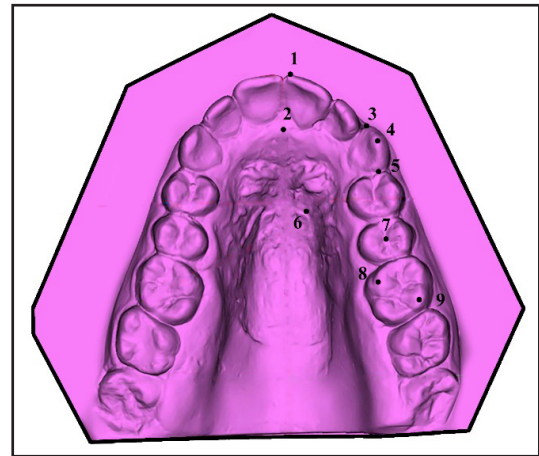


Figure (1): Cast scanning showing reference points

Reference Lines of the scanning cast: (fig.2)

1. Midline along the median palatine suture.
2. Line tangent to the most labial central incisors and perpendicular to the first reference line.
3. Line touching uppermost point of the 3rd palatal rugae and perpendicular to the first reference line.
4. Line tangent to the most distal point of the upper second molars and perpendicular to the first reference line.
5. First reference line: midline along the median palatine suture.
6. Second reference line: line tangent to the most labial central incisor and perpendicular to the first reference line.
7. Third reference line: line touching uppermost point of the 3rd palatal rugae and perpendicular to the first reference line.
8. Fourth reference line: line tangent to the most distal points of the upper second molars and perpendicular to the first reference line.

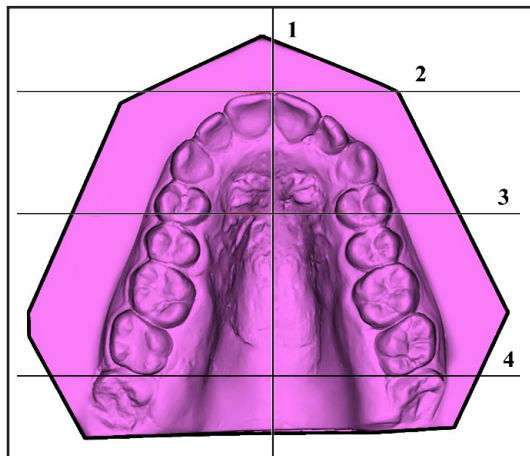


Figure (2): cast scanning showing reference lines

The amount of anchorage loss, rotation and amount of canine distalization was measured after complete canine retraction on the scanning cast.

The results were subjected to statistical analysis.

RESULTS

In the present study anchorage loss of the first permanent molar when measured from the mesio-buccal cusp to the 2nd reference line (line tangent to the most labial surface of the upper central) was 0,01mm in the right side and 0,09mm in the left side, and when measured from the mesiobuccal cusp of six to the 4th reference line (tangent to the most distal surface of upper seven) is 0.01 mm in the right side and 0.14 mm in the left side which no statistically significance. (Table 1,2)

Table (1) showing Distance from mesiobuccal cusp of upper six to 2nd reference line (line tangent to the most labial central incisors) between both sides pre and post.

	pre		Post		Anchorage loss	
	Right	Left	Right	Left	Right	Left
Mean	34.71	36.70	34.70	36.66	0.01	0.09
Std Dev	3.42	3.18	3.40	3.15	0.003	0.04
Min	29.40	32.20	29.40	32.20	0.00	0.00
Max	39.20	41.20	39.10	41.10	0.05	0.20
T	1.21		1.19		5.64	
P	0.248 NS		0.25 NS		<0.0001*	

Table (2) Comparison of distance from mesiobuccal cusp of upper six to 2nd reference line (Paired t test) between both side pre and post

	Right		Left	
	Pre	Post	Pre	Post
Mean	34.71	34.70	36.70	36.66
Std Dev	3.42	3.40	3.18	3.15
Min	29.40	29.40	32.20	32.20
Max	39.20	39.10	41.20	41.10
T	0.006		0.025	
P	0.99 NS		0.98 NS	

Significance level $p < 0.05$, *significant, ns=non-significant

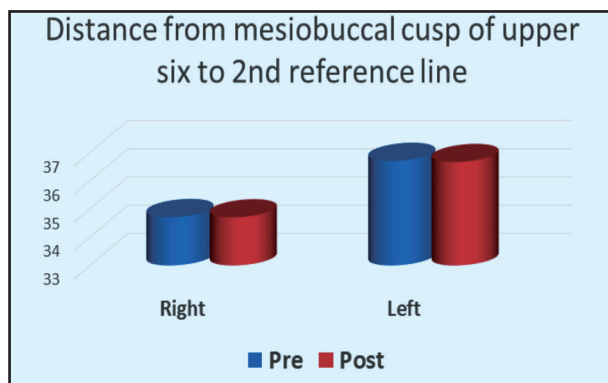


Figure (3): Bar chart showing distance from mesiobuccal cusp of upper six to 2nd reference line independent t test




Figure (4) : Bar chart showing distance from mesiobuccal cusp of upper six to 2nd reference line paired t test

DISCUSSION

In the current study right and left side canine retracted on the micro-implant by NiTi coil spring from the micro-implant to the power arm but in the right side the permanent first molar was tie back to the micro-implant by ligature wire. The anchorage loss reported in this study was found to be minimal.

In the present study anchorage loss of the first permanent molar when measured from the mesiobuccal cusp to the 2nd reference line (line tangent to the most labial surface of the upper central) is 0,01mm in the right side and 0,09mm in the left side, and when measured from the mesiobuccal cusp of six to the 4th reference line (tangent to the most distal surface of upper seven) is 0.01 mm in

the right side and 0.14 mm in the left side which no statistically significance.

While anchorage loss of the upper second premolar when measured from the midpoint of upper five to the 2nd reference line (line tangent to the upper most labial surface of two central) was 0.08 mm in the right side and 0.16 mm in the left side, and when measured from midpoint of upper five to the 3rd reference line (line tangent to the upper most point of the 3rd rugosa) was 0.03 mm in the right side and 0.05 mm in the left side.

These results were in accordance by a studies (11,12). The former authors stated that 73% of the first molars did not move mesially whereas 27% moved less than 0.5%. They attributed this minimal amount of anchorage loss to the fact that the canine were rapidly retracted while the molars were still in the lag phase of the tooth movement. The lag phase was the second phase of the tooth movement where in tooth movement stopped until the hyalinization areas were removed by undermining resorption and typically lasted for two to three week. The minimal anchorage loss in present study agree with another study (13,14)

The findings were also in accordance with the studies that demonstrated the absence of the mesialization of upper first molar during mass retraction movement of the anterior upper teeth using micro-implant as anchorage (15-17).

The most important finding of this study is that all loaded implants retained stability throughout the period of continuously applied orthodontic mesiodistal force. The same event yielded by a study (18) who made trials in which force was applied for a maximum of 16 weeks. In this study, the diameter of titanium micro-implants was 1,6 mm which considered as the larger diameter can be used in this place that provide good stability because the retention of micro-implant depend mainly on thickness more than length, this comes in agreement with a studies. (19,20)

Orthodontists⁽²¹⁾ have shown that as much as 5%–55% of the total extraction space can be taken up by an anchor unit made up of the first molar and second bicuspid when used for the retraction of a cuspid tooth. Various animal and human studies have shown that immediate loading of orthodontic micro-implants does not affect osseointegration and anchorage potential.^(22,23)

In report⁽²⁴⁾ found that the bone deposition rate was higher in the immediately loaded group than in the unloaded group.

A noted report⁽²⁵⁾ in 2003 considerably fewer failures when the implants are placed in the areas of attached gingiva rather than movable soft tissue. The best sites for micro-implant placement for retraction are the interdental spaces between the second premolars and first molars.

Relatively few studies have measured the amount of anchorage loss and the rate of canine retraction during canine retraction in humans.

The results of our study matched the results of another human study^(14,24) that concluded that micro-implants are efficient for intraoral anchorage reinforcement for en masse retraction and intrusion of the maxillary anterior teeth. The results agree with another study⁽²⁷⁾.

CONCLUSIONS

From the results the present study, the following conclusions could have been extracted :

1. The micro-implant placed between the upper first molar and second molar proved to be efficient for intra oral anchorage during canine retraction.
2. There was no significant anchorage loss when using micro-implant as temporary anchorage device.
3. The anchorage loss between the right side (tie back) side and the left side was significantly different.
4. When tie back the upper first permanent molar to micro-implant the molar rotation was significantly decreased.
5. The canine rotation between the right (tie back) side and the left side was insignificantly different.
6. The distance of canine retraction was greater in the right (tie back) side than the left side in the tasted time.

REFERENCES

1. Proffit WR. Contemporary Orthodontics 5th ed, 2015.
2. Nanda,RamS. Biomechanics in Orthodontics Principle and Practice 2nd, 2015.
3. Geron S, Shpack N. Kandos S. Davidovitch M. Vardimon AD. Anchorage loss-a multifactorial response. Angle Orthod.2003; 73:730-7.
4. Branemark PI, Adell R, Breine U, et al. Intra-osseous anchorage of dental prostheses. 1. Experimental studies. Scand J Plast Reconstr Surg. 1969; 3:81-100.
5. Creekmore TD, Eklund MK. The possibility of skeletal anchorage. J Clin Orthod. 1983; 17:266-9.
6. Linkow LI. Implanto-orthodontics, J Clin Orthod. 1970; 4:685-90.
7. Kanomi R. Mini-implant for orthodontic anchorage, J Clin Orthod. 1997; 31:763-7.
8. Costa A, Raffaini M, Melsen B. Mini-cscrews as orthodontic anchorage: a preliminary report. Int J Adult Orthod Orthog Surg. 1998; 13:201-9.
9. Rabab A. Elhosiény. Evaluation of low intensity laser on the rate of orthodontic tooth movement. A thesis submitted to Faculty of Dental Medicine, Al-Azhar University (girl's branch). For partial fulfillment of master degree in orthodontics. 2017.
10. Essam M I. Orthodontic maxillary canine retraction after partial corticotomy of the buccal plate; Clinical and radiographic investigations. A thesis submitted to Faculty of Dental Medicine, Al-Azhar University. For partial fulfillment of master degree in orthodontics. 2008.
11. Liou J, Huang S. Rapid canine retraction through distraction of the periodontal ligament. Am J of orthod Dentofacial Orthop . 1998; 114:372-82.

12. Iseri H, Kisnisci R, Bzizi N, Tuz H. Rapid canine retraction and orthodontic treatment with dentoalveolar distraction osteogenesis. *Am J Orthod Dentofacial Orthop.* 2005; 127:533-41.
13. Thiruvengkatachari B, Pavithranand A, Rajasigamani K, Kyung HM. Comparison and measurement of the amount of anchorage loss of the molars with and without the use of implant anchorage during canine retraction. *Am J Orthod Dentofacial Orthop.* 2006; 129(4):551-54.
14. Thiruvengkatachari B, Ammayappan P, Kandaswamy - R. Comparison of rate of canine retraction with conventional molar anchorage and titanium implant anchorage. *Am J Orthod Dentofac Orthoped.* 2008; 134:30-35.
15. Chung KR. Severe bidentoalveolar protrusion treated with orthodontic micro-implant-dependent en-masse retraction. *Am J Orthod Dentofacial Orthop.* 2007; 132:105-15.
16. Proffit WR, Fields HW Jr. *Contemporary orthodontics.* 3rd ed. St. Louis, Mo: CV Mosby. 2000; 348.
17. Liou EJ. Do mini-screws remain stationary under orthodontic forces? *Am J Orthod Dentofac Orthop.* 2004; 126:42-47.
18. Southard TE, Buckley MJ, Spivey JD, Krizan KE, Casco JS. Intrusion anchorage potential of teeth versus rigid endosseous implants: a clinical and radiographic evaluation. *Am J Orthod Dentofacial Orthop.* 1995; 107:115-20.
19. Echarri P, Kim TW, Favero L, Kim HJ. *Orthodontics and micro-implant complete technique, step by step.* 1st edition, ripano editorial medica, Printed in Spain by Linegrafic SA. 2007; 23-34, 55-7, 61-9.
20. Garfinkle JS, Cunningham LL, Beeman CS, Kluemper GT, Hicks EP, Kim MO. Evaluation of orthodontic mini-implant anchorage in premolar extraction therapy in adolescents. *Am J Orthod Dentofac Orthoped.* 2008; 133: 642-53.
21. Storey E, Smith R. Force in orthodontics and its relation to tooth movement. *Aust J Dent.* 1952; 56:11-8.
22. Chen Y. Clinical and histologic analysis of the stability of micro-implants with immediate orthodontic loading in dogs. *Am J Orthod Dentofacial Orthop.* 2009; 136:260-7.
23. Lisiane. Long-term follow-up of dental single implants under immediate orthodontic load. *Angle Orthod.* 2010; 80:807-11.
24. Serra G. Sequential bone healing of immediately loaded mini-implants: histomorphometric and fluorescence analysis. *Am J Orthod Dentofacial Orthop.* 2010; 137:80-90.
25. Park K. Development of orthodontic micro-implants for intraoral anchorage. *J Clin Orthod.* 2003; 321-8.
26. Davis D, Krishnaraj R. comparison of Rate of Canine Retraction and Anchorage Potential between Mini-implant and Conventional Molar Anchorage: An In vivo Study. *Contemp Clin Dent.* 2018; 9:337-42.