

Liposuction Assisted Abdominoplasty (Re-visit)

Ahmed Zaki Elbhery^{1,*} MB Bch, Ahmed Taha Sayed¹ MD and Abd-Elmonem Hota MD***Corresponding Author:**Ahmed Zaki Elbhery
az075876@gmail.com

Received for publication, April 29, 2020; Accepted, July 4, 2020; published online, July 4, 2020.

Copyright 2020 The Authors published by Al-Azhar University, Faculty of Medicine, Cairo, Egypt. All rights reserved. This an open-access article distributed under the legal terms, where it is permissible to download and share the work provided it is properly cited. The work cannot be changed in anyway or used commercially.

doi:[10.21608/aimj.2020.28808.1210](https://doi.org/10.21608/aimj.2020.28808.1210)

¹Department of Plastic & Reconstructive and Burn surgery, Faculty of Medicine, Al-Azhar University

Abstract

Background: Abdominoplasty is one of the principal common aesthetic operations. Many research articles have revealed that; Surgeon can combine both techniques adequately together (liposuction and abdominoplasty)

Objective: This study is to evaluate the abdominoplasty assisted with liposuction.

Patient and Methods: This study was done on 30 patients at Al-Azhar university hospitals. The patients were suffering from pendulous abdomen with fullness at love-handle and epigastric areas. Study implemented lipo-suction with three varieties of abdominoplasty techniques (extended, complete, and mini abdominoplasty)

Results: The use of liposuction in combination with abdominoplasty shows marked improvement in postoperative results including belly rejuvenation, better contour, less extended scars, patient satisfaction and surgeon satisfaction.

Conclusion: Using abdominoplasty assisted liposuction techniques give better results regarding scar length and high patient satisfaction.

Keywords: Liposuction; Abdominoplasty; Combined procedures.

Disclosure: The authors have no financial interest to declare in relation to the content of this article. The Article Processing Charge was paid for by the authors.

Authorship: All authors have a substantial contribution to the article.

INTRODUCTION

Abdominoplasty became the most common aesthetic surgical procedure with development of safe anesthesia and fast recovery.

In 1980s illoze¹ introduced liposuction in addition to abdominoplasty in the same procedure this give more contour enhancement in the same procedure. Articles on combining liposuction and abdominoplasty have been published during the 1990's; but, the literature at that point became not generally supportive of this combination, advising warning.¹

In 2001, Saldanha et al.² defined lipoabdominoplasty technique much like Illouz's Suction Abdominoplasty.

Liposuction assisted abdominoplasty became first executed in October 1996 by means of detaching an belly flap from the deep fascia with liposuction.²

Abdomioplasty procedure has developed for all patients and asking for contouring and reshaping of this body areas.³

Surgical abdominoplasty is also insufficient within the obese affected person because the thickness of the belly panniculus which isn't always reduced; in addition, secondary to tissue tension with wound closure, a few necrosis of pores and skin above the pubis are n't uncommon.⁴

The introduction of liposuction strategies has allowed surgeons to limit scar duration in positive applicants, remodeling abdominoplasty right into a minimally invasive manner.⁵

Using liposuction in addition with abdominoplasty has been controversial. The combination of techniques has been related to increased incidence of venous thromboembolism and wound-recovery complications. With using of thromboembolism prophylaxis, the risk of thromboembolism was decreased and so on increased rate of liposuction assisted abdominoplasty.⁶

So in this study Re-visit for the use of liposuction assisted abdominoplasty and monitoring its results.

PATIENT AND METHODS

This a prospective study case series that included 30 patients. They have been passed through assisted liposuction abdominoplasty.

All patients indicated for this technique were chosen from the plastic surgical treatment outpatient clinic. They all were having; belly lipodystrophy, skin redundancy, and musculoaponeurotic divarication.

The patients classified according to Mattarasso classification to 3 groups; group (A) ten patients indicated to liposuction assisted extended abdominoplasty, group (B) ten patients indicated to liposuction assisted full abdominoplasty and group

(C) ten patients indicated to liposuction assisted mini abdominoplasty.

The study was performed in Al-Azhar university Hospitals (Al-Hussin and Sayed Galal) from October 2019 to April 2020.

The assessment included operative time, hospitals stay, general drain output, time of drain removal, aspirate volume, weight of excised tissue, scar length, complications, return to work, and patients' satisfaction.

All patients were signed a consent about the operation, anesthesia, viable complications, dangers, photographing, and inclusion in this study. All patients have belly deformities marked skin excess, lipodystrophy without or with muscle laxity (Matarasso type 2, 3 and 4). All Patients have BMI <35. There was no abdominoplasty patients with recent massive weight loss or lost weight with bariatric surgery and /or acute life-style

modifications. Heavy smoker patients and ex-smokers advised to stop smoking one month before operation. Patients with ongoing weight reduction, or refused to enroll in the study and patients with co-morbid health issues have been excluded.

Preoperative exam, planning and marking:

Full investigations, radiology including U/S, CBC, SGPT /CREAT, INR were done for each patient. The patients were examined for hernias or previous operation scars as subcostal cholecystectomy scar. Images are normally taken in 6 cardinal views.

We marked the incision line while patient standing; 7 cm above superior vulvar commissure. This mark is prolonged laterally, along skin crease while patient manually elevate her belly. The length and region of this proposed incision and liposuctions is then measured to make certain symmetry. (Figure 1,2).

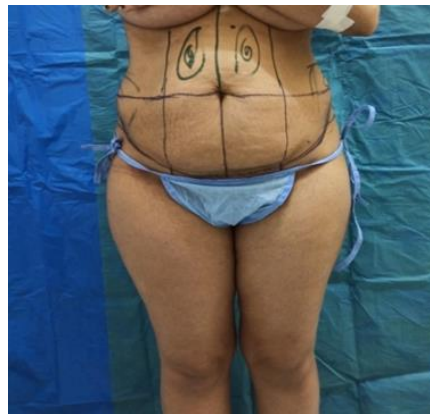

Fig. 1: Preoperative markings are made with the patient standing.

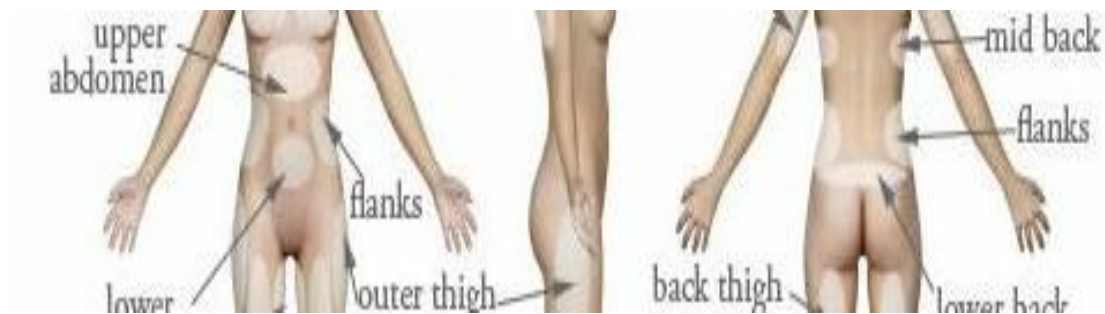

Fig. 2: All areas for liposuction are marked this includes; the entire central abdomen, flanks, and hip rolls.

Lateral part of the incision is marked and agreed by the patient then the proposed upper incision is identified and marked by pinch test.

Operative procedures:

The patient then lied in supine position, compression stockings then wrapped around both legs, sterilization, toweeling, anesthesia is

administered. Tumescent solution is infiltrated in the abdominal flap and liposuction areas (epigastric region, central abdomen, lateral abdomen, hip rolls and flanks). Tumescent consists of lidocaine 2% 10 cm and epinephrine solution (1/200,000). 1cm put on 500 ringers or saline. Surgeons infiltrate the

loose areolar tissue between abdominal wall and skin flap to make easier dissection with 3mm infiltration cannula till achieving tissue turgor. 20 minutes later the liposuction of deep plane started with 4 mm cannula, then final refining with 3mm cannula

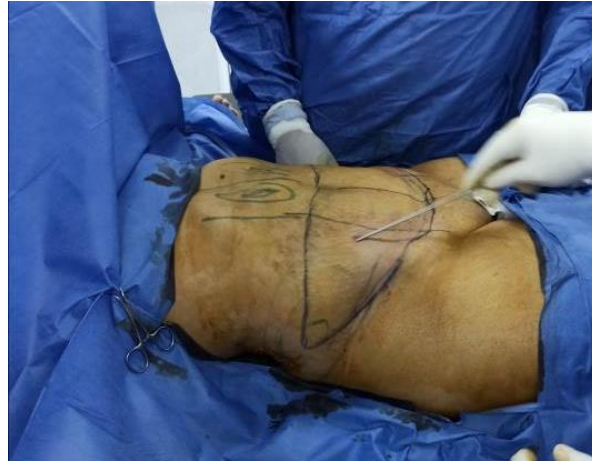

Fig. 3: Traditional liposuction with 4 mm diameter cannulas

Surgeon assesses the equality of flap thickness by pinch test. Liposuction begins in the central abdomen between the 2 outer borders of recti, we leave a thick flap (4cm) in the central abdomen and thinner flap (2cm) in the lateral abdomen and flanks to simulate the youthful abdomen. Additional cannula entry sites may be done in the excisional abdominal flap. Direction of cannula should be

infero-superior to preserve much perforators. Then the incision made with 15 blade, it is better to be located 2 centimeters below the marked line to overcome the later upward scar migration. I.V fluid is infused for compensation of liposuction aspirate and blood loss.

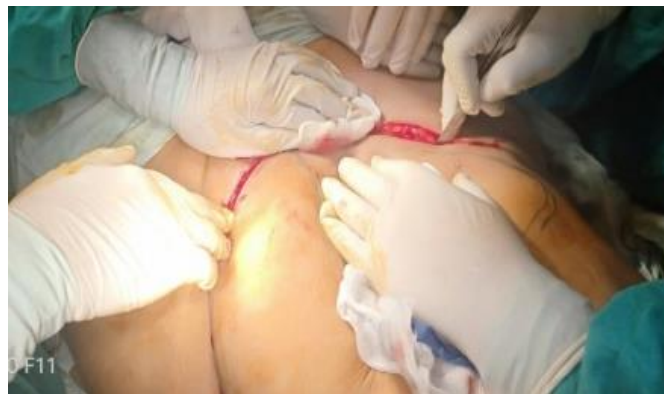

Fig. 4: Transverse incision of formerly marked is made with 15 blade

Diathermy is utilized to open the dermis and to coagulate the blood vessels. (Figure 5).

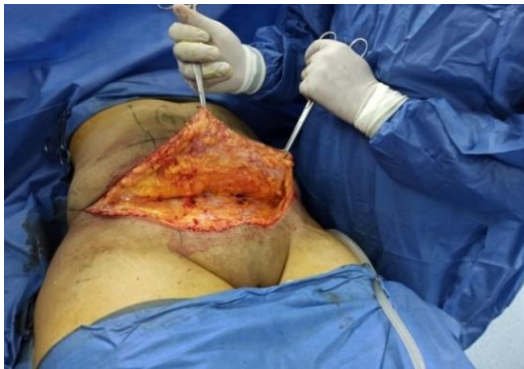

Fig. 5: bevel dissection through the fat of the skin flap

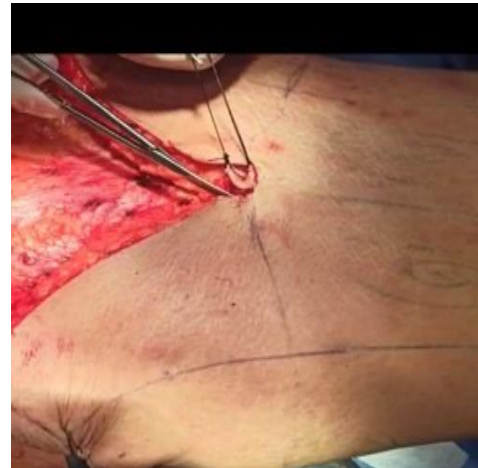

Fig. 6: umbilicus separation

Dissection beveled through the fat of the skin flap till reaching the rectus sheath at appoint midway between the umbilicus and the symphysis, this preserves more lymphatic's and decreases seroma formation . Meticulous homostasis should be done along the course of dissection. The Umbilicus then raised vertically with 11 blade and dissection scissors. The upper and lower poles of umbilicus are marked by threads, dissection is continued up to costal margins and xiphoid. Then we plicate rectus abdominis muscle sheath by marking its medial border by methylene blue. This defines the diastasis, plication is don from xiphoid process superiorly and symphysis inferiorly, and laterally from medial border of recti , plication is done by zero or 1 nilon looped suture, in one or two layers according to situation, At the level of the pubic symphysis, the knot tied and buried. Now it is time for flap resection, the patient is put in semi setting position by tilting operation table. The table is tilted in forty five degrees to release tension off of the wound closure and allow excision of maximum skin excess (Figure 8).

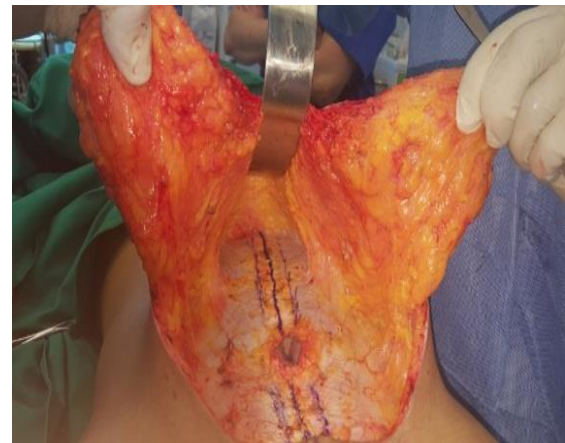

Fig. 7 Wide rectus abdominal muscle placcation

It is forbidden to detach the the flap beyond costal margin to preserve its vascularity, but gentle cannula dissection is allowed to get more flap mobility and eliminate tissue ridge without affecting blood supply. This keeps the fibrous septa which contain vascular perforators. then we simulates linea alba of the youthful abdomen by traction sutures with Vicryl 2/0 in the midline. (Figure 9)

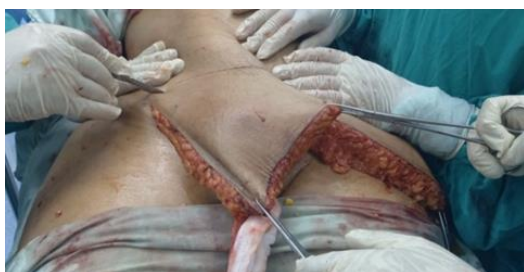

Fig. 8: Towel clips are placed at the tips of the flaps to apply gentle suture before flap excision

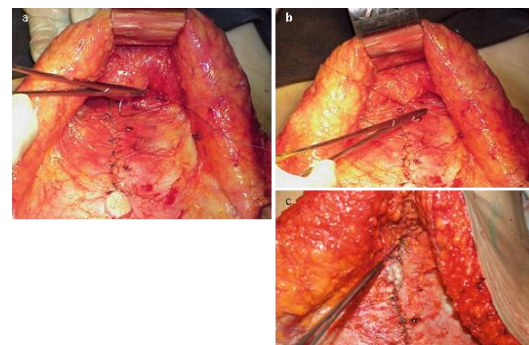


Fig. 9: shows Supra-umbilical central portion adhesion sutures

this makes amidline deprssion like an athletic abdomen (linea alba). We apply gentle traction on the flaps by towel clips, mark the excision mark while counter pushing of the inferior edge, assess symmetry between both excision marks, then cutting. (Figure 8)

The new umbilicus is placed at the position midway between symphysis and xiphoid, thin pulling the umbilical stalk and suturing it.

Then we final revision of hemostasis before stay sutures to distribute tension. 2 drains put laterally then is skin closed by suturing of scarpa's fascia, which is important layer and must be closed under maximum tension to relieve the overlying layers, it is closed with 0 vicryl suture. Upper flap is advanced medially to eliminate any dog ears then deep dermal 2/0 vicryl sutures is put before final sub cuticular 4/0 prolene sutures. Then we dress the wound and dress the pressure bandage.

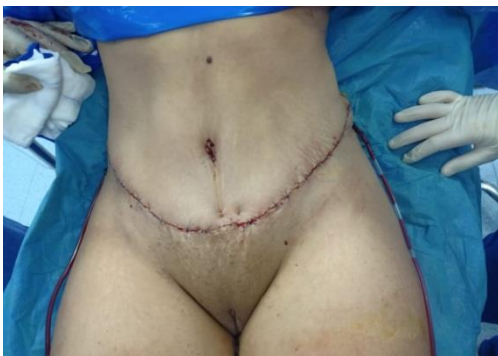

Fig. 10: Immediate post-operative

RESULTS

Patients are classified to 3 groups according to Mattarasso classification, each of 10 patients; 1st group did extended abdominoplasty, 2nd did full abdominoplasty and 3rd did mini-abdominoplasty. All with liposuction, we evaluated resultant contour, aspirate volume, excised tissue weight, drain output, drain removal, hospital stay complications and patient satisfaction in each group.

Group A

The weight of excised skin and subcutaneous fat in the 10 cases under group (A) ranged from 2500 to 4000gm. with a mean of 3.070 kg. Operative time was ranged from 3.5 to 5 hours with a mean of 4 hours. The volume of Aspirate in 10 cases ranged from 3000 to 4000 cm with mean of 3.6 liters each case. The total drain output in the 10 cases under group (A) ranged from 600 to 1500 ml. with a mean of 885 ml per case. The days needed for drains removal in the 10 cases under this group ranged from 3 to 7 days with a mean of 4.8 days per case. The days of hospital stays in the 10 cases under this group ranged from 2 to 7 days with a mean of 3.8 days per case. Bad patient satisfaction occurred in one patient showed recurrent protrusion of ant. Abdominal wall which needed revision.

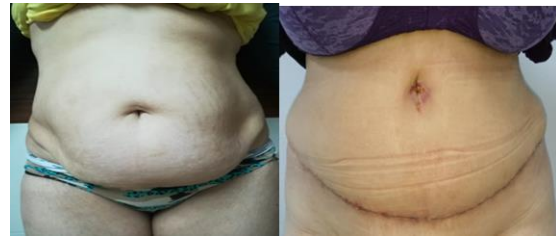

Fig. 11: Pre and post-operative view of liposuction assisted extended abdominoplasty

Group B

Operative time was ranged from 2.5 to 4 hours with a mean of 3.25 hours. The weight of excised skin and subcutaneous fat in the 10 cases under group (b) ranged from 2000 to 3000g, with a mean of 2.37kg. The total aspirate volume in group B ranged from 3000 to 4000 ml, the mean was 3.65. The total drains output in the 10 cases under group (B) ranged from 3000 to 4000ml. with a mean of 676.5 per case. The total days needed for drain removal in the 10 cases under this group ranged from 2 to 3 days with a mean of 2.9 days per case. The total days of hospital stays in the 10 cases under ranged from 2 to 3 days with a mean of 2.9 days per case. Fair patient satisfaction was achieved in single case (5%) due to asymmetric scar along the incision line. Others are fully satisfied.

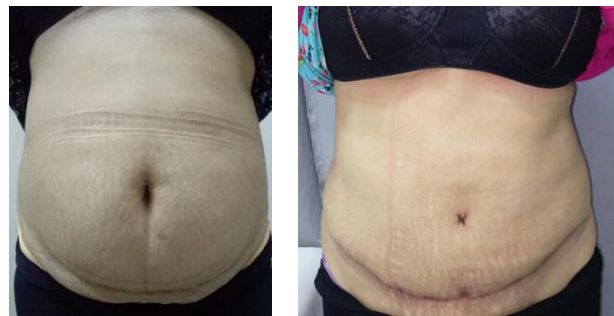

Fig. 12: Pre and post-operative view of liposuction assisted full abdominoplasty

Group C

Operative time was ranged from 2 to 3 hours with a mean of 2.6 hours. The weight of excised skin and subcutaneous fat in the 10 cases under group (C) ranged from 950 to 1300 kg. With a mean of 1.24 kg. The aspirate volume ranged from 2500 to 3500 ml, the mean volume was 2.8l per case. The drain output in the 10 cases under group (C) ranged from 250 to 500 ml. with a mean of 445 ml per case. The days needed for drains removal in the 10 cases under this group ranged from 2 to 3 days with a mean of 2.5 days per case. The days of hospital stays in the 10 cases under this group ranged from 1 to 2 days with a mean of 1.7 days per case.

Complications

In group (A) there is wound dehiscence and recurrent protrusion of the ant. Abdominal wall, in group (B) there is minimal dehiscence in one case and scar asymmetry in another case, in group (C) there is a case of dog ear. The reduced incidence of epithelializes to 0 percent, seroma to 0percent, and necrosis to 0 percent dehiscence 1.1percent, has statistical significance. Because the previous known

worldwide percent with traditional abdominoplasty alone was 50, 3.8, 5.1 for seroms, epithiliolysis and dihescence respectively as published by saldanha2007 Although the incidence of hematoma was reduced to 0 compared to 0.6 percent and the incidence of deep venous thrombosis/pulmonary (0 percent compared to 0.2), we cannot consider these findings as statistically significant due to the small number of cases.

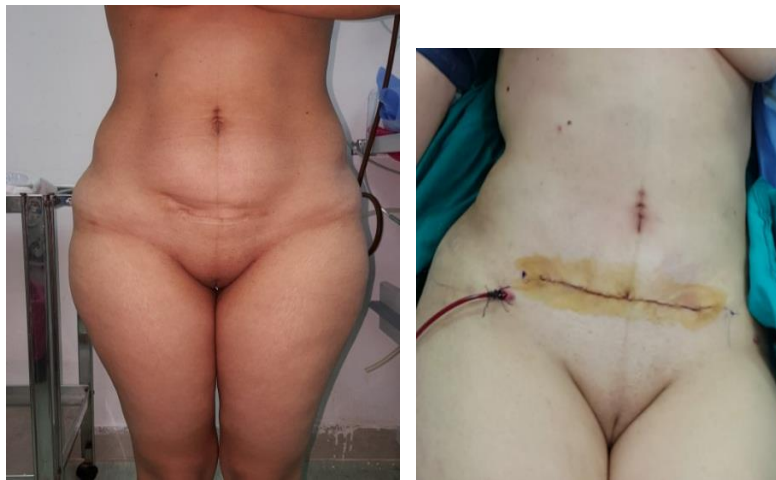

Figure (13) pre and post-operative view of liposuction assisted mini-abdominoplasty

N	Total drains output volume	Time to drains removal	Hospital stays	Aspirate volume	Weight of excised tissue	HB 2 nd day postoperative	Complications		Patient satisfaction
							early	late	
1	600	3	3	3000	3500	7.5(2 units packed RBCs)	NIL	NIL	Excellent
2	650	3	4	3500	4000	11	NIL	Wound dehiscence	Fair
3	700	4	4	3000	3000	11	NIL	Recurrent protrusion	Good
4	810	5	3	4000	2800	11.6	NIL	NIL	Excellent
5	930	5	3	3500	2500	11.3	NIL	NIL	Excellent
6	1100	7	4	3500	2700	10.2	NIL	NIL	Excellent
7	1050	4	3	4000	3200	11.4	NIL	NIL	Excellent
8	1150	5	5	3500	2100	11.5	NIL	NIL	Excellent
9	1500	7	7	4000	2900	11	NIL	NIL	Excellent
10	1250	5	5	4000	3800	12	NIL	NIL	Excellent

Table 1: Summary of postoperative results in group A

N	Drain output volume 400-1000	Time to drain removal	Hospital stay	Weight of excised tissue 2000-3000	Aspirate volume 3000-4000	HB 2 nd day post-operative	Complications		Patient satisfaction
1	430	3	3	2600	3000	11.5	NIL	NIL	Excellent
2	400	2	2	3000	3500	11.6	NIL	NIL	Excellent
3	490	3	3	2000	3000	11.7	NIL	NIL	Excellent
4	600	3	3	2300	4000	11.6	NIL	Scar assymetry	Good
5	1000	3	3	2200	3500	11.3	NIL	NIL	Excellent
6	750	3	3	2500	3000	12.2	Minimal dehiscence	NIL	good
7	620	3	3	2400	4000	11.3	NIL	NIL	Excellent
8	730	3	3	2300	4000	11.8	NIL	NIL	Excellent
9	820	3	3	2500	4000	10.3	NIL	NIL	Excellent
10	965	3	3	2200	4000	13	NIL	NIL	Excellent

Table 2: Summary of postoperative results in group B

N	Total drains output volume 250-500 mm	Time to drains removal 2-3 days	Hospital stays 2-3 days	Aspirate volume 2500-4000 mm	Weight of excised tissue 950-1300mm	HB 2 nd day post-operative 11.5-13 mm	Complications		Patient satisfaction
							early	late	
1	500	3	3	2500	1100	11.2	NIL	NIL	Excellent
2	400	3	3	3000	1300	11.6	NIL	Dog ears	fair
3	330	3	3	3000	1250	11.7	NIL	NIL	Excellent
4	250	2	2	3500	1270	11.6	NIL	NIL	Excellent
5	360	3	3	4000	1100	11.3	NIL	NIL	Excellent
6	400	3	3	2500	1050	10.2	NIL	NIL	Excellent
7	330	2	2	2500	1060	11.3	NIL	NIL	Excellent
8	340	2	2	3000	950	11.8	NIL	NIL	Excellent
9	290	2	2	4000	970	11.3	NIL	NIL	Excellent
10	310	2	2	4000	1030	12	NIL	NIL	Excellent

Table 3: Summary of postoperative results in group C

DISCUSSION

The Liposuction assisted abdominoplasty method is not only using liposuction with abdominoplasty, but it is wider concept including enhancing abdominal contour with least complications. Total results of liposuction assisted abdominoplasty obtained in this series were satisfactory, 90% of the patients showed excellent to good results, while 10% showed fair results and this is consistent with Daniel Brauman⁷ which noted that 92% are fully satisfying. As regard patient satisfaction 27 of the 30 pt. were fully satisfied and this is conductive with the study of Kim and Thomas⁸ with 87% of patients achieving satisfactory results. 2 of 3 unsatisfied patients became satisfied after revision. Hospital stay was maximum 1 week in group a, 3 days in group b and 2 days in group c, actually this is longer than prescribed methods but we needed this for strict follow up. As regard blood loss and needing for blood transfusion, only on case has needed, this consistent with Espinosa-de-los-monteros' study⁹ when there is no blood transfusion in his 55 cases study. In this series, the timing for return to work or resumption of everyday life activities achieved by 84% these patients were 3 weeks in group A and B ,2weeks in group C consistent with the study of Brauman 2018 where 89% of patients were able to resume working 3 weeks post-operative. We observed a decrease in the final scar extension when compared with the initial marking in 10, 50, 50 percent of patients, in the mini, full, extended abdominoplasty respectively which is conducted with saldanha 2007¹⁰ which reported 2cm decrease in scar in 30% of cases. Only 2 patients needed revision (6.6 %) which is superior to Saldanha¹⁰ who reported 10% needing revision. As regard complications one of the patients developed seroma which was discovered clinically and confirmed by ultrasonography, it was managed intraoperative by aspiration after cannula dissection of fibrous septa and pressure garment and followed up later by second ultrasonography which was normal. And these results are consistent with the observations of Bromley¹¹ where 5% of patients experienced seroma. In this study we preferred vertical shape umbilicoplasty with good results, less complication and more natural appearing umbilicus. Same results obtained by Saldanha¹² regards a cross shape umbilicoplasty scar.

The resulting scar was problematic in 3 patients, one of them developed bilateral dog ears in group C which needed revision later, the second case was in group A and the scar was higher in position although it was pre-designed and marked in the crease. It may be better to place the incision 2 cm below the bikini line to overcome upward migration of the scar in some patients. The third case in group C there was hypertrophic scar which became better after using silicon sheet and pressure garment. In 27 patients there was accepted scar which is conducted to Sozer¹². There is one post bariatric patient showed recurrent ptosis in the abdomen which most probably was related to inadequate excision of the skin. Only one patient showed minimal wound dehiscence which improved by optimal wound care which is conductive with Whiteman.¹³ The mean operation time takes about 3.5 to 5 hours in group A, 2.5 to 4 in group b

and 2 to 3 in group c with slight increase with increasing BMI and vice versa. Which is coming with Bromley findings.¹¹ No patients showed flap necrosis or DVT. Study precautions as regard blood supply preservation, early ambulation and fluid resuscitation were sufficient. This agrees with kim⁸ observations. It is recommended that further studies would be conducted on a bigger number of cases, to allow assessing all possible techniques of liposuction assisted abdominoplasty and to allow the comparison of results of different modalities.

CONCLUSION

Liposuction assisted abdominoplasty is based totally on the selective undermining of the belly wall, resulting within the protection of blood supply, lymphatic vessels, and nerves. The traditional dissection become changed with cannula dissection, to keep the blood supply of abdominal wall perforators. This guarantees patient safety. The approach is based on sound surgical principals. The fundamental surgical operation of hydro and lipo-dissection of the abdominal flap continue as a verified method.

REFERENCES

1. Illouz YG. Body contouring by lipolysis: a 5-year experience with over 3000 cases. *Plast Reconstr Surg.* 1983; 72:591–597.
2. Saldanha OR, Pinto EB, Matos WN Jr, et al. Lipoabdominoplasty without undermining. *Aesthet Surg J.* 2001; 21:518–526.
3. Matarasso A. Abdominoplasty. *Aesthetic Plast Surg* 1989; 16:289–303. Back to cited text no. 1
4. Ramirez OM. Abdominoplasty and abdominal wall rehabilitation: a comprehensive approach. *Plast Reconstr Surg* 2000; 105:425–435. Back to cited text no. 2
5. Matarasso A, Matarasso SL. When does your liposuction patient require an abdominoplasty? *Dermatol Surg* 1997; 23:1151–1160. Back to cited text no. 3
6. Ousterhout DK. Combined suction-assisted lipectomy, surgical lipectomy, and surgical abdominoplasty. *Ann Plast Surg* 1990; 24:126–132; discussion 132–133. Back to cited text no. 5
7. Brauman Daniel. Liposuction abdominoplasty: An evolving concept. *Plastic and reconstructive surgery.* 2003; (112)1: 288-298.
8. Kim, James and Thomas R. Stevenson. "Abdominoplasty, liposuction of the flanks, and obesity: analyzing risk factors for seroma formation." *Plastic and reconstructive surgery.* 2006; (117) 3: 773-779.
9. Espinosa-de-los-Monteros, Antonio, et al. Abdominoplasty with total abdominal liposuction for patients with massive weight loss." *Aesthetic plastic surgery.* 2006; (30)1: 42-

10. Saldanha OR, De Souza Pinto EB, Mattos WN Jr, et al. Liposuction assisted abdominoplasty with selective and safe undermining. *Aesthetic Plast Sur.* 2007; 10: 322-327
11. Bromley, Miluska, Walter Marrou, and Luiz Charles-de-Sa. "Evaluation of the Number of Progressive Tension Sutures Needed to Prevent Seroma in Abdominoplasty with Drains: A Single-Blind, Prospective, Comparative, Randomized Clinical Trial." *Aesthetic plastic surgery.* 2018; 1600-1608.
12. Sozer, Sadri Ozan, Karaca Basaran, and Hasan Alim. "Abdominoplasty with circumferential liposuction: a review of 1000 consecutive cases." *Plastic and reconstructive surgery* 2018; (142) 4: 891-901.
13. Whiteman, David, and Gabriele C. Miotto. "Abdominoplasty with Scarpa's Fascia Advancement Flap to Enhance the Waistline." *Aesthetic Surgery Journal.* 2016; (36)7: 852-857.