

Efficacy and safety of Thulium Laser for Treatment of short segment bulbomembranous Urethral Stricture

Gamal Ibrahim Selmy, Ahmed Mohamed Elshal, Mohamed Ramadan Rehan and Mohamed Farid Ali Ebrahim

Urology Department, Faculty of Medicine, Al_Azhar University, Damietta, Egypt
Corresponding author: Mohamed Farid Ali Ebrahim, E-mail: kokmfa3@gmail.com, Tel: 00201004063660

ABSTRACT

Background: Evaluation of outcome of thulium laser urethrotomy for patients with urethral strictures as a minimally invasive treatment for urethral stricture. **Objective:** The purpose of this study was to evaluate Efficacy and safety of Thulium Laser for treatment of short segment bulbomembranous Urethral Stricture. **Patient and methods:** A prospective non controlled study conducted on twenty patients with urethral stricture selected from outpatient clinic of Al-Azhar-university hospital New Damietta in duration between June 2017 and July 2018. Evaluated by retrograde urethrography, uroflowmetry, International Prostate Symptom Score (IPSS), Sexual function assessment: International Index of Erectile Function (IIEF), Male Sexual Health Questionnaire (M.S.H.Q)] and quality of life preoperatively. All patients were treated with thulium laser urethrotomy. All patients were followed up for 6 months postoperatively by uroflowmetry and by retrograde urethrography after 6 months. And all patients were followed up by mailed questionnaire, including IPSS (International prostate symptom score), (IIEF), (M.S.H.Q) and quality of life. **Result:** Thulium laser urethrotomy was performed in all 20 cases. The mean operative time was 23.7 ± 4.5 minutes range (15–30 minutes). No intraoperative complications were encountered. Despite perioperative antibiotics, 15% of the patients developed urinary tract infection postoperatively that was managed with antibiotics according to urine culture sensitivity. Stricture treatment was successful in 17 patients (85%). three patient developed recurrent stricture treated with urethral dilation. In 17 patient the postoperative mean Qave (average urine flow) $> 12.3 \pm 3.6$ ml /second ($P < 0.05$) and adequate caliber urethra in retrograde urethrogram (RUG) 6 months after operation. Three patients (15%) showed narrow stream of urine (Qave) average urine flow < 8.0 ml/second) and performed urethral dilation 1 time every month for 4 months. The average postoperative Qmax (the maximum flow rate) was 21.7 ± 2.1 ml/second ($P < 0.05$) with insignificant PVR urine. The mean postoperative IPSS was 2.6 ± 1.2 ($P < 0.05$). **Conclusion:** We demonstrated that thulium laser endourethrotomy was a reliable and safe therapy with minimal invasive therapeutic modality for urethral strictures.

Keywords: urethral stricture; urethrotomy; laser surgery; thulium.

INTRODUCTION

Urethral stricture is one of the most difficult urological problems to cure adequately and is known to mankind since ages as it has been documented in ancient literature of the Hindus, Egyptians and Greeks^(1,2). Different techniques used for the treatment of urethral strictures, depending on the stricture length, location, and depth of scar, which include: simple dilatation, visual urethrotomy, uroLume stent placement urethroplasty, perineal urethrostomy and laser endourethrotomy^(3,4). The types of lasers that have been used for urethrotomy include: carbon dioxide, Nd: YAG, the KTP, the Argon, and the Ho: YAG and excimer laser^(4,5).

Thulium LASER is a continuous laser with a wave length of 2,013nm that achieves a shallow tissue penetration of less than 0.4 nm⁽⁶⁾. Compared to holmium there is less mechanical effect but a higher production of continuous heat⁽⁷⁾. The thulium laser has several theoretical advantages over the holmium laser such as rapid and efficient vaporization and coagulation as well as tissue incision⁽⁸⁾. Water absorption peak in the tissue at 1.92 mm, result in

sufficient hemostasis, a clear visual field, and fast tissue incision with little thermal damage⁽⁹⁾. Disadvantage of other type of laser. This laser energy is delivered most commonly in a pulsatile manner, using athermomechanical mechanism of action. It superheats water, which heavily absorbs light energy at this wavelength. This creates a vaporization bubble at the tip of a low-water density quartz or silica fiber used for delivery. This vapor bubble expands rapidly and destabilizes the molecules it contacts. This is ideal for lithotripsy of all stone types better than tissue⁽¹⁰⁾.

PATIENTS AND METHODS

There were 20 male patients with urethral stricture disease treated with thulium laser endourethrotomy at Al-Azhar university hospital, New Damietta in duration between June 2017 and July 2018. The average age of the patients was 45.2 ± 11.14 years (range 27–35 years). The average course of disease was 10 years (range 1 month–30 years). The diagnosis of urethral stricture was based on history of illness, symptom scores, uroflowmetry, and retrograde urethrography.

Uroflowmetry and postvoid residual urine volume (PVR) were determined both preoperatively and postoperatively, together with the International Prostate Symptom Score (IPSS), International Index of Erectile Function (IIEF), Male Sexual Health Questionnaire (M.S.H.Q) and Quality of Life Index (QoL). And retrograde urethrography were done after 6 months. We considered our procedure successful if the patient did not report any voiding difficulty, the maximum flow rate (Qmax) >15 ml/second with no or insignificant residual urine, and the IPSS was <12.

Surgical Technique

The operations were performed under spinal anesthesia and the antibiotic prophylaxis was given perioperatively. The patient was placed in a lithotomy position, and the stricture was examined using short ureteroscope. Introduction of safety guide wire. Using laser fiber (365 micron end firing fiber). laser setting: the power used will be 15-20 watts.

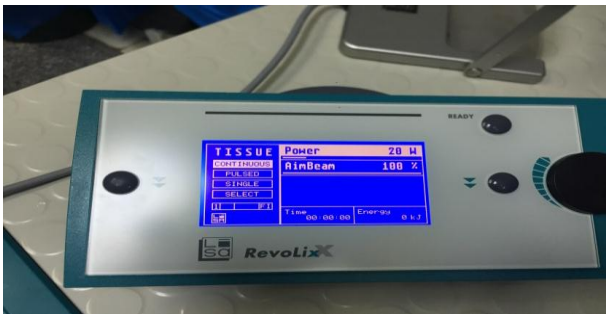

Fig (1): Al-Azhar university hospital thulium laser.

Stricture were incising dorsally with evaporation of scared tissue until adequate caliber of urethra were attained comparable to the proximal urethra then urethroscopy were done with using 22 french cystoscope to ensure patency of the urethra. insert of 16_20 french silicone catheter for 5 days. Intra operative complication including gross blood loss and extravasation of fluid from urethra. The mean operative time was 23.7±4.5 minutes range (15–30 minutes).

Ethical Issues

Informed consents were taken from all of the patients included in our study. The study was approved by the Ethics Board of Al-Azhar University.

RESULTS

Thulium laser urethrotomy was performed in all 20 cases. The mean operative time was 23.7±4.5 minutes range (15–30 minutes). No intraoperative complications were encountered. Despite perioperative antibiotics, 15% of the patients developed urinary tract infection postoperatively that was managed with antibiotics according to urine culture sensitivity.

The etiology of strictures was iatrogenic in 20%, inflammatory in 35%, traumatic in 30% (N¼45), and idiopathic in 15%. During the iatrogenic causes, there were two patients with indwelling catheter for a long time and two patients with history of transurethral operation. The length of stricture ranged from 1ml to 5ml. The site of the stricture was the bulbar urethra in 80%, the membranous urethra in 10%, and bulbomembranus 10%. The stricture was primary in 60% of the patients and recurrent in 40%. These 8 cases (20%) were recurrent having been treated by a cold-knife technique previously.

Stricture treatment was successful in 17 patients (85%). three patient developed recurrent stricture treated with urethral dilation. In 17 patient the mean Qmax (the maximum flow rate) preoperatively was 9.1±2.1 ml/second with a (PVR) postvoid residual urine volume of 60 (40-110) ml. The mean Qavarage preoperatively was 4.4±1.6 ml/second. The mean IPSS (International prostate symptom score) was 30.1±4.2. The mean IIEF 1(International Index of Erectile Function) preoperatively was 33.8±3.7. The mean IIEF 2 (International Index of Erectile Function) preoperatively was 21.5±4.9. The mean MSHQ (Male Sexual Health Questionnaire) preoperatively was 25.9±3.7. And the postoperative mean Qave(average urine flow) > 12.3±3.6ml /second (P <0.05) and adequate caliber urethra in retrograde urethrogram (RUG) 6 months after operation. Three patients (15%) showed narrow stream of urine Qave (average urine flow) <8.0 ml/second and performed urethral dilation 1 time every month for 4 months. The average postoperative Qmax (maximum urinary flow) was 21.7±2.1 ml/second (P <0.05) with insignificant PVRU(postvoiding resedual urine). The mean postoperative IPSS (International prostate symptom score) was 2.6±1.2 (P <0.05).

Table (1): Q max and Q average evaluation before and after operation.

Variable	Before	1m after	3m after	6m after	p
Qmax	9.1±2.1	16.5±1.9	18.7±1.3	21.7±2.1	<0.05
Q average	4.4±1.6	9.3±3.3	9.8±1.8	12.3±3.6	<0.05

Table (1) Show: significant improvement of Q max and Q average.

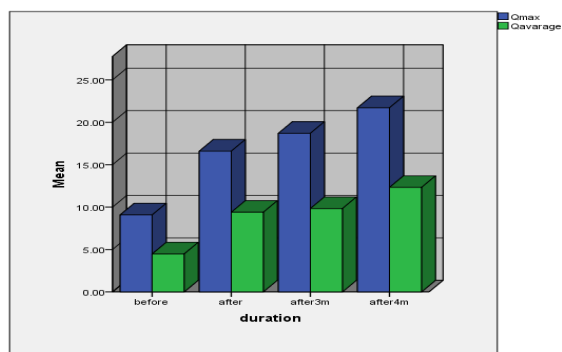


Figure (2): Bar chart for Q max and Q average before and after operation.

Table (2): IIEF1, IIEF2 and MSHQ before and after.

Variable	before	after	p
IIEF 1	33.8±3.7	38.4 ±1.4	<0.05
IIEF 2	21.5±4.9	32.2±5.6	<0.05
MSHQ	25.9±3.7	33.7±0.9	<0.05

Table (2) Show: Significant improvement in IIEF1, IIEF2 and MSHQ after.

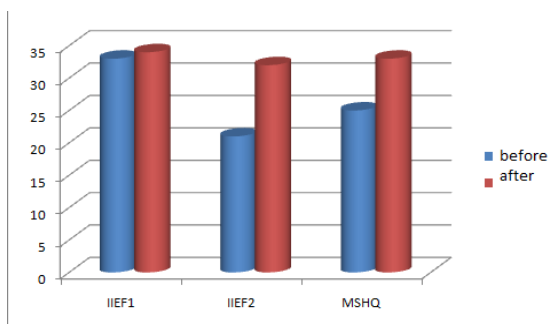


Figure (3): Bar chart for IIEF1, IIEF2 and MSHQ before and after.

Table (3): PVR and IPSS evaluation before and after surgery.

Variable	Before	After	p
PVR			
Median (range)	60(40-110)	0(0-40)	0.05
IPSS			
Mean±SD	30.1±4.2	2.6±1.2	0.05

Table (3) Show: significant reduction of PVR and IPSS after surgery.

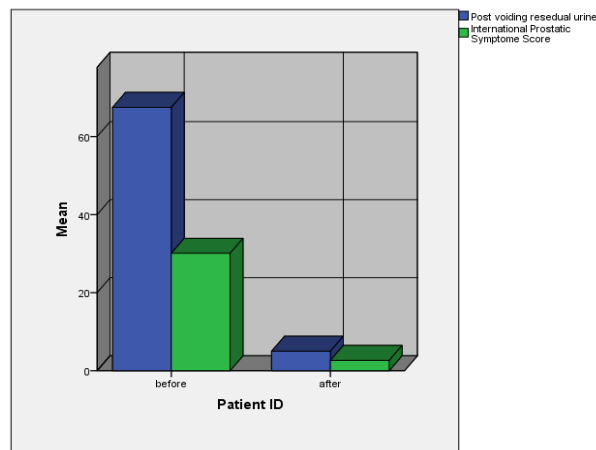


Figure (4): Bar chart for PVR and IPSS evaluation before and after surgery.

DISCUSSION

Thulium laser endourethrotomy has several advantages. The major advantages of using laser include clear vision during incision so that scar tissue can be incised more precisely, less blood loss, shorter hospital stay, and primarily possible less scar tissue after healing^(11,12). Laser was widely used in urology operation including urinary calculi, urethral stricture and benign prostate hyperplasia treated with thulium laser.^(13,14) The 50 W thulium laser was approved by the USA Food and Drug Administration and European Community in 2004 and came into the Chinese medical market in 2005. Thulium laser is a new surgical laser, whose wavelength is 2,013 nm. This wave length is strongly absorbed by water, with a low tissue penetration, <0.3 mm.

Thulium laser provides a short depth of penetration and with perfect hemostatic effect. With these advantages, thulium laser could be useful for urologist to reconstruct the urethra⁽¹⁵⁾. In our study, using the laser fibers in a contact mode under endoscopic vision and careful monitoring of the extent of tissue destruction, we obtained encouragingly good results in our patients, with a total success rate of almost 85% when follow-up of 6 months.

According to the results of follow up, 17 patients were satisfied with the results of thulium laser urethrotomy. After thulium laser urethrotomy, the postoperative retrograde urethrogram (RUG), IPSS (International prostate symptom score), Qmax (the maximum flow rate) and Qaverage (average urine flow) in uroflowmetry after followed-up of

6 months. As reported by (Djulepa and Potempa) most of the urethral strictures showed annular stricture. More attention should be paid when incising at 11 O'clock – 1 O'clock in stricture of the bulbomembranous urethra to avoid injury to surrounding important tissue ⁽¹⁶⁾. For patients with urethral stricture disease with a high rate of urinary tract infection (41%) we suggest that urine cultivation should be done routinely ⁽¹⁷⁾.

In our study despite perioperative antibiotics 15% of the patients developed urinary tract infection postoperatively. A long-term follow up with thulium laser urethrotomy had not been reported. We achieved a good result with high patient satisfaction (85%) and a great improvement in quality of life. No complications were encountered in this study. Intraurethral instillation of triamcinolone gel after removal of the catheter was suggested by some authors in order to reduce inflammatory reaction ⁽¹¹⁾. It was reported that most of the recurrent strictures that finally necessitated open urethroplasty were long segment (> 1.5 cm) having previous transurethral operations ⁽¹¹⁾.

It was reported by (wang and his colleagues) ⁽¹⁸⁾ that thulium laser urethrotomy was performed in all 21 cases. The mean operative time was 35 minutes range (15–75 minutes). No intraoperative complications were encountered. Despite perioperative antibiotics, 9.5% of the patients developed urinary tract infection postoperatively that was managed with antibiotics according to urine culture sensitivity.

Stricture treatment was successful in 17 patients (73.9%). One patient developed recurrent stricture that required open surgery with buccal mucosa. Two patients underwent repeat endoscopic treatment using the thulium laser, which was successful in one patient. Most patients (N = 16; 76.2%) did not need any interventions postoperatively.

Five patients developed recurrent strictures, of which two were treated with laser urethrotomy again, two were treated with urethral dilation, and one was treated with open urethroplasty. Including two patients treated with repeat laser urethrotomy (81%) 17 showed good flow of urine Qave (average urine flow) > 16.0 ml/second and adequate caliber urethra in retrograde urethrogram (RUG) 12 months after operation. Three (14.3%) patients showed narrow

stream of urine Qave (average urine flow) < 8.0 ml/second and performed urethral dilation every month or 2 months. A patient whose Qave (average urine flow) was between 8.0 and 16.0 ml/second was treated by neither urethral dilation nor another laser urethrotomy.

The average postoperative Qmax (the maximum flow rate) was 25.3 ml/second (range 6.5–35 ml/second) with an average volume more than 250 ml and an average PVR (postvoiding residual urine) of 56 ml (range 0–310 ml). The mean postoperative IPSS (International prostate symptom score) was 7.6 ± 5.8 (decrease of 11.2 points; $P < 0.05$) and the mean postoperative QoL was (2.5 ± 1.4) (decrease of 2.3 points; $P < 0.05$) after followed-up of 6 months. After followed-up of 12 months, the mean IPSS (International prostate symptom score) was 8.3 ± 4.5 (decrease of 10.5 points; $P < 0.05$), and the mean postoperative QoL was 2.5 ± 1.3 .

In study by (Liu and his coworkers) ⁽¹⁹⁾ detected that The mean operation time was 35 min ranging from 10 to 90 min.

In our study thulium laser urethrotomy was performed in all 20 cases. The mean operative time was 23.7 ± 4.5 minutes range (15–30 minutes). No intraoperative complications were encountered. Despite perioperative antibiotics, 15% of the patients developed urinary tract infection postoperatively that was managed with antibiotics according to urine culture sensitivity. Stricture treatment was successful in 17 patients (85%). Three patients developed recurrent stricture treated with urethral dilation. In 17 patients the mean postoperative Qave (average urine flow) > 12.3 ± 3.6 ml/second ($P < 0.05$) and adequate caliber urethra in retrograde urethrogram (RUG) 6 months after operation. Three patients (15%) showed narrow stream of urine Qave (average urine flow) < 8.0 ml/second and performed urethral dilation 1 time every month for 4 months. The mean postoperative Qmax (the maximum flow rate) was 21.7 ± 2.1 ml/second ($P < 0.05$) with insignificant PVR urine. The mean IIEF 1 (International Index of Erectile Function) postoperatively was 38.4 ± 1.4 . ($P < 0.05$). The mean IIEF 2 (International Index of Erectile Function) postoperatively was 32.2 ± 5.6 ($P < 0.05$). The mean MSHQ (Male Sexual Health Questionnaire) postoperatively was 32.2 ± 5.6 . ($P < 0.05$).

CONCLUSION

We demonstrated that thulium laser endourethrotomy was a reliable and safe therapy with minimal invasive therapeutic modality for urethral strictures and clear vision during incision so that scar tissue can be incised more precisely, less blood loss, shorter hospital stay, and primarily possible less scar tissue after healing. We believed that incisions for urethral strictures using the thulium laser should be considered in endoscopic urethrotomy. However, randomized studies with longer follow-up are necessary to determine the clinical value of the thulium laser in the treatment of urethral strictures.

REFERENCES

1. **Das S (2007):** Urology in ancient India. *Indian J Urol*, 23:2–5.
2. **Peterson AC and Webster GD (2004):** Management of urethral stricture disease: Developing options for surgical intervention. *BJU Int*, 94:971–6.
3. **Myers JB and McAninch JW (2011):** Perineal urethrostomy. *BJU Int.*;107:856–65.
4. **Wein AJ, Kavoussi LR, Novick AC et al. (2012):** Campbell-Walsh urology 10th ed. Philadelphia: Elsevier Saunders;. Campbell-walsh urology, 967–73.
5. **Herrmann TR, Liatsikos EN, Nagele U et al. (2012):** EAU Guidelines Panel on Lasers, Technologies. EAU Guidelines on Laser Technologies. *Eur Urol.*, 61:783–95.
6. **Zeitels SM, Burns JA, Akst LM et al. (2006):** Office-based and microlaryngeal applications of a fiber-based thulium laser. *Ann Otol Rhinol Laryngol.*, 115(12): 891–896.
7. **Lerner LB and Rajender A (2015):** Laser prostate enucleation techniques. *Can J. Urol.*, 22(1):53-59.
8. **Frid NM and Murray KE (2005):** High-power thulium fiber laser ablation of urinary tissues at 1.94 micron. *J Endourol.*, 19 (1):25-31.
9. **Chang C, LinEmail T, Chang Y et al. (2015):** Vapoenucleation of prostate using a high power thulium laser: a one year follow up study. *BMC Urol.*, 15:40.
10. **Kronenberg P and Traxer O (2014):** Update on lasers in urology: current assessment on holmium: yttrium- aluminum-garnet (Ho:YAG) laser lithotripter settings and laser fibers. *World J Urol.*, 33 (4):463-9.
11. **Kamp S, Knoll T, Osman MM et al. (2006):** Low-power holmium: YAG laser urethrotomy for treatment of urethral strictures: Functional outcome and quality of life. *J Endourol.*, 20(1):38–41.
12. **Hussain M (2008):** Urethral stricture disease: An old disease with newer treatments. *J Pak Med Assoc.*, 58(5):227–228.
13. **Wollin TA and Denstedt JD (1998):** The holmium laser in urology. *J Clin Laser Med Surg.*, 16(1):13–20.
14. **Xia SJ, Zhuo J, Sun XW et al. (2008):** Thulium laser versus standard transurethral resection of the prostate: A randomized prospective trial. *Eur Urol.*, 53(2):382–389.
15. **Teichmann HO, Herrmann TR and Bach T (2007):** Technical aspects of lasers in urology. *World J Urol.*, 25(3):221–225.
16. **Djulepa J and Potempa J (1983):** Urethrotomy technique in urethral strictures: 6-year results. *J Urol.*, 129(5):955–957.
17. **Santucci RA, Joyce GF and Wise M (2007):** Male urethral stricture disease. *J Urol.*, 177(5):1667–1674.
18. **Wang L, Wang Z, Yang B et al. (2010):** Thulium laser urethrotomy for urethral stricture: A preliminary report. *Laser in surgery and medicine*, 42(7):620-623.
19. **Liu CL1, Zhang XL, Liu YL et al. (2011):** [Transurethral thulium laser urethrotomy for urethral stricture]. *Zhonghua Nan Ke Xue*, 17(9):832-4.