



ORIGINAL ARTICLE

Lower Body Contouring after Massive Weight Loss at Zagazig University Hospitals

Yahia Zakaria Awaad ⁽¹⁾, Ayman Fikry Mehanna ⁽¹⁾, Mostafa Mohamed El Aidy ⁽¹⁾, and Ahmad Alaa Ezzat Ali Soud ^{*(1)}.

Department of Plastic Surgery, Faculty of Medicine, Zagazig University Egypt

***Corresponding Author:**

Name: Ahmad Alaa Ezzat Ali Soud

Email:

ahmadalaa_ahly@hotmail.com

Submit Date 2020-05-12

Revise Date 2020-06-19

Accept Date 2020-07-08

ABSTRACT

Background: Lower body contouring after massive weight loss exhibits a great challenge for the plastic surgeon. **Aim of the work:** is to assess surgical outcomes of lower body contouring after massive weight loss. **Methods:** This prospective cohort study was conducted at Plastic Surgery Unit, General Surgery Department, Faculty of Medicine, Zagazig University Hospitals on ten patients who underwent lower body contouring after massive weight loss. Full medical assessment, scar placement and meticulous marking, surgical procedure and post-operative care. **Results:** The mean of patient satisfaction on a scale from zero to 10 was 9 ± 1.26 , most of operated cases had no complications (70 %), and there was significant positive correlation between lipoaspirate amount and hospital stay. **Conclusions:** Lower body contouring is an extremely effective procedure to restore body contour in post bariatric patients. Careful preoperative marking, team work and few surgical tips are the keys for a procedure that is both



Key words: BMI, lipoaspirate, bariatric surgery, body contouring, abdominoplasty.

INTRODUCTION

Obesity is a global epidemic disease affects around 1.1 billion people worldwide. In 2008 the WHO stated that more than 1.4 billion adults were overweight or obese. The mortality rate that related to overweight or obesity is more than 3 million patients each year. Obesity is also associated with other morbidities as it is associated with more than 40% of diabetic patients, 40% of certain cancer patients and more than 20% of ischemic heart disease patients [1].

Patients with mild to moderate obesity can achieve weight reduction by life style modification through adjusting their caloric intake, regular exercise and behavior modifications but relapse is very common as it occurs in about >90% of the cases [2].

The development of excess redundant skin is considered common sequelae after successful bariatric surgery and massive weight reduction. It occurs in around 70-96% of patients who underwent bariatric surgery [3].

Massive weight loss patients put forward a great challenge to plastic surgeons to achieve a

better body contouring. Moreover they suffer from multiple complications such as psychological disorders and fungal skin infections. Body contouring surgeries for these patients isn't a single procedure; it is rather a process that implies a multiple excisional procedures. It requires a dedicated team to keep a safe management to help these patients to achieve their goal [4].

Skin redundancy after massive weight loss can affect any part of the body. The most common parts to be affected are the abdomen, inner arms, thighs, breasts, buttocks and knees. However, prediction whether this part will be affected or no is not feasible and no part of the body is immune against this complication [5].

The percentage of post bariatric patients who have undergone body-contouring procedures is about 85%. Abdominoplasty is by far the most common procedure after massive weight loss [6].

The lower body contouring surgeries are aiming to improve the contour of the waist, buttocks and thighs. It targets the lower truncal subunit and thighs as a one unit to improve the

lower body contour. Several procedures are reported for lower body contouring in post bariatric patients such as abdominoplasty, thigh lifting and gluteal lifting, etc. However, none of them is taking the upper hand over the other [7].

METHODS

This prospective cohort study was conducted at Plastic Surgery Unit, Department of General Surgery, Faculty of Medicine, Zagazig University Hospitals on 10 patients who underwent lower body contouring after massive weight loss. Full medical assessment, scar placement and meticulous marking, surgical procedure and post operative care. Informed written consent was taken from the patient to participate in the study. Approval for performing the study was obtained from general surgery departments, Zagazig University Hospitals after taking approval of Institutional Review Board (IRB). The study was carried out in accordance with The Code of Ethics of the World Medical Association. The study was done according to The Code of Ethics of the World Medical Association (Declaration of Helsinki) for studies involving humans.

Inclusion criteria: All patients must have been weight stable for 3 months at the time of undergoing lower body contouring.

Exclusion criteria: Patients who had lost weight due to diseases e.g. patients with blood, platelet, pro-thrombotic and vascular disorders, bone marrow aplasia, uncontrolled diabetes and sepsis and patients with cancer underwent chemotherapy. Patients with infection, loss of substance, deep vein thrombosis (DVT), and lymphedema. If the skin was not elastic enough, when they were obese.

The following parameters were recorded prospectively in a database: patient age, Gender, Job, Co-morbidities like hypertension, Tobacco smoking. preoperative evaluation was mandatory because the body-contouring procedures following MWL were often extensive with the potential for significant morbidity and even mortality.

Pre operative markings and photographs:

Meticulous markings were done for the selected procedure at least one day before the scheduled date of surgery with patients placed in standing position. Patients were photographed in all the standard views after the markings in good illumination. Figure (1)

Surgical technique

All patients were given an anti-coagulant overnight (clexan) together with a perioperative antibiotic. All patients were instructed to shower before operation with application of topical anti-

fungal cream in case of present fungal infection. All patients underwent general anaesthesia.

Surgery was performed using a supine to prone approach by surgeon and two assistants divided into two groups (right and left sides), with the leading surgeon supervising the entire procedure. The vertical grid was scratched with the backside of the scalpel dipped in methylene blue; this was to avoid the markings loss during surgery. The epidermis and upper part of dermis were incised with a scalpel, with the rest of the procedure carried out by cautery (monopolar diathermy) to minimize the blood loss and shortening the time of the operation. Posterior excision was performed without undermining. In the buttocks area, the surgeon left a moderate quantity of areolar adipose tissue to improve the gluteal region shape; at the flanks, the level of dissection laid just above the external oblique muscle fascia. The two groups were proceeding from the midline to lateral until reaching the mid-axillary line; in this way, the posterior skin closure was made easier. The wounds were closed in three layers: Scarpa's layer with vicryl 2/0, dermis with monocryl 3/0 and nylon 3/0 for the subcuticular stitch. At the flank, on both sides three stitches of vicryl 1 suture were placed to improve the wound closure strength and avoid wound breaking while the patient was rotated. The patient was turned to the supine position, re-prepped and draped. The pre-marked lower abdominal line was incised, and the flap was raised leaving a thin layer of fibrofatty tissue above the rectus sheath. The flap was elevated widely to the umbilical horizontal line. From the level of the umbilicus, cephalad dissection then proceeded on the midline up to the xiphoid, just to allow the future rectus sheath plication and to allow the flap advancement. Once the umbilical stalk was isolated, it was cut of the targeted size (length of the stalk). A plication of midline rectus was performed with interrupted vicryl 0 X-suture. Slightly above and below the umbilicus, the fascia was sutured with vicryl 1 in order to secure the stalk and prevent future dislocation. The umbilicus was sutured to the rectus sheath with interrupted suture at 3, 6, 9, 12 o'clock. The flap advancement was checked, and the superior incision line was chosen between The flap was advanced toward the pubis, and the wound was closed temporarily. The new position of umbilicus was estimated and marked on the abdominal flap in a Y design with the branches being 1 cm each. The anterior abdominal wall was moderately defatted around the new umbilical position for a 3 cm radius. The abdominal fascia slightly cranial and caudal to the stalk was anchored to the dermis

of the abdominal flap at 6 and 12 o'clock with nylon 2/0 sutures. Two large suction Blake 19F drains were left in situ. Wounds were closed, and the circumferential surgical wound was covered with mesh tape and cyanoacrylate glue to prevent contamination. Figure (2)

Postoperative care

Prophylactic antibiotic was administered. A second-generation cephalosporin was given intraoperatively and for 7 days postoperatively. Graded compression stockings and pneumatic calf compression boots were worn throughout the operation, and the stockings also postoperatively. We only perform mechanical prophylaxis for the majority of the patients. If the patient is graded as high risk at Caprini score, we administer enoxaparine; the dosage and length depend on the risk. The drains were removed when output was less than 40 cc in a 24h period. All patients were ambulated on the first postoperative day and were discharged home on the second postoperative day (only four patients were discharged after that, on the sixth postoperative day). Compression garments were worn for 12 weeks postoperatively night and day; from this time, an adequate rehabilitation program was allowed.

Follow up was done to the patient for 6 months at least. Evaluation was done by photography, asking the patient about his satisfaction, measuring pre and post circumferential diameters and process of care. similar views of the patient were taken post-operatively (immediate and long-term postoperative) with same background and illumination. Figure (3)

Statistical Analysis

The collected data were analyzed by computer using Statistical Package of Social Services

version 24 (SPSS). Data were represented in graphs and tables, Continuous Quantitative variables e.g age was expressed as the mean ± SD and median (range), and categorical qualitative variables were expressed as absolute frequencies (number) and relative frequencies (percentage).

RESULTS

This study was conducted on 10 patients to describe and appraise the different modalities of lower body contouring after massive weight loss.

Demographic data of the studied patients were demonstrated in (table. 1), the mean age of the studied patients was 38.50 ± 6.98 years old, with a range from 31 to 50 years old, most of the studied patients were female (80 %).

The mean of lipoaspirate amount was 1213 ± 216.9 ml with a range from 850 to 1500 ml, while mean of Resection weight (gm) was 939 ± 209.25 gm with a range from 670 to 1250 gm. Regarding hospital stay, the mean was 2.5 ± 0.84 days with a range from one to 4 days. The mean Time to drain removal was 4 ± 1.3 days with a range from 2 to 6 days. (table. 2).

Regarding patients satisfaction about the results, that mean of Patient satisfaction on a scale from zero to 10 was 9 ± 1.26 with a range from 6.5 to 10 (Figure 3). Most of operated cases had no complications (70 %), while complication either in the form of infection, seroma and wound dehiscence occurs in 10% respectively (table.3).

Finally we figured out that, there is significant positive correlation between lipoaspirate amount and hospital stay, which means that hospital stay is prolonged according to the amount of lipoaspirate, the more the amount of lipoaspirate, the longer hospital stay.

Table (1): Demographic data of the studied patient

Demographic data	Studied patients (N=10)	
	No.	%
Sex		
Male	2	20.0%
Female	8	80.0 %
Age (years)		
Mean ± SD	38.5 ± 6.5	
Median (Range)	36.5 (31-50)	

Table (2): Lipoaspirate amount and resection weight among the studied group.

studied patients (N=10)	
Lipoaspirate amount (ml)	
Mean ± SD	1215 ± 216.75

Median (Range)	1230(850-1500)
Resection weight (gm)	
Mean ± SD	936 ± 209.25
Median (Range)	925(670-1250)

Table (3): Complication of operation among the studied group

Complication	Studied patients (N=10)	
	No.	%
• No complications	7	70.0
• Wound infection	1	10.0
• Seroma	1	10.0
• Wound dehiscense	1	10.0

Figures

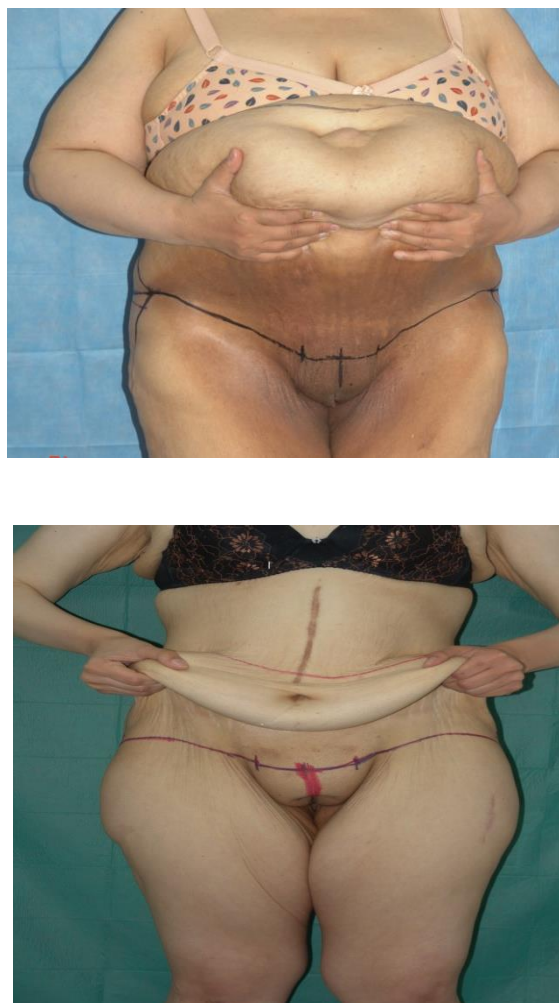


Figure (1): preoperative anterior incisional markings with forced elevation of abdominal skin.

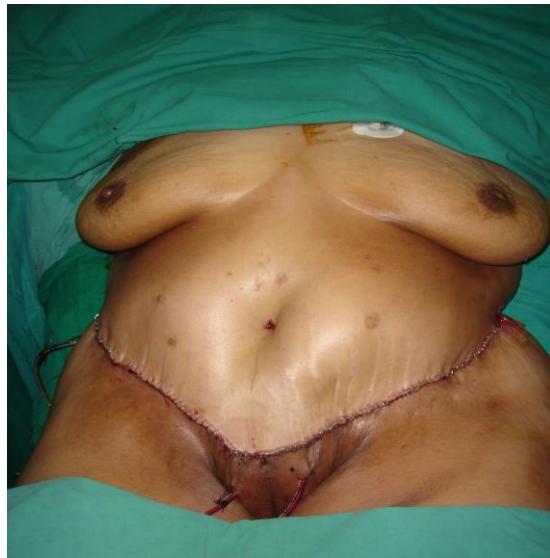

Figure (2): closing of the wound with skin stables with subcutaneous suction drains

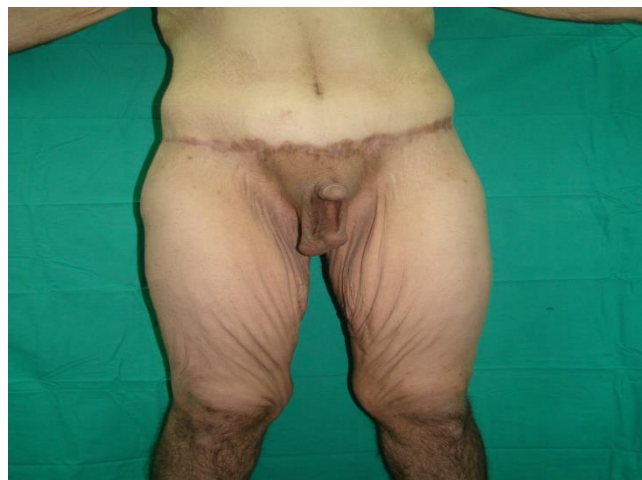
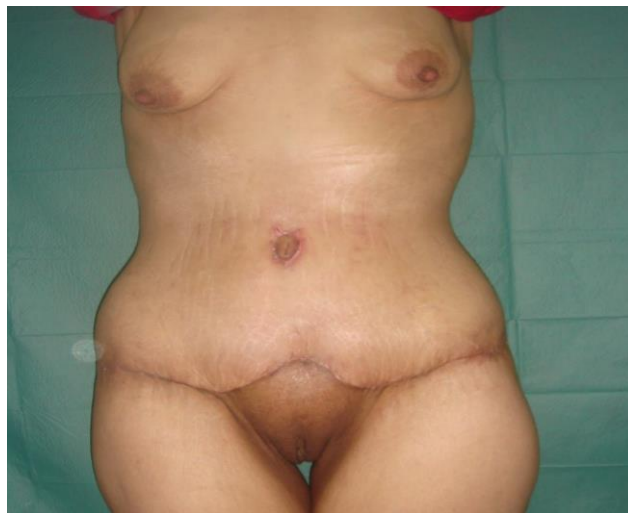
Figure (3): 6 months later post-operative scar with absence of redundancy iscusssion

DISCUSSION

Obesity is a major risk factor for development of a lot of chronic diseases, Obesity may create difficulties in the activities of daily life, thus negatively affecting the quality of life and triggering psychological disorders, including a poor self-image and depression [8].

Post bariatric reconstructive surgery has evolved significantly, it was pushed both by the increasing incidence of obesity and by the growing popularity of bariatric weight loss surgeries [9].

Although bariatric surgeries achieve successful weight loss, many aesthetic concerns arise such as, increase skin folds. Consequently, many patients report interference with proper fitting of clothes, social interactions or hygienic issues; aesthetic concerns might be, among others: abdomen, mons pubis, hip region, gluteal region [10].

Attempts to manage the postbariatric patient with abdominoplasty alone are result in an unsatisfactory outcome. For patients with saddlebags and laxity of the lower trunk, thighs and buttock region, a lower body lift could be a treatment of choice and the most proper.[11]

This study showed that that mean operative time was 213.2 ± 28.36 min with a range from 165 to 250 min. We did not observe any differences in duration of the operation, because the liposuction was performed on a very limited surface. So, it was completed by the surgeon in a short time; furthermore, the cut was bloodless, in this way, we proceeded faster as we should not coagulate the dermis. Regarding liposuction volume, our study showed that was 1213 ± 216.9 ml with a range from 850 to 1500 ml, while mean of resection weight (gm) was 939 ± 209.25 gm with a range from 670 to 1250 gm.

This approximately goes in agreement with Bertheuil et al .[12]. that found that the mean of operative time was 229 ± 34 minutes, and the mean mass of resected skin was 956 ± 216.75 g. Yet, mean liposuction volume in their study was 2760 ± 1011 ml which was way higher than the volume in our results which was 1213 ± 216.9 ml with a range from 850 to 1500 ml. Our results also agree with **Losco et al., [13]** that found the mean operative time was 222 ± 20.7 min. as our study which showed that the mean operative time was 213.2 ± 28.36 min with a range from 165 to 250 min.

This study showed that mean of time to drain removal was 4 ± 1.3 days with a range from 2 to 6 days, while length of hospital stay was 2.5 ± 0.84 days with a range from 1 to 4 days that agreed with Bertheuil et al [12] who found that

the average drainage duration was 3.56 ± 0.65 days and the average hospital length of stay was 2.1 ± 0.5 days.

However, Losco and his colleagues [13] found that the average length of stay was 3.52 ± 0.77 days, and the mean of drain duration was 13.7 ± 1.9 days , which disagrees with our study.

Regarding patient satisfaction, it was measured on a scale from 1 to 10, Our patients were highly satisfied with the results with a mean of patient satisfaction reaching (9 ± 1.26) with a range from 6.5 to 10. An innovative aspect to consider was the usage of drains led to an increase in the patient comfort and at the same time a reduction in the risk of wound infection that in fact was very low.

Most of our operated cases had no complications (70%), while complications either in the form of infection, seroma and wound dehiscence occur in 10% respectively. All the complications were managed on an outpatient basis. The cases of wound infection were treated with local medications and oral antibiotics, while the seroma was treated by fine needle aspirations. We have had no cases of skin necrosis or postoperative edema clearly confirms the benefits of liposuction.

CONCLUSIONS

Based on our study we conclude that, Lower body contouring is an extremely effective procedure to restore body contour, abdominal and back enhancement, improve thigh and gluteal appearance in postbariatric patients with massive weight loss. preoperative marking, team work and few surgical tips are the keys for a procedure that is both satisfactory for the surgeon and safe for the patient. We performed a safe surgery with no undermining or liposuction in short operative times

Funding information: None

Conflict of interest: None

REFERENCES

- 1- **Shrivastava P, Aggarwal A, Khazanchi R.** Body contouring surgery in a massive weight loss patient: An overview. *Indian J Plast Surg.* **2008**; 41:114-29.
- 2- **Anderson JW, Konz EC, Frederich RC, Wood CL.** Long-term weight loss maintenance: A meta-analysis of US studies. *Am J Clin Nutr.* **2001**; 74(5):579 -84.
- 3- **Kitzinger HB, Abayev S, Pittermann A, Karle B, Bohdjalian A, Langer FB, et al.** After massive weight loss: patients' expectations of body contouring surgery. *Obesity Surgery.* **2012**; 22(4):544-8.
- 4- **Langer V, Singh A, Aly A, Cram A.** Body contouring following massive weight loss. *Indian J Plast Surg.* **2011**; 44(1), 14-20.

- 5- **Björserud C, Olbers T, Sjøvik TT, Mala T, Elander A, Olsén MF.** Experience of excess skin after gastric bypass or duodenal switch in patients with super obesity. *Surgery for Obesity and Related Diseases, J Am Soc Baria Surg.* **2014**; 10(5), 891-6.
- 6- **Aldaql SM, Samargandi OA, El-Deek BS, Awan BA, Ashy AA, Kensarah AA.** Prevalence and desire for body contouring surgery in postbariatric patients in Saudi Arabia. *Am J Med Sci.* **2012**; 4(2):94-8.
- 7- **ElKafrawy H, Wasief S.** Circular Abdominoplasty (Belt Lipectomy) in Obese Patients. *Body Contouring and Sculpting,* **2016**; 109.
- 8- **Gallagher EJ, Leroith D, Karnieli E.** Insulin resistance in obesity as the underlying cause for the metabolic syndrome. *Mt Sinai J Med.* **2010**; 77(5), 511–23.
- 9- **Gimigliano F, Moretti A, de Sire A, Calafiore D, Iolascon G.** The combination of vitamin D deficiency and overweight affects muscle mass and function in older post-menopausal women. *Aging Clin Exp Res.* **2018**; 30(6): 625–31.
- 10- **Poodt IG, van Dijk MM, Klein S, Hoogbergen MM.** Complications of lower body lift surgery in postbariatric patients. *Plast Reconstr Surg Glob Open.* **2016**; 4(9), 1030.
- 11- **Richter DF, Stoff A, Velasco-Laguardia FJ, Reichenberger MA.** Circumferential lower truncal dermatolipectomy. *Clin Plast Surg.* **2008**; 35(1): 53-71.
- 12- **Bertheuil N, Chaput B, De Runz A, Girard P, Carloni R, Watier E.** The lipo-body lift: A new circumferential body-contouring technique useful after bariatric surgery. *Plast Reconstr. Surg.* **2017**; 139(1): 38-49.
- 13- **Losco L, Roxo AC, Roxo CW, Torto FL, Bolletta A, de Sire A, et al.** Lower body lift after bariatric surgery: 323 consecutive cases over 10-year experience. *Aesth Plast Surg.* **2019**; 44(2): 421-32.
- 14- **Roxo AC, Del Pino Roxo C, Marques RG, Rodrigues NC, Carneiro DV, Souto FM, et al.** Endocrine-metabolic response in patients undergoing multiple body contouring surgeries after massive weight loss. *Aesthet Surg J.* **2019**; 39(7): 756–64.

To Cite:

Ezzat, A., Awaad, Y., Mehanna, A., El Aidy, M. Lower Body Contouring after Massive Weight Loss at Zagazig University Hospitals. *Zagazig University Medical Journal*, 2022; (1269-1280): -. doi: 10.21608/zumj.2020.29296.1838