

## **Retropharyngeal calcific tendonitis complicated by retropharyngeal abscess: Case report**

**Nawal Mohammed Alhulaimy<sup>1</sup>, Nadia Mohammed Albraheem<sup>2</sup>**

<sup>1</sup>Aljabr hospital in KSA, <sup>2</sup>King Faisal University.

**Corresponding author:** Nadia Mohammed Albraheem, **E.mail:** n.g.e.a.h.123@hotmail.com

### **ABSTRACT**

**Background:** Retropharyngeal calcific tendonitis is defined as an uncommon and self-limiting inflammatory process of the superior oblique tendons of the longus colli muscle. It is considered as one of the differential diagnosis of retropharyngeal fluid collection. Furthermore, it causes neck pain resulting in limitation of the range of motion due to calcification of longus colli muscle and accumulation of sterile effusions. It is very important to have a definitive diagnosis by using computed tomography (CT) because the symptoms of retropharyngeal calcific tendonitis can resemble other serious conditions such as retropharyngeal abscess, thus it will affect the management plan. Retropharyngeal calcific tendonitis does not require surgical treatment; it is treated medically using non-steroidal anti-inflammatory medications. On the other hand, retropharyngeal abscess required incision and drainage. In this study, we discuss one case of retropharyngeal calcific tendonitis complicated by retropharyngeal abscess, discussing key radiologic features, and treatment options.

**Key-words:** Retropharyngeal space, Calcific tendonitis, Longus colli muscle, Abscess

### **INTRODUCTION**

We present this case which was initially diagnosed as retropharyngeal abscess according to the first presentations. After further investigations the patient was found to have retropharyngeal calcific tendonitis (RCT) complicated by retropharyngeal abscess. The mean annual crude retropharyngeal calcific tendinitis incidence was 0.50 cases per 100,000 person/years, and the standardized incidence was 1.31 for the age-matched population [1]. The purpose of this case report is to highlight the diagnostic features that will help the surgeon to give a definitive diagnosis that will minimize the risk of unnecessary operative interventions and manage the patient medically according to the severity of the case. Finally, it is important to differentiate between retropharyngeal abscess and RCT in order to set the suitable management plan as the RCT is not very rare and cases are rather under-diagnosed.

### **CASE HISTORY**

A 52-year-old male presented to our Emergency Room complaining of severe dysphagia, neck pain and restricted neck movement for 9 days, but no significant airway compromising symptoms. He is a known case of diabetes and hypertension on medical treatment with poorly controlled blood sugar level. He denied any history of fever, upper respiratory tract infection or dental problem.

On examination, his vital signs were normal, positive neck rigidity and tender neck muscle mainly at the right side associated with loss of the laryngeal crepitus, but no definite mass

palpable nor any lymph-adenopathy. Brudzinski's and kernig's signs were negative.

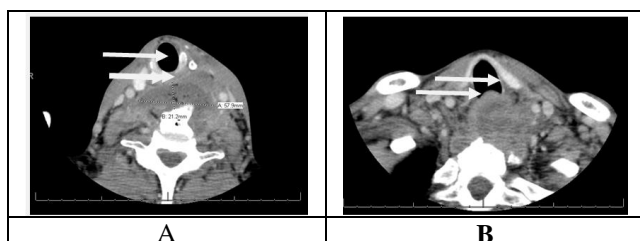
Fibro-optic endoscopy findings: mild bulging of the posterior pharyngeal walls seen, causing mild airway compression, laryngeal structures appeared normal.

### **Treatment course:**

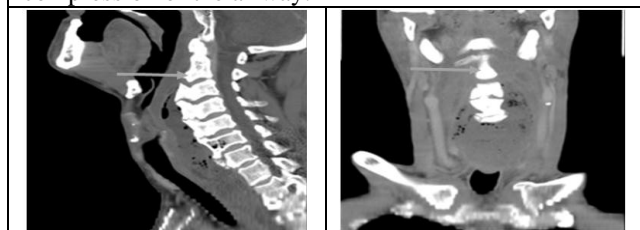
Immediately Ceftazidime and Clindamycin were started and CT scan of head & neck was done (figure 1) and showed pre-vertebral fluid collection, big osteophyte and airway compression.

On the next day, patient condition started to worsen, he complained of shortness of breath. Under general anaesthesia: trans-oral incision and drainage was done and a drain kept for 3 days. The drained fluid appeared milky and we took swabs for C/S, TB and cytology. The patient symptoms started to improve immediately after the surgery but after 4 days he started to deteriorate. Follow up CT Images showed a clear retro-pharyngeal space but persistent mediastinal fluid (figure 2).

Thoracic surgeon, neuro-surgeon and infectious disease specialties had involved in this case, they agreed to manage the case medically by changing the Ceftazidime to Tazocin. Culture result was negative for bacteria and AFB stain. Patient remained in the hospital for 2 weeks on antibiotics and he responded well clinically.



**Figure 1 (a):** Axial CT scan with IV contrast, at the level of T1, shows pre-vertebral fluid collection and big osteophyte. **(b):** Axial CT scan of neck, shows compression of the airway.



**Figure 2 (a):** Sagittal view of CT scan with IV contrast shows prevertebral fluid collection from 1st vertebra to the superior mediastinum. **(b):** Coronal view of CT scan with IV contrast shows the same (arrows).

## DISCUSSION

Acute retropharyngeal calcific tendonitis is poorly described in the literature of otolaryngology. It is one of the medical emergencies that threaten patient airway by occluding it through abscesses collections.

Retropharyngeal space lies posterior to the pharynx and starts from the base of the skull superiorly to the mediastinum inferiorly, buccopharyngeal fascia and prevertebral fascia bound to it anteriorly and posteriorly, respectively. In this space there are several accesses to multiple organisms due to its different blood supply which make it easy to get infected by variety of organisms. In our case both blood culture and wound swab did not isolate any growing organisms. There are two explanations for such finding: either the effect of antibiotic pre and post operative eliminate the organisms and gave false negative result or there is a secondary cause for this case which is not infection. On the other hand, different cases were reported with aerobic organisms, anaerobic organisms and Gram-negative as a causative organisms.

The longus coli is a combined thin flexor muscle that traverses the front surface of the vertebral bodies from C2 and T3. It gets its blood supply from the vertebral, mediocre thyroid and climbing pharyngeal conduits and is innervated constantly through 6th cervical spinal nerves <sup>[2]</sup>. The

profound layer of the profound cervical fascia lies anterior to the muscle and posterior to the retropharyngeal space. As first described by Hartley in 1964, calcium stores in this region have been related with side effects of diminished range of motion on the neck, odynophagia, dysphagia, and throat swelling <sup>[3]</sup>. Likewise with deposition of calcium inside joint spaces, there are related inflammatory changes, which, in the case of calcium deposition inside the longus colli muscle, is related with tendonitis.

Ring and partners in 1994 described a progression of 5 patients, one of them had an open biopsy for suspected malignancy. At the point when this tissue was inspected microscopically, an inflammatory foreign body response was discovered, likely in response to hydroxyapatite deposition <sup>[4]</sup>. This has been the generally accepted pathophysiologic mechanism of longus coli tendonitis. They additionally reported oedema in the posterior part of the nasopharynx.

On flexible fiberoptic laryngoscopy examination, our patient seemed to have inflammation and erythema of the adenoid pad which had not been previously distinguished. This is likely because of spread of inflammation along the fascial plane between the adenoids and longus colli muscles.

The differential diagnosis of a retropharyngeal liquid accumulation on imaging is extensive, and the oedema related with tendonitis can be mistaken for a retropharyngeal abscess. Pathognomonic radiologic findings in RCT are the presence of a prevertebral effusion from C1 to C4 and calcifications beneath the anterior arch of C1. In some instances, calcifications are not found and a contrast CT is justified to confirm whether the fluid collection is ring enhancing <sup>[5]</sup>. More recent literature also reports that calcifications at C4-C5 could be related with symptoms of respiratory distress <sup>[6,7]</sup>.

Adult patients with retropharyngeal abscess commonly present with fever, disrupted and painful swallowing resulting in poor oral intake, sore throat, diminished range of neck motion with neck pain, difficult breathing and they may have a blocked airway. They additionally give some physical presentations, for example, voice changes, uncontrolled salivation dribbling from the mouth, inability to flex the neck forward, cervical adenopathy and above all they present with

posterior pharyngeal oedema <sup>[8]</sup>. Our patient presented with severe dysphagia and neck rigidity.

Clinical diagnosis of such a case is usually made by the otolaryngologist and it is not easy to make the certain diagnosis because of the variable and nonspecific presentations of the disease. Also, some patients are lacking the infectious signs due to the immunosuppression like our patient who was diabetic and afebrile. However, since retropharyngeal space oedema is deep and have many differential diagnoses we used CT scan to find the exact diagnosis because it is very important to differentiate between retropharyngeal calcific tendonitis and retropharyngeal abscess in order to set the suitable treatment plan.

Even though RCT is a self-limiting disease, our patient symptoms and C.T indicated abscess formation and airway compression which prompted us to drain and not to wait for medical treatment. The patient started to improve immediately after the surgery but after 4 days he started to deteriorate due to extension of fluid to the upper mediastinum. Retropharyngeal abscess is considered as one of the serious emergencies that's why Otolaryngologist should be familiar with the differences between it and RCT and this will be mainly based on clinical diagnosis supported by imaging techniques and this will help in minimizing un-necessary invasive procedures to the patient.

## REFERENCES

1. **Horowitz G, Ben-Ari O, Brenner A, Fliss DM, Wasserzug O (2013):** Incidence of retropharyngeal calcific tendinitis (longus colli tendinitis) in the general population. *Otolaryngol Head Neck Surg.*, 148(6):955-8.
2. **Pollak N and Wexler S (2013):** Retropharyngeal Calcific Tendonitis Mimics a Retropharyngeal Abscess. *Case reports in otolaryngology*, 2013.
3. **Hartley J (1964):** Acute cervical pain associated with retropharyngeal calcium deposit. A case report. *Journal of Bone and Joint Surgery*,46:1753–1754.
4. **Ring D, Vaccaro AR, Scuderi G, Pathria MN, and Garfin SR(1994):** Acute calcific retropharyngeal tendinitis. Clinical presentation and pathological characterization. *Journal of Bone and Joint Surgery*,76: 1636–1642.
5. **Paik NM, Lim CS, and Jang HS (2012):** Tendinitis of longus colli: computed tomography, magnetic resonance imaging, and clinical spectra of 9 cases. *Journal of Computer Assisted Tomography*,36: 755–761.
6. **Boikov AS, Griffith B, Stemer M, and Jain R (2012):** Acute calcific longus colli tendinitis: an unusual location and presentation. *Archives of Otolaryngology*, 138: 676–679.
7. **Kupferman TA, Rice CH, and Gage-White L (2007):** Acute prevertebral calcific tendinitis: a nonsurgical cause of prevertebral fluid collection. *Ear, Nose and Throat Journal*, 86: 164–166.
8. **Bou-Assaly W, Mckellop J, and Mukherji S (2010):** Computed tomography imaging of acute neck inflammatory processes. *world journal of radiology*, 2(3): 91-96.