

Surgical Complications of Endoscopic Endo-nasal Trans-Sphenoidal Approach for Pituitary Tumors

Islam Hassaan Al-Arabi,^{1*} Magdy Assad El-Hawary¹ MD and Ibrahim Gameel Ewais¹ MD

***Corresponding Author:**

Islam Hassaan Al-Arabi
neuro88islam@gmail.com

Received for publication January 14, 2020;
accepted July 14, 2020; **published** online July 14, 2020.

10.21608/aimj.2020.26253.1175

Copyright 2020 The Authors published by Al-Azhar University, Faculty of Medicine, Cairo, Egypt. All rights reserved. This an open-access article distributed under the legal terms, where it is permissible to download and share the work provided it is properly cited. The work cannot be changed in anyway or used commercially.

doi: 10.21608/aimj.2020.22945.1105

¹Neurosurgery Department, Faculty of Medicine, Al-Azhar University, Cairo, Egypt

Abstract

Background: Pituitary macro-adenomas form about 10% of intracranial tumors. Most of them are non-functioning and manifestations are due to space-occupying effects or clinical hypopituitarism. Functioning adenomas result in the conditions of Cushing's disease, galactorrhoea/oligo/amenorrhoea and acromegaly. Non-functioning pituitary tumors may also produce hyper-prolactinaemia due to dis-inhibition of the effects of hypothalamic dopamine on lactotroph cells.

Aim of the work: Detection of surgical complications of endoscopic endo-nasal trans-sphenoidal surgery for pituitary tumors and how to avoid and manage them.

Material and Methods: This study is conducted upon 40 cases diagnosed to have pituitary tumors, operated upon in the department of Neurosurgery at Al-Azhar University Hospitals, and Shibin Al-Kawm teaching hospital from March 2017 to March 2019. Prospectively collected and retrospectively analyzed.

Results: Eleven patients suffered complications, as CSF leak, intra-operative bleeding, and herniation of diaphragm sellae.

Conclusions: Endoscopic Trans-sphenoidal approach usually is the method of choice for treating pituitary tumors due to lower risk of complications.

Keywords: Pituitary tumors; Endoscopic pituitary surgery; Complications.

Authorship: All authors have a substantial contribution to the article.

Disclosure: The authors have no financial interest to declare in relation to the content of this article. The Article Processing Charge was paid for by the authors.

INTRODUCTION

Pituitary tumors incidence is about 0.4: 8.2 per 100,000 / year with the highest incidence in females aged 45: 64 years. Some studies showed equal sex incidence, but female predominance was found in both the Mayo Clinic and UK series in the 1970s.¹

Pituitary gland anatomically can be described as being in two places at once: under the brain or at the top of the nose. This is the base for trans-sphenoidal and trans-cranial approaches.²

The endoscope was first used in trans-sphenoidal approach for sellar lesions by Gerard Guiot about 50 years ago. Subsequently, ENT surgeons acquired confidence with the endoscope while performing FESS, and this showed them first the way to the sella. This was followed by Jho and Carrau, who pioneered the pure endoscopic approach to pituitary lesions about 20 years ago.³

This approach is considered a minimally invasive yet maximally effective neurosurgical management for cases with pituitary tumors.⁴

Complications of trans-sphenoidal technique can be categorized based on the anatomic structures and on body systems affected. Intracranial complications are probably the most devastating. Direct intracranial hemorrhage may occur, subarachnoid bleeding or organized intracranial hematoma may be the cause of complications or death.⁵

Meningitis may occur as a result of the introduction of organisms into the intracranial space at time of operation or if postoperative CSF rhinorrhea occurs. Other infections as subdural empyema and brain abscess are usually secondary to meningitis.⁶

Carotid artery complications can result in either mortality or serious disability. Carotid injury occurs when the artery, as it lies in the cavernous sinus, is lacerated, avulsed, or perforated. The cavernous sinus, together with its contents, also is a source of complications during transsphenoidal surgery.⁷

Visual complications are capable of causing severe disability, yet rarely fatal.⁵

Postoperative CSF rhinorrhoea occurs mostly through the sella and its diaphragm. Sphenoid sinus

and naso-facial complications can be also troublesome and may last for a while following surgery.⁵

Endocrinological complications, commonly hypopituitarism, should be quickly diagnosed and corrected using appropriate thyroid, steroid and gonadotropic replacement treatments.⁵

PATIENTS AND METHODS

Study design:

A prospective study conducted on 40 patients diagnosed with pituitary tumours, they were operated upon in Neurosurgery department at Al-Azhar University Hospitals, and Shibin Al-Kawm teaching hospital from March 2017 to March 2019, prospectively collected and retrospectively analyzed. All patients were subjected to complete history taking, visual assessment, complete hormonal profile assessment, and routine pre-operative laboratory investigations. All 40 cases were subjected to multislice parasagittal, coronal and axial CT scan cuts of the nose, para-nasal sinuses and sellar area. High resolution MR imaging was used for all cases to evaluate tumor size. MRI in sagittal, axial and coronal images pre and post gadolinium diethylenetriamine pentaacetic acid intravenous injection.

Ethical approval:

The study was revised and approved by the Al-Azhar University Ethics Board.

Statistical analysis:

The data were collected, tabled and analyzed by SPSS (statistical package for social science) version 17.0. Two types of statistics were done, descriptive statistics and analytic statistics: which include the following tests: Chi-square test (χ^2), Fisher's Exact test, t-test, Mann Whitney U test and the Wilcoxon signed-rank test. P-value of <0.05 was considered statistically significant.

RESULTS

40 patients with endoscopic endonasal trans-sphenoidal approach participated in this study. Their mean \pm SD age were 37.02 \pm 11.39 years with maximum and minimum values of 54 and 18 years respectively as shown in (Figure 1).

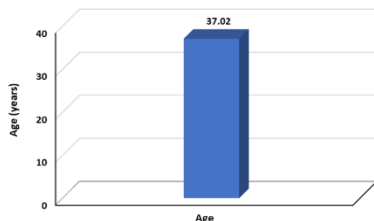


Fig. 1: Mean age of the study group.

The sex distribution of the study group revealed that there were 23 females with reported percentage of 57% while the number of males was 17 with reported percentage of 43% as demonstrated in (Figure 2).

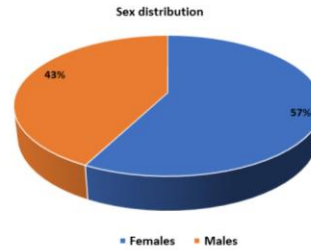


Fig 2: Sex distribution of the study group.

The adenoma size distribution of the study group revealed that there were 33(82%) patients with macroadenoma and 7(18%) patients with microadenoma as demonstrated in (Figure 3).

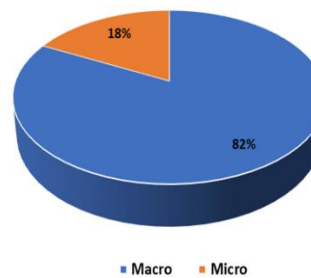


Fig 3: Adenoma size distribution of the study group.

31 (77.5%) patients had sellar sphenoid, presellar sphenoid sinus type was found in 9 patients (22.5%) as shown in (Figure 4).

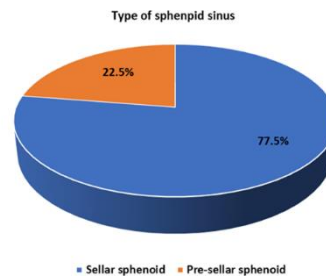


Fig 4: Types of sphenoid sinus pneumatization

36 (90%) patients complained of headache, 16 (40%) had diminution of vision, 8 (19.5%) had blurring of vision, 7 (17.5%) had visual field defect, 4 (10%) had secondary amenorrhea, 4 (10%) had menstrual irregularity, 4 (10%) amenorrhea, 3 (7.5%) had galactorrhea, 8 (20%) had acromegalic features, 2 (5%) had erectile dysfunction, 2 (5%) had double vision, 1 (2.5%) had failure of lactation, 1 (2.5%) had gynecomastia, 1 (2.5%) had loss of libido, 1 (2.5%) had loss of pubic and axillary hair, 1 (2.5%) had ophthalmoplegia, 2 (5%) had left blind eye, 1 (2.5%) had vomiting and 1 (2.5%) had weight gain. (Table 1).

Patients complaints	No (%)
Headache	36 (90%)
Diminution of Vision	16 (40%)
Blurring of Vision	8 (19.5%)
Visual Field Defect	7 (17.5%)
Secondary Amenorrhea	4 (10%)
Menstrual Irregularity	4 (10%)
Amenorrhea	4 (10%)
Galactorrhea	3 (7.5%)
Acromegalic features	8 (20%)
Erectile Dysfunction	2 (5%)
Double Vision	2 (5%)
Failure of Lactation	1 (2.5%)
Gynecomastia	1 (2.5%)
Loss of Libido	1 (2.5%)
Loss of Pubic and axillary hair	1 (2.5%)
Ophthalmoplegia	1 (2.5%)
Left Blind Eye	2 (5%)
Vomiting	1 (2.5%)
Weight Gain	1 (2.5%)

Table 1: The frequency of patients' complaints in the study group.

11 (27.5%) patients of the study group had surgical complications while 29 (72.5%) patients didn't have surgical complications as demonstrated in (Figure 5).

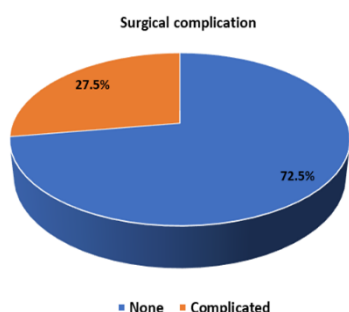


Fig. 5: Occurrence of surgical complications.

5 (45.45%) patients had CSF leak, 5 (45.45%) patients had intra-operative bleeding and 1 (9.1%) patient had herniation of diaphragm sellae as demonstrated in (Figure 6).

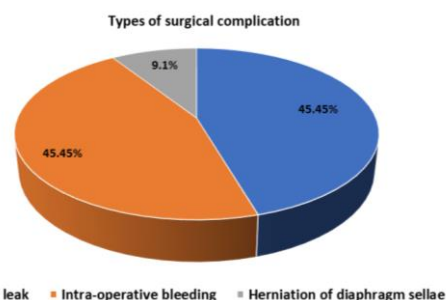


Fig 6: Frequency of surgical complications distribution in the study group.

DISCUSSION

This study included 40 patients with pituitary tumors operated upon in the Departments of Neurosurgery in Al-Azhar University Hospitals and Shibin Al-Kawm teaching hospital from March 2017 to March 2019. All the cases were operated upon by endoscopic endonasal transsphenoidal approach.

Epidemiologic findings:

In our work, female patients were more common representing 23 cases (57%) and male patients were 17 cases (34%).

The age ranged from 18: 54 years (mean of 37.02 years). While in studies performed by Cavallo et al⁸ and Gamrotet al.,⁹ the age ranged from 17-75 years (mean age of 45 years).

The most frequent symptom in our study is headache, and it is found in 90% of patients (36 patients), whereas in a large literature review as in Rotariu et al¹⁰ and Pal et al¹¹, headache was mentioned in only 76% of cases.

Visual symptoms were the 2nd most frequent presentations as 16 (40%) had diminution of vision, 8 (19.5%) had blurring of vision, 7 (17.5%) had visual field defect, these results are nearly equal to the results of Verrees et al.¹²

Pituitary apoplexy was found in 3 cases (7.5%). They presented with sudden visual failure. 2 patients improved post-operatively and 1 patient did not improve in spite of good decompression. This patient was operated upon after one week from the apoplexy which explains why he did not improve post-operatively despite the tumor was removed totally .

In our study, 60% of the cases had no identifiable contributing factor and the apoplectic event was the first presentation which asserts the cases seen in the series of Peterson.¹³

However, the remaining cases showed various risk factors, the most common was arterial hypertension documented prior to the apoplectic event, similar to that documented by Randeve et al.¹⁴

Preoperative evaluation:

MRI with IV contrast was done for all cases. It was considered the imaging test of choice for sellar tumors. It gave information about the suprasellar extensions, invasions of cavernous sinus and carotids. CT paranasal sinuses were done for all 40

patients. Axial and coronal CT scans displayed the bony features that act as anatomical landmarks of the endoscopic pathway (nasal septum, nasal turbinates, sphenoid ostium, etc) and allowed the assessment of the symmetry and aeration of the sphenoid sinus. In our study, all lesions were nearly identified by MRI rather than CT, similar to what happened with Recinos et al¹⁵, who reported that CT scans detected about 21% of pituitary masses in their series of 35 patients, whereas MRI identified 88% of the cases.

Operative data:

In this study, the operation was started with the enlargement of the sphenoid ostium, so there wasn't an incision in the nasal mucosa which decreased the incidence of nasal complications as nasal septal perforation. The endonasal approach was made via a para-septal pathway medial to the middle turbinate. The landmark leading to the sella was the inferior margin of the middle turbinate. A line that is drawn along the inferior margin of the middle turbinate and extends to 1 cm inferior to sellar floor and the posterior wall of the sphenoidal sinus was exposed through small anterior sphenoidotomy hole. The middle turbinate is removed in some cases if the tumor was invading the right cavernous sinus, in order to facilitate the procedure. Many authors have reported partial or total removal of the middle turbinate to facilitate the approach to sphenoidal sinus as Har-El G,¹⁶ and Thomas et al.¹⁷ In our series, endoscope holders weren't used, because one of the most important advantages of the endoscope is its mobility; it can be rapidly repositioned without having to be released and fixated. The holding technique may not be sufficient to hold the endoscope exactly in the desired position.¹⁸

Outcome:

83.4% (5 out of 6 cases) of the cases with visual field defects improved post-operatively, 87.5% (14 out of 16 cases) of the cases with diminished visual acuity improved after surgery. In the present study, there were no cases with visual deterioration. The previous results are more similar to the study by Cappabianca et al.¹⁹

Complications:

CSF leakage was the commonest intra-operative problems as 5 patients (45.45%) had CSF leak, 5 patients (45.45%) had intra-operative bleeding and 1 patient (9.1%) had herniation of diaphragm sellae. Patients with an intra-operative CSF leak, efficient packing of the sella, with or without packing of the sphenoid sinus, was performed. This procedure consists of a first layer of autologous or synthetic dura, placed intradurally so as to protect the arachnoid mater; it followed the use of autologous fat or resorbable substances into the sella. A 2nd layer composed of an autologous or synthetic dura was fitted extradurally, and the closure was completed via fibrin glue film on the outer surface of the sellar floor. In our study, we used a fat graft to pack the sella after surgery, trying to prevent CSF leakage and sagging of the arachnoid membrane or the chiasm. We had one case (old age) of mortality with pituitary

adenoma due to cardiac arrest with no hyponatremia or hypokalemia.

Limitations of the study:

Endoscope holders can hinder the movement of the surgeon's tools. Sometimes it is necessary to clean the tip of the endoscope, that may become covered or blocked by blood; if the endoscope is fixed; time will be lost during the procedure. Some authors used a cleaning system for the tip of the endoscope via irrigation with saline, trying to overcome this obstacle. Finally, the need for image intensifiers to confirm the surgical tools trajectory maybe routinely used in sellar region surgery with microscopes and by some authors that use the endoscopic approach.

CONCLUSION

Endoscopic endo-nasal trans-sphenoidal pituitary surgery decreases post-op patient discomfort. Also, it has good outcome. The benefits of endoscopic visualization, together with continuous refinement of the endoscopic techniques and instruments as well as the growing experience will allow this method to become the future gold standard surgical approach to pituitary tumors.

REFERENCES

1. Monson JP. The epidemiology of endocrine tumours. *Endocrine-related cancer*, 2000; 7(1):29-36.
2. Teasdale G. Surgical management of pituitary adenoma. *Clinics in endocrinology and metabolism*, 1983; 12(3):789-823
3. Cavallo LM, Dal Fabbro M, Jalalod'din H, et al. Endoscopic endonasal transsphenoidal surgery. Before scrubbing in: tips and tricks. *Surgical neurology*, 2007; 67(4):342-7.
4. Charalampaki P., Ayyad A., Kockro RA, et al. Surgical complications after endoscopic transsphenoidal pituitary surgery. *Journal of Clinical Neuroscience*, 2009; 16 (6):786-89.
5. Laws ER. Complications of transsphenoidal surgery. *In Surgery of the Sellar Region and Paranasal Sinuses*. Springer Berlin Heidelberg 1991; 336-40.
6. Nicola GC, Tonnarelli GP, and Griner AC. Complications of transsphenoidal surgery in pituitary adenomas. *Pituitary Adenomas*. Paris, Asclepios Publishers, 1980; 237-40.
7. Landolt AM. Complications and pitfalls of transsphenoidal pituitary surgery. *Neurosurgeons*, 1984; 4:395-404.
8. Cavallo L, Colao A, Del Basso De Caro M, et al. Endoscopic endonasal transsphenoidal approach: Outcome analysis of 100 consecutive procedures. *Minim Invas Neurosurg*, 2002; 45:193-200.
9. Gamrot J, Zawadzki T, Wojtacha M, et al. Endoscopic Transnasal Transsphenoidal Treatment of Pathology of the Sellar Region. *Minim Invas Neurosurg*, 2005; 48:101-7.
10. Rotariu DI, Faiyad Z, Gaivas S, et al. Pituitary apoplexy management and conditioning factors of outcome. *Acta Endocrinologica*, 2014; 10:1841-987.

11. PalA, CapatinaC, Tenreiro AP, et al. Pituitary apoplexy in non-functioning pituitary adenomas: long term follow up is important because of significant numbers of tumour recurrences. *Clinical endocrinology*, 2011; 75(4), 501-04.
12. VerreesM, ArafahBM, and SelmanWR. Pituitary tumor apoplexy: characteristics, treatment, and outcomes. *Neurosurgical focus*, 2004; 16(4):1-7.
13. Peterson EW. Pituitary apoplexy: a review. *Neurosurgery*, 1984; 14(3):363-73,.
14. RandeVaHS, SchoebelJ, ByrneJ, et al. Classical pituitary apoplexy: clinical features, management, and outcome. *Clinical endocrinology*, 1999; 51(2): 181-88.
15. RecinosPF, GoodwinCR, BremH, et al. Transcranial surgery for pituitary macroadenomas. In *Schmidek and Sweet Operative Neurosurgical Techniques: Indications, Methods, and Results: Sixth Edition, Elsevier In*, .2012; 280-91.
16. Har-El G. Endoscopic transnasal transsphenoidal pituitary surgery--comparison with the traditional sublabial transseptal approach. *Otolaryngol Clin North Am*, 2011; 38(4):723-35,.
17. ThomasRF, MonacciWT, and MairEA. Endoscopic image-guided transtethmoid pituitary surgery. *Otolaryngology—Head and Neck Surgery*, 2002; 127(5), 409-16.
18. RudnikA., ZawadzkiT, WojtachaM, et al. Endoscopic transnasal transsphenoidal treatment of pathology of the sellar region. *min-Minimally Invasive Neurosurgery*, 2005; 48(02):101-07.
19. CappabiancaP, CavalloLM, ColaoA, et al. Endoscopic endonasal transsphenoidal approach: outcome analysis of 100 consecutive procedures. *Min-Minimally Invasive Neurosurgery*, 2002; 45(04):193-200.