

Albumin and Magnetic Resonance Imaging-Liver Volume to Identify Hepatitis C-related Cirrhosis and Esophageal Varices

Said Abd Elbaky Gad Shams El Deen

Department of Internal Medicine, Faculty of Medicine, Zagazig University, Sharkia, Egypt

Corresponding author: Said Abd Elbaky Gad Shams El Deen, Mobile: 01227517689, Email: saidabelbaky12345@gmail.com

ABSTRACT

Background: Liver cirrhosis is the 3rd leading cause of death globally, with increasing mortality rate worldwide portal hypertension is a frequent consequence in the progress of liver cirrhosis and plays a crucial role in the progression of the disease. One of the most serious complications of portal hypertension is the development of esophageal varices.

Objective: To evaluate the changes in the liver lobes volume with that of albumin as non-invasive predictors of liver cirrhosis and esophageal varices. **Patients and methods:** One hundred cases are chosen and classified into four groups as 20 healthy as controls, 20 cases HCV without cirrhosis, 40 cases with cirrhosis but without varices, and 20 cirrhotic cases with varices. All participants undergo magnetic resonance imaging for liver lobes volume, biochemical analysis of serum albumin. All cirrhotic patients are exposed to upper gastro-intestinal endoscopy to differentiate cirrhotic with or without varices. Statistical analysis was done to determine the combination of liver lobes volume change together with albumin changes to predict the severity of cirrhosis and for esophageal varices.

Results: RV, LMV, LLV, and albumin are significantly lower in cases of cirrhosis and LMV/albumin LLV/ALB, CV/Albumin shows a more significant difference in cirrhotics with varices.

Conclusion: From the results of our study we conclude that MRI liver lobes volume and albumin are good predictors noninvasive markers of liver cirrhosis.

Keywords: Liver cirrhosis, Serum albumin, MRI.

INTRODUCTION

Liver cirrhosis is defined as the histological development of regenerative nodules surrounded by fibrous bands in response to chronic liver injury, which leads to portal hypertension and end-stage liver disease. Recent advances in the understanding of the natural history and pathophysiology of cirrhosis, and treatment of its complications⁽¹⁾.

Portal hypertension is a frequent complication of liver cirrhosis, which develops in many patients and plays a role in the development of other complications of the disease. Portal hypertension results in the development of esophagogastric varices which often bleed; and plays a role in the development of ascites, hepatorenal syndrome, and hepatic encephalopathy⁽²⁾.

Therefore, it is important to follow up on the progress of this disease and determine the stage of cirrhosis. The modified Child-Pugh classification system has been confirmed as an independent prognostic factor for the survival of cirrhotic patients and can be utilized to adequately assess liver transplantation candidates^(3,4).

The morphology of the liver changes with the progress of the Child-Pugh classification. Previous studies reported that changes in liver lobe volume were positively correlated with prognosis and Child-Pugh classifications⁽⁴⁾.

Esophageal varices are one of the major complications of liver cirrhosis, with a risk of bleeding from varices of approximately 25%-35%. Prophylactic endoscopic variceal ligation can decrease the incidence of first variceal bleeding and mortality in cirrhotic

patients who have large varices^(5,6). Nevertheless, repeated endoscopic examinations are not accepted for patients and are expensive. As a safe, effective, and repeatable noninvasive modality, magnetic resonance imaging (MRI) has increasingly been used to assess liver diseases^(7,8). Previous studies reported that liver volume indexes measured on MRI could be used as a method for grading the severity of cirrhosis^(9,10).

AIM OF THE WORK

The work aimed to evaluate the changes in the liver lobes volume with that of albumin as non-invasive predictors of liver cirrhosis and esophageal varices.

PATIENTS AND METHODS

Ethical approval:

This study had carried out at the internal medicine and radiology departments of Zagazig University after approval by the institutional human research review committee of our hospital after complete written consent from the participants.

The study included 100 consecutive patients with confirmed cirrhosis in the period between February 2018 and April 2019.

Inclusion criteria:

- Diagnosis of liver cirrhosis due to HCV infection based on history, examination, imaging finding, and histopathological findings, if available according to the American association of study if liver disease practice guidelines on chronic HCV.



This article is an open access article distributed under the terms and conditions of the Creative Commons Attribution (CC BY-SA) license (<http://creativecommons.org/licenses/by/4.0/>)

- All patients chosen in the study underwent a triphasic enhanced MRI scan for the abdomen biochemical wall up and upper GI endoscopy.

Exclusion criteria:

- Patients with previous portal hypertension treatment.
- Portal vein thrombosis.
- Patients with any liver disease causing cirrhosis.
- Patients with hematological malignancies.
- Patients are classified into 3 groups (80 patients):
 - 20 cases with HCV without cirrhosis
 - 40 cases with HCV but with cirrhosis.
 - 20 cases with HCV with cirrhosis and varices.
- Another 20 healthy volunteers without liver disease as control were chosen and exposed to the same of the patient's group.

MRI technique:

Each participant underwent MRI scans supinely with a 3.0-T scanner (Signa Excite; GE Medical Systems, Milwaukee, WI, United States) in an 8-channel phased-array body coil after the establishment of respiratory signals from the diaphragm to the inferior border of the spleen to cover the entire liver. The routine MRI sequences included spoiled gradient recalled T1- and fast recovery fast spin-echo T2-weighted imaging. Subsequently, each patient received an injection of the standard dose (0.2 mmol/kg of body weight) of gadodiamide (Magnevist; Bayer Healthcare, Germany) at a standard flow rate (3 mL/s) through a 21-gauge peripheral venous access followed by a 20-mL saline solution flush. After the previous injection, each participant underwent axial three-dimensional liver acquisition with volume acceleration (3D-LAVA), with a repetition time of 3.9 ms, echo time of 1.8 ms, a field of view of 34 cm × 34 cm, a slice thickness of 5.0 mm, a slice gap of zero and a matrix of 256 mm × 224 mm.

Image data analysis:

The analysis of the original MRI data was performed on a workstation (GE Advantage Workstation Version 4.4-09; Sun Microsystems, Palo Alto, CA, United States). The portal venous phase images were used for the above-mentioned analysis

because the boundary of each liver lobe could be traced more clearly on the portal venous phase than on the arterial or delayed phase ⁽¹¹⁾. As depicted in the Goldsmith and Woodburne system ⁽¹²⁾, the liver comprises four lobes including left lateral and medial lobes, the right lobe, and caudate lobe. Each liver lobe volume was measured retrospectively and independently by two experienced abdominal radiologists without the knowledge of clinical data. On each axial 3D-LAVA image, liver lobe contour was manually drawn, excluding the inferior vena cava and gallbladder, and the cross-sectional area of each liver lobe was automatically calculated by the software ⁽¹³⁾. This previous data analysis on each contiguous transverse level was repeated until the entire liver lobe was covered. Right liver lobe volume (RV), left medial liver lobe volume (LMV), left lateral liver lobe volume (LLV), and caudate lobe volume (CV) were acquired by the sum of the corresponding liver lobe areas × section thickness ⁽¹³⁾. Based on each liver lobe volume and albumin, the ratios of RV to albumin (RV/ALB), of LMV to albumin (LMV/ALB), of LLV to albumin (LLV/ALB), and of CV to albumin (CV/ALB) were calculated.

Statistical analysis

Data collected throughout history, basic clinical examination, laboratory investigations, and outcome measures coded, entered, and analyzed using Microsoft Excel software. Data were then imported into Statistical Package for the Social Sciences (SPSS version 20.0) (Statistical Package for the Social Sciences) software for analysis. According to the type of data qualitative represent as number and percentage, a quantitative continuous group represented by mean ± SD, the following tests were used to test differences for significance, difference, and association of qualitative variable by Chi-square test (X²). Differences between quantitative independent groups by t-test, multiple by ANOVA, ROC curve for cutoff, and validity by sensitivity and specificity. P-value was set at <0.05 for significant results & < 0.001 for high significant result.

RESULTS

Table (1): Age and BMI distribution among studied groups.

		N	Mean	SD	F	P
Age	Control	20	46.1500	2.23077	15.409	0.001**
	HCV	20	49.3500	3.85630		
	HCV + Cirrhosis	40	52.0000	4.90421		
	HCV +Cirrhosis and Varices	20	54.0500*	3.45612		
BMI	Control	20	26.3250	1.69888	1.947	0.211
	HCV	20	25.4650	1.29423		
	HCV + Cirrhosis	40	25.1975	1.19625		
	HCV +Cirrhosis and Varices	20	25.1100	1.25064		

* **Group cause the significance.** Age was distributed among the studied group as 46.15±2.23, 49.35±3.85, 52.0±4.9 and 54.05±3.45 among Control, HCV, HCV + Cirrhosis and HCV +Cirrhosis and Varices respectively and HCV +Cirrhosis and Varices group was significantly older than other groups, and BMI was distributed as 26.32±1.69, 25.46±1.29, 25.19±1.19 and 25.11±1.25 respectively among groups.

Table (2): Sex distribution among studied groups.

			Group				Total	X ²	P
			Control	HCV	HCV+ Cirrhosis	HCV+ Cirrhosis and varices			
Sex	Male	N	13	13	26	14	66	0.17	0.98
		%	65.0%	65.0%	65.0%	70.0%	66.0%		
	Female	N	7	7	14	6	34		
		%	35.0%	35.0%	35.0%	30.0%	34.0%		
Total		N	20	20	40	20	100		
		%	100.0%	100.0%	100.0%	100.0%	100.0%	100.0%	

Males were the majority of the studied group.

Table (3): Liver volume and albumin and volume / Albumin ratio distribution among the studied group.

		N	Mean	SD	F	P
RV	Control	20	851.8500	59.16727	123.403	0.001**
	HCV	20	752.8000	74.51570		
	HCV + Cirrhosis	40	640.6500	65.74135		
	HCV +Cirrhosis and Varices	20	473.0000	63.50300		
LMV	Control	20	265.3500	17.22689	246.517	0.001**
	HCV	20	229.5000	24.97683		
	HCV + Cirrhosis	40	176.6250	7.83381		
	HCV +Cirrhosis and Varices	20	154.1000	9.64038		
LLV	Control	20	249.8000	20.23442	17.239	0.001**
	HCV	20	222.7500	12.79751		
	HCV + Cirrhosis	40	223.5500	16.91752		
	HCV +Cirrhosis and Varices	20	213.0000	17.82370		
CV	Control	20	22.9000	1.69830	2.544	0.098
	HCV	20	23.0000	2.02614		
	HCV + Cirrhosis	40	23.7000	1.85085		
	HCV +Cirrhosis and Varices	20	23.1500	1.83174		
Albumin	Control	20	4.3400	.21126	159.098	0.001**
	HCV	20	4.2400	.20876		
	HCV + Cirrhosis	40	3.3425*	.43846		
	HCV +Cirrhosis and Varices	20	2.4300#	.18382		
RV/ALB	Control	20	196.5877	15.26316	1.354	0.222
	HCV	20	191.3407	23.10084		
	HCV + Cirrhosis	40	193.0401	18.00829		
	HCV +Cirrhosis and Varices	20	195.3189	27.53705		
LMV/ALB	Control	20	55.1637	3.21298	12.810	0.001**
	HCV	20	54.3432	7.19668		
	HCV + Cirrhosis	40	53.8120	8.09390		
	HCV +Cirrhosis and Varices	20	63.7698	6.29414		
LLV/ALB	Control	20	57.4989	2.62685	130.782	0.001**
	HCV	20	52.7915	5.62479		
	HCV + Cirrhosis	40	67.6081	6.84201		
	HCV +Cirrhosis and Varices	20	87.8817	7.27890		
CV/ALB	Control	20	5.1786	.53142	202.657	0.001**
	HCV	20	5.4393	.56483		
	HCV + Cirrhosis	40	7.3781	.71280		
	HCV +Cirrhosis and Varices	20	9.3719	.54067		

RV: Right liver lobe volume; LMV: Left medial liver lobe volume; LLV: Left lateral liver lobe volume; CV: Caudate lobe volume; ALB: Albumin

*** & # Group cause the significance**

RV and LMV significantly lower in varices than cirrhosis, HCV cases, and significantly higher among control regard LLV control group were significantly higher than other groups and 4th group were significantly lower than other groups with no significant difference between 2nd and 3rd groups, there was no significant

difference regard CV, albumin was similar in 1st two groups and sig higher among them than 3rd and 4th group and 4th group was sig lower than 3rd, regard ration no sig found regard RV/ ALB, Regard LMV/ALB only last group was sig higher than other three groups with no significant difference among them, regard LLV/ALB and CV/ALB, 3rd group was sig higher than 1st and 2nd and 4th group sig higher than others,

Table (4): Comparison between HCV and control.

	HCV	Mean	SD	t	P
RV	Control	851.8500	59.16727	8.084	0.001**
	HCV	626.7750	120.59746		
LMV	Control	265.3500	17.22689	11.145	0.001**
	HCV	184.2125	31.31494		
LLV	Control	249.8000	20.23442	6.685	0.001**
	HCV	220.7125	16.65145		
CV	Control	22.9000	1.69830	-1.523-	0.083
	HCV	23.2375	2.02043		
Albumin	Control	4.3400	.21126	6.076	0.001**
	HCV	3.3388	.72679		
RV/ALB	Control	196.5877	15.26316	1.238	0.219
	HCV	189.9349	22.73914		
LMV/ALB	Control	55.1637	3.21298	1.033	0.241
	HCV	56.4342	8.51685		
LLV/ALB	Control	57.4989	2.62685	-3.589	0.001**
	HCV	68.9724	14.18487		
CV_ALB	Control	5.1786	.53142	-6.334	0.001**
	HCV	7.3918	1.53480		

RV, LMV, LLV, and Albumin were sig lower in cases and LLV/ALB and CV_ALB were sig higher among HCV cases

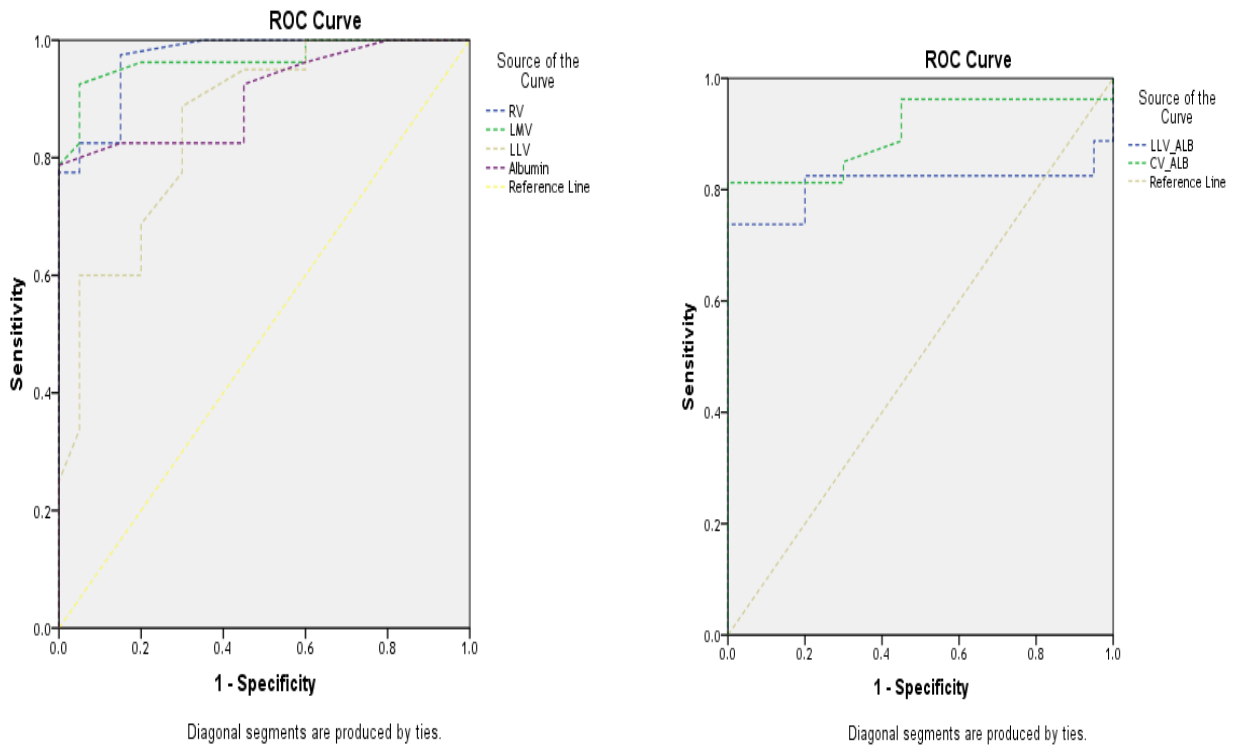


Fig. (1): ROC Curve for cutoff regard HCV.

Table (5): AUC and validity of parameters regard HCV

Test Result Variable(s)	Area	Std. Error ^a	P	95% Confidence Interval		Sensitivity	Specificity
				Lower Bound	Upper Bound		
RV	0.969	<811	0.001**	.935	1.000	98.2%	83.3%
LMV	0.967	<246.5	0.001**	.935	.999	93.3%	95.5%
LLV	0.858	<235.5	0.001**	.765	.951	85.5%	78.8%
Albumin	0.906	<4.22	0.001**	.849	.964	90.0%	60.0%
LLV_ALB	.811	>60.5	0.001**	.728	.894	85.8%	79.8%
CV_ALB	.903	>5.9	0.001**	.845	.962	83.0%	78.8%

Showing cutoffs and validity.

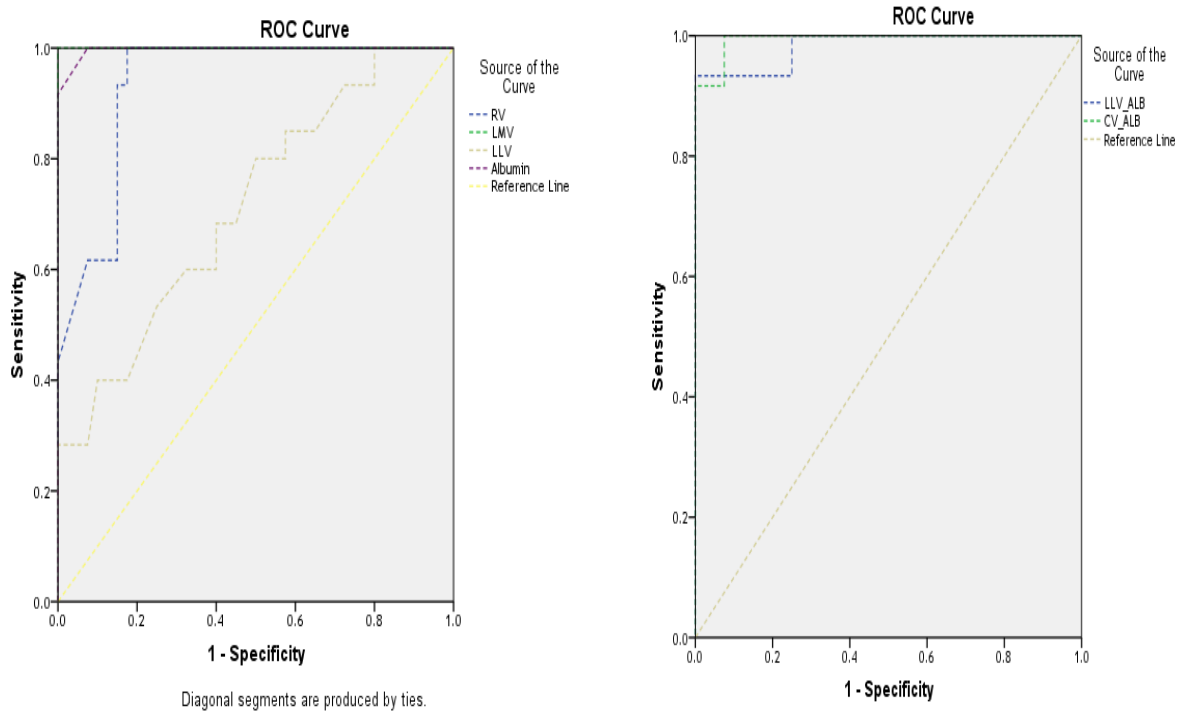


Fig. (2): ROC Curve for Cirrhosis cutoffs.

Table (6): AUC and validity of parameters regard Cirrhosis.

Test Result Variable(s)	Area	Cutoff	P	95% Confidence Interval		Sensitivity	Specificity
				Lower Bound	Upper Bound		
RV	.934	<692	0.001**	.882	.986	96.6%	89.8%
LMV	1.000	<195	0.001**	1.000	1.000	100.0%	100.0%
LLV	.714	<234.5	0.001**	.614	.814	80.0%	55.0%
Albumin	.997	<3.85	0.001**	.991	1.000	99.0%	98.0%
LLV_ALB	.983	>62.9	0.001**	.965	1.000	94.8%	92.8%
CV_ALB	.994	>6.2	0.001**	.985	1.000	95.0%	83.3%

Showing cutoffs and validity

Table (7): Comparison between varices and no varices.

	Varices	Mean	Std. Deviation	t	P
RV	-VE	721.4875	110.31910	9.657	0.001**
	+VE	473.0000	63.50300		
LMV	-VE	212.0250	41.02947	6.248	0.001**
	+VE	154.1000	9.64038		
LLV	-VE	229.9125	20.31660	3.407	0.001**
	+VE	213.0000	17.82370		
CV	-VE	23.3500	2.03700	1.601	0.113
	+VE	22.7500	1.83174		
Albumin	-VE	3.8163	.58709	10.398	0.001**
	+VE	2.4300	.18382		
RV/ALB	-VE	190.2521	19.86175	-0.940	0.350
	+VE	195.3189	27.53705		
LMV/ALB	-VE	55.7827	7.55656	-4.359	0.001**
	+VE	63.7698	6.29414		
LLV/ALB	-VE	61.3767	8.63172	-12.642	0.001**
	+VE	87.8817	7.27890		
CV/ALB	-VE	6.3435	1.21980	-10.808	0.001**
	+VE	9.3719	.54067		

RV, LMV, LLV, and Albumin were sig lower in cases and LMV/ALB, LLV/ALB, and CV_ALB were sig higher among Cirrhosis cases

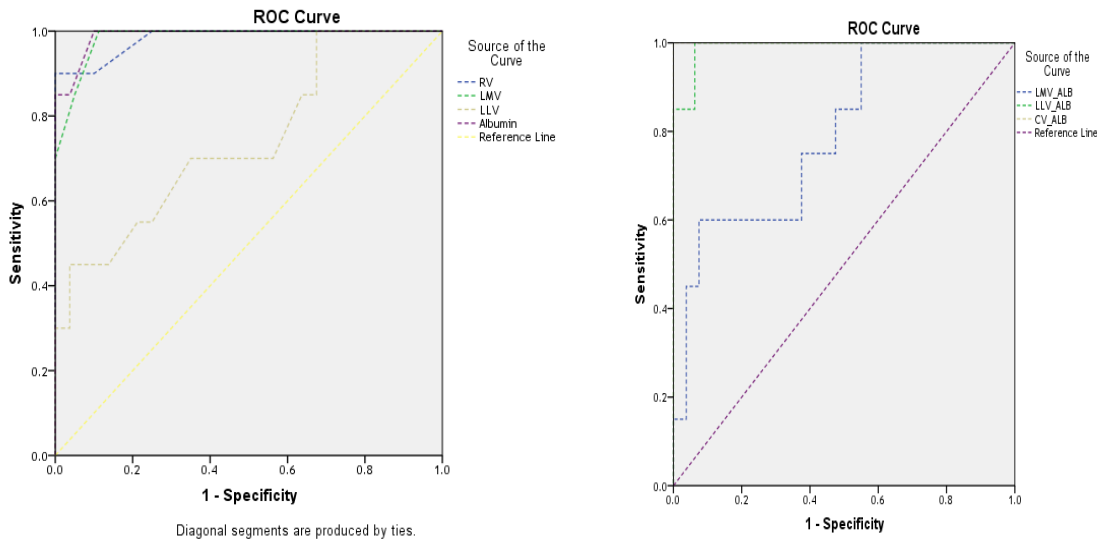


Fig. (3): ROC Curve for varices cutoffs.

Table (8): AUC and validity of parameters regard varices.

Test Result Variable(s)	Area	Cutoffs	P	95% Confidence Interval		Sensitivity	Specificity
				Lower Bound	Upper Bound		
RV	.983	<584	0.001**	.957	1.000	94.2%	92.2%
LMV	.984	<167	0.001**	.966	1.000	95.0%	90.0%
LLV	.741	<216	0.001**	.613	.868	75.0%	67.6%
Albumin	.990	<2.78	0.001**	.975	1.000	93.3%	94.8%
LMV_ALB	.791	>62.5	0.001**	.684	.899	78.2%	66.7%
LLV_ALB	.991	>79.0	0.001**	.977	1.000	98.2%	94.0%
CV_ALB	1.000	>8.17	0.001**	1.000	1.000	99.0%	98.0%

Showing cutoffs and validity.

DISCUSSION

Liver cirrhosis is the end stage wound healing response to chronic liver injury with consequent liver cell failure, hepatocellular carcinoma (3, 10). It is the 3rd cause of death worldwide (14). One of the most serious complications of portal hypertension is oesophageal varices that produced by increased intrahepatic vascular resistance due to fibrosis and regenerative nodules (10, 15). Rupture of varices is these that fatal complication of cirrhosis that needs regular periodic follow up of documented cirrhosis by endoscopy which is an invasive maneuver need special precautions (12).

HCV is a worldwide public health problem Egypt is considered one of the countries with higher prevalence with consequent cirrhosis (8, 16).

In our study, we tried to introduce non-invasive modalities to predict the severity of cirrhosis and esophageal varices (10).

Study of the utility of MRI liver lobes volume and changes in albumin level to determine the presence of cirrhosis and find that there is a significant difference between control, HCV without cirrhosis, HCV with cirrhosis and HCV with cirrhosis and various in the age group of the population is the risk of cirrhosis and varices is increased with age which is in agreement in a study done by **Schiano et al.** (17) but no significant changes as regard body mass index, our study has shown a high prevalence of cirrhosis and varies with male groups. A study done by **Li et al.** (11) found RLV and LMV are significantly small in varices>cirrhosis >HCV which is in agreement with our results. LLV was significantly lower than in cirrhosis with varices other groups serum albumin level was normal in CONTROL and HCV without cirrhosis and gradual significant decrease from group cirrhosis without varices into cirrhosis with varices the same results obtained by **Bintintan et al.** (18).

As cirrhosis begins hypertrophy of lateral liver lobe and caudate lobe reaches maximum then the two hypertrophied lobes begin to atrophy as cirrhosis progress (8, 12). As regard RLV, LMV, LLV, and albumin show lower significance but LLV/ ALB and CLV/Alb were high significances among cirrhotic which is in agreement with **Alempijevic et al.** (16) the same results **Talwalkar et al.** (7), **Chen et al.** (14) on using ultrasonography to albumin in ratio. AUC curve regards HCV, liver lobes show cutoffs and validity with P. 0.00 in the comparison between cirrhotics and non-cirrhotic there is a significant difference between liver lobes volumes and albumin as regard cirrhotics which is correlated with the same results obtained by **Li et al.** (11). As regard cirrhosis, our study has shown the validity of parameters with AUC 0.093.

There is marked significant differences in liver lobes volume and albumin in cirrhosis with varices

other than cirrhosis only as regard ROC curve for varices AUC under the curve show validity (P. 0.00) which is in close association with previous studies as **Esmat et al.** (19).

CONCLUSION

From the results of our study, we conclude that MRI liver lobes volume and albumin are good predictors of noninvasive markers of liver cirrhosis.

REFERENCES

1. **Schuppan D, Afdhal NH (2008):** Liver Cirrhosis. *Lancet*, 371(9615): 838–851.
2. **Naeije R (2003):** Hepatopulmonary syndrome and portopulmonary hypertension. *Swiss Med Wkly.*, 133: 163-169.
3. **Durand F, Valla D (2005):** Assessment of the prognosis of cirrhosis: Child-Pugh versus MELD. *J Hepatol.*, 42:100–107.
4. **Zhou XP, Lu T, Wei YG, Chen XZ (2007):** Liver volume variation in patients with virus-induced cirrhosis: findings on MDCT. *AJR Am J Roentgenol.*, 189:153–159.
5. **Alempijevic T, Bulat V, Djuranovic S, Kovacevic N, Jesic R, Tomic D, Krstic S, Krstic M (2007):** Right liver lobe/albumin ratio: contribution to non-invasive assessment of portal hypertension. *World J Gastroenterol.*, 13:5331–5335.
6. **Psilopoulos D, Galanis P, Goulas S, Papanikolaou IS, Elefsiniotis I, Liatsos C, Sparos L, Mavrogiannis C (2005):** Endoscopic variceal ligation vs. propranolol for prevention of first variceal bleeding: a randomized controlled trial. *Eur J Gastroenterol Hepatol.*, 17:1111–1117.
7. **Talwalkar JA, Yin M, Fidler JL, Sanderson SO, Kamath PS, Ehman RL (2008):** Magnetic resonance imaging of hepatic fibrosis: emerging clinical applications. *Hepatology*, 47:332–342.
8. **Taouli B, Ehman RL, Reeder SB (2009):** Advanced MRI methods for assessment of chronic liver disease. *AJR Am J Roentgenol.*, 193:14–27.
9. **Ito K, Mitchell DG, Hann HW, Kim Y, Fujita T, Okazaki H, Honjo K, Matsunaga N (1999):** Viral-induced cirrhosis: grading of severity using MR imaging. *AJR Am J Roentgenol.*, 173:591–596.
10. **Ito K, Mitchell DG, Hann HW, Outwater EK, Kim Y (1997):** Compensated cirrhosis due to viral hepatitis: using MR imaging to predict clinical progression. *AJR Am J Roentgenol.*, 169:801–805.
11. **Li H, Chen TW, Zhang XM, Li ZL, Zhang JL, Wang D, Li T, Wu JL, Guo X, Chen XL (2013):** Liver lobe volumes and the ratios of liver lobe volumes to spleen volume on magnetic resonance imaging for staging liver fibrosis in a minipig model. *PLoS One*, 8:79681.
12. **Goldsmith NA, Woodburne RT (1957):** The surgical anatomy of liver resection. *Surg Gynecol Obstet.*, 105:310–318.
13. **Mazonakis M, Damilakis J, Maris T, Prassopoulos P, Gourtsoyiannis N (2002):** Comparison of two volumetric techniques for estimating liver volume using magnetic resonance imaging. *J Magn Reson Imaging*, 15:557–563.

14. **Chen XL, Chen TW, Li ZL, Zhang XM, Chen N, Zeng NL, Li H, Tang HJ, Pu Y, Li CP (2013):** Spleen size measured on enhanced MRI for quantitatively staging liver fibrosis in minipigs. *J Magn Reson Imaging*, 38: 540-547.
15. **Cho KC, Patel YD, Wachsberg RH, Seeff J (1995):** Varices in portal hypertension: evaluation with CT. *Radiographics*, 15: 609-622.
16. **Alempijevic T, Kovacevic N (2007):** Right liver lobe diameter albumin ratio: a new non-invasive parameter for prediction of oesophageal varices in patients with liver cirrhosis (preliminary report). *Gut*, 56: 1166-1167.
17. **Schiano TD, Bodian C, Schwartz ME, Glajchen N, Min AD (2000):** Accuracy and significance of computed tomographic scan assessment of hepatic volume in patients undergoing liver transplantation. *Transplantation*, 69: 545-550.
18. **Bintintan A, Chira RI, Mircea PA (2013):** Non-invasive ultrasound-based diagnosis and staging of oesophageal varices in liver cirrhosis. A systematic review of the literature published in the third millennium. *Med Ultrason.*, 15:116–124.
19. **Esmat S, Omarn D, Rashid L (2012):** Can we consider the right hepatic lobe size/albumin ratio a noninvasive predictor of oesophageal varices in hepatitis C virus-related liver cirrhotic Egyptian patients? *Eur J Intern Med.*, 23: 267-272.