

Pretreatment Renal Biopsy Findings as a Predictor of Post Treatment Renal Function in Patients with Hepatitis C Virus Associated Nephropathy: A Prospective Study

Marwa K. Khairallah¹, Effat A. E. Tony¹, Mohamed A. Tohamy¹, Mahmoud Essmat²

¹Internal Medicine Department, Assuit University Hospital and

²Nephrology Unit, Assuit General Hospital, Assuit, Egypt

*Corresponding author: Marwa K. Khairallah, Institution: Assiut University Hospital, Department of Internal medicine,

EMAIL: marwa.kamal82@hotmail.com, MOBILE: (+20)01097878113

ABSTRACT

Background: Renal histopathological patterns are established predictors of outcomes in many disorders. However, its role in predicting outcomes in hepatitis C virus (HCV)-associated nephropathy has not been elucidated yet. The preset study aimed to assess utility of biopsy in predicting post treatment renal functions in HCV-associated nephropathy patients. **Patients and Methods:** Prospective study included HCV 30 nephropathy-established patients, recruited from Nephrology Unit of Internal Medicine Department from September 2016 to September 2017. Ultrasound-guided, percutaneous, needle biopsy was utilized to obtain the renal samples.

Results: Commonest form of HCV-associated glomerular disease was membranoproliferative (43.3%), followed by membranous glomerulonephritis (16.7%). Focal segmental glomerulosclerosis (FSGS), crescentic glomerulonephritis (CGN), and cryoglobulinemic were equally presented in 13.3% of the patients, each. Interstitial fibrosis was found in (73.3%), tubular atrophy in (70%), glomerular sclerosis in (46.7%), and arteriosclerosis in (33.3%). Twelve weeks after new antiviral therapy, patients with moderate tubular atrophy exhibited statistically significant higher reductions in serum creatinine and urea levels than patients with severe form (-1.13 ± 0.45 versus -0.71 ± 0.56 mg/dL and -9.98 ± 1.67 versus -4.01 ± 4.02 mg/dL, respectively; $p = 0.01$). No significant difference between both groups was noted regarding 24-hours urinary protein and e-GFR. Patients with mild and moderate interstitial fibrosis and arteriosclerosis exhibited statistically significant higher reductions in serum creatinine and urea levels. Tubular atrophy and Interstitial fibrosis significantly affect post treatment serum creatinine and urea ($p < 0.05$).

Conclusion: Pretreatment renal histopathology significantly influence post treatment renal functions in HCV nephropathy patients.

Keywords: Hepatitis C Virus Glomerulopathies; Renal Biopsy; Viral Response; Direct-acting antiviral.

INTRODUCTION

Recent decade has witnessed major advances regarding controlling hepatitis C virus (HCV) infection. Nonetheless, recent figures demonstrated that seroprevalence of HCV is still increasing, especially in the Eastern Mediterranean and European Regions, with an estimated global prevalence of 2.5%^(1,2). Egypt has the highest prevalence rate of HCV worldwide with approximately 2 to 6 new cases per 1000 population every year⁽³⁾. Despite being largely asymptomatic in acute stage, chronic HCV is associated with a significant risk of liver-related complications⁽⁴⁾. Recently, up to 30% of patients with chronic HCV was reported to have liver cirrhosis, while prevalence of decompensated liver failure is 11%⁽⁵⁾; moreover, chronic HCV is documented to be the leading risk factor for hepatocellular carcinoma (HCC)⁽⁶⁾. In addition, mortality rates secondary to chronic HCV showed a notable increase from 2006 to 2010⁽⁵⁾. Chronic HCV represents a financial burden, in global levels, as well⁽⁷⁾.

Renal outcomes are common extra hepatic complications of chronic HCV, patients with HCV

exhibited an increased risk of proteinuria, chronic kidney disease, and need for permanent hemodialysis⁽⁸⁾. While the exact pathogenesis of HCV-associated kidney disease has not been fully elucidated yet, previous reports demonstrated that hepatitis virus binding to receptors in mesangial and epithelial cells is a major contributor to proteinuria⁽⁹⁾. Other mechanisms include development of mixed cryoglobulinemia and overexpression of Toll-like receptors⁽¹⁰⁾. Although membranoproliferative glomerulonephritis (MPGN) is the commonest renal pathology injury, other patterns were reported including glomerulonephritis, membranous nephropathy, glomerulosclerosis, and tubular atrophy⁽¹¹⁾.

Historically, a combination of pegylated-interferon and ribavirin were the main therapy for chronic HCV with reported low rates of sustained virological response (SVR) (less than 50%) but high rates of severe adverse events⁽¹²⁾. However, since the usage of direct-acting antivirals (DAAs), tremendous achievements in treatment and outcomes of chronic HCV had been noticed. DAA medications, with or



This article is an open access article distributed under the terms and conditions of the Creative Commons Attribution (CC BY-SA) license (<http://creativecommons.org/licenses/by/4.0/>)

without ribavirin, exhibited a well-tolerable safety profile with high efficacy; according to current published literature, all oral DAAs for chronic HCV genotype 1 and 3 achieved high cure rates of almost 90% in clinical practice^(13,14). For genotype 4, a daily regimen of ledipasvir 90 mg and sofosbuvir 400 mg for 12 weeks exhibited high SVR rates and it is recommended in patients with or without compensated cirrhosis⁽¹⁵⁾. In addition, recent reports demonstrated that DAA led to improvement in renal functions in HCV-associated kidney disease⁽¹⁶⁾.

However, the role of renal histopathology in predicting renal functions in patients with HCV-associated nephropathy has not been elucidated yet. The preset study aimed to assess the utility of renal biopsy in predicting post treatment renal functions in patients with HCV-associated nephropathy.

PATIENTS AND METHODS

Thirty patients were included in a prospective observational study, which was conducted in Outpatient Clinic of Renal Unit of Internal Medicine Department, Assiut University Hospital in the period of September 2016 to September 2017. HCV patients were included if they had evidence of stage I-III CKD or proteinuria (24 hours urinary proteins > 150 mg/day). Patients who refused to sign the informed consent or patients with concomitant hepatitis B infection, non-HCV related kidney disease, advanced liver cirrhosis, HCC, diabetes mellitus, autoimmune disease, patients on steroids or immunosuppressive drugs, and/or patients with contraindications to renal biopsy were excluded.

The present study was a post-hoc analysis about our previously published study about the post treatment hepatic and renal outcomes following DAA therapy in patients with HCV-associated nephropathy⁽¹⁶⁾.

Ethical approval:

The protocol of the present study gained the approval of the Ethics Committee of Assiut University Hospital. (Code number is: IRB: 17/00412), which is compelled to the ethical standards of the declaration of Helsinki and applicable local regulatory laws. Informed consents were obtained by all included patients.

Pretreatment Data Collection:

The following data were collected from all eligible participants at the start of the study: Demographic characteristics, history and characteristics of CKD, complete blood count (CBC), renal function tests, liver function tests, PCR for HCV infection, HCV Ab, HBsAg, HIV, rheumatoid factor by ELISA, antinuclear antibody, hemoglobin A1C, urine analysis by dipstick and microscopic examination, 24 h urinary

protein or ACR, C3 and C4 levels in serum by immunoturbidimetric method and findings of pretreatment renal biopsy.

Renal Biopsy:

Renal samples were obtained by percutaneous needle biopsy under the vision of ultrasound scanner (GE V5 American) in Interventional Nephrology Unit, Assiut University Hospital by staff members of nephrology. For light microscopy, paraffin sections were stained with hematoxylin and eosin, and then microscopic histopathological lesions were classified according to presence of tubular atrophy, interstitial fibrosis, arteriolosclerosis and glomerulosclerosis. These lesions were classified into mild, moderate and severe lesions.

All patients enrolled in the study were positive HCV Ab, positive HCV RNA by PCR, negative HBsAg and HIV, positive rheumatoid factor, negative antinuclear antibody, and normal hemoglobin A1C to exclude other causes of nephropathy.

Treatment and Follow-up:

Treatment regimens were one of two, sofosbuvir, daclatasvir with ribavirin (in 60% of the patients) or ombitasvir, ritonavir, paritaprevir, and ribavirin in the rest of the patients. Regimens were continued for twelve months. Following twelve weeks of treatment end, the patients were followed-up and the laboratory investigations were repeated.

Statistical Analysis

The SPSS version 20.0 (SPSS Inc., Chicago, Illinois, USA) was used for data analysis. The continuous and dichotomous data were summarized in the form of the quantitative mean± standard deviation (SD) and frequency (percentages), respectively. The association between continuous and dichotomous data was examined by independent-samples t-test or Mann-Whitney test. But the association between categorical variables was assessed by chi-square or Fisher's exact tests. Logistic regression analysis was conducted to assess the predictor of post treatment renal functions. A p value < 0.05 was significant.

RESULTS

The present study included 30 patients with a mean age of 52 years old and male predominance. The mean body mass index was 28.48 Kg/m². Almost one-third of the patients were illiterate. Three patients were presented with purpura and hematuria was positive in nine patients. Regarding comorbidities, four patients had ischemic heart disease. The pretreatment laboratory characteristics are shown in table 1.

Table (1): Baseline data of studied groups

Variables	Patients (n= 30)
Age (year), Mean ±SD	52.18 ± 8.72
Male, No. (%)	21 (70%)
Systolic blood pressure (mmHg), Mean ±SD	117.24 ± 9.21
Diastolic blood pressure (mmHg), Mean ±SD	72.75 ±7.51
Body mass index (BMI) (Kg/m²), Mean ±SD	28.48 ±2.27
Urban Residency, No. (%)	12 (40%)
Intravenous drug users, No. (%)	3 (10%)
Purpura	3 (10%)
Hematuria (>= 6/HPF)	9 (30%)
Other comorbidities, No. (%)	
- Ischemic heart disease	4 (13.3%)
- Chronic obstructive lung disease	3 (10%)
- Cerebrovascular stroke	2 (6.7%)
Complete blood picture, Mean ±SD	
Hemoglobin (g/dl)	13.2 ± 2.2
Platelets (x10 ³ /l)	223.12 ± 54.67
Leucocytic count (x10 ³ /l)	6.22 ± 1.45
MCV (fL)	87.98 ± 10.13
Liver function tests. Mean ±SD	
Total bilirubin (mg/l)	0.81 ± 0.16
Direct bilirubin (mg/l)	0.26 ± 0.05
Alanine transaminase (U/L)	72.23 ± 10.31
Aspartate transaminase (U/L)	75.63 ± 13.92
Serum albumin (mg/dl)	34.96 ± 1.4
Total protein (mg/dl)	85 ± 4.8
Alkaline phosphatase (U/L)	123.98 ± 9.8
Coagulation profile, Mean ±SD	
PT (seconds)	11.03 ± 1.9
PC (%)	97.5 ± 4.61
INR	1.01 ± 0.01
Renal function tests, Mean ±SD	
Blood urea nitrogen (mg/dl)	13.16 ± 5.52
Serum creatinine (mg/dl)	3.85 ± 1.07
24h-urinary protein (mg)	1597.34 ± 527.38
eGFR(ml/m/1.73m ²)	54.46 ± 10.15

With regard to glomerular disease, the most frequent form of HCV-associated glomerular disease was membranoproliferative type, followed by membranous glomerulonephritis. The focal segmental glomerulosclerosis (FSGS), crescentic glomerulonephritis (CGN), and cryoglobulinemic type were equally presented in the patients (Figure 1). With regard to renal histopathology pattern, we observed interstitial fibrosis in 22 patients, tubular atrophy in 21 patients, glomerular sclerosis in 14 patients, and arteriosclerosis in 10 patients (Figure 2).

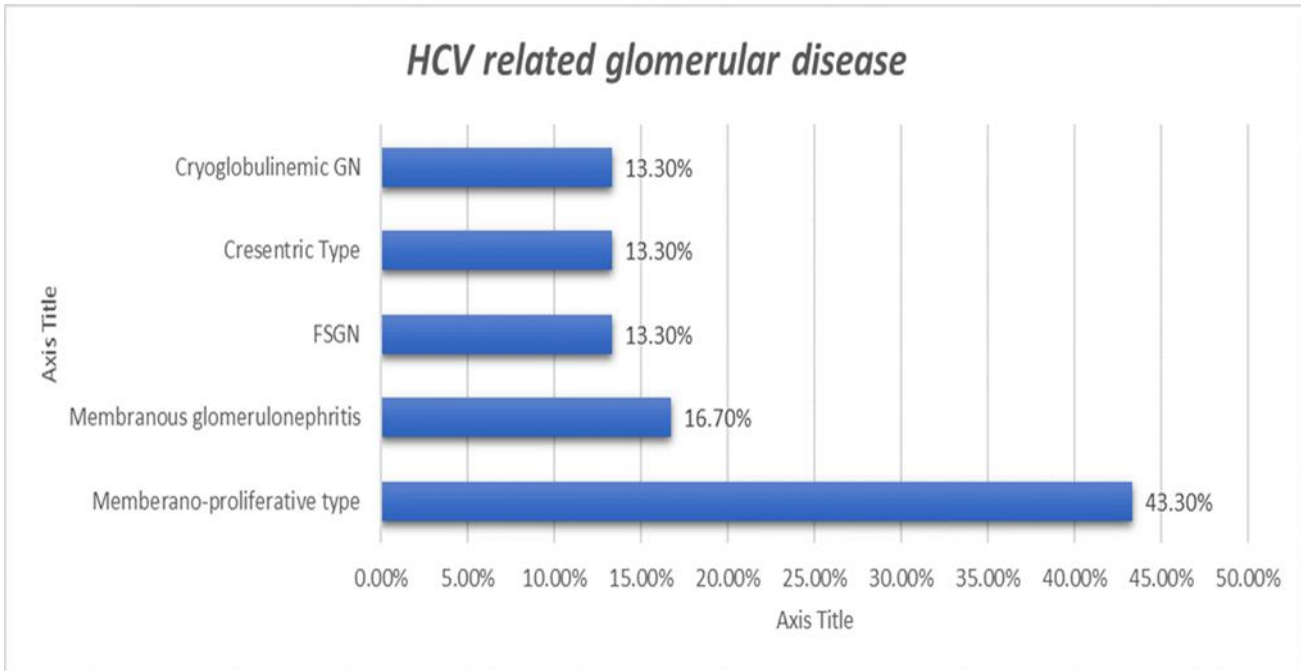


Figure (1): Types of HCV-related glomerular disease in our studied patients.

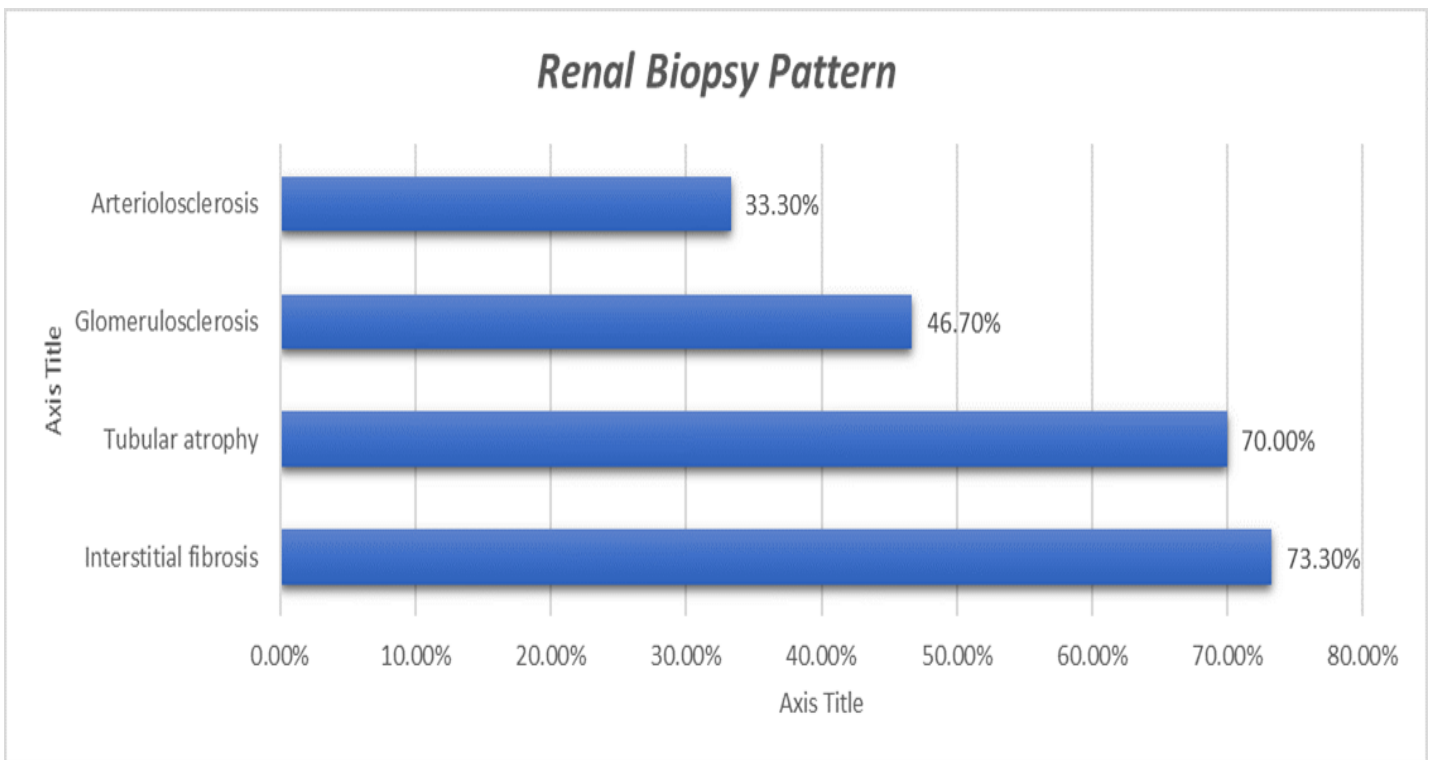


Figure (2): Pattern of Renal Histopathology in renal biopsy by light microscopy in our patients.

Pretreatment, patients with CGN and cryoglobulinemia had significantly higher serum urea level than other groups. Likewise, they had significantly higher serum creatinine level, and higher 24h-urinary protein and e-GFR than other groups. Notably, patients with severe degree of tubular atrophy exhibited significantly higher level of serum urea and serum creatinine than moderate and mild degree; while they had higher e-GFR and 24h-urinary proteins. The severe degree of interstitial fibrosis on light microscopy in biopsy was associated with the higher mean level of serum urea and serum creatinine than moderate and mild degree with significant difference. Similarly, the severe degrees of arteriosclerosis and glomerulosclerosis on light microscopy in biopsy were associated with the higher mean level of serum urea and serum creatinine than moderate and mild degree with significant difference (Table 2).

Table (2): Renal functions based on HCV-related glomerular disease and patterns of renal biopsy findings

	Urea (mg/dl)	Creatinine (mg/dl)	24h-urinary protein (mg/d)	eGFR (ml/m/1.73m ²)
HCV-related glomerular disease	17.15± 0.92	6.05± 0.99	1307.13±256.67	34.11±9.45
Crescentic GN	15.19±7.12	5.80± 2.01	1399.22±221.54	44.40± 7.83
Cryoglobulinemic N	13.01±4.02	3.05± 1.44	1447.11±399.11	53.87± 10.09
Membranous GN	10.67±3.55	2.85± 1.77	1507.01±427.01	59.54 ± 8.88
FSGS.	8.98 ± 1.67	2.15± 1.90	1707.04±321.22	66.11 ± 6.89
Memberano-proliferative GN				
P value	0.01	0.03	0.01	0.04
Tubular atrophy				
Mild	7.91 ± 2.02	1.11± 0.99	1691.45 ± 301.45	60.80 ± 7.83
Moderate	13.19 ± 2.52	4.90± 2.03	1456.11 ± 299.11	50.87 ± 10.54
Severe	18.15 ± 2.55	6.99 ± 0.97	1307.01 ± 345.76	45.54 ± 9.88
P value	0.01	0.04	0.01	0.01
Interstitial fibrosis				
Mild	8.18 ± 2.78	2.17± 0.94	1606.41 ± 301.51	66.01 ± 5.45
Moderate	14.02 ± 3.12	5.00± 2.19	1450.34 ± 311.23	48.53 ± 9.99
Severe	17.01 ± 2.65	6.01 ± 1.07	1311.01 ± 325.11	41.09 ± 8.64
P value	0.01	0.03	0.04	0.01
Arteriosclerosis				
Mild	8.16 ± 2.39	2.02± 1.01	1616.87 ± 321.76	59.33 ± 5.05
Moderate	14.07 ± 3.22	5.90± 1.08	1534.10 ± 309.45	50.09 ± 10.11
Severe	18.00 ± 2.52	6.01 ± 0.87	1322.65± 300.15	45.54 ± 7.45
P value	0.01	0.03	0.02	0.03
Glomerulosclerosis				
Mild	8.45 ± 2.55	1.02 ± 1.95	1614.19 ± 319.87	59.30 ± 5.45
Moderate	13.87 ± 4.02	5.01 ± 2.17	1439.10 ± 356.22	49.56 ± 9.44
Severe	17.31 ± 5.02	6.93 ± 1.11	1302.11± 311.45	44.71 ± 6.66
P value	0.01	0.02	0.01	0.04

Data are expressed in form of mean±SD.

FSGS: focal segmental glomerulosclerosis, **GN:** glomerulonephritis, **eGFR:** estimated glomerular filtration rate

Patients with moderate tubular atrophy exhibited statistically significant higher reductions in serum creatinine and serum urea levels than patients with severe form; while no significant differences were detected between mild and moderate tubular atrophy groups regarding the changes in serum creatinine and serum urea. No significant difference between different degrees of tubular atrophy were noted regarding 24-hours urinary protein and eGFR. On the other hand, patients with moderate interstitial fibrosis and arteriosclerosis exhibited statistically significant higher reductions in serum creatinine and serum urea levels than patients with severe form. Again, no significant differences were noted between mild and moderate degrees of interstitial fibrosis and arteriosclerosis (Table 3).

Table (3): The changes in renal functions based on HCV-related glomerular disease and patterns of renal biopsy findings.

	Urea (mg/dl)	Creatinine (mg/dl)	24h-urinary protein (mg/d)	eGFR ml/m/1.73m ²
Tubular atrophy				
Mild	-3.01 ± 1.02	-0.42 ± 0.21	-914.45 ± 231.6	10.3 ± 2.45
Moderate	-9.98 ± 1.67	-1.13 ± 0.45	-832.1 ± 301.4	12.67 ± 9.8
Severe	-4.01 ± 4.02	-0.71 ± 0.56	-703.2 ± 298.7	5.9 ± 10.2
P value	0.01	0.01	0.205	0.09
Interstitial fibrosis				
Mild	-4.15 ± 2.1	-0.67 ± 0.72	-606.41 ± 301.51	10.3 ± 5.45
Moderate	-10.58 ± 3.12	5.00 ± 2.19	-450.34 ± 311.23	8.53 ± 9.99
Severe	-3.67 ± 5.42	6.01 ± 1.07	-311.01 ± 325.11	7.09 ± 8.64
P value	0.01	0.01	0.42	0.52
Arteriolosclerosis				
Mild	-3.16 ± 2.39	-0.62 ± 0.11	-616.87 ± 321.76	59.33 ± 5.05
Moderate	-7.14 ± 3.22	-1.9 ± 0.18	-534.10 ± 309.45	50.09 ± 10.11
Severe	-2.8 ± 2.52	-0.12 ± 0.87	-622.65 ± 300.15	45.54 ± 7.45
P value	0.01	0.01	0.32	0.03
Glomerulosclerosis				
Mild	8.45 ± 2.55	1.02 ± 1.95	-614.19 ± 319.87	59.30 ± 5.45
Moderate	13.87 ± 4.02	5.01 ± 2.17	-539.10 ± 356.22	49.56 ± 9.44
Severe	17.31 ± 5.02	6.93 ± 1.11	-602.11 ± 311.45	44.71 ± 6.66
P value	0.01	0.01	0.67	0.04

Data are expressed in form of mean±SD.

FSGS: focal segmental glomerulosclerosis **GN:** glomerulonephritis **eGFR** estimated glomerular filtration rate

The regression analysis demonstrated that severe tubular atrophy was significant predictor of post treatment serum urea and creatinine. Likewise, the severe interstitial atrophy was significant predictor of post treatment serum urea and creatinine. The same findings were observed for severe arteriolosclerosis (Table 4).

Table (4): Univariate analysis for the parameters affecting post treatment renal functions

Variables	Urea (mg/dl)		Creatinine (mg/dl)		24h-urinary protein (mg/d)		eGFR (ml/m/1.73m ²)	
	B (95%C.I)	p	B (95%C.I)	p	B (95%C.I)	p	B (95%C.I)	p
Sever Tubular atrophy	1.771 (0.903 – 2.639)	<0.001	0.015 (0.1 – 0.65)	0.023	0.25 (-0.023 – 0.480)	0.33	0.003 (-0.004 – 0.011)	0.368
Severe Interstitial fibrosis	0.098 (0.039 – 0.157)	0.002	0.31 (0.06 – 2.8)	0.028	0.004 (-0.015 – 0.024)	0.641	0.122 (1.181 – 1.426)	0.846
Severe Arterio-sclerosis	0.252 (0.023 – 0.480)	0.033	0.533 (0.04 – 0.65)	0.022	1.010 (-2.534 – 4.554)	0.559	2.45 (-0.29 - 20.29)	0.41
Severe Glomerulo-sclerosis	-0.048 (-0.12 – 0.24)	0.82	0. (-0.523 - 1.4)	0.47	-0.067 (-0.155 – 0.021)	0.127	0. (-0.12 - 1.64)	0.22

DISCUSSION

In this study, we have shown that it is practical and comparatively secure to do kidney biopsies in HCV infected patients. Moreover, we have realized that renal histology in patients with HCV infection is variable; even with lengthy lab assessment; the pathology present

is hard to foretell. The histopathology seems to be a helpful indicator for modifying therapeutic strategies including new antiviral therapies. Still renal biopsy is of great risk in cirrhotic patients due to existence of coagulopathy⁽¹⁷⁾.

While renal biopsy has demonstrated significant predictive utility in wide range of renal diseases, little is known about the role of renal histopathological patterns in predicting renal functions in patients with HCV-associated nephropathy. In this prospective study, our analysis demonstrated that severe forms of histopathological patterns were associated with less improvement in the renal function compared to mild-to-moderate forms. Patients with moderate tubular atrophy, interstitial fibrosis, arteriosclerosis, and glomerulosclerosis had significantly higher reduction in the serum urea and creatinine twelve weeks after DAA treatment. Moreover, our results demonstrated significant association between HCV-related glomerular disease and post treatment renal outcomes and thus our study gives first proof that renal pathological changes can predict GFR after new antiviral treatment for infection with HCV.

Renal biopsy is the gold standard diagnostic modality for diagnosis and characterization of the severity of kidney diseases. It is usually indicated in cases of hematuria due to renal diseases, significant proteinuria, progressive renal impairment, and renal affection in the setting of multi-system diseases⁽¹⁷⁾. With the acknowledgment of poor prognostic utility of serum creatinine, renal biopsy gained momentum in assessment renal disease progression and treatment response, despite the technical limitations⁽¹⁸⁾. For example, interval biopsy are widely used to assess the remission of histopathological abnormalities in lupus nephritis, IgA nephropathy, and vasculitis; histopathological remission was found to be significantly correlated with the clinical activity^(19, 20). Many reports also demonstrated that post-transplantation biopsy was useful in predicting allograft rejection and changing treatment plan⁽²¹⁾. Recently, a growing body of evidence highlighted that pretreatment renal biopsy can significantly predict post treatment renal function in wide range of kidney disease⁽²²⁾. Thus, we hypothesized that renal biopsy can significantly predict post-DAA renal functions in patients with HCV-related nephropathy. Our analysis demonstrated that severe forms of histopathological patterns were associated with less improvement in the renal function compared to mild-to-moderate forms. Patients with moderate tubular atrophy, interstitial fibrosis, arteriosclerosis, and glomerulosclerosis had significantly higher reduction in the serum urea and creatinine twelve weeks after DAA treatment. Notably, the regression analysis showed that severe histopathological patterns were significant predictors of post treatment serum urea and creatinine.

To our knowledge, our study is the first of its kind to address the role of renal histopathological patterns in predicting renal functions in patients with

HCV-associated nephropathy; however, the role of renal biopsy in predicting renal functions was demonstrated in other renal diseases. For example, **Pichler and colleagues**⁽²²⁾ showed a significant association between renal biopsy and post-transplantation renal functions, in which severe histopathological abnormalities were associated with worse outcomes. Other reports showed similar findings⁽²³⁾. Likewise, it was found that pretreatment renal biopsy significantly predict post treatment renal function in the setting of idiopathic nephrosis⁽²⁴⁾, lupus nephritis⁽²⁵⁾, and patients undergoing native kidney biopsy⁽²⁶⁾.

With regard to the impact of DAA therapy on renal outcomes, our analysis demonstrated statistically significant improvements in serum creatinine and serum urea twelve weeks after treatment. These findings are in line with a previous study on patients with albuminuria that demonstrated significant reduction in albuminuria and serum creatinine after DAA. Additionally, **Bonacci et al.**⁽²⁷⁾ showed significant improvement in e GFR after DAA regimen.

Interestingly our regression analysis showed that tubular atrophy and interstitial fibrosis but not glomerulosclerosis may help to predict serum urea and creatinine post new direct antiviral treatments. This is in agreement with most studies of progression of primary renal disorders where the degree of tubular atrophy was found to predict loss of kidney function⁽²⁸⁾. However we do recognize that interstitial fibrosis may not be helpful in prediction of post-treatment e-GFR as a result of bias of selection, as those with severe interstitial fibrosis were chosen to receive other antiviral protocols rather than the protocols used in our study. From our results, the significant association between interstitial fibrosis pattern and kidney functions must be explained with care and larger sample of populations is required for future studies.

Despite our efforts to reduce the limitations of this study, the observational nature of the present study is a main limitation of this study, which significantly affects the analytical power of our findings. In addition to the small sample of the patients and absence of long-term follow-up are other limitations.

CONCLUSION

Pretreatment histopathological patterns of renal involvement significantly influence post treatment renal functions in patients with HCV nephropathy. Further studies with larger samples and longer duration are required to evaluate the predictive role of renal biopsy findings.

Conflict of interest: All authors confirm no financial or personal relationship with a third party whose interests could be positively or negatively influenced by the article's content.

Funding source: None (authors confirm they did not receive any funding to do this work).

REFERENCES

1. **Petruzzello A, Marigliano S, Loquercio G et al. (2016):** Global epidemiology of hepatitis C virus infection: An update of the distribution and circulation of hepatitis C virus genotypes. *World Journal of Gastroenterology*, 22: 7824–40.
2. **Cooke GS, Lemoine M, Thursz M et al. (2013):** Viral hepatitis and the Global Burden of Disease: A need to regroup. *Journal of Viral Hepatitis*, 20: 600–1.
3. **Mohamoud Y, Mumtaz GR, Riome S et al. (2013):** The epidemiology of hepatitis C virus in Egypt: a systematic review and data synthesis. *BMC Infect Dis.*, 13(1):288.
4. **Rosenberg ES, Rosenthal EM, Eric W et al. (2018):** Prevalence of Hepatitis C Virus Infection in US States and the District of Columbia, 2013 to 2016. *JAMA Network Open*, 1(8): 186371.
5. **Lu M, Li J, Rupp LB et al. (2018):** Changing trends in complications of chronic hepatitis C. *Liver Int.*, 38(2):239–47.
6. **Zamor PJ, deLemos AS, Russo MW (2017):** Viral hepatitis and hepatocellular carcinoma: etiology and management. *J Gastrointest Oncol.*, 8(2): 229–242.
7. **Razavi H, Elkhoury AC, Elbasha E et al. (2013):** Chronic hepatitis C virus (HCV) disease burden and cost in the United States. *Hepatology*, 57(6):2164–70.
8. **Latt N, Alachkar N, Gurakar A (2012):** Hepatitis C virus and its renal manifestations: A review and update. *Gastroenterology and Hepatology*. Millenium Medical Publishing, 8: 434–45.
9. **Barsoum RS (2007):** Hepatitis C virus: From entry to renal injury - Facts and potentials. *Nephrology Dialysis Transplantation*, 22: 1840–8.
10. **Ozkok A, Yildiz A (2014):** Hepatitis C virus associated glomerulopathies. *World J Gastroenterol.*, 20(24):7544–54.
11. **Barsoum RS, William EA, Khalil SS (2017):** Hepatitis C and kidney disease: A narrative review. *Journal of Advanced Research*, 8: 113–30.
12. **Do A, and Reau NS (2020):** Chronic Viral Hepatitis: Current Management and Future Directions. *Hepatol Commun*, 4(3): 329–341.
13. **Ji1 F, Wei1 B, Yeo YH et al. (2018):** Systematic review with meta-analysis: effectiveness and tolerability of interferon-free direct-acting antiviral regimens for chronic hepatitis C genotype 1 in routine clinical practice in Asia. *Aliment Pharmacol Ther.*, 47: 1–13.
14. **Wei B, Ji F, Yeo YH et al. (2018):** Systematic review and meta-analysis: real-world effectiveness of direct-acting antiviral therapies in chronic hepatitis C genotype 3 in Asia. *BMJ open Gastroenterol.*, 5(1):e000209.
15. **Liang TJ, Ghany MG (2013):** Current and Future Therapies for Hepatitis C Virus Infection. *N Engl J Med.*, 369(7):679–80.
16. **Tony EE, Tohamy M, Abdelaal R et al. (2019):** Immunological and biochemical parameters in patients with hepatitis C virus nephropathy before and after direct hepatitis C virus antiviral agents. *J Curr Med Res Pract.*, 4(2):158.
17. **Fernandez-Lorente L, Martin-Moreno PL, Arteaga J (2020):** Acute kidney failure in the cirrhotic patient: management, kidney biopsy and dual kidney liver transplantation indication. *Nephrology Dialysis Transplantation*, 35(3): 408–410.
18. **Bennett MR, Devarajan P (2017):** Characteristics of an Ideal Biomarker of Kidney Diseases. *Edelstein CL. Biomarkers of Kidney Disease*. 2nd ed. Academic Press, Pp. 1–20.
19. **Malvar A, Alberton V, Lococo B et al. (2020):** Kidney biopsy-based management of maintenance immunosuppression is safe and may ameliorate flare rate in lupus nephritis. *Clinical Investigation*, 97(1): 156–162.
20. **AlYousef A, AlSahow A, AlHelal B et al. (2020):** Glomerulonephritis Histopathological Pattern Change. *BMC Nephrology*, 21:186
21. **Katsuma A, Yamakawa T, Nakada Y et al. (2017):** Histopathological findings in transplanted kidneys. *Renal Replacement Therapy*, 3:6.
22. **Pichler RH, Huskey J, Kowalewska J et al. (2016):** Kidney Biopsies May Help Predict Renal Function after Liver Transplantation. *Transplantation*, 100(10):2122–8.
23. **Wadei HM, Heckman MG, Rawal B et al. (2014):** Renal outcomes of liver transplant recipients who had pretransplant kidney biopsy. *Transplantation*, 98(12):1323–30.
24. **Habib R, Niaudet P (1994):** Comparison between pre- and posttreatment renal biopsies in children receiving ciclosporine for idiopathic nephrosis. *Clin Nephrol.*, 42(3):141–6.
25. **Piñeiro GJ, Arrizabalaga P, Solé M et al. (2016):** Repeated Renal Biopsy - A Predictive Tool to Assess the Probability of Renal Flare in Lupus Nephritis. *Am J Nephrol.*, 44(6):439–46.
26. **Srivastava A, Palsson R, Kaze AD et al. (2018):** The prognostic value of histopathologic lesions in native kidney biopsy specimens: Results from the Boston kidney biopsy cohort study. *J Am Soc Nephrol.*, 29(8):2213–24.
27. **Bonacci M, Lens S, Londoño MC et al. (2017):** Virologic, Clinical, and Immune Response Outcomes of Patients With Hepatitis C Virus-Associated Cryoglobulinemia Treated With Direct-Acting Antivirals. *Clin Gastroenterol Hepatol.*, 15(4):575–83.
28. **Schelling JR (2016):** Tubular atrophy in the pathogenesis of chronic kidney disease progression. *Pediatr Nephrol.*, 31(5): 693–706.