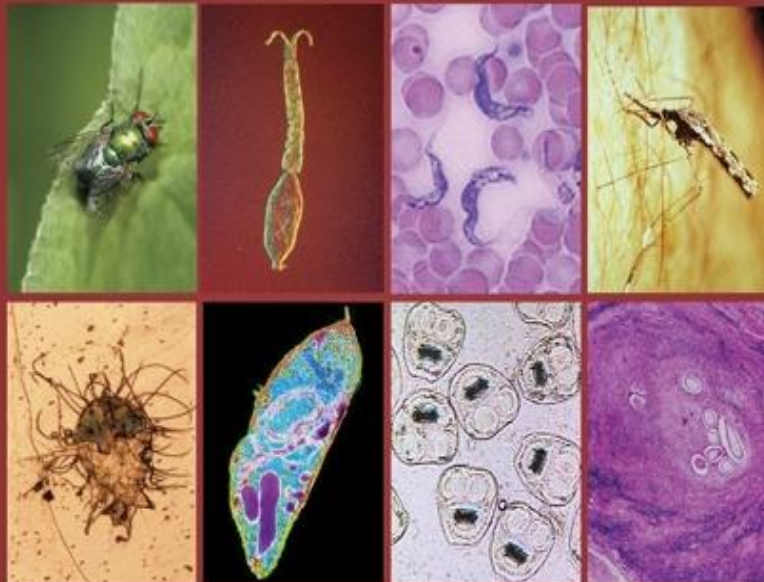



EGYPTIAN ACADEMIC JOURNAL OF
BIOLOGICAL SCIENCES

MEDICAL ENTOMOLOGY & PARASITOLOGY

E



ISSN
2090-0783

WWW.EAJBS.EG.NET

Vol. 12 No.2 (2020)



Maggot Therapy “Use of Fly Larvae for Treatment of Wounds”- A Review

Mohamed A. Kenawy^{1*} and Yousrya M. Abdel-Hamid²

1- Department of Entomology, Faculty of Science, Ain Shams University, Abbassia, Cairo 11566, Egypt

2- Research Institute of Medical Entomology, The General Organization for Institutes and Teaching Hospitals, Ministry of Health, Dokki, Giza, Egypt.

E-mail: mohamedkenawy@sci.asu.edu.eg, mohamedkenawy330@gmail.com

REVIEW INFO

Review History

Received:16/5/2020

Accepted:26/7/2020

Keywords:

Maggot therapy,
Maggot
debridement therapy,
MT, MDT,
Wound debridement,
Lucilia sericata.

ABSTRACT

Several chronic wounds require alternative therapy in addition to the conventional ones. Maggot therapy (MT) is one of these alternatives. MT is one form of animal-based treatment options known as Biotherapy (medicinal use of live organisms). MT or Maggot debridement therapy (MDT) is the medical use of live maggots for cleaning chronic, non-healing wounds or certain wounds that are not amenable to other forms of therapy. MT is achieved through maggots' secretion of proteolytic enzymes that liquefy the necrotic tissues and then feed on such tissues (wound debridement activity), wound disinfection (antimicrobial) activity and growth-promoting (wound healing) activity. MT has been used for centuries. Occasionally used since the 1930's and early 1940's and then in 2004, the Food and Drug Administration (FDA) approved maggots as a medical device that has been prescribed for patients in more than 200 hospitals in the United States. This article presents a review of published articles on the different aspects of MT (mainly the past and current uses, maggots used, how to apply maggots for wound treatments, advantages and disadvantages, problems and adverse reactions and its application in Egypt) that serves as a guide to health professionals who may be users of this form of treatment now and in the future.

INTRODUCTION

Maggots or fly larvae (Order Diptera) are often highly specialized for living in a wet environment and very few are adapted to dry conditions. A few species are internal parasites of animals or humans. When maggots infest humans or other vertebrates, it is called myiasis. Myiasis is classified based on the type of tissue attacked or the site of infestation (Hosni *et al.*, 2019). Flies causing myiasis are either obligate parasites that develop only on live hosts or facultative parasites that develop on either live hosts or carrion (Zumpt, 1965 and Hall and Wall, 1995). The naturally-occurring myiasis can be beneficial, but sometimes it can be harmful, depending upon the type of maggots and the circumstances surrounding the infestation. The known beneficial applications of myiasis are: (1) the use of maggots that feed on human corpses to give an indication of the time that elapsed since death, as well as the place of death “Forensic Entomology” or the legal use of such maggots to help solve crimes (Byrd and Castner, 2010) and (2) for treatment of wounds “Maggot therapy (Bonn, 2000 and Thomas, 2003).

Maggot therapy (MT) is one form of animal-based treatment options known as Biotherapy (medicinal use of live organisms) which includes also those of the honey bee (Apitherapy), leech (Hirudotherapy), fish (Ichthiotherapy), worm (Helmithotherapy), pets (Animal-assisted therapy) and Phage (Microbialtherapy). Maggot therapy “Larva therapy, Biosurgery or Maggot debridement therapy (MDT)” is the medical use of live maggots for cleaning human chronic and non-healing wounds or certain wounds that are not amenable to other forms of therapy (Sherman *et al.*, 2000; Church and Courtenay, 2002; Tantawi *et al.*, 2007 & 2010; Gupta, 2008; Hall, 2010; Marineau *et al.*, 2011; Sherman, 2014a; Naik and Harding, 2017 and Yan *et al.*, 2018). It involves allowing maggots of certain species of blowflies (Family: Calliphoridae) to consume the necrotic tissue in the wound, and to produce antibiotic substances that kill the pathogenic bacteria and promote tissue healing (Sherman *et al.*, 2000; Nigam *et al.*, 2006a & b; Tantawi *et al.*, 2010 and Yan *et al.*, 2018). MT is also used for veterinary purposes. Human and veterinary case histories were reviewed by Hinshaw (2000) and Zarchi and Jemec (2012).

This article presents an overview of the research evidence on the past and current uses of MT that serves as a guide to health professionals who may be users of this form of treatment now and in the future.

MATERIALS AND METHODS

This article is based primarily on a series of lectures presented by the first author for undergraduate students at the Department of Entomology, Faculty of Science, Ain Shams University, Cairo. Moreover, a systematic search and review of the available published articles on the different aspects of MT using “Wound debridement, MDT, MT, and *Lucilia* maggots” as keywords were performed on Pub Med and internet-based ones. In addition, several related web pages were accessed. Moreover, the studies carried out

in Egypt were added and discussed. A total of 66 articles of the different MT aspects were included in this review.

RESULTS AND DISCUSSION

Brief History and Current Status:

The early history of maggots in wound care was reviewed by Goldstein in 1932 (Thomas, 2003). During the 1930’s and early 1940’s, MT was extensively performed by thousands of physicians. By the mid-1940s, once penicillin was discovered and antibiotic therapy became common world-wide, MT had virtually ceased, except as a treatment of last resort. Later, MT was occasionally used during the 1970’s for skin and soft tissue wounds which did not respond to surgery and antibiotic therapy. With the emergence of antibacterial-resistant strains of microbes, the recent interest in maggots re-emerged in 1982. From 1989 on, MT has been re-introduced for the treatment of wounds in the USA, Canada, Great Britain, and some other European and Asian countries. Maggot therapy was offered in around 50 hospitals throughout the UK, for various conditions, ranging from burns to aiding recovery after surgery (Mumcuoglu *et al.*, 1999).

In 2004, the Food and Drug Administration (FDA) granted permission and approved maggots as a medical device to be marketed for wound care (Sherman, 2005; Andersen *et al.*, 2010; Cazander *et al.*, 2010; Choudhary *et al.*, 2016; and Yan *et al.*, 2018) which has been prescribed for patients in more than 200 hospitals in the USA. It was reported that thousands of patients have been treated by this method (Mumcuoglu, 2001) as for *e.g.*, some 20,000 patients throughout the UK have benefited from MT (Brindley, 2004). Currently, there are 12 laboratories in some countries dispensing maggots at low cost (Marineau *et al.*, 2011).

Maggots Used for Medical Applications:

While many species of fly larvae have been recorded to cause human myiasis, only a relatively small number (Francesconi

and Lupi, 2012) are known to have been used medicinally. The use of some facultative calliphorids (*e.g.*, the black bottle blowfly, *Phormia regina*) has been described in the literature. Today, the recommended and widely used therapeutic maggots are those of *Lucilia* (= *Phaenicia*) *sericata*, the green bottle blowfly (Sherman *et al.*, 2000 and Nigam *et al.*, 2006a); a facultative parasite that, in humans, only attacks necrotic tissues and do not burrow down into live flesh. Moreover, *Lucilia cuprina* showed effectiveness in the treatment of diabetic foot wounds (Paul *et al.*, 2009; Tantawi *et al.*, 2010 and Hassan *et al.* 2014). Clearly, considerable caution should be taken when selecting any other species of maggots for medicinal use as some calliphorids, however, cannot be used therapeutically for *e.g.*, *Cochliomyia macellaria*, *Cochliomyia hominivorax* (screwworms) and *Chrysomya megacephala* (the common green bottle fly or oriental latrine fly) since they will attack healthy human tissues.

Production of the Medicinal Maggots:

Early, non-sterile larvae of *L. sericata* were produced and used to promote wound debridement and disinfection. Although these were non-sterile, no serious adverse reactions (except tetanus) were reported. However, it was reported that for successful larval therapy, the maggots should be free of bacteria before being placed into wounds.

To obtain medicinal maggots, eggs collected from specially bred adult blowflies are sterilized by washing in a dilute solution of sodium hypochlorite (5%), rinse in sterile water, agitate in 4% formaldehyde and then the eggs are rinsed and allowed to hatch on fresh liver or on sterile meat-agar media. Several facilities producing sterile maggots have been established in the USA and some other countries. Since 1995, Biosurgical Research Unit (BRU, Princess of Wales Hospital), in Bridgend, UK is producing sterile maggots under the brand name of *LarvE* and supplying 1300 centers throughout the UK and Europe.

Methods of Applications:

Before application, the wound is cleaned with normal salt solution or sterilized water to remove the grease and dirt (Baer. 2011). Maggots are applied on the wound in two-ways (Choudhary *et al.*, 2016): the free-range dressing (direct contact method) and the biobag dressing (indirect contact method) (Janssen, 2005; Jones and Wall, 2007; Lepage *et al.* 2012 and Brown, 2013).

In the free-range dressing, maggots are applied directly to the wound for 3 days and allowed to roam freely (Brown, 2013) over the surface seeking out areas of necrotic tissue but due to which, maggots can escape out from the wound site (Choudhary *et al.*, 2016), while in biobag dressing, the maggots are enclosed in a net pouch containing a piece of hydrophilic polyurethane foam, which is placed directly upon the wound surface, so that maggots cannot escape dressing (Jones and Wall, 2007).

For biobag dressing (Fig. 1), sterile first instar larvae of *L. sericata* are applied to the wound sealed in with a bandage (Janssen, 2005; Naik and Harding, 2017) and left to feed for 2-3 days and then removed and replaced with fresh ones. The old larvae are removed simply by detaching the outer dressing and collecting them with forceps or flushed out of the wound with sterile saline (Baer. 2011). The treatment is repeated until the wound is clean or the healthy tissue has formed. The healthy skin surrounding the ulcer is covered with a hydrocolloid dressing to protect it from the proteolytic enzymes produced by the larvae and to eliminate the tickling sensation caused by the maggots' movements (Baer. 2011). For this, the wound is measured and cuts out a sample of a barrier like Duoderm, creating a frame around the wound then maggots are contained within the area of the wound under a fine mesh net (chiffon) so there is a little cage for the maggots, which prevents their escape. The edges are secured with a tape. Moist gauze swabs are placed over the net and changed on a daily basis to prevent the larvae from

drying out. Maggots are obligatory air-breathers so that the dressing must allow fresh air to enter the area and let the liquefied necrotic tissue to drain freely from the wound (Dar *et al.*, 2013; Dholaria *et al.*, 2014 and Sherman, 2014b).

The number of maggots applied to a wound depends upon the amount of necrotic tissue present, wound depth, and width of wound area (Lepage *et al.* 2012 and Abdolmaleki *et al.*, 2015). Typically, five to 10 larvae per square centimeter of the wound (Sherman, 2009 and Singh *et al.*, 2014) are used twice a week. It is more cost-

effective to use a large number of maggots for a short period of time than a small number for an extended period. The period of time necessary for maggot debridement of a wound depends on a number of factors, including (1) The depth and extent of the wound, (2) The part of the body affected, and (3) The number of maggots present in the wound. However, the maggots should be removed immediately once they have removed all the dead tissue and before they have become established in healthy tissue.

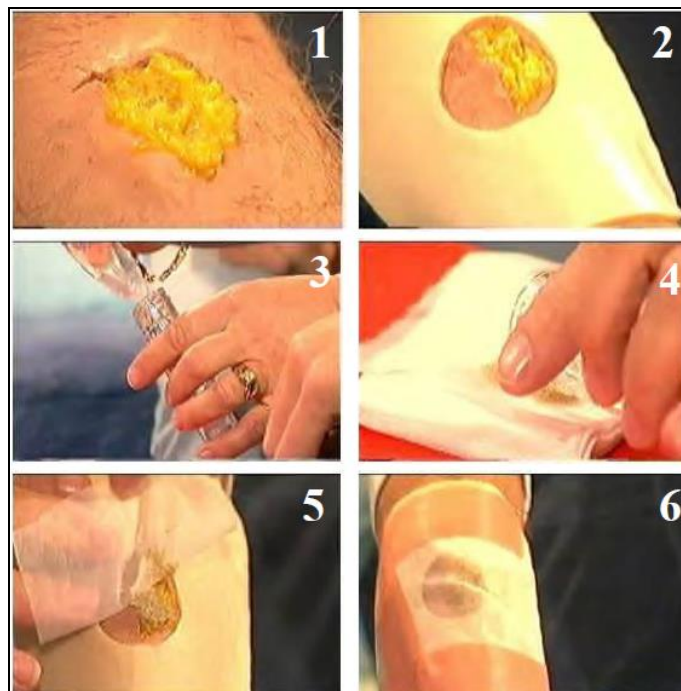


Fig.1: Maggots' application to a wound: (1) an injury on the arm before applying MT, (2) a large dressing (like a plaster) is placed over the wound first, (3) saltwater is added to the maggots to wash them, (4) maggots are then emptied out onto a piece of net so that the saltwater drained away, (5) the net is turned over and placed on the wound and stuck down and (6) the maggots stay on the wound for 2-3 days (Modified from Jones, 2004).

Wound Management:

It was observed that maggots are capable of entering any part of the wound wherever necrotic tissue exists and clean minute areas without harming healthy tissue in a manner resembling microsurgery; a task which is very difficult to attain by the conventional surgery.

Maggot therapy can be and has been used in the treatment of a wide variety of

infected or necrotic wounds including abscesses, leg ulcers, pressure ulcers/ sores, venous stasis ulcers, pressure ulcers in spinal cord injury, bedsores, diabetic foot wounds/ ulcers, infected postsurgical wounds, burns, and Meticillin-resistant *Staphylococcus aureus* (MRSA)-infected wounds (Sherman *et al.*, 1995 & 1996; Mumcuoglu *et al.* 1998; Mercola, 2000; Knowles *et al.*, 2002; Kotb *et al.*,

2002; Sherman, 2002 & 2003; Thornton *et al.*, 2002; Hwang *et al.*, 2011; Marineau *et al.*, 2011 and Nasoori and Hoomand, 2017).

Although maggot therapy can be applied to most cavity wounds, they are not recommended for use in wounds that might connect with the body cavity or important internal structures or organs. As a precautionary measure, it is also advised that they should not be applied near to exposed major blood vessels

How Do the Maggots work? “Mechanisms of Action”:

Although it is not fully understood how the maggots work, however, different mechanisms of wound healing by maggots were suggested and including:

1. **Wound debridement activity:** maggots secrete proteolytic enzymes (Casu *et al.*, 1996 and Honda *et al.*, 2011) that liquefy the necrotic tissues into a semi-liquid substance and then feed on these tissues.
2. **Antimicrobial activity “Wound disinfection”** through (a) the presence and activity of the larvae increasing the exudates from the host wound which mechanically washes the bacteria out of the wounds (Vowden and Vowden, 2003 and Marineau *et al.*, 2011), (b) the destruction of bacteria in the wound by maggots excretions which contain anti-bacterial substances (Pavillard and Wright, 1957; Greenberg, 1968; Mumcuoglu *et al.*, 2001; Kruglikova and Chernysh, 2011; Poepfel *et al.*, 2015 and Yan *et al.* 2018) and (c) maggot secretion of ammonia (Guerrini, 1988) that rises wound pH (from acidic to alkaline) which may partly contribute to wound disinfection.
3. **Growth promoting activity “Wound healing”** (Marineau *et al.*, 2011 and Sherman, 2014b) through (a) larvae secrete substances with wound healing properties (such as allantoin and urea) which also have antimicrobial activity and (b) the continuous crawling action of the larvae stimulates the formation of healthy granulation tissue

which may actually lead wounds to heal more quickly.

Factors Influencing Maggot Survival within a Wound:

1. **Systemic antibiotic therapy:** Maggots may sometimes be applied to treat wounds in patients who are receiving antibiotic therapy. It was observed that antibiotics have adverse effects on maggot growth and development so that maggots should not be applied to patients on antibiotic therapy.
2. **Topical treatments:** Because MT is not generally regarded as the first-line treatment, the wounds to which MT is applied may have previously been treated with numerous products, *e.g.* amorphous hydrogels. Studies have indicated that some hydrogels markedly inhibit *Lucilia* maggot survival and growth (Thomas and Andrews, 1999), so that all traces of such products need to be removed from a wound prior to the application of maggots.
3. **X-rays** have no effects on larval development, indicating that maggots do not have to be removed from wounds prior to X-ray investigations.

Advantages and Disadvantages

A. Advantages:

1. It is a rapid, more effective treatment of infected and necrotic wounds than many of the other treatments commonly prescribed.
2. It is currently one of the most effective means of treating MRSA-infected wounds.
3. It is easy to apply and does not require a specialist.
4. It does not destroy the normal gastrointestinal flora as do systemic antibiotics.
5. It is relatively inexpensive.
6. Offers many clinical benefits to patients including rapid wound debridement, eliminates infection, reduces healing times, and prevents amputation.

7. Has a positive impact upon patients' quality of life as it can help to reduce the pain associated with infected wounds, eliminates unpleasant odors, decreases the number of hospital visits, and prevents the need for hospital admission and thus reduces treatment costs.

B. Disadvantages:

1. Maggots have a short shelf life and cannot be stored prior to use.
2. Some clinicians and patients find them unacceptable.
3. Maggots can be a 'runaway' dressing.
4. Not available in drug stores.
5. Slower than sharp or surgical debridement.
6. Not suitable for all wounds for *e.g.*, cannot be used in treating wounds in body cavities or in close proximity to large vessels (Vowden and Vowden, 2003).
7. Effectiveness is limited by the environment (wound pH, fluid, and oxygen).

Problems and Adverse Reactions

Although no serious side effects were noted following the use of maggots, there are some minor reactions have been described:

1. **Transient pyrexia and bleeding** in a very few cases.
2. **Pain and physical discomfort** that varies from a mild sensation to severe pain that may lead to termination of the treatment.
3. **Ammonia toxicity** resulting from the absorption of maggot-secreted ammonia into the bloodstream leading to a rapid rise in temperature and respiratory rate, accompanied by loss of weight and appetite of the animals (Guerrini, 1988). Ammonia toxicity is theoretically possible in humans, although maggot therapy utilizes far fewer larvae.
4. **Failure of maggots to survive** on the wound as a result of maggots' drowning due to poor drainage of the exudates from the wound or unsuitable pH of

the wound for the young larvae and its proteolytic enzymes.

Situation and Use of Maggot Therapy in Egypt:

The first study on the application of MT for wound debridement in Egypt was that on animals by Eve Iversen (Iversen, 2000). Moreover, Hassan *et al.* (2014) used *L. cuprina* maggots for treatment of an artificial wound made in a diabetic foot of rabbit and observed that the wound was completely healed after 13 days.

For humans, Tantawi *et al.* (2010) reported that *L. cuprina* proved to be safe and effective in healing the diabetic foot wounds of two patients at Alexandria Main University Hospital (AMUH) and Tantawi *et al.* (2017) used *L. sericata* for treatment of 14 bed-bound patients with pressure ulcers at AMUH. Since 2000, MT has been practiced at AMUH and more than 250 patients had their venous and diabetic wounds were successfully treated using disinfected maggots of *L. sericata* (Tantawi, 2004).

CONCLUSION

Maggot therapy proved to be effective in the treatment of a wide variety of necrotic wounds / ulcers and antibiotic-resistant ones than some of the other treatments commonly prescribed. Maggots of *L. sericata* are mainly used for such purpose due that in humans, they attack only necrotic tissues and do not burrow down into live flesh. Considerable caution should be taken when selecting any other species of maggots for medicinal use for *e.g.*, some Calliphoridae as *Cochliomyia macellaria*, *C. hominivorax*, and *Chrysomya megacephala* cannot be used since they will attack healthy tissues. Such method of wound treatment is easy to apply and do not require a specialist and has a positive impact upon patients' quality of life as it decreases the number of hospital visits and prevents the need for hospital admission and thus reduces treatment costs.

REFERENCES

- Abdolmaleki, A.; Mirarab Razi, J.; Nourzad Moghaddam, M. and Mastari

- Farahani, H, (2015). Maggot debridement therapy: concepts, methods, issues and future. *International Journal of Pharmacotherapy*, 5: 27–31.
- Andersen. A.S.; Sandvang, D.; Schnorr, K.M.; Kruse, B.; Joergensen, S.N.; Karlsmark, T. and Krogfelt, K.A. (2010). A novel approach to the antimicrobial activity of maggot debridement therapy. *Journal of Antimicrobial Chemotherapy*, 65: 1646–1654.
- Baer, W.S. (2011). The classic, the treatment of chronic osteomyelitis with the maggot (Larva of the Blow Fly). *Clinical Orthopaedics and Related Research*, 469: 920–944.
- Bonn, D. (2000). Maggot therapy: an alternative for wound infection. *Lancet*, 356: 1174.
- Brindley, M. (2004). Maggot therapy on demand. <https://www.walesonline.co.uk/news/wales-news/maggot-therapy-on-demand-2450689>.
- Brown, A. (2013). The role of debridement in the healing process. *Nursing Times*, 109: 16–19.
- Byrd, J.H. and Castner, J. L. (Eds.) (2010). Forensic Entomology: The Utility of Arthropods in Legal Investigations. 2nd Edition, CRC Press Inc, Boca Raton, FL, 681 pp.
- Casu, R.E.; Eisemann, C. H.; Vuocolo, T. and Tellam, R. L (1996). The major excretory/ secretory protease from *Lucilia cuprina* larvae is also a gut digestive protease. *International Journal for Parasitology*, 26: 623–628.
- Cazander, G.; van de Veerdonk, M.C.; Vandenbroucke-Grauls, C.M.; Schreurs, M.W. and Jukema, G.N. (2010). Maggot excretions inhibit biofilm formation on biomaterials. *Clinical Orthopaedics and Related Research*, 468: 2789–2796.
- Choudhary, V.; Choudhary, M.; Pandey, S.; Chauhan, V. D. and Hasnani, J. J. (2016). Maggot debridement therapy as primary tool to treat chronic wound of animals. *Veterinary World*, 9: 403–409.
- Church, J.C.T. and Courtenay, M. (2002). Maggot debridement therapy for chronic wounds. *International Journal of Lower Extremity Wounds*, 1: 129-134.
- Dar, L.M.; Hussain, S.A.; Abdullah, S.; Rashid, A.; Parihar, S. and Rather, F.A. (2013). Maggot therapy and its implications in veterinary medicine: An overview. *Journal of Advanced Veterinary Research*, 3: 47–51.
- Dholaria, S.; Dalal, P.; Shah, N. and Narkhede, R. (2014). Maggots debridement therapy [MDT]. *Gujarat Medical Journal*, 69:1.
- Francesconi, F. and Lupi, O. (2012). Myiasis. *Clinical Microbiology Reviews*, 25: 79-105.
- Greenberg, B. (1968). Model for destruction of bacteria in the midgut of blow fly maggots. *Journal of Medical Entomology*, 5: 31-38.
- Guerrini, V.H. (1988). Ammonia toxicity and alkalosis in sheep infested by *Lucilia cuprina* larvae. *International Journal for Parasitology*, 18: 79-81.
- Gupta, A. (2008). A review of the use of maggots in wound therapy, *Annals of Plastic Surgery*, 60: 224–227.
- Hal, M. and Wall, R. (1995). Myiasis of humans and domestic animals. *Advances in Parasitology*, 35: 257-334.
- Hall, S. (2010). A review of maggot debridement therapy to treat chronic wounds. *British Journal of Nursing*, 19: S28-31.
- Hassan, M. I.; Hammad, K.M.; Fouda, M.A. and Kamel, M. R. (2014). The using of *Lucilia cuprina* maggots in the treatment of diabetic foot wounds. *Journal of the Egyptian Society of Parasitology*, 44 125-129.
- Hinshaw, J. (2000). Larval therapy: A review of clinical human and veterinary studies. *World Wide Wounds*:

- Version: 1.0. <http://www.WorldwideWounds.com/2000/oct/Janet-Hinshaw/Larval-Therapy-Human-and-veterinary.html>.
- Honda, K.; Okamoto, K.; Mochida, Y.; Ishioka, K.; Oka, M.; Maesato, K.; Ikee, R.; Moriya, H.; Hidaka, S.; Ohtake, T.; Doi, K.; Fujita, T.; Kobayashi, S. and Noiri, E. (2011). A novel mechanism in maggot debridement therapy: protease in excretion/secretion promotes hepatocyte growth factor production. *American Journal of Physiology-Cell Physiology*, 301: C1423-1430.
- Hosni, E. M.; Kenawy, M.A.; Nasser, M. G.; Al-Ashaal, S. A. and Rady, M. H. (2019). A brief review of myiasis with special notes on the blow flies' producing myiasis (F.: Calliphoridae). *Egyptian Academic Journal of Biological Sciences*, 11: 25 - 32.
- Hwang, J. H.; Modi, H.N.; Suh, S.W.; Hong, J.Y.; Yang, J.H. and Park, J.H. (2011). Maggot debridement therapy for postsurgical wound infection in scoliosis: a case series in five patients. *Spine*, 36:313-319.
- Iversen, E. (2000). Biotherapy Research Sojourn in Egypt. http://www.ucihs.uci.edu/com/pathology/sherman/vet_mdt/index.htm.
- Janssen, D. (2005). Types of wound debridement. Wound Care Information Network, <http://www.medicaledu.com/debridhp.htm>.
- Jones, M. (2004). In the Studio: Maggot Therapy. The Foundation TV Productions Ltd, <http://www.foundationtv.co.uk/brilliantcreatures/>
- Jones, G. and Wall, R. (2007). Maggot-therapy in veterinary medicine. *Research in Veterinary Science*, 85: 394-398.
- Knowles, A.; Findlow, A. and Jackson, N. (2002). Management of a diabetic foot ulcer using larval therapy. World Wide Wounds: Revision: 1.0. <http://www.WorldwideWounds.com/2002/march/Knowles/Larval-Therapy-Diabetic-Foot.html>.
- Kotb, M. M.; Tantawi, T. I.; Gohar, Y. M.; Beshara, F.M.S. and Fattallah, S.M.S. (2002). The medicinal use of maggots in the management of venous stasis ulcers and diabetic foot ulcers. *Bulletin of Alexandria Faculty of Medicine*, 37: 205-214.
- Kruglikova, A.A. and Chernysh, S. I. (2011). Antimicrobial compounds from the excretions of surgical maggots, *Lucilia sericata* (Meigen) (Diptera, Calliphoridae). *Entomological Review*, 91: 813-819.
- Lepage, O.M.; Doumbia, A.; Perron-Lepage, M.F. and Gangl, M. (2012). The use of maggot debridement therapy in 41 equids. *Equine Veterinary Journal*, 44: 120-125.
- Marineau, M. L.; Herrington, M. T.; Swenor, K. M. and Eron, L. J. (2011). Maggot debridement therapy in the treatment of complex diabetic wounds. *Hawaii Medical Journal*, 70: 121-124.
- Mercola, J. (2000). Maggot therapy: An alternative for wound infection. *Lancet*, 30: 1174 - 1178.
- Mumcuoglu, K.Y. (2001). Clinical applications for maggots in wound care. *American Journal of Clinical Dermatology*, 2: 219-227.
- Mumcuoglu, K.Y.; Ingber, A.; Gilead, L.; Stessman, J.; Friedmann, R.; Schulman, H.; Bichucher, H.; Ioffe-Uspensky, I.; Miller, J.; Galun, R. and Raz, I. (1998). Maggot therapy for the treatment of diabetic foot ulcers. *Diabetes Care*, 21: 2030-2031.
- Mumcuoglu, K.Y., Ingber, A.; Gilead, L.; Stessman, J.; Friedmann, R.; Schulman, H. and Bichucher, H. (1999). Maggot therapy for the treatment of intractable wounds. *International Journal of Dermatology*, 38: 623-627.

- Mumcuoglu, K.Y., Miller, J.; Mumcuoglu, Sherman, R.A. (2002). Maggot versus conservative debridement therapy for the treatment of pressure ulcers. *Wound Repair and Regeneration*, 10: 208-214.
- M.; Friger, M. and Tarshis, M. (2001). Destruction of bacteria in the digestive tract of the maggot of *Lucilia sericata* (Diptera: Calliforidae). *Journal of Medical Entomology*, 38: 161-166.
- Naik, G., Harding, K. G. (2017). Maggot debridement therapy: the current perspectives. *Chronic Wound Care Management and Research*, 4: 121–128.
- Nasoori, A. and Hoomand, R. (2017). Maggot debridement therapy for an electrical burn injury with instructions for the use of *Lucilia sericata* larvae. *Journal of Wound Care*, 26: 734-741.
- Nigam, Y.; Bexfield, A.; Thomas, S. and Ratcliffe, N. A. (2006a). Maggot therapy: the science and implication for CAM. Part I: history and bacterial resistance. *Evidence-Based Complementary and Alternative Medicine*, 3: 223-227.
- Nigam, Y.; Bexfield, A.; Thomas, S. and Ratcliffe, N. A. (2006b). Maggot therapy: the science and implication for CAM Part II: maggots combat infection. *Evidence-Based Complementary and Alternative Medicine*, 3: 303-308.
- Paul, A. G.; Ahmad, N. W.; Lee, H. L.; Ariff, A. M.; Saranum, M.; Naicker, A. S. and Osman, Z. (2009). Maggot debridement therapy with *Lucilia cuprina*: a comparison with conventional debridement in diabetic foot ulcers. *International Wound Journal*, 6: 39-46.
- Pavillard, E.R. and Wright, E.A. (1957). An antibiotic from maggots. *Nature*, 180: 916-917.
- Poepfel, A.K.; Vogel, H.; Wiesner, J. and Vilcinskis, A. (2015). Antimicrobial peptides expressed in medicinal maggots of the blow fly *Lucilia sericata* show combinatorial activity against bacteria. *Antimicrobial Agents and Chemotherapy*, 59: 2508–2514.
- Sherman, R.A. (2003). Maggot therapy for treating diabetic foot ulcers unresponsive to conventional therapy. *Diabetes Care*, 26: 446-451.
- Sherman, R.A., (2005). Age-old therapy gets new approval, *Advances in skin & wound care*, 18: 12–15.
- Sherman, R.A. (2009). Maggot therapy takes us back to the future of wound care: New and improved maggot therapy for the 21st century. *Journal of Diabetes Science and Technology*, 3: 336–344.
- Sherman, R.A. (2014a). Using maggots in wound care: Part 1. *Wound Care Advisor*, 3: 12-19.
- Sherman, R.A. (2014b). Mechanisms of maggot induced wound healing: What do we know, and where do we go from here? *Evidence-Based Complementary and Alternative Medicine*, 2014: 592419.
- Sherman, R. A.; Hall, M.J.R. and Thomas. S. (2000). Medicinal maggots: an ancient remedy for some contemporary afflictions. *Annual Review of Entomology*, 45: 55-81.
- Sherman, R.A.; Tran, J. M.; Sullivan, R. (1996). Maggot therapy for venous stasis ulcers. *Archives of Dermatology*, 132: 254-256.
- Sherman R.A.; Wyle, F.A. and Vulpe, M. (1995). Maggot debridement therapy for treating pressure ulcers in spinal cord injury patients. *Journal of Spinal Cord Medicine*, 18: 71–74.
- Singh, N.M.; Bhatia, S.K. and Singh, G. (2014). Maggots therapy in facilitating wound debridement: Present status. *Medical Journal of Dr. D.Y. Patil University*, 7: 639–642.
- Tantawi, T. I. (2004). Maggot therapy in Egypt, Reviewed. The BeTER LeTTER, BioTherapeutics, Education

- & Research Foundation, 1 (1) October, 3 pp.
- Tantawi, T. I.; Gohar, Y. M.; Kotb, M. M.; Beshara, F. M. and El-Naggar, M. M. (2007). Clinical and microbiological efficacy of MDT in the treatment of diabetic foot ulcers. *Journal of Wound Care*, 16: 379-383.
- Tantawi, T. I.; Gohar, Y. M.; William, S. G.; Kotb, M. M. and Abou Zeid, N. A. (2017). Clinical and microbiological efficacy of medicinal maggots in the treatment of pressure ulcers in Egypt, *Journal of Bioscience and Applied Research* 3: 152-177.
- Tantawi, T.I.; Williams, K.A. and Villet, M.H. (2010). An accidental but safe and effective use of *Lucilia cuprina* (Diptera: Calliphoridae) in maggot debridement therapy in Alexandria, Egypt. *Journal of Medical Entomology*, 47: 491-494.
- Thomas, S. (2003). Introduction to maggot therapy. <http://www.Larve.com>.
- Thomas, S. and Andrews, A. (1999). The effect of hydrogel dressings on maggot development. *Journal of Wound Care*, 8: 75-77.
- Thornton, D.; Berry, M. and Ralston, D. (2002). Case report: maggot therapy in an acute burn. *World Wide Wounds: Version: 1.0*, <http://www.worldwidewounds.com/2002/august/Thornton/Larval-Therapy-Acute-Burn.html>.
- Vowden, K. and Vowden, P. (2003). Understanding exudate management and the role of exudate in the healing process. *British Journal of Community Nursing*, 8: 4-13.
- Yan, L.; Chu, J.; Li, M.; Wang, X.; Zong, J.; Zhang, X.; Song, M. and Wang, S. (2018). Pharmacological properties of the medical maggot: A novel therapy overview. *Evidence-Based Complementary and Alternative Medicine*, 2018: 1-11.
- Zumpt, F. (1965). Myiasis in Man and Animals in the Old World. A Textbook for Physicians, Veterinarians and Zoologists. Butterworths, London, United Kingdom, pp. 267.
- Zarchi, K.; Jemec, G.B. (2012). The efficacy of maggot debridement therapy- a review of comparative clinical trials. *International Wound Journal*, 9: 469-477.

ARABIC SUMMARY

العلاج بيرقات الذباب " استخدام يرقات الذباب لعلاج الجروح": مراجعه

محمد امين قناوى¹ ويسريه محمد عبد الحميد²

1- قسم علم الحشرات، كلية العلوم، جامعة عين شمس، العباسيه، القايره 11566

2- معهد بحوث الحشرات الطبية، الهيئه العامه للمعاهد والمستشفيات التعليميه، وزارة الصحه، الدقى، جيزه، جمهوريه مصر العربيه

تتطلب عدة جروح مزمنة علاجاً بديلاً بالإضافة إلى العلاجات التقليدية. يعد العلاج بيرقات الذباب (MT) أحد هذه البدائل والذي يعتبر أحد أشكال العلاج الحيوي (الاستخدام الطبي للكائنات الحية). يعرف MT بالاستخدام الطبي للديدان الحية لتنظيف الجروح المزمنة وغير القابلة للشفاء أو التي لا تستجيب لأشكال أخرى من العلاج. يتم تحقيق MDT من خلال إفراز الديدان انزيمات محللة للبروتين والتي تسيل الأنسجة الميتة ثم تتغذى على مثل هذه الأنسجة (نشاط إزالة الجرح)، نشاط تطهير الجرح (مضادات الميكروبات) ونشاط تعزيز النمو (التئام الجروح). لقد تم استخدامه في بعض الأحيان منذ ثلاثينيات القرن العشرين وأوائل الأربعينيات، ثم في عام 2004، وافقت إدارة الغذاء والدواء (FDA) على اعتباره كأداة طبية وتم وصفها للمرضى في أكثر من 200 مستشفى في الولايات المتحدة. تقدم هذه المقالة مراجعة للمقالات المنشورة حول الجوانب المختلفة للـ MT (بشكل رئيسي الاستخدامات السابقة والحالية، واليرقات المستخدمة، وكيفية تطبيق اليرقات لعلاج الجرح، ومزاياها وعيوبها، والمشاكل وردود الافعال السلبية وتطبيقها في مصر) كدليل للمهنيين الصحيين الذين قد يكونوا مستخدمين لهذا النوع من العلاج الآن وفي المستقبل.