

Effect of D-Limonene on the Age-Related Androgenic Changes in Male Rats

MAHMOUD A. EL HEFNAWY, M.Sc.; SHEREEN M. SAMIR, M.D.; MOHAMED ADEL, M.D. and MOHAMED Z. BORAIE, M.D.

The Department of Medical Physiology, Faculty of Medicine, Mansoura University, Egypt

Abstract

Background: Aging has deteriorating effects on physiological functions of many organs including the sex organs, which are suggested to be due to oxidative stress. D-limonene which is an extract from the peel of Citrus plants, has multiple therapeutic properties, mainly due to its antioxidant capacity.

Aim of Study: Was to detect the androgenic changes in aging male rats and trying to find out the possible beneficial effects of D-limonene on these androgenic changes.

Material and Methods: 32 male rats were divided into 2 main groups; adult sexually mature group and old aged group. Each group was subdivided into; control subgroup and subgroup supplemented with D-limonene for 4 weeks. Blood samples, dissected testes and epididymides were used for detection of oxidative stress markers, sperm analysis, androgen receptors by immunohistochemistry and histopathological examination.

Results: The control old aged rats showed significant decrease in all sperm parameters, androgen receptors, antioxidants and testosterone levels as compared with the adult ones. Amazingly, supplementation of D-limonene corrected all these aging inducing effects on androgenic capacity which may be attributed to its antioxidant ability. This improving effect was proved by more spread of androgen receptors in rats' epididymides with improving count and morphology of sperms.

Conclusion: Supplementation of D-limonene daily to rats, especially the old aged ones could protect the sexual organs from aging oxidative stress inducing deterioration of its physiological functions. So, we recommend in this study to add limonene to the diet of old age men and those who exposed to chronic stress in their lives to save, to some extent, their androgenic capacity which may help in treating many cases of male infertility.

Key Words: *D-limonene – Aging – Oxidative stress – Androgenic capacity – Epididymal androgen receptors.*

Introduction

INFERTILITY is a major clinical worldwide problem. Around 8 to 12 percent of couples have

Correspondence to: Dr. Mahmoud A. El Hefnawy, The Department of Medical Physiology, Faculty of Medicine, Mansoura University, Egypt

fertility problems; male factor is responsible for 50% of these cases [1]. One of the major causes of male infertility is oxidative stress which may be involved in male aging.

Aging has harmful effects on most tissues with deterioration of physiological functions of many organs. Though men can preserve their fertility till advanced age, studies concerning semen analysis in men older than 55 years or younger than 35 years have detected that semen volume and sperm motility are inversely correlated with age [2]. Also, it was noticed that oxidative stress affected normal packaging of chromatin and spermatozoa integrity of aged Brown Norway rats, suggesting that reactive oxygen species production has a direct effect on male fertility [3]. Furthermore, histopathological studies have detected that aging is accompanying with thickened seminiferous tubules basement membrane together with a decrease in Leydig and Sertoli cells number, in addition to a rise in the rate of arrested germ cells divisions [4]. A histological and ultrastructural study by Jiang et al., [5] has noticed that aging testes are characterized by a reduction in germ cells proliferation besides increasing rate of their apoptosis. In supporting evidence, Wang et al., [4], demonstrated a reduction in the steroidogenic capacity of the Leydig cells in aged rats by about 50% and delivered an evidence that Reactive Oxygen Species (ROS) might induce destruction to membrane proteins and lipids of the Leydig cell.

Limonene, a monoterpene, is a major volatile component of the essential oils extracted from the peel of Citrus plants such as orange and lemon. It has two isomers: D and L; the main active form of limonene is D-limonene [6]. It has a pleasant lemon-like odor, so it is used as a flavor and food additive in fruit juices, candies, soft drinks, cosmetics and beauty products [6].

Multiple therapeutic properties have been referred to D-limonene. It has antioxidant properties through inhibiting lipid peroxidation and arresting the free radical-induced damage, so it is used for preventing physical stress, psychological stress [7] and for prevention of stress-induced hypertension [8]. Also, Jesudoss et al. [9] have been found that D-Limonene has a promising role in regulation of pulmonary hypertension. In addition, D-limonene is reported to have chemotherapeutic properties against many types of cancers as in human gastric carcinoma and colon cancer [10]. Kummer et al., [11] discovered that limonene has the ability to decrease TNF- α level and to reduce the chemotaxis of neutrophils and leukocytes in zymosan-induced peritonitis in vitro. Surprisingly, Biccinelli and his coworkers [12] reported the antihyperalgesic and antidepressant effects of limonene on rat neuropathic pain in Spared Nerve Injury (SNI) model. The efficiency of limonene as immunomodulatory agent was tested on the immune system function using an isolated in vitro assay that revealed inhibited TH1 and TH2 cytokines production by activated T cells [13].

So, aim of this study was to detect the androgenic changes in aging male rats including; the hormonal assay, sperm sample analysis and detection of epididymal androgen receptors by immunostain. Also, trying to find out the possible beneficial effects of D-limonene on these androgenic changes.

Material and Methods

Experimental animals:

In this study, we used male Sprague Dawley rats. Animals were housed in the Medical Experimental Research Center (MERC) animal house, Mansoura University, at adjusted environmental conditions (temperature of 20°C and twelve hours light/dark cycles). They were kept on a standard chow with free access to tap water. The experimental protocol was approved by the Ethics Committee of Animal Care in Mansoura Faculty of Medicine (19.02.494).

Experimental protocol:

Thirty-two male Sprague Dawley rats were divided into 2 main groups (16 rats in each group); Group I: Adult sexually mature rats (aged 4-5 months) and Group II: Old age rats (aged 20-24 month). Each group was subdivided into two subgroups (8 rats per each): Sub group (A): (Control group) normal rats maintained on standard rat chow, and sub group (B): Rats supplemented with

D-limonene (50mg/kg) orally daily for 4 weeks in (October 2019) [14].

At the end of the experimental period (4 weeks), scarification of all rats was done under sodium thiopental anesthesia (30-40mg/kg I.P injection). Then blood samples were collected directly from heart, left for 2 hours at room temperature to clot before being centrifuged at 1000r.p.m for 20 minutes to obtain serum samples for hormonal assay. Also, the testes were dissected along with its epididymides and sperm samples were collected from the cauda epididymis. Right testes with their epididymides were fixed in Bouin's solution for histopathological examination and immunohistochemical detection of androgen receptors. The left testes samples were weighted and stored at -20°C for the analyses of malondialdehyde (MDA), reduced glutathione (GSH) levels, and Superoxide Dismutase (SOD) activities.

Sperm sample from epididymis:

Sperm samples were collected by surgical exposing of the cauda epididymis after scarification. Samples are taken from distal part of cauda epididymides and collected by using the diffusion method [15]. This method in short was done by placing the excised and trimmed epididymis in a Petri dish with 5ml of Hanks Balanced Salts Solution composed of 2.0g/L bovine serum albumin, 4.2g/L N-2-Hydroxyethyl piperazine-N-2 ethansulfonic acid, 0.35g/L sodium bicarbonate, 0.1g/L sodium pyruvate, 0.025g/L soybean trypsin inhibitor and 0.9g/L d-glucose (Sigma Chemical Company, USA) pH 7.4. The lumen of the distal portion of cauda epididymal tube was pierced by scalpel blade at various locations with taking care to avoid cutting blood vessels. Sperm quickly start to diffuse out from the lumen of the tubule due to the inside fluid pressure. Once turbidity appears, take around 30sec, the epididymal tissue was moved away, with placing the dish in a tissue culture incubator (5% CO₂, 34°C) for ~15min till consequent analysis of sperm motion was done.

Computer Assisted Sperm Analysis (CASA):

Sperm samples were analyzed using VideoTest® ZooSperm® (rat module) software (Russia). VideoTest® ZooSperm® CASA consists of two standard methods, "Motility" and "Morphology", a facility for automatic report generation, and an in-built database. The parameters analysis is executed automatically [16].

A- Motility standard method:

It was designed to evaluate the concentration of spermatozoa and their motility in a specimen.

To accomplish the analysis, a counting chamber with the specimen was placed under microscope, after which a video was recorded. The recorded objects were threshold and their motion paths were automatically reassembled. The spermatozoon path color was corresponded to its motility class. Several clips could be recorded in order to obtain statistically valid results. The analysis of each clip was transferred to the database.

B- Morphology standard method:

The method was planned to evaluate the spermatozoa morphological parameters and to divulge pathology. Geometrical measurements of spermatozoa heads were used in this method. All parts of the spermatozoa were threshold and measured automatically. The pathology was shown based on the head parameters. The attained results were transferred to the database automatically.

Biochemical analysis in serum:

Serum levels of Follicle Stimulating Hormone (FSH) [17], Luteinizing Hormone (LH) [18] and testosterone [19] were determined by using Rat ELISA Kit purchased from Abcam Company, UK, using the Sandwich-ELISA principle.

Biochemical analysis in tissue:

The left testes were diluted with PBS (pH 7.4), shredded in a glass and homogenized for 3 minutes in cold physiological saline using a Teflon-glass homogenizer. Total protein assay was carried out on homogenized sample to be used for determination of oxidative stress markers. Reduced glutathione (GSH) was determined in the prepared samples according to the method described by Beulter et al., [20]. In order to determine malondialdehyde (MDA), a method described by Draper and Hadley [21] was used. While, Superoxide Dismutase (SOD) activity was assayed by the procedure of Nishikimi et al., [22].

Histopathological examination:

24 hours after fixation of right testes and epididymides in Bouin's solution, the tissues were dehydrated in alcohol, treated with xylene and embedded in paraffin wax. A total of 6 μm -thick sections were cut using a rotary microtome. Sections of testis were processed for hematoxylin-eosin staining, and sections of epididymis were processed for immunohistochemistry of Androgen Receptors (ARs).

Immunohistochemistry procedure:

To execute the standard staining process, first the epididymal sections have to be deparaffinized and rehydrated prior to the primary antibody was

applied. Enzyme-conjugated secondary antibodies were then applied and after addition of the enzyme-specific substrate, the specific staining can be visualized.

Computer assisted digital image analysis (digital morphometric study):

A- *Slide imaging and digitizing:* Slides were photographed using Olympus® microscope with Olympus® digital camera with 0.5 X photo adaptor, using 40 X objective. Analysis of the results was done via Intel® Core I3® based computer using VideoTest Morphology® software (Russia) with a specific built-in automated counting object. Five random fields from each slide and two slides from each rat were prepared and analyzed.

B- *Quantification of androgen receptor:* Firstly, image obtained from the camera via a u-tech® frame grabber. Then, improving color tones of the image based on the hue of target stains. After that, thresholding of the image at the level of the desired stain hue range to form a binary mask that represents target stain area. We define the thresholded area as Region of Interest (ROI). Application of the object counting routine on (ROI) that was utilized to estimate the area percent of target stain in relation to the total field.

Statistical analysis:

Statistical Package for Social Sciences (SPSS) version 16 was used to analyze the data. Data were described as means \pm SD after normality testing using Shapiro-Wilk test. Independent samples *t*-test and One-way ANOVA with LSD post-hoc test were used to compare among groups. "*p*-value ≤ 0.05 " was considered to be statistically significant.

Results

As trying to find out the limonene effects on various aged rat groups, these results detected first the comparison between the control rats in each group to find out the effect of age on different parameters. Then we compare rats supplemented with limonene and control rats in each age group.

Results of sperm parameters:

By comparing the control old aged (IIa) subgroup with the control adult (Ia) rats, Table (1) showed significant decrease in percentage of motile sperms associated with decline in percentage of sperm count and those with normal morphology in epididymal samples. As regard the sperm count in testicular tissue, there was significant decline in subgroup (IIa) as compared to Subgroup (Ia).

Table (1): Comparison of measured sperm samples parameters among different experimental subgroups.

n=8 rats/subgroup	Group I		Group II	
	Ia	Ib	IIa	IIb
% of motile sperms	78.9±3.3	85.8±5.2\$	63±4.7*	70.9±2.8\$
% of change		8.75%		12.54%
% of sperms with normal morphology	71.9±1.6	78.2±7.4\$	56.7±4*	64.2±3.6\$
% of change		8.76%		13.23%
Sperm count (million/ml)	15.1±0.9	18.8±0.1\$	9.3±0.5*	13.3±0.7\$
% of change		24.50%		43.01%
Sperm count in tissue/HPF	6108.2±716	7472.6±755.4\$	4638.6±485.7*	6415.4±773.5\$
% of change		22.33%		38.30%

(Ia) Control adult rats. (IIa) Control old age rats.
 (Ib) Limonene treated adult rats. (IIb) Limonene treated old age rats.
 Test used for analysis is Independent samples *t*-test and One-way ANOVA with LSD post-hoc.
p≤0.05 considered statistically significant.
 \$: Significance between both subgroups in each group.
 *: Significance with Subgroup Ia.
 % of change: Between both subgroups in each group.

Table (1) showed results concerned with comparing limonene treated subgroups with the control ones. As comparing the subgroups of adult rats, the results revealed significant increase in % of sperm motility, % with normal morphology and sperm count in epididymal samples, together with increase of the sperm count in testicular tissue Fig. (1).

Marvelously, by comparing the limonene supplemented old age (IIb) rats with the control old age (IIa) ones, Figs. (2,3) showed significant increase in sperm motility, sperm with normal morphology and sperm count (43.01 %) in epididymal samples, in addition to significant increase in sperm count of testicular tissue (38.30%).

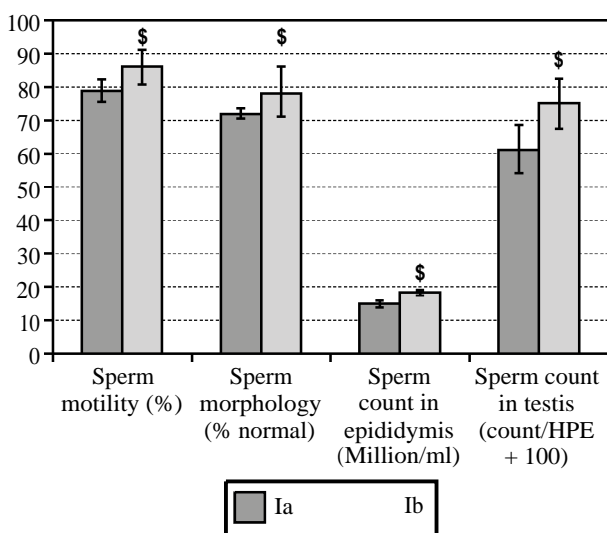


Fig. (1): Comparison of measured sperm samples parameters among adult subgroups.

(Ia) control adult rats. (Ib) limonene treated adult rats.
p≤0.05 considered statistically significant.
 \$: Significance between both subgroups in each group.

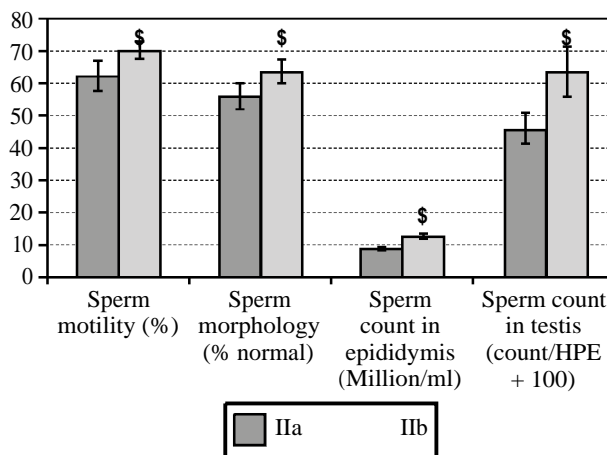


Fig. (2): Comparison of measured sperm samples parameters among old aged subgroups.

(IIa) control old age rats. (IIb) limonene treated old age rats.
p≤0.05 considered statistically significant.
 \$: Significance between both subgroups in each group.

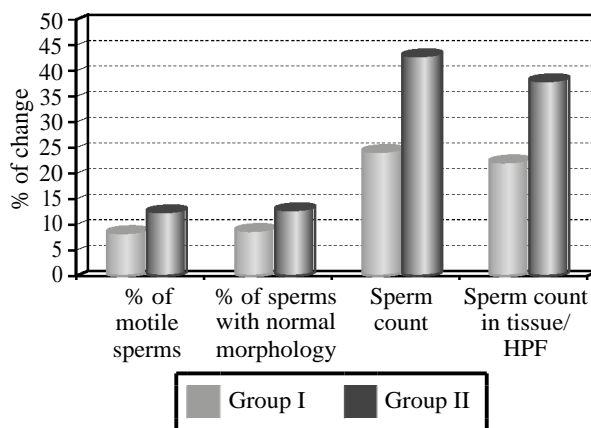


Fig. (3): Illustration of percentage of changes induced by administration of D-limonene in adult and old aged groups.

(I) adult rats. (II) old age rats.
 % of change: Difference between both subgroups in each group.

Results of hormonal levels:

Table (2) expressed significant decrease in testosterone together with significant increase in LH levels in control old aged rats as compared to the control adult ones. While, this comparison showed insignificant increase in FSH level of the old aged control rats.

Also, the results showed significant increase in testosterone level of limonene treated adult (Ib) rats as compared to the control age matched (Ia) ones. In addition to significant decrease in FSH and LH levels in the treated subgroup. In the old age subgroups, the data showed significant increase in testosterone (15.95%) with significant decrease in FSH and LH levels in limonene treated rats as compared to its age matched control one.

Table (2): Comparison of measured hormonal parameters among different experimental subgroups.

n=8 rats/ subgroup	Group I		Group II	
	Ia	Ib	IIa	IIb
Testosterone	28±1.8	33.2±2.5\$	25.7±1.5*	29.8±3.4\$
% of change		18.57%		15.95 %
FSH	8.7±0.5	7±0.3\$	9±0.8	6.9±0.3\$
% of change		19.54%		23.33%
LH	0.3±0.02	0.25±0.01\$	0.33±0.03*	0.24±0.05\$
% of change		16.67%		27.27%

(Ia) Control adult rats.
 (Ib) Limonene treated adult rats.
 (IIa) Control old age rats.
 (IIb) Limonene treated old age rats.
 Test used for analysis is Independent samples *t*-test and One-way ANOVA with LSD post-hoc.
p≤0.05 considered statistically significant.
 \$: Significance between both subgroups in each group.
 *: Significance with Subgroup Ia.
 % of change: Between both subgroups in each group.

Results of oxidative stress markers:

Table (3) showed significant increase in tissue lipid peroxidation level (MDA), together with significant decrease in levels of testicular antioxidants (SOD and GSH) in control rats with increasing age. However, by comparing the two subgroups of adult rats; limonene supplemented rats (Ib) showed significant increase in SOD and GSH with significant decrease in MDA as compared to its control ones (Ia). Also, results revealed that in old age subgroups the limonene treated rats showed significant increase SOD and GSH with significant decrease in MDA as compared to its age matched control rats.

Histopathological results:

As shown in Fig. (4 A) that represents a section of the testis of control adult rat (subgroup Ia), there

are multiple cut sections of seminiferous tubules lined by multiple layers of spermatogenic cells in different stages of development. Spermatogonia are seen resting on the basement membrane with rounded dark nuclei overlaid by layers of developing spermatocytes. Multiple sperms are seen in the lumen of the tubules. Groups of Leydig cells are seen in between seminiferous tubules.

Otherwise, in Fig. (4B) which represents a section of the testis of treated adult rat (subgroup Ib), there are multiple cut sections of seminiferous tubules with increased thickness of spermatogenic cell layers. More sperms are seen in the lumen of the tubules with relative increase in the number of Leydig cells in between seminiferous tubules as compared with subgroup (Ia).

Regarding Fig. (5A), which is a section of the testis of control old aged (subgroup IIa) rat, showing degeneration and vacuolation of the lining cells of some seminiferous tubules with others show irregular outline. Few sperms are seen in the lumen of some tubules that become completely absent in others. Leydig cells are less frequently seen in the thickened interstitial tissue.

While, in Fig. (5B) a section of the testis of treated old aged rat (subgroup IIb) showing marked improvement of the degenerative changes in the seminiferous tubules as compared with subgroup (IIa). Restoration of the thickness of the wall of seminiferous tubules is evident with regularly-organized layers of different types of spermatogenic cells resting on a regular basement membrane. Numerous sperms are seen in the lumen of seminiferous tubules. Also, multiple groups of Leydig cells are seen in the interstitial tissue between the tubules as compared with subgroup (IIa).

Table (3): Comparison of measured testicular oxidative parameters among different experimental subgroups.

n=8 rats/ subgroup	Group I		Group II	
	Ia	Ib	IIa	IIb
MDA	3±0.1	1.9±0.2\$	3.2±0.2*	2±0.1\$
SOD	55.2±4	59.7±4\$	48.7±3.2*	57.2±4\$
GSH	3.5±0.2	4±0.3\$	3.04±0.6*	3.6±0.2\$

(Ia) Control adult rats.
 (Ib) Limonene treated adult rats.
 (IIa) Control old age rats.
 (IIb) Limonene treated old age rats.
 Test used for analysis is Independent samples *t*-test and One-way ANOVA with LSD post-hoc.
p≤0.05 considered statistically significant.
 \$: Significance between both subgroups in each group.
 *: Significance with Subgroup Ia.

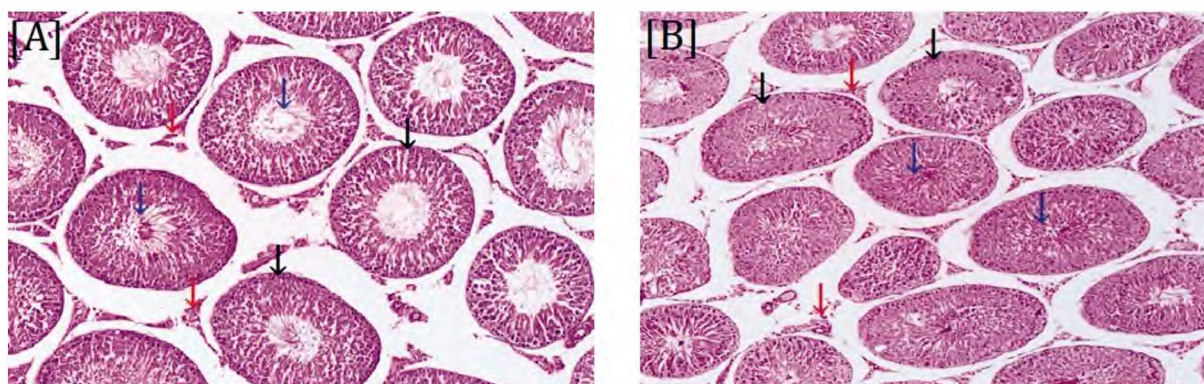


Fig. (4): Photomicrograph of a section of the testis of adult rats: [A] Subgroup Ia showing multiple cut sections of seminiferous tubules (black arrow). Multiple sperms (blue arrow) are seen in the lumen of the tubules. Groups of Leydig cells (red arrow) are seen in between seminiferous tubules. [B] Subgroup Ib showing multiple cut sections of seminiferous tubules (black arrow). More sperms (blue arrow) are seen in the lumen of the tubules. Relative increase in the number of Leydig cells (red arrow), is seen in between seminiferous tubules.

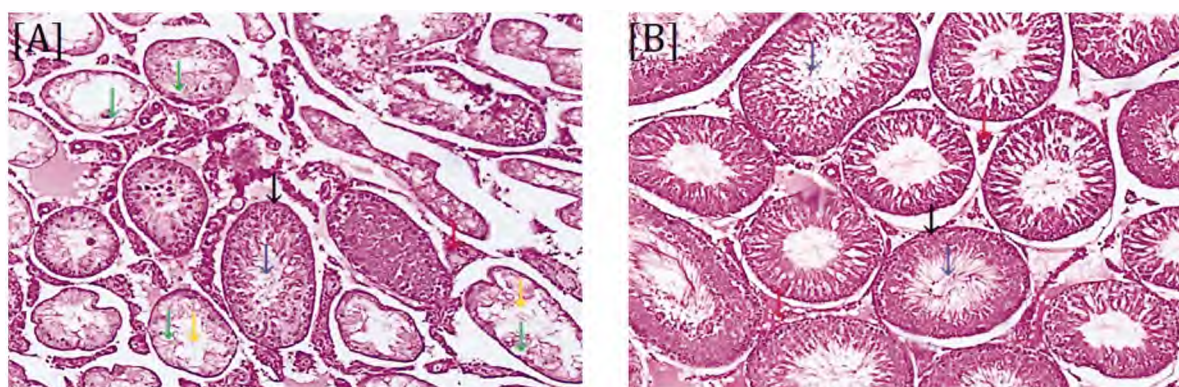


Fig. (5): Photomicrograph of a section of the testis of old aged rats: [A] Subgroup IIa showing degeneration (yellow arrow) and vacuolation (green arrow) of the lining cells of some seminiferous tubules (black arrow). Few sperms (blue arrow) are seen in the lumen of some tubules that become completely absent in others. Leydig cells (red arrow) are less frequently seen in the thickened interstitial tissue. [B]: Subgroup IIb showing restoration of the thickness of the wall of seminiferous tubules (black arrow) is evident. Numerous sperms (blue arrow), are seen in the lumen of seminiferous tubules. Multiple groups of Leydig cells (red arrow) are seen in the interstitial tissue between the tubules.

Immunohistochemical results:

Table (4) and Fig. (7) represented immunohistochemistry for androgen receptor in epididymal tissue of all rats in different experimental subgroups evaluated by digital morphometric analysis. Data were expressed as the percentage area of target stain which represents the androgen receptors as compared to the total field area. This table showed that there was significant increase in androgen receptors density in subgroup (Ib) Fig. (8B) as compared to subgroup (Ia) Fig. (8A) with percentage of change between both subgroups (~28%).

In subgroup (IIb) slides Fig. (9B), there was a significant increase in the density of androgen receptors than those of subgroup (IIa) Fig. (9A), with percentage of change between both subgroups around (~47%).

Table (4): Comparison of androgen receptors density with immunostain among different experimental subgroups.

n=8 rats/ subgroup	Group I		Group II	
	Ia	Ib	IIa	IIb
% area of stain	24.2±2.8	31±4.6\$	11.5±1.3*	16.9±2.2\$
% of change		28.1%		46.96%

(Ia) Control adult rats.

(Ib) Limonene treated adult rats.

(IIa) Control old age rats.

(IIb) Limonene treated old age rats.

Test used for analysis is Independent samples *t*-test and One-way ANOVA with LSD post-hoc.

$p \leq 0.05$ considered statistically significant.

\$: Significance between both subgroups in each group.

*: Significance with Subgroup Ia.

% of change: Between both subgroups in each group.

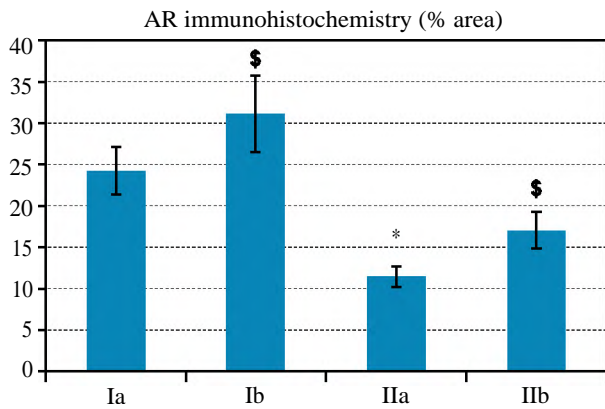


Fig. (7): Comparison of androgen receptors density with immunostain among different experimental subgroups.

(Ia) Control adult rats.
 (Ib) Limonene treated adult rats.
 (IIa) Control old age rats.
 (IIb) Limonene treated old age rats.
 Test used for analysis is Independent samples *t*-test and One-way ANOVA with LSD post-hoc.
 $p < 0.05$ considered statistically significant.
 \$: Significance between both subgroups in each group.
 *: Significance with Subgroup Ia.

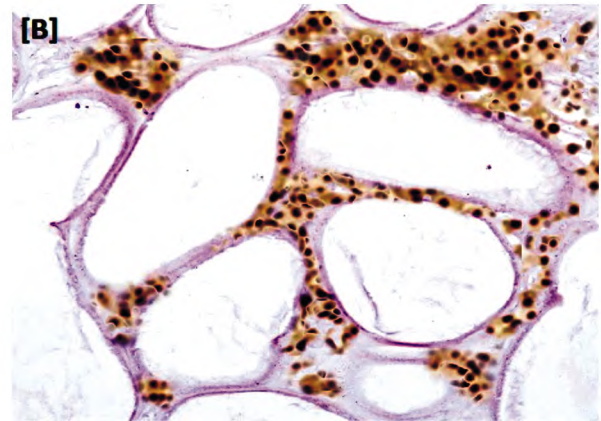
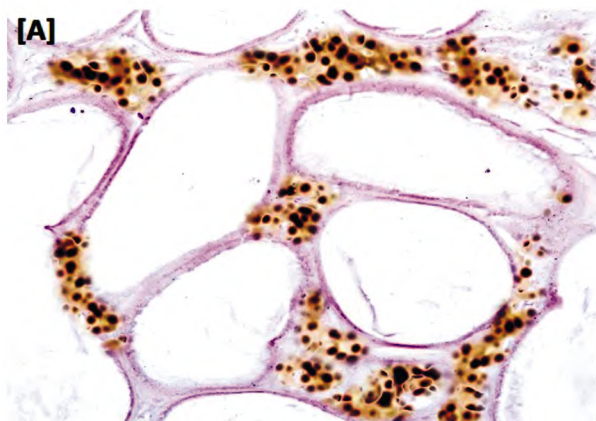


Fig. (8): Show density of androgen receptor with immunostain in adult control rats [A] and adult rats supplemented with D-Limonene [B].

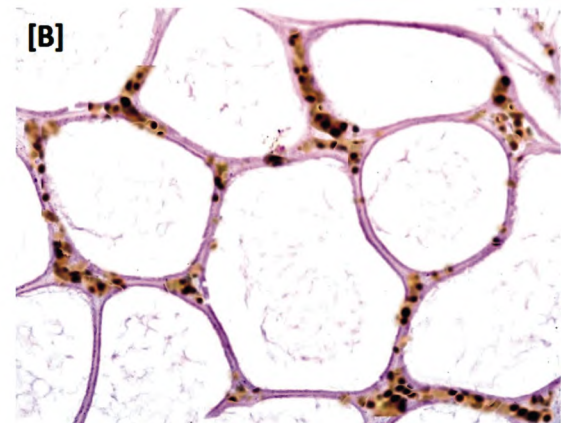
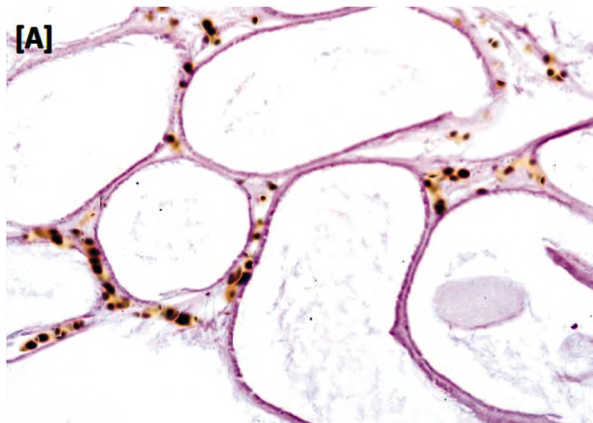


Fig. (9): Show density of androgen receptor with immunostain in old aged control rats [A] and old aged rats supplemented with D-Limonene [B].

Discussion

This is the first research that studies the effect of daily consumption of D-limonene on the androgenic capacity in male rats of different ages; especially, the old aged rats.

Our study demonstrates that sperm parameters change with age. As with aging, there are significant deterioration in all testicular and epididymal sperm parameters. Also, testosterone level is declined

markedly with partially loss of negative feed-back on pituitary gonadotropins as compared to the adult control rats. These results prove what Stone and his colleagues [23] noticed about the daily sperm production and total sperm count which are negatively correlated with age. The present study reveals significant decline in sperm count (~43%), motility and morphology in epididymal samples together with significant decrease in sperm count in testicular tissue (~38%) of old age rats as compared to

adult rats' epididymal and testicular parameters. These changes may be due to functional decline of both testes and accessory glands, expressed as significantly higher mean serum levels of gonadotropins and lower serum free testosterone. Gunes et al., [24] noticed that serum testosterone levels tend to decrease with getting old, which may be particularly due to decline in the Leydig cells number, worsening of testicular perfusion, and disruption in GnRH and pituitary gonadotropin diurnal rhythm secretion.

More than 300 theories have been proposed to explain the aging process, but none has yet been generally accepted by gerontologists. However, the free radical theory of aging hypothesizes a single common process, modifiable by genetic and environmental factors, in which oxygen-derived free radicals are responsible (due to their high reactivity) for the age-associated damage at the cellular and tissue levels. Oxidative stress may cause unfavorable alterations in the reproductive organs, including the epididymis and accessory glands [25]. These alterations may affect normal sperm maturation processes and reduce semen volume [2]. A study indicated that increased ROS levels may be a major cause of idiopathic male infertility [26]. As detected in this present study, the levels of lipid peroxidation show significant increase together with marked decrease in antioxidants in control aged rats as compared to the adult ones.

The present oxidative stress markers results could explain our pathological findings in aged testicular tissues, which reveal degeneration and vacuolation of the lining cells of many seminiferous tubules with very few sperms in some tubules and completely absent in others. Besides, Leydig cells are less frequently seen in the thickened interstitial tissue. Moreover, the decline in androgenic capacity with aging is proved by marked decline in epididymal androgen receptors density detected with immunostain as compared with the control adult group. Our findings are in consistence with Zitzmann [27] results which detected that during the course of aging in human, the thickness of the tunica propria of the basal membrane of seminiferous tubules increases while the seminiferous epithelium reduces. The decline of seminiferous tubules with age is characterized by a decrease in the number of Sertoli cells and germ cells, despite personal differences; the number of Leydig cells also decreases with age [28].

Several studies have shown an association between sperm motility and ROS production, lipid

peroxidation, and sperm oxidative DNA damage [29-31]. Also, Belloc et al., [32] have indicated higher levels of double strand DNA breaks and higher DNA Fragmentation Index (DFI) in older men sperms. In supporting evidence, histological and ultrastructural study by Jiang et al., [33] has shown increased apoptosis along with a reduced proliferation in germ cells of the aging testes.

Our understanding of oxidative stress has given rise to several new treatment modalities, which are now being investigated for improving male infertility. Many new antioxidants are now available which may improve the sperm quality but a major concern in their usage is lack of scientific evidence of their effectiveness. Several studies tried to prove the antioxidant effect of D-limonene in conditions associated with oxidative stress as Murali et al., [34] study that exhibits decline in lipid peroxidation in kidney and liver of diabetic rats with administration of D-limonene. Also, Roberto et al., [35] found that limonene can protect lymphocytes from oxidative stress through enhancing SOD activity and level of hydrogen peroxide.

In the current study, administration of D-limonene to the rats shows reduced levels of lipid peroxidation by-products and increased levels of antioxidants in rats with both age categories as compared to the age matched control ones, which could explain the arrest of free radical-induced damage and antioxidant potential of D-limonene. These results are in consistence with the study of Jesudoss et al., [9] in which limonene alleviates oxidative stress-induced liver injury in high-fat diet and L-NAME treated rats. The antioxidant effect of Limonene in the present study may explain its improving effects on old aged rats as compared with age matched control ones. Our results reveal obvious improvement in sperm analysis including; sperm count, percentage of sperms with normal morphology and motile sperms together with sperm count in testicular tissue specimen in aged rats. Similarly, this effect of limonene in aged rats is associated with significant increase in testosterone level and return of the negative feedback on pituitary gonadotropins as compared to the control aged results. Furthermore, the hormonal levels and sperm parameters show marked improvement in adult rats supplemented with limonene when compared to its age-matched control ones.

Additionally, D-limonene improves the androgen receptor density detected by immunostain in both age groups as compared to their age matched control rats. This improvement appears markedly in old aged rats that express higher percentage of

change approximately 47% than adult rats that improve with a percentage of change around 28%. All these limonene improving parameters are proved with the histopathological findings that show restoration of the thickness of the wall of seminiferous tubules with regularly-organized layers of different types of spermatogenic cells in aged rat's testis. In addition to these findings, numerous sperms in the lumen of seminiferous tubules with multiple groups of Leydig cells in the interstitial tissue are detected. Moreover, limonene exerts obvious improving effects in adult rats' testes showed as increased thickness of spermatogenic cell layers and more sperms in the lumen of the tubules with relative increase in the number of Leydig cells as compared with their age matched control ones.

So, we conclude in this study; that supplementation of D-limonene daily to either adult or old aged rats, especially in old age, can protect the sexual organs from oxidative stress deteriorating effects. This protective effect preserves both the steroidogenic and spermatogenic functions of testes with conservation of the normal count, morphology and motility of manufactured sperms. So, we recommend in this study to add limonene to the diet of old age men and those who exposed to chronic stress in their lives to save, to some extent, their androgenic capacity which may help in treating many cases of male infertility.

Acknowledgements: The Physiology Department and Medical Experimental.

Research Center of Mansoura University are acknowledged for their significant contribution to the experimental part of the study.

Author contribution: All authors designed and performed research, Shereen M Samir wrote the paper.

Conflict of interest: The authors declare that there is no conflict of interest.

References

- 1- TAHMASBPOUR E., BALASUBRAMANIAN D. and AGARWAL A.: A multi-faceted approach to understanding male infertility: Gene mutations, molecular defects and assisted reproductive techniques (ART). *Journal of assisted reproduction and genetics*, 31 (9): 1115-37, 2014.
- 2- KUMAR N., SINGH A. and CHOUDHARI A.: Impact of age on semen parameters in male partners of infertile couples in a rural tertiary care center of central India: A cross-sectional study. *International journal of reproductive biomedicine (Yazd, Iran)*, 15 (8): 497-502, 2017.
- 3- WALCZAK-JEDRZEJOWSKA R., WOLSKI J. and SLOWIKOWSKA-HILCZER J.: The role of oxidative stress and antioxidants in male fertility. *Central European journal of urology*, 66 (1): 60-7, 2013.
- 4- WANG Y., CHEN F., YE L., ZIRKIN B. and CHEN H.: Steroidogenesis in Leydig cells: Effects of aging and environmental factors. *Reproduction (Cambridge, England)*, 154 (4): R111-R122, 2017.
- 5- JIANG H., ZHU W., LI J., CHEN Q., LIANG W. and GU Y.: Quantitative histological analysis and ultrastructure of the aging human testis. *International Urology and Nephrology*, 46 (5): 879-85, 2014.
- 6- VIEIRA A., BESERRA F., SOUZA M., TOTTI B. and ROZZA A.: Limonene: Aroma of innovation in health and disease. *Chemico-Biological Interactions*, 283: 97-106, 2018.
- 7- FUKUMOTO S., MORISHITA A., FURUTACHI K., TERASHIMA T., NAKAYAMA T. and YOKOGOSHI H.: Effect of flavour components in lemon essential oil on physical or psychological stress. *Stress Health*, 24: 3-12, 2008.
- 8- ROBERTO D., MICUCCI P., SEBASTIAN T., GRACIELA F. and ANESINI C.: Antioxidant Activity of Limonene on Normal Murine Lymphocytes: Relation to H2O2 Modulation and Cell Proliferation," *Basic & Clinical Pharmacology & Toxicology*, 106: 38-44, 2010.
- 9- JESUDOSS V., ANTONY S., JAYARAMAN J. and NAMASIVAYAM N.: Dietary D limonene alleviates insulin resistance and oxidative stress-induced liver injury in high-fat diet and L NAME treated rat. *European Journal of Nutrition*, 51 (1): 57, 2012.
- 10- YU X., LIN H., WANG Y., LV W. and ZHANG S.: D-limonene exhibits antitumor activity by inducing autophagy and apoptosis in lung cancer. *OncoTargets and therapy*, 11: 1833-47, 2018.
- 11- KUMMER R., FACHINI-QUEIROZ F.C., ESTEVÃO-SILVA C.F., GRESPLAN R., SILVA E.L., BERSANI-AMADO C.A. and CUMAN R.K.N.: Evaluation of anti-inflammatory activity of Citrus latifolia Tanaka essential oil and limonene in experimental mouse models. *Evidence-Based Complementary and Alternative Medicine*, Article ID 859083: 8 pages. <http://dx.doi.org/10.1155/2013/859083>, 2013.
- 12- PICCINELLI A.C., SANTOS J.A., KONKIEWITZ E.C., OESTERREICH S.A., FORMAGIO A.S. N., CRODA J., ZIFF E.B. and KASSUYA C.A.L.: Antihyperalgesic and antidepressive actions of (R)-(+)-limonene, a-phellandrene, and essential oil from Schinus terebinthifolius fruits in a neuropathic pain model. *Nutritional neuroscience*, 18: 217-24, 2015.
- 13- LAPPAS C.M. and LAPPAS N.T.: D-Limonene modulates T lymphocyte activity and viability. *Cellular immunology*, 279: 30-41, 2012.
- 14- BACANLI M., GÜL ANLAR H., AYDIN S., ÇAL TUGÜ, ARI N., BUCURGAT, ÜÜ ÜG, BAŞARAN A. and BAŞARAN NURŞ: D-limonene ameliorates diabetes and its complications in streptozotocin induced diabetic rats, *Food and Chemical*, 110: 434-42, 2017.
- 15- KLINEFLTER G.R., GRAY L.E. and SUAREZ J.D.: The method of sperm collection significantly influences sperm

- motion parameters following ethane dimethanesulphonate administration in the rat. *Reprod. Toxicol.*, 5: 39-44, 1991.
- 16- MENKVELD R., FRANKEN D.R., KRUGER T.F., OEHNINGER S. and HODGEN G.D.: Sperm selection capacity of the human zona pellucida. *Mol. Reprod Dev.*, 30 (4): 346-52, 1991.
- 17- ZHU D., LI X., MACRAE V.E., SIMONCINI T. and FU X.: "Extragenital Effects of Follicle-Stimulating Hormone on Osteoporosis and Cardiovascular Disease in Women during Menopausal Transition". *Trends in Endocrinology and Metabolism*, 29 (8): 571-80. doi:10.1016/j.tem.2018.06.001. PMID 29983231, 2018.
- 18- STOLÉRU S.G., ENNAJI A., COURNOT A. and SPIRA A.: "LH pulsatile secretion and testosterone blood levels are influenced by sexual arousal in human males". *Psychoneuroendocrinology*. 18 (3): 205-18. doi: 10.1016/0306-4530(93)90005-6. PMID 8516424, 1993.
- 19- CHEN A., BOOKSTEIN J.J. and MELDRUM D.R.: Diagnosis of a testosterone-secreting adrenal adenoma by selective venous catheterization. *Fertil. Steril.*, 55: 1202-3, 1991.
- 20- BEULTER E., DURON O. and KELLY B.M.: Improved method for the determination of blood glutathione. *J. lab. Chem. med.*, 61 (5): 882-880, 1963.
- 21- DRAPER W. and HADLEY M.: "Indirect determination of oxygen free radicals". *Methods Enzymol.*, 186: 421-31, 1990.
- 22- NISHIKIMI M., ROA N.A. and YOGI K.: "The occurrence of superoxide anion in the reaction of reduced phenazine methosulfate and molecular oxygen. *Biochem. Biophys. Res. Commun.*, 46: 849-54, 1972.
- 23- STONE B.A., ALEX A., WERLIN L.B. and MARRS R.P.: Age thresholds for changes in semen parameters in men. *Fertil. Steril.*, 100: 952-8, 2013.
- 24- GUNES S., HEKIM G.N.T., ARSLAN M.A. and ASCI R.: Effects of aging on the male reproductive system. *Journal of assisted reproduction and genetics*, 33: 441-54, 2016.
- 25- EGEA J., FABREGAT I., FRAPART Y., GHEZZI P. and GÖRLACH A.: European contribution to the study of ROS: A summary of the findings and prospects for the future from the COST action BM1203 (EU-ROS). *Redox biology*, 13: 94-162, 2017.
- 26- DURAIRA JANAYAGAM D., AGARWAL A., ONG C. and PRASHAST P.: Lycopene and male infertility. *Asian journal of andrology*, 16: 420, 2014.
- 27- ZITZMANN M.: Effects of age on male fertility. *Best Practice & Research Clinical Endocrinology & Metabolism*, 27 (4): Pages 617-28. <https://doi.org/10.1016/j.beem.2013.07.004>, 2013.
- 28- WU F.C., TAJAR A., BEYNON J.M., PYE S.R., SILMAN A.J., FINN J.D., O'NEILL T.W., BARTFAI G., CASANUEVA F.F. and FORTI G.: Identification of late-onset hypogonadism in middle-aged and elderly men. *N. Engl. J. Med.*, 363: 123-35; PMID: 20554979; <https://doi.org/10.1056/NEJMoa0911101>. 2010.
- 29- SABETI P., POURMASUMI S., RAHIMINIA T., AKYASH F. and TALEBI A.R.: Etiologies of sperm oxidative stress. *International Journal of Reproductive Biomedicine*, 14: 231, 2016.
- 30- PETERSEN C.G., MAURI A.L., VAGNINI L.D., RENZI A., PETERSEN B., MATTILA M., COMAR V., RICCI J., DIEAMANT F. and OLIVEIRA J.B.A.: The effects of male age on sperm DNA damage: An evaluation of 2,178 semen samples. *JBRA assisted reproduction*, 22: 323, 2018.
- 31- BEATTIE M., CHEN H., FAN J., PAPADOPOULOS V., MILLER P. and ZIRKIN B.: Aging and luteinizing hormone effects on reactive oxygen species production and DNA damage in rat Leydig cells. *Biology of reproduction*, 88 (4): 100, 2013.
- 32- BELLOC S., BENKHALIFA M., COHEN-BACRIE M., DALLEAC A., AMAR E. and ZINI A.: Sperm deoxyribonucleic acid damage in normozoospermic men is related to age and sperm progressive motility. *Fertility and sterility*, 101: 1588-93, 2014.
- 33- JIANG H., ZHN W.J., LI J., CHEN Q.J., LIANG W.B. and GU Y.Q.: Quantitative histological analysis and ultrastructure of the aging human testis. *International urology and nephrology*, 46: 879-85, 2014.
- 34- MURALI R., KARTHIKEYAN A. and SARAVANAN R.: Protective effects of D-limonene on lipid peroxidation and antioxidant enzymes in streptozotocin-induced diabetic rats. *Basic & clinical pharmacology & toxicology*, 112: 175-81, 2013.
- 35- ROBERTO D., MICUCCI P., SEBASTIAN T., GRACIELA F. and ANESINI C.: Antioxidant activity of limonene on normal murine lymphocytes: Relation to H2O2 modulation and cell proliferation. *Basic & clinical pharmacology & toxicology*, 106: 38-44, 2010.

تأثير د. ليمونين على التغيرات الذكورية المرتبطة بالعمر لذكور الجرذان

المقدمة: إن التقدم في العمر يصاحبه آثار تدهور على الوظائف الفسيولوجية لكثير من الأعضاء ومنها الأعضاء التناسلية، والتي يعتقد أنها إلى حد كبير مرجعها إلى الإجهاد التأكسدي. ولذلك فإن الإتجاه إلى إستخدام مضادات الأكسدة قد يؤدي إلى تحسن في تلك الوظائف. وقد تم إكتشاف العديد من الخواص العلاجية لمادة الليمونين المستخلصة من قشور الموالح وذلك لإملاكه خواص مضادة للأكسدة.

ولذلك فإن الهدف من هذا البحث هو:

أولاً: بحث التغيرات الذكورية في ذكور الجرذان المتقدمة في العمر ممثلة في: قياس مستوى الهرمونات (تستوستيرون، FSH، LH) في الدم، فحص كامل لعينات الحيوانات المنوية وتحديد مستقبلات الهرمون الذكوري في البربخ عن طريق الصبغة المناعية.

ثانياً: محاولة إيجاد الآثار المفيدة المحتملة لليمونين على هذه التغيرات الذكورية.

طريقة الدراسة: لإجراء هذه الدراسة، تم تقسيم إثنان وثلاثون جرد ذكر إلى مجموعتين رئيسيتين وهما:

المجموعة الأولى: جردان بالغة ناضجة جنسياً (٤-٥ شهراً).

المجموعة الثانية: جردان متقدمة في العمر (٢٠-٢٤ شهراً).

كل مجموعة تم تقسيمها إلى مجموعتين فرعيتين تحتوى كل منهما على ٨ جردان:

• مجموعة فرعية (أ): مجموعة ضابطة.

• مجموعة فرعية (ب): مجموعة تم إعطاها الليمونين (٥٠مجم/كجم) عن طريق الفم لمدة ٤ أسابيع.

بعد إنتهاء مدة الدراسة (٤ أسابيع)، تم أخذ عينات من الدم وإزالة الخصيتين والبربخ لإستخدامهم في قياس الهرمونات ودلالات الإجهاد التأكسدي وفحص كامل لعينات الحيوانات المنوية، بالإضافة إلى تحديد مستقبلات الهرمون الذكوري بإستخدام الصبغة المناعية، وإجراء فحص نسيجي.

النتائج والمناقشة: أظهرت النتائج للمجموعة الضابطة للجرذان المتقدمة في العمر إنخفاض ذو دلالة إحصائية في عدد وشكل ونسبة الحركة في عينات الحيوانات المنوية بالإضافة إلى الإنخفاض الملحوظ في مستقبلات الهرمون الذكوري ومضادات الأكسدة ومستوى هرمون التستوستيرون عند مقارنتهم بمستوياتهم في المجموعة البالغة الضابطة. ولقد كان من المدهش أن إعطاء الليمونين للجرذان أظهر تقدماً ملحوظاً في القدرة الذكورية في المجموعتين العمريتين خصوصاً في الجرذان المتقدمة عمرياً والتي يمكن إرجاعها لقدرتها على زيادة مضادات الأكسدة وتقليل آثار الإجهاد التأكسدي على الأعضاء التناسلية. وقد تم إثبات هذا الأثر الفعال عن طريق الفحص النسيجي وفحص العينات المنوية وانتشار مستقبلات الهرمون الذكوري في البربخ.

الخلاصة: إعطاء الليمونين يومياً للجرذان وخصوصاً المتقدمة في العمر قد أدى دوراً كبيراً في حماية الأعضاء التناسلية من الإجهاد التأكسدي المحدث من التقدم العمري والمؤدى إلى التدهور في الوظائف الفسيولوجية لهذه الأعضاء.