

## Role of Multi Detector Computed Tomography (MDCT) in Evaluation of Operated Malignant Neck Tumors

MOHAMMED H. ABO WARDA, M.D.; MAGED A. HAMED, M.D.; MANAR A. BESSAR, M.D. and  
AYMAN S. MAHMOUD, M.Sc.

The Department of Radiodiagnosis, Faculty of Medicine, Zagazig University, Egypt

### Abstract

**Background:** Neck cancers are common worldwide and have many subtypes according to site of origin. The management of them involves multidisciplinary evaluation and treatment which may include surgery, radiation therapy, and chemotherapy. Post-operative findings include tumor recurrence and post-operative complications. Imaging plays an important role in the post-treatment surveillance of neck cancer and one of these imaging modalities is MDCT which offers rapid image acquisition and are helpful in acute clinical diagnosis and provide precise anatomic detail.

**Aim of Study:** Is to review CT findings after neck cancer surgery (post-operative changes) and differentiate them from persistent or recurrent tumors.

**Patients and Methods:** This study was carried out at Radio Diagnosis Department, Zagazig University Hospitals; the present study was carried on 48 patients of operated neck cancers. CECT were done.

**Results:** This study included 48 patients with operated neck tumors, 35 cases of tumor recurrence and 9 cases of post-operative changes and 4 cases with tumor recurrence associated with post-operative changes. All patients underwent CECT. Biopsies were made for all suspected cases of tumor recurrence after surgical intervention for histological types identification.

**Conclusion:** Our results show that contrast enhanced multi detector CT is considered a good non-invasive tool for evaluation of operated malignant tumors in correlation with histopathological biopsy after surgery

**Key Words:** CECT – Tumor recurrence – Post-operative complications.

### Introduction

**THE** anatomy of the neck has long been a challenge to clinicians and radiologists. The neck is a cylinder. The vertebral column, with its surrounding musculature, occupies the posterior half of the cylinder. The cervical viscera (the pharynx, larynx, esophagus,

trachea, and parathyroid and thyroid glands) lie in the anterior half of the cylinder. Superiorly, the neck is bounded by the mandible anteriorly, and the base of the skull posteriorly. Inferiorly, the neck is bounded by the scapulae posteriorly, and the thoracic inlet centrally. The thoracic inlet consists of the sternum, the first ribs, and the first thoracic vertebral body [1].

Neck cancers have common sites according to organ of origin like thyroid, larynx, oropharynx and salivary glands. The management of neck cancer involves multidisciplinary evaluation and treatment, which may include surgery, radiation therapy, and chemotherapy [2].

The post-treatment imaging findings in patients with neck cancer can be divided into 3 groups: Altered anatomy secondary to surgical reconstruction, potential postsurgical complications and tumor recurrence [3].

Often tumor recurrence may not be evident clinically until the recurrence is large enough to be clinically palpable, and hence imaging plays an important role in the post treatment surveillance of head and neck cancer. Furthermore, radiation therapy may induce tissue distortions such as edema, inflammation, and fibrosis which make post-treatment images more difficult to interpret. It is therefore important to be familiar with the characteristics of common post-treatment changes and to distinguish these characteristics from those of tumor recurrence and treatment-related complications [4].

---

### Abbreviations:

CECT : Contrast Enhanced Computed Tomography.  
MDCT : Multi Detector Computed Tomography.  
SCC : Squamous Cell Carcinoma.

---

**Correspondence to:** Dr. Ayman S. Mahmoud,  
[E-Mail: Aymansaid51990@yahoo.com](mailto:Aymansaid51990@yahoo.com)

MDCT allows the acquisitions of image datasets with isotropic resolution, from which multi planar thin-section images and three-dimensional images can be reconstructed and offers rapid image acquisition. Certain distinguishing CT characteristics (e.g., the patterns of lesion mineralization, degree of attenuation, and involvement in adjacent bone, and the degree and pattern of vascularity) may be suggestive of a specific diagnosis [5].

### Patients and Methods

#### Patients:

48 patients with operated neck cancers were referred from the surgery and ENT Departments to the Radio-Diagnosis Department, Zagazig University Hospitals in the period from July 2018 to July 2019. The ages range from 30 to 70 years with mean age group  $\pm$  SD  $55.08 \pm 11.25$  and 36 of them are males and the remaining 12 are females. The study was carried after obtaining institutional board review from our hospital. Written informed consent was obtained from all participants and the study was approved by the Research Ethical Committee of Faculty of Medicine, Zagazig University. The work has been carried out in accordance with The Code of Ethics of the World Medical Association (Declaration of Helsinki) for studies involving humans.

#### Patient inclusion criteria:

- 1- Any age.
- 2- Any sex.
- 3- Any patient with history of operated neck tumor followed by adjuvant radiation therapy.

#### Patient exclusion criteria:

##### Absolute contraindications:

- 1- Patients with elevated renal functions, but not on dialysis.
- 2- Patients with contraindications to contrast media.
- 3- Pregnant females.

##### Relative contraindications:

Patients of renal diseases on dialysis.

*Methods: All patients were subjected to the following:*

- 1- Full clinical history: Personal history (name, age, sex, type of the operation, its timing and patient's complaint like as swelling or sore that doesn't heal (the common complaint), Hoarseness or change in voice, lump or mass in the head or neck area, with or without pain ...etc , life style: As smoking and drinking alcohol and

medical history: As Human Papillomavirus (HPV) infection which is recognized as a potential risk factor in neck Squamous Cell Carcinoma (SCC).

#### 2- Clinical examination:

- *Physical examination:* To feel any neck lump.
- *Blood and urine tests:* May be done to help diagnosing cancer.
- *Biopsy:* A common type of biopsy is called a fine needle aspiration. During this procedure, cells are withdrawn using a thin needle inserted directly into the tumor or lymph node. The cells are examined under a microscope for cancer cells, which is called a cytological examination.

#### Technique of examination:

*Positioning:* Head first, supine with arms by the sides of the trunk with hands tucked under the hips. Head rest/support can be applied to restrict the neck movements.

#### CECT protocol:

- 1- *Scan type:* Multi slice (with contrast injection); the purpose of Contrast-Enhanced CT (CECT) is to find pathology by enhancing the contrast between a lesion and the normal surrounding structures.
- 2- *Anesthesia:* Generally not required, but may be indicated depending on the patient. Anesthesia on these studies always needs to be authorized by a radiologist.
- 3- *Scan start/end locations:* Axial images from external auditory meatus to aortic arch.
- 4- *Respiratory phase:* Inspiration.
- 5- *Contrast injection:*
  - Contrast type: Iohexol (Omnipaque 300).
  - Contrast volume: 70ml.
  - Contrast injection rate:
- A- *5cc/sec through an 18 gauge IV catheter:*
  - Use for instance a green venflon. Test by fast injection of 10cc NaCl manually.
  - Hold the arm stretched.
- B- *4cc/sec through a 20 gauge pink venflon.*
- 7- *Scan delay:* 35 seconds.

*Image interpretation: Cases were revised and analyzed to assess:*

- Making sure that the scan is optimal and no need for re imaging if the contrast isn't properly injected.

- Analysis of image findings: Like post-operative changes, tumor recurrence and late complications after surgery.

*Statistical analysis:*

The findings of imaging studies were evaluated and correlated to clinical and histopathological results. Sensitivity, specificity, positive predictive value, negative predictive value, and accuracy intervals were calculated.

**Results**

This study included 48 cases with operated neck cancers. Regarding age distribution, their ages ranged from (30 to 70 years) with the mean age was 55 years; the most common age group was 60-70 years old found in 22 patients (45.8%) as shown in (Table 1). Regarding sex distribution, it was noted that males (36 patients) were affected more than females (12 patients) that represent 75% and 25% respectively as shown in (Table 2). Regarding post-operative assessment of our patients by histopathological biopsy correlated with image findings, tumor recurrence was found to be the most common imaging finding which was present in 35 patients (72.9%) followed by post-operative changes in 9 patients (18.8%) and tumor

recurrence with postoperative changes in 4 patients (8.3%) as shown in (Table 3). Regarding the pathological types, the most common pathological type of recurrent neck tumors in our study was squamous cell carcinoma seen in 17 patients which represents (35.4%) of the total number as shown in (Table 4). Regarding post-operative changes, it was observed that vascular complications either accelerated atherosclerosis of the internal carotid artery or thrombosis of the internal jugular vein were the most common findings and found in 4 patients (8.3%), osteoradonecrosis is observed in 3 cases (6.25%) while mucosal necrosis and serous retention are rare findings were found only in two cases, one case for each of them (2%) as shown in (Table 5).

Table (2): Shows sex distribution of the patients included in the study.

Variable	N=48	%
Sex:		
Male	36.00	75.0
Female	12.00	25.0

Table (4): Shows the post-operative histo-pathological results of the patients included in this study.

Pathological result	N=48	%
Carcinoma ex-pleomorphic adenoma	1	2.1
Follicular thyroid carcinoma	7	14.6
Lymphoma	2	4.2
Muco-epidermoid carcinoma	1	2.1
Medullary thyroid carcinoma	6	12.5
Schwanoma	1	2.1
Squamous cell carcinoma	17	35.4

Table (1): Shows age distribution of the studied cases.

Variable	Mean ± SD	Range
Age/year	55.08± 11.25	(30.0-70.0)
	No.	%
30-<40	2	4.16
40-<50	8	16.7
50-<60	16	33.3
60-70	22	45.8

Table (3): Shows results of the post-operative assessment of studied cases.

Post-operative assessment	N=48	%
Tumor recurrence	35	72.9
Post-operative changes	9	18.8
Tumor recurrence with post-operative changes	4	8.3

Table (5): Displaying post-operative changes found in our patients.

Post-operative changes	N=9	%
• Mucosal necrosis	1	11.1
• Osteoradionecrosis	3	33.4
• Thrombosis of the IJV	2	22.2
• Accelerated atherosclerosis of the internal carotid artery	2	22.2
• Serous retention	1	11.1

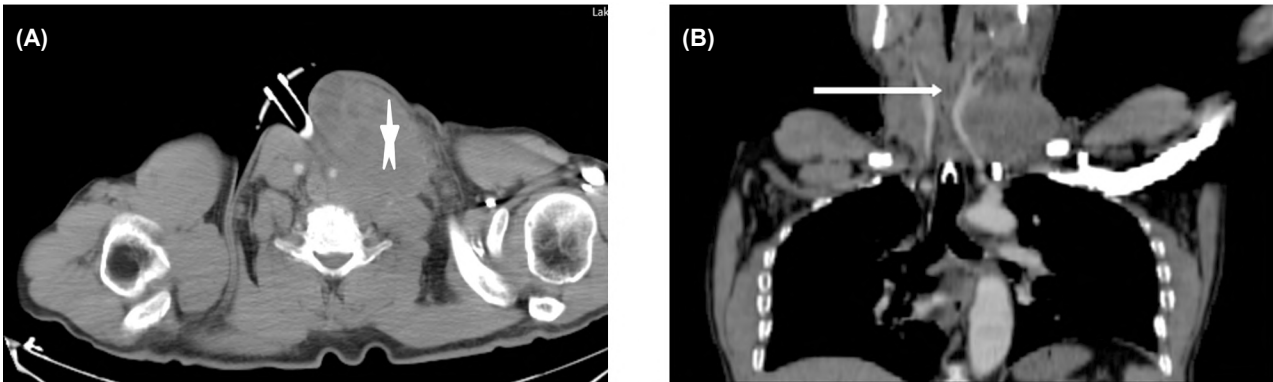


Fig. (1): Recurrent squamous cell carcinoma. A male patient, 66 years old with left lower neck soft tissue mass after laryngectomy and total thyroidectomy. (A) Axial MDCT image shows: Left lower neck homogenous soft tissue mass (star) seen displacing the tracheostomy tube medially with lost in between fat planes. (B) Coronal MDCT image shows: The displacement of the carotid sheath (arrow) by the large left lower neck mass.

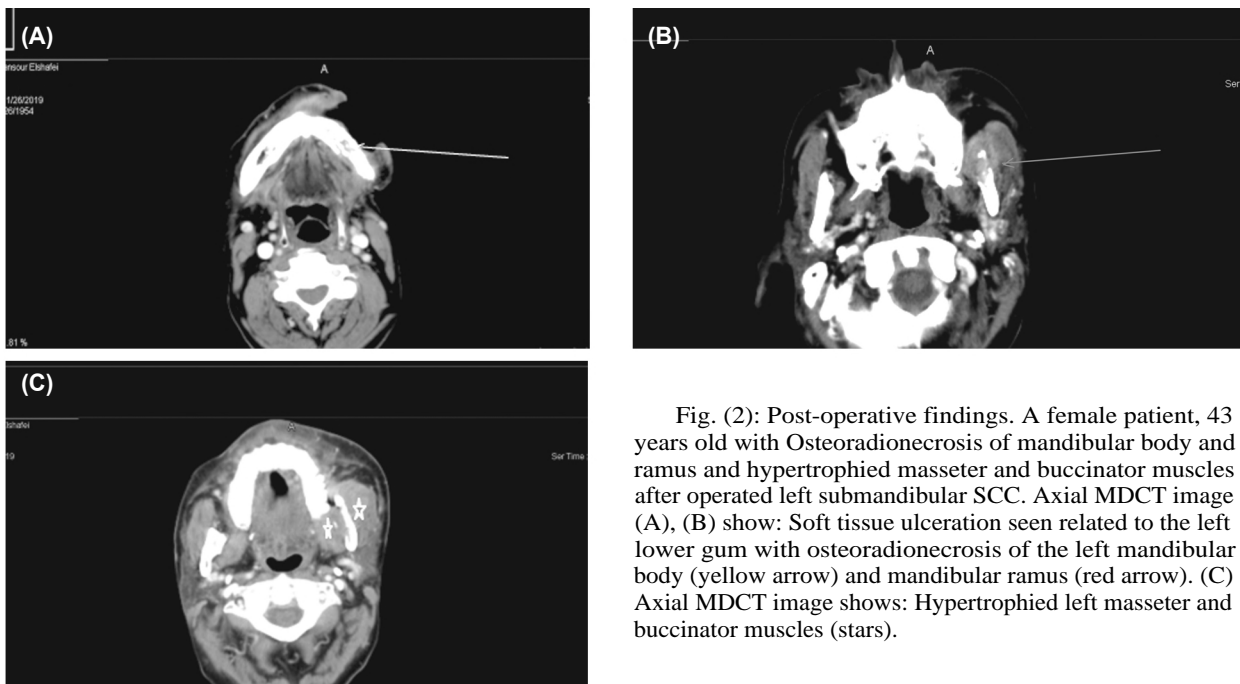


Fig. (2): Post-operative findings. A female patient, 43 years old with Osteoradionecrosis of mandibular body and ramus and hypertrophied masseter and buccinator muscles after operated left submandibular SCC. Axial MDCT image (A), (B) show: Soft tissue ulceration seen related to the left lower gum with osteoradionecrosis of the left mandibular body (yellow arrow) and mandibular ramus (red arrow). (C) Axial MDCT image shows: Hypertrophied left masseter and buccinator muscles (stars).

**Discussion**

Neck cancer is the sixth most common worldwide and its management involves multidisciplinary evaluation and treatment, which may include surgery, radiation therapy, and chemotherapy in some cases [6].

The postsurgical imaging findings in patients with neck cancer can be divided into 2 groups: Postsurgical complications and tumor recurrence [3].

Here we discuss the role of MDCT in evaluation of operated neck cancers as it offers rapid image acquisition. MDCT allows the acquisitions of image

datasets with isotropic resolution, from which multi planar thin-section images and three-dimensional images can be reconstructed [7].

Our study included 48 patients with operated malignant neck tumors referred to radiology department with clinical suspicion of post-surgical complications (may be due to associated radiotherapy) or tumor recurrence [7].

There were 48 patients in our study, 36 males (75.0%) and 12 females (25.0%). This was in agreement with Jon Andrew Ridge et al., [8] who reported that recurrent neck cancers are more common in males with percentage 66% to 95% of cases.

Regarding sex distribution, our study was in agreement with Jemal A et al., [9] who mentioned that ratio of head and neck cancer in male to that in females ranging from 2:1 to 4:1. This ratio may be explained by many risk factors; one of these factors is Human Papilloma Virus (HPV) which considered one of the most common causes of head and neck cancer especially oropharyngeal cancers in males.

The ages of our studied cases ranged between 30-70 years with. Mean age  $55.0 \pm 11.1$  years. 16 cases were between 50-60 years old and 22 cases were between 60-70 years old while number of cases younger than 50 years are about 10 cases which was in agreement with Jon Andrew ridge et al., [8] who reported that the incidence of neck cancer increases with age, especially after 50 years of age.

This may be explained by Cook-Wiens G et al., [10] study who mentioned that Tobacco-related head and neck squamous cell cancer (the most common type) is widely accepted as a disease that disproportionally affects elderly individuals.

Regarding outcomes after total laryngectomy, our study was in contrast to Shi RJ et al., [11] whose study included 82 patients underwent total laryngectomy and he reported that the 1 year survival rate was 97.5% while our study showed that the main percentage of cases with tumor recurrence either with or without post-operative changes occurred after total laryngectomy which were reported about 41.7% (20 cases) either post-surgical complications or tumor recurrence.

In our study, there were 7 cases (14.6%) were diagnosed to have loco regional recurrence after total thyroidectomy done for treatment of follicular thyroid carcinoma and these results were in agreement with Carsten E. Palme et al., [12] who had study included 524 patients with papillary thyroid carcinoma and 201 patients treated with total thyroidectomy and only 35 patients had recurrence after treatment.

Our study was in agreement with Anslem Osasuyi et al., [13] regarding out come after radical parotidectomy. In his study, a total of 20 patients underwent parotidectomy and only five cases (33.3%) had post-operative complications and in our study there were only 1 case (2%) out of the total number (48 cases) had post-operative complications.

In contrast to Timothy R. Helliwell et al., [14] who had a retrospective study including 699 pa-

tients with performed radical neck dissections. One hundred nineteen patients who had undergone radical neck dissections had recurrence. Factors that increased the risk of neck recurrence in this study were neck node (N) status and no adjuvant radiotherapy while in our study all our cases had adjuvant radiotherapy or/and chemotherapy which improves post-surgical out comes.

In agreement with Daniel W. Bowles et al., [15] who reported that 80 cases out of the total number (170 cases) which were diagnosed to have Squamous Cell Carcinoma (SCC) of the head and neck would experience tumor recurrence. In our study, 20 cases of the total number (48 cases) had recurrence of SCC which proved pathologically after the surgery.

Also in our study, 30 cases with tumor recurrence were detected late after surgical intervention followed by radiotherapy or chemotherapy. This was in agreement with Naoko Saito et al., [16] who mentioned that tumors typically recur within the first 2 years after treatment and only few cases are detected within weeks after surgery and before adjuvant radiotherapy.

Regarding post-operative changes, mucosal necrosis was detected in only one case (11.1%) out of the total number (9 cases) and this was in agreement with Naoko Saito et al., [16] who mentioned that mucosal necrosis is un common complication of radiotherapy and heals spontaneously within 6 months.

Also in our study, only one case had serous retention that was in contrast with Naoko Saito et al., [16] who mentioned that serous retention is a common complication after neck surgery.

In our study, of the total number of cases with post-operative changes, 4 cases (44.4%) had vascular complications in the form of thrombosis of internal jugular vein and accelerated atherosclerosis of internal carotid artery and this was in agreement with Naoko Saito et al., [16] who mentioned that vascular complications are common in patients with head and neck cancer treated with radiation therapy.

In our study, osteoradionecrosis was found in 3 cases (33.4%) and it was considered a large number regarding the total number of cases diagnosed with post-operative changes (9 cases). This was in agreement with Alhilali L, et al., [17] his study included 63 patients and osteoradionecrosis was diagnosed in 46 patients.

Our results indicate that the non-invasive contrast enhanced MDCT provide reliable information for the assessment of operated malignant neck tumors.

#### Conclusion:

Contrast enhanced multi detector CT is considered a good non-invasive tool for evaluation of operated malignant tumors as tumor recurrence may not be evident clinically until the recurrence is large enough to be clinically palpable. Correlation with histopathological biopsy after surgery confirms suspected findings with CECT. CECT also can differentiate between recurrent tumors and post operative changes that may resemble them. There are imaging modalities that may be used in correlation with CECT to confirm presence of tumor recurrence after surgery as PET-CT.

#### References

- 1- HARNBERGER H.R., CHRISTINE M. GLASTONBUR, MICHEL M.A., et al.: Diagnostic Imaging: Head and Neck. 3rd Edition, 2016.
- 2- De SCHEPPER A.M. and BLOEM J.L.: Soft tissue tumors: Grading, staging, and tissue-specific diagnosis; Top. Magn. Reson. Imaging, 2007.
- 3- SOM P.M., LAWSON W., HUGH D. CURTIN, et al.: The post-treatment neck: Clinical and imaging considerations In Head and neck imaging. 5th ed. St Louis, Mo: Mosby, 2011.
- 4- MUKHERJI S.K. and WOLF G.T.: Evaluation of head and neck squamous cell carcinoma after treatment; AJNR A, 2003.
- 5- De BREE R., VAN DER PUTTEN L., JONAS A. CASTELIJS, et al.: Detection of locoregional recurrent head and neck cancer after (chemo) radiotherapy using modern imaging, 2012.
- 6- DECHEN WANGMO TSHERING VOGEL and HARRIET C. THOENY: Cross-sectional imaging in cancers of the head and neck: How we review and report, 2016.
- 7- MANIKANTAN K., KHODE S., DWIVEDI R.C., et al.: Making sense of post-treatment surveillance in head and neck cancer: When and what of follow-up, 2009.
- 8- JOHN ANDREW RIDGE, RANEE MEHRA, COLIN T. MURPHY, et al.: Head and Neck Tumors; American journal of oncology.
- 9- JEMAL A., SIMARD E.P. and TORRE L.A.: International trends in head and neck cancer incidence rates: Differences by country, sex and anatomic site; journal of oral oncology, 2014.
- 10- COOK-WIENS G., ZUMSTEG Z.S., YOSHIDA E., et al.: Incidence of Oropharyngeal Cancer Among Elderly Patients in the United States; Jama oncology, 2016.
- 11- SHI R.J., XU C.Z., ZHANG C.P., et al.: Outcomes of laryngectomy in elderly patients with laryngeal carcinoma; Department of Oral & Maxillofacial-Head & Neck Oncology, Shanghai, 2014.
- 12- CARSTEN E. PALME, ZEESHAN WASEEM, NAWEED RAZA, et al.: Management and Outcome of Recurrent Well-Differentiated Thyroid Carcinoma; otolaryngeal head and neck surgery, 2004.
- 13- EYITUOYO OKOTURO and ANSLEM OSASUYI: Clinical Outcome of Parotidectomy with Reconstruction: Experience of a Regional Head and Neck Cancer Unit; Nigerian Journal of Surgery, 2016.
- 14- TIMOTHY R. HELLIWELL, ANDREW S JONES, SANKALAP TANDON, et al.: Survival of patients with neck recurrence following radical neck dissection: Utility of a second neck dissection; journal of oral oncology, 2018.
- 15- DANIEL W. BOWLES, KRISHNA REDDY, WINE T., et al.: Loco regional Recurrence of an HPV-Positive Squamous Cell Carcinoma of the Head and Neck journal of oral oncology, 2011.
- 16- NAKO SAITO, ROHINI N. NADGIR, MITSUHIKO NAKAHIRA, et al.: Post treatment CT and MR Imaging in Head and Neck Cancer: What the Radiologist Needs to Know; RSNA, 2012.
- 17- ALHILALI L., REYNOLDS A.R. and FAKHRAN S.: Osteoradionecrosis after radiation therapy for head and neck cancer: Differentiation from recurrent disease with CT and PET/CT imaging; AJNR, 2014.

## دور الأشعة المقطعية متعددة المقاطع في تقييم أورام الرقبة الخبيثة ما بعد التدخل الجراحي

أجريت هذه الدراسة بقسم الأشعة التشخيصية، مستشفيات جامعة الزقازيق في الفترة من شهر يوليو ٢٠١٨ إلى شهر يوليو ٢٠١٩، وقد اشتملت الدراسة على ٤٨ مريضاً بأنواع مختلفة من أورام الرقبة وتم إجراء تدخل جراحي لهم مصحوباً في بعض الحالات بالعلاج الإشعاعي أو الكيماوي وتراوحت أعمارهم ما بين ٣٠-٧٠ عاماً بمتوسط ٥٠ عاماً. هدفت هذه الدراسة إلى تقييم دور الأشعة المقطعية متعددة المقاطع باستخدام الصبغة في تقييم أورام الرقبة ما بعد التدخل الجراحي. وقد أثبتت نتائج الدراسة كفاءة الأشعة المقطعية متعددة المقاطع في المتابعة الدورية لحالات أورام الرقبة ما بعد التدخل الجراحي والتفرقة بين تغيرات ما بعد التدخل الجراحي ومعاودة الورم مرة أخرى.