



Journal of Bioscience and Applied Research

JBAAR

WWW.JBAAR.ORG



The possible protective effect of vitamin E and/or silymarin on rat testes exposed to 950MHz electromagnetic field

Amr Mahmoud Abd El-Hady* and Noaman Abd El-Latif. El-Tahawy**

* Faculty of Applied Medical Sciences, Misr University for Science and Technology (MUST), 6th of October, Cairo, Egypt.

** Radiation Biology Dept. National Centre for Radiation Research and Technology (NCRRT), atomic energy authority, P.O. Box 29, Nasr city, Cairo, Egypt.

Corresponding author email: amreem2005@yahoo.com

Abstract

This work aims to study the histopathological and histochemical changes in the testes of male albino rats post exposure to mobile phone radiation and the possible protective role of vitamin E and/or silymarin. The current experiment was carried out on 30 adult male albino rats (Sprague dawly). Rats were randomly and equally divided into five groups: 1) Group C: control rats left without treatment; 2) Group R: rats exposed to frequency equals 950 MHz of electromagnetic field (EMF); 3) Group R + E: rats received vitamin E before exposure to frequency equals 950 MHz of EMF; 4) Group R + S: rats received silymarin before exposure to frequency equals 950 MHz of EMF and 5) Group R + E+ S: rats received vitamin E parallel to silymarin before exposure to frequency equals 950 MHz of EMF. Electromagnetic field exposed rats showed testicular alterations which were ameliorated by using either vitamin E or silymarin alone. However, both vitamin E and silymarin administration ameliorated the damaging effects of testes of mobile phone exposed rats more than that of silymarin or vitamin E alone.

Key words. Mobile phones, electromagnetic field, vitamin E, silymarin, testis.

1 Introduction

Modern technology allowed the development of many different instruments emitting electromagnetic waves such as mobile phones, microwaves, television sets, satellite signals, radar and transmitting and receiving stations and also computers. Humans are exposed to electromagnetic waves every day, more than the day before. Electromagnetic radiofrequency radiation from a mobile

phones, Wi-Fi, microwaves or other devices were reported earlier to affect negatively male fertility (Hales et al., 2005; Lukac et al., 2011), whereas a number of studies in contrast did not show any abnormalities (Dasdag et al., 2003; Chung et al., 2005).

Exposure to extremely low and high electromagnetic fields (ELF-EMF) affect living cells and tissues. There are an increasing number of cell phone users all over the world and the question is whether Micro Wave (MW) of these instruments could cause health hazards (Dasdag et al., 2003). There has been increasing interest in the biological effects and possible health outcomes of weak, high frequency electric and magnetic fields (Knaue, 2001). When the biological systems were exposed to an external magnetic field with a very large strength relative to the biomagnetic field of the cells, a disturbance in their metabolic function is expected and may lead to death of the cells or increase their cell division (Horiuchi et al., 2002).

Exposure of mice to 900-1800 MHz microwaves affected the histological structure of testis particularly Leydig cells and showed an apoptosis-inducing effect on the spermatogenic cells (Nassar, 2009). Free radical formation and their interaction with biological system is a matter of major concern. There is evidence of free radical generation after RF microwave exposures (D'Angelo et al., 2015). EMF may disturb reactive oxygen species (ROS) metabolism by increasing the production of ROS or by decreasing the activity of antioxidant enzymes (Abd El Rahman et al., 2014). ROS generated by mobile phones exposure if not scavenged may lead to widespread lipid, protein and DNA damage (Jajte et al., 2002).

Electronic household items and cell phones are reported to decrease fertility potential in men by decreasing sperm count, motility and viability and inducing pathological

changes in sperm and testes morphology (Erogul et al., 2006). Spermatogenesis is a complex process takes place in the testis, which may be exposed to various microwave frequencies which are currently in use (Behari and Kesari, 2006). Among various factors of infertility, oxidative stress has become the main focus of interest as a potential cause of male infertility (Kumar et al., 2010).

Vitamin E is one of the major antioxidants, it plays an important role in reducing oxidative stress (Aydogan et al., 2014). It is the most important hydrophobic antioxidant protecting biological molecules like DNA, proteins and lipids against ROS (Alba et al., 2008). It has also been shown to suppress lipid peroxidation in testicular microsomes and mitochondria and to reverse the detrimental effects of oxidative stress on the testicular function (Al-Damegh, 2012). Vitamin E administration to male albino rats post-exposure to 900 MHz of mobile phone radiation showed significant anti-damaging effect of the lung tissues more than the anti-damaging effect of silymarin (Mohamed, 2014).

Silymarin or Silybum marianum is a complex mixture of four flavonolignan isomers, namely, silybin, silychristin, silydianin, and isosilybin (Salter et al., 2001; Shaarawy et al., 2009). Silymarin has been reported to have antioxidative, anti-inflammatory, immunomodulatory, anti-lipid and liver-regenerating properties (Pradhan and Girish, 2006). Silymarin is the most used natural compound for the treatment of hepatic diseases worldwide due to its antioxidant, anti-inflammatory and anti-fibrotic activities; it functions by stabilizing biological membranes and increasing protein synthesis (Vargas-Mendoza et al., 2014). The present study was designed to investigate the histopathological and histochemical changes in the testicular tissues exposed to 950 MHz mobile phone radiation and the possible protective role of vitamin E and silymarin either alone or in combination.

2 Materials and Methods

Animals: 30 Male albino rats (Sprague dawley) 10 ± 2 weeks old weighing 120 ± 20 g were obtained from the Egyptian Holding Company for Biological Products and Vaccines (Cairo, Egypt). Animals were housed collectively in plastic cages, maintained under standard conditions of light, ventilation, temperature and humidity and allowed free access of standard pellet diet and tap water. Animals were acclimatized to laboratory conditions before starting the experiment. All animal procedures were carried out in accordance with the Ethics Committee of the National Research Centre conformed to the "Guide for the Care and Use of Laboratory Animals" published by the US National Institutes of Health.

Electromagnetic wave exposure: irradiation was carried out at the National Center for Radiation Research and Technology (NCRRT), Nasr city, Cairo, Egypt. Animals were housed collectively in wooden cages (30 x 40 x 40 cm; W x L x H) exposed to 950 MHz (EMF) with constant power about 1.4 mW/cm² measured during the experiment using power (Holaday Industries Inc., UK). The whole body

average specific absorption rate, 1.2 W/kg, was calculated from the relation specific absorption rate (SAR) = Power/density

Vitamin E treatment: vitamin E was purchased as a concentrate of DL-alpha-tocopheryl acetate with the highest purity from Pharco-Pharmaceutical Company, Cairo Egypt. The concentrate was suspended in distilled water and given orally to rats at a dose of 1.35 mg/Kg body weight 3 times/week for 2 months, two hours before exposure to radiation (Jarrin et al., 2002).

Silymarin treatment: silymarin was purchased from South Egypt Drug Industries Company (SEDICO), South Egypt, Egypt. Silymarin was suspended in distilled water and administered to rats via gavages at a dose of 18 mg/Kg body weight 3 times/week for 2 months two hours before exposure to frequency equals 950 MHz of radiation (Abou Safi, 2005).

Experimental design: animals were randomly divided into five groups (n=6), these groups were: 1) Group C: control rats normal healthy rats left without any treatment; 2) Group R: rats exposed to frequency equals 950 MHz of EMF 2hrs/day, 3days/week for 2 months; 3) Group R + E: rats received vitamin E 1.35 mg/ kg, b.wt, suspended in distilled water, 3 times/week for 2 months two hours before exposure to frequency equals 950 MHz of EMF; 4) Group R + S: rats received silymarin 18 mg/ kg, b.wt, suspended in distilled water, 3 times/week for 2 months two hours before exposure to frequency equals 950 MHz of EMF and 5) Group R + S+ E: rats received vitamin E parallel to silymarin 3 times/week for 2 months two hours before exposure to frequency equals 950 MHz of EMF.

Histopathological and histochemical observations:

Rats of the control and treated groups were sacrificed after two months and the testes were immediately excised and fixed in 10% formol saline and Carnoy's fixative. Paraffin section (5µm in thickness) were prepared for processing the histological and histochemical studies. For general histology sections were stained with haematoxylin and eosin and Mallory's trichrome stain to illustrate collagen fibers (Bancroft and Gamble, 2008). Polysaccharides were detected by using periodic acid Schiff's (PAS) method (Drury and Wallington, 1980); DNA was detected using Feulgen reaction (Kiernan, 1981). Total proteins were detected using the mercury bromophenol blue method (Pearse, 1972).

Image analysis and statistical analysis:

Image analysis was performed at the Pathology Department, National Research Center using the Leica Qwin 500 Image Analyzer (LEICA Imaging Systems Ltd, Cambridge, England,). Polysaccharides, total protein and DNA materials were calculated. The SPSS/PC computer program was used for statistical analysis of the results. Data were analyzed using one-way analysis of variance (ANOVA) followed by Post Hoc LSD test. The data were expressed as mean \pm standard deviation (SD). Differences were considered statistically significant at (P < 0.05).

3 Results

Histopathological observations

The control group C: light microscopic examination of the stained sections of testes illustrates the normal histological structure of the seminiferous tubules, basement membranes, spermatogenic cells, normal sperms and interstitial cells of Leydig (Fig. 1). Irradiated group R: the testes of the irradiated rats showed many histopathological changes represented as disorganization, degeneration, decreased diameters and atrophy in some seminiferous tubules with highly dilated interstitial spaces, highly decreased spermatogenic layers and spermatogenic cells, highly reduced number and size of Leydig cells which were randomly distributed in between the seminiferous tubules, highly reduced number of mature sperms with debris of degenerated cells collected in the middle of the seminiferous tubules and delaminated spermatogenic cells from their basement membranes. Hyalinization inside some seminiferous tubules with highly distorted seminiferous tubules and Leydig cells were also noted (Figs. 2, 3 & 4).

Vitamin E and silymarin treated groups R + E, R + S, and R + E + S: examination of the testicular tissues of rats treated with vitamin E showed somewhat normal appearance of most seminiferous tubules and Leydig cells. In spite of normal appearance of some seminiferous tubules, some showed delamination of spermatogenic layers from the basement membranes (Fig. 5). The testicular tissues of male albino rats of R + S group showed obvious signs of improvement in the seminiferous tubules and Leydig cells with reappearance of mature sperms (Figs. 6 & 7). However, the testicular tissues of male rats of R + E + S group showed somewhat normal architecture where most of the seminiferous tubules retained their normal appearance with normal spermatogenic layers and Leydig cells in between them (Figs. 8 & 9).

Mallory's trichrome stained sections of the testes of the control group show normal distribution of the collagen fibres supporting cellular membranes of the spermatogenic layers, Leydig cells, basement membranes of the seminiferous tubules and the connective tissue (Fig. 10).

Irradiated R group showed highly increased collagen fibres under the testicular capsule, basement membranes, Leydig cells and around the blood vessels with signs of fibrosis in the capsule and some seminiferous tubules (Figs. 11, 12, 13 & 14). Reduced collagen fibres were observed in the testicular tissues of R + E group (Fig. 15) and R + S group in and around the seminiferous tubules (Fig. 16). Somewhat normal appearance of collagen fibres was noted in R + E + S group in the seminiferous tubules and their basement membranes and in mature sperms with no signs of fibrosis (Fig. 17).

Histochemical observations and image analysis of the testes

Polysaccharides

Fig. (18) showing normal distribution of PAS +ve reaction (magenta color) in the testes of the control C group where moderate staining affinity is seen in the basement membranes of the seminiferous tubules and Leydig cells

with deeply stained heads of mature sperms. Reduced staining affinity of the PAS +ve materials in the testicular tissue of rats of R group was detected (Figs. 19). However, increased PAS +ve materials were realized in either vitamin E (Fig. 20) or silymarin treated groups (Figs. 21 & 22). More obvious increase in PAS +ve materials was demonstrated in both silymarin and vitamin E treated group (Fig. 23) as compared to control group.

Image analysis of PAS +ve materials showed that EMF caused marked diminution ($P < 0.05$) of polysaccharides content in the testicular tissue (0.180 ± 0.022) as compared to control value (0.261 ± 0.030). However, either vitamin E or silymarin treated groups showed a significant increase ($P < 0.05$) in PAS positive materials (0.225 ± 0.036) and (0.244 ± 0.038) respectively as compared to control value. A significant increase ($P < 0.05$) was also detected in both silymarin and vitamin E treated group and nearly reached the control value (0.261 ± 0.030) (Table 1).

Total protein

The testicular tissue of the control rat group shows normal distribution of the total protein content represented by deeply stained granules inside the nuclei and cytoplasm of all spermatogenic cells. The boundaries of the seminiferous tubules as well as intertubular connective tissue showed strong mercury bromophenol blue reaction (Fig. 24). However, decreased staining affinity of total protein was noticed in the testicular tissue of the irradiated R group (Figs. 25 & 26). To some extent, normal appearance of the total protein was detected in either vitamin E (Fig. 27) or silymarin treated groups (Figs. 28, 29 & 30) which were more obvious in both silymarin and vitamin E treated group (Figs. 31 & 32).

Mean optical density values showed significant decrease ($P < 0.05$) in total protein (0.473 ± 0.072) in the irradiated group as compared to that of the control value (0.553 ± 0.065); whereas a significant increase ($P < 0.05$) in total protein content was detected in either vitamin E (0.531 ± 0.040) or silymarin (0.545 ± 0.039) treated groups as compared to control value. In addition both vitamin E and silymarin administrated group showed a significant increase ($P < 0.05$) in total protein value (0.597 ± 0.069) in a degree more or less similar to that of the control value (Table 1).

DNA

The nuclei of the cells of testicular tissue of the control rats showed normal distribution of DNA in the form of granules of magenta color in the nuclei of all spermatogenic cells. Strong reaction is also seen in the interstitial cells and Sertoli cells (Fig. 33). Exposure of rats to EMF of mobile phone showed a noticeable reduction in DNA content of the nuclei (Figs. 34 & 35) compared to DNA contents of the control group. The testicular tissue of vitamin E treated group also revealed a decrease in Feulgen stained materials (Fig. 36). An increase in the DNA +ve materials was noticed in silymarin treated group (Figs. 37 & 38) and more

obvious increase was observed in both silymarin and vitamin E treated group (Fig. 39).

Optical density measurements showed significant decrease ($P < 0.05$) in DNA content post-exposure to EMF (0.190 ± 0.026) as compared to that of the control value (0.302 ± 0.043). Also, a significant decrease ($P < 0.05$) in DNA materials was noted in vitamin E treated group (0.196 ± 0.020) as compared to that of the control value; whereas silymarin administrated group showed a significant increase in DNA content (0.241 ± 0.028) as compared to control value. A significant increase ($P < 0.05$) was also noted in both silymarin and vitamin E treated group (0.268 ± 0.045) as compared to the control value (0.302 ± 0.043) (Table 1).

4 Discussion

Cell phones have become a vital part of our lives. Cell phones emit radiofrequency electromagnetic waves (RF-EMW) to nearby relay base stations or antennas. Our bodies act as antennas that absorb the radiation and convert it into electric and magnetic fields. Leydig cells, seminiferous tubules and spermatozoa are the main targets of the damage caused by mobile phones on the male reproductive tract. In particular, cellular phone exposure reduces testosterone biosynthesis impairs spermatogenesis and damages sperm DNA (La Vignera et al., 2012).

The current study showed that exposure of male rats to 950 MHz EMF three days a week, day after day, for two months induced disorganization, degeneration and atrophy in some seminiferous tubules with dilated interstitial spaces and highly reduced Leydig cells. Delaminated spermatogenic cells from the basement membrane, ruptured basement membranes of some seminiferous tubules, decreased spermatogenic layers and spermatogenic cells with highly reduced sperms in the lumen of the seminiferous tubules were also realized. EMF of 950 MHz radiation selected in the present experiment because it is a frequency of the Global System Mobile (GSM) signal modulation used for all mobile communication (Khalil et al., 2012).

Electric field exposure significantly affected the testes and caused histological changes (Erpek et al., 2007). Carrying the mobile phones near reproductive organs for longer time may have negative effects on the sperm motility and male fertility (Fejes et al., 2005; Kesari and Behari, 2008). In agreement with the present findings Cao et al. (2009) showed that magnetic fields at 1000 Hz or 2000 Hz damaged the testes by inducing injury to the seminiferous tubules and Leydig cells, thickening of the basal membranes, massive apoptosis and necrosis of the spermatogenic cells in the lumen and consequently resulted in the absence of sperm. In addition Kesari et al. (2010) showed reduced sperm count and increased apoptosis in male Wistar rats exposed to 900 MHz 2 h/d for 45 days. Moreover, Chen et al. (2011) indicated that long-term microwave radiation caused injury to male reproduction, which was positively correlated with the radiation dose.

Histopathological manifestations of testicular damage in the current experiment may be due to an imbalance between the activities of an oxidant agent and the antioxidant system within the cell. It is well known that cytotoxicity is related to reactive oxygen species (ROS), superoxide radical (O_2^-), hydrogen peroxide (H_2O_2), and hydroxyl radical (OH^*), which are produced by various factors. This link causes oxidative damage to cell membrane, increases in oxygen radical's production and ultimately permits leakage of enzymes, leading to organ damage (Uttara et al., 2009). ROS can harm cells by depleting enzymatic and/or non-enzymatic antioxidants triggering progressive dysfunction and eventually genotoxic events (Kong and Lin, 2010).

Mobile phone radiation results in increased oxidative stress, with subsequent sperm membrane lipid and DNA damage. These abnormalities seem to be directly related to the duration of mobile phone use (La Vignera et al., 2012). Metabolic processes which generate oxidants and antioxidants can be influenced by environmental factors such as EMFs (Kovacic and Somanathan, 2010). Increased EMFs exposure can modify the cellular balance by generating reactive oxygen species (Simko, 2007; Achudume et al., 2010) which could be responsible for the testicular tissue damage appeared in the present experiment.

In contrast to the current findings Ribeiro et al. (2007) reported that rats exposed to RF-EMR emitted by cellular phone (1835– 1850 MHz) for 1 h/d for 11 weeks had similar testicular and epididymal weight, lipid peroxidation levels, serum total testosterone volume, and epididymal sperm count compared to unexposed control rats. Also, the results of Meo et al. (2011) showed that no spermatogenesis abnormalities were found in rats exposed to mobile phone radiation for 3 months.

Results of the present experiment showed that single administration of vitamin E to rats for 2 months before exposure to 950 MHz of EMF resulted in remarkable regenerative features as most of the seminiferous tubules and Leydig cells retained their normal histological appearance in spite of the presence of numerous empty spaces in between the spermatogenic cells. Single administration of silymarin for 2 months prior to exposure of 950 MHz of mobile phone radiation showed obvious signs of recovery indicated by more or less normal appearance of the seminiferous tubules and Leydig cells with normal arrangement of the spermatogenic layers and cells with reappearance of mature sperms. Administration of both silymarin and vitamin E before exposure to 950 MHz of mobile phones radiation showed somewhat normal testicular architecture where most of the seminiferous tubules and Leydig cells retained their normal appearance in a degree better than their single administration.

The current observations come in agreement with the previous reports of Jacobs et al. (2002) and Oral et al. (2006) who reported that antioxidants can protect living cells from radiation damage by ameliorating the deleterious effect of free radicals. Also supplementation with antioxidants (vitamins A, E, C + Selenium) scavenging

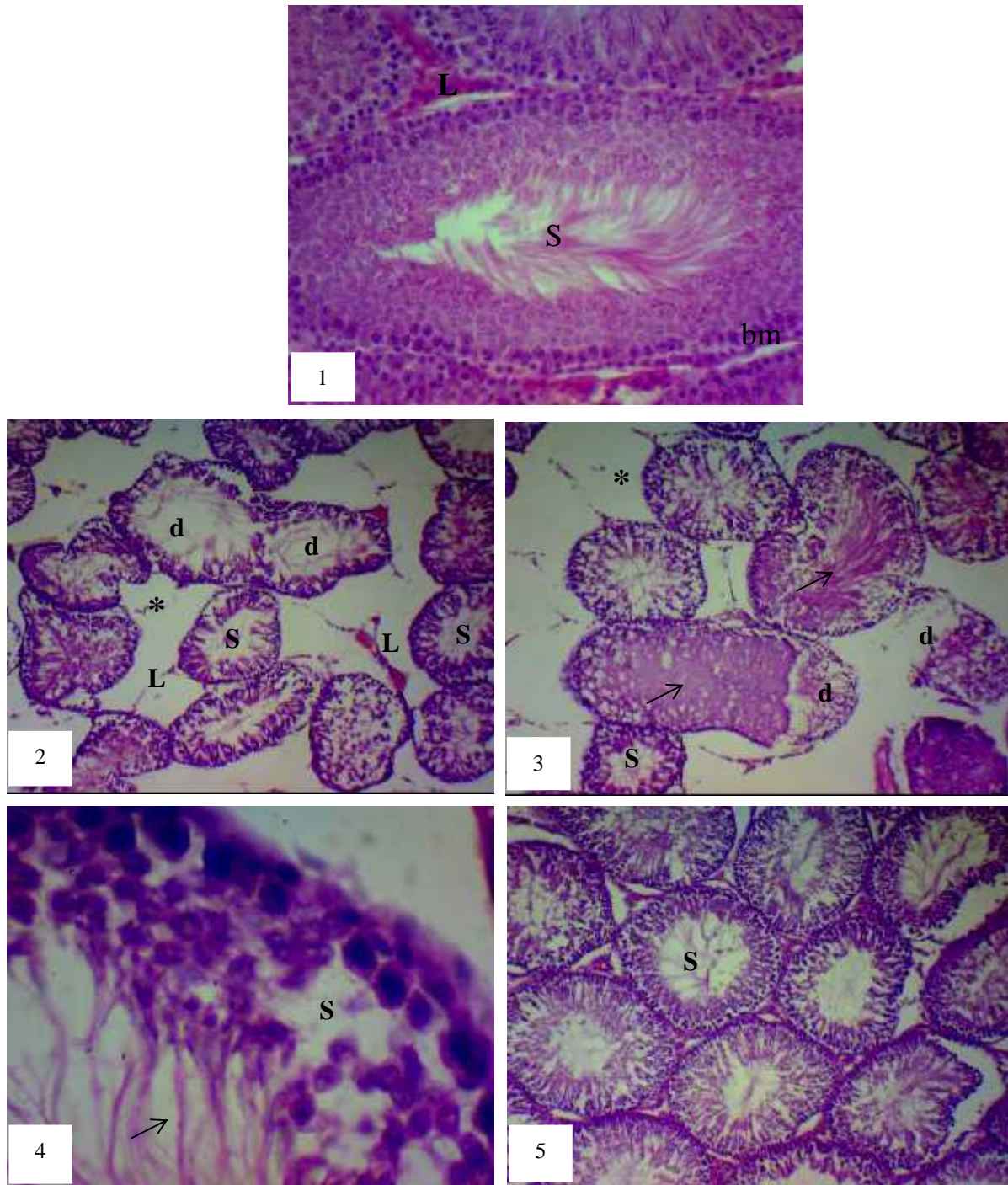
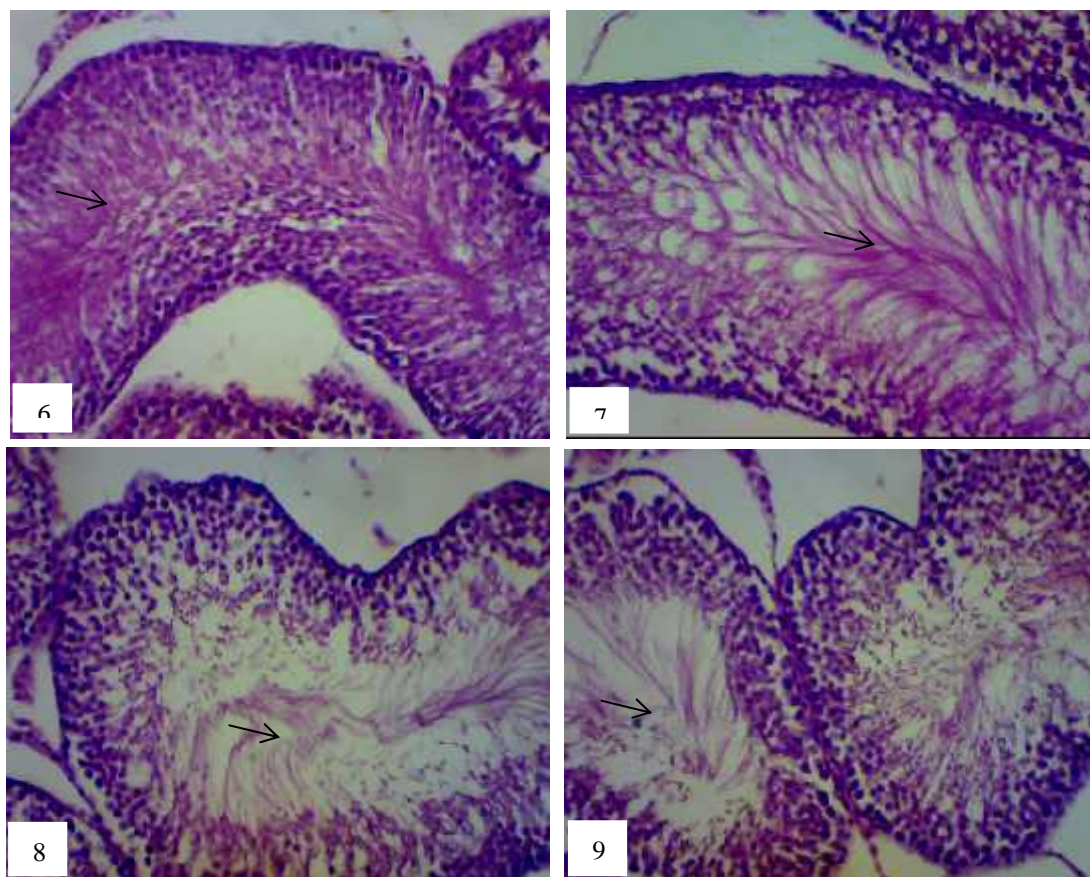


Fig.1. Testicular tissue of the C group showing seminiferous tubules (S) which are surrounded by the basement membranes (bm), sperms in the lumens and interstitial tissue in between the tubules which containing Leydig cells (L). (H&E X 200). Figs. 2-4. Testicular tissue of R group showing disorganization (*), degeneration (d), decreased diameters and atrophy in some seminiferous tubules (S), widening of interstitial spaces, highly reduced sperms (arrow) in the lumen of the seminiferous tubules (S), highly reduced Leydig cells (L) with decreased number of spermatogenic layers and their cells (sp). (2, 3 X 200 & 4 X 400). Fig. 5. Testicular tissue of R+E group showing remarkable regenerative features. (X 200).



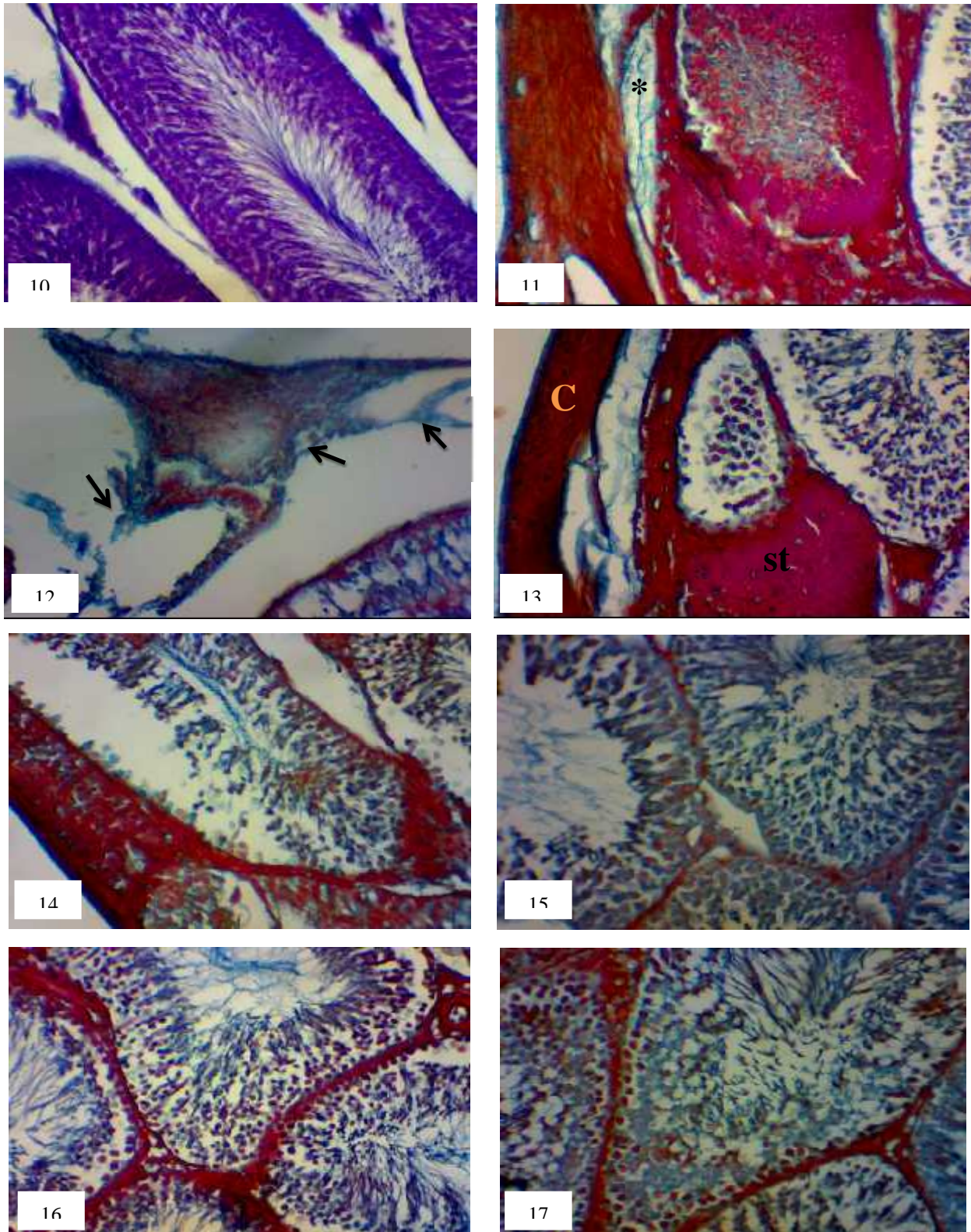
Figs. 6,7. Testicular tissue of R+S group showing signs of improvement in the seminiferous tubules and Leydig cells (L) with reappearance of mature sperms (arrow). (X 200). Figs. 8,9. Testicular tissue of R+S+E group showing improved architecture of the spermatogenic layers and their cells. (X 200)

Table 1: showing mean optical density (MOD) values of polysaccharides, total protein and deoxyribonucleic acid (DNA) contents in the testicular tissues of the control and treated rat groups.

Groups	Polysaccharides	Total protein	DNA
1- Control	0.261±0.030	0.553±0.065	0.302±0.043
2- R group % change	0.180±0.022 ^a -31.15 %	0.473±0.072 ^a -14.47 %	0.190±0.026 ^a -37.09 %
3- R + E group % change	0.225±0.036 ^{ab} -13.80 %	0.531±0.040 ^{ab} -3.99 %	0.196±0.020 ^a -35.10 %
4- R + S group % change	0.244±0.038 ^{ab} -6.51 %	0.545±0.039 ^{ab} -1.45 %	0.241±0.028 ^{ab} -20.20 %
5- R + E + S group % change	0.321±0.034 ^{ab} 22.99 %	0.597±0.069 ^{ab} 7.96 %	0.268±0.045 ^{ab} -11.26 %

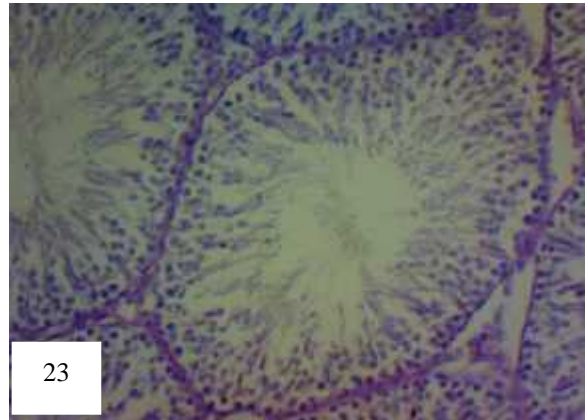
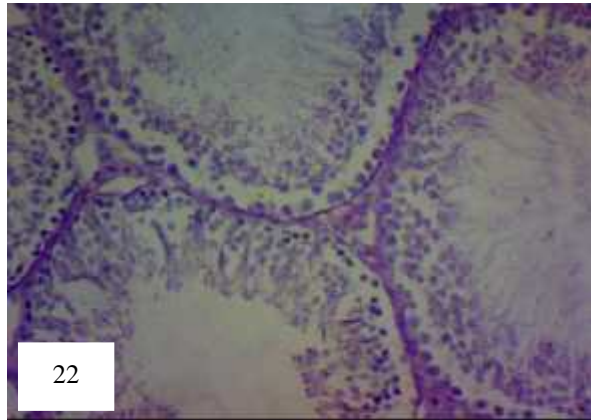
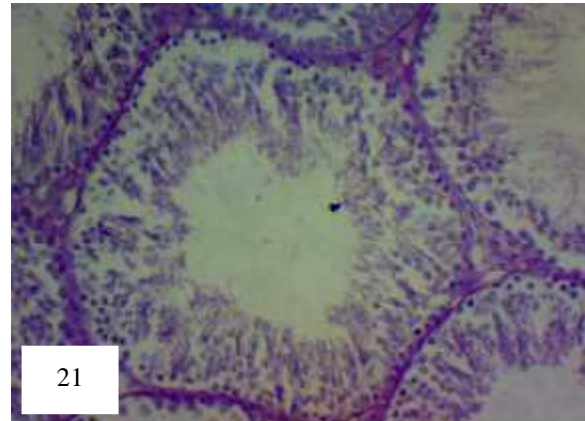
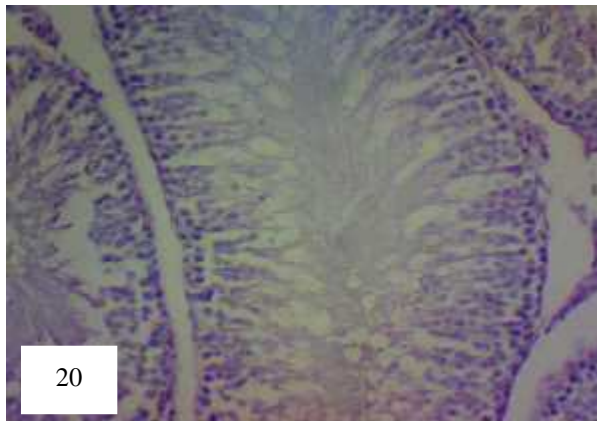
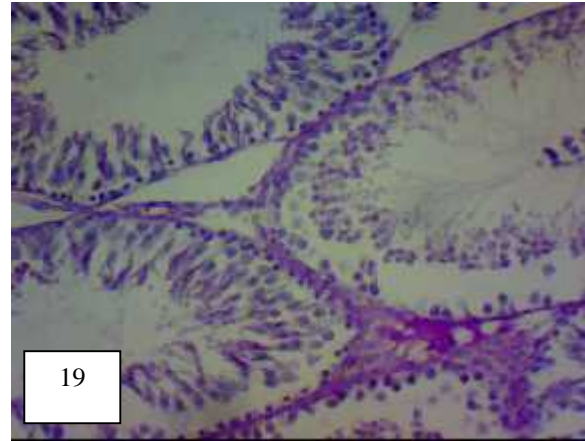
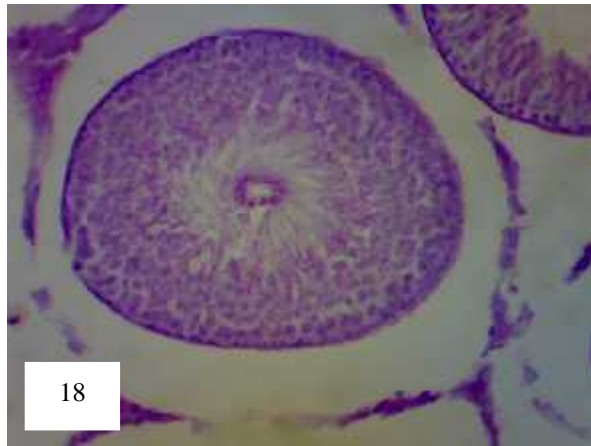
Values are expressed as Means ± Standard Deviation (n=10 readings from each group).

^a : significant vs control, ^b : significant vs EMF group at P<0.05



Figures 10-17 Photomicrographs showing distribution of collagen fibres in the testicular tissue of rats of the control and treated groups (Mallory's trichrome stain X 200)

Fig. 10. Showing thin collagen fibres supporting the walls of the spermatogenic cells and Leydig cells in the interstitial spaces of the testicular tissue of the control group. Fig. 11-14. Testicular tissue of R group showing increased collagen fibres under the capsule (*), in the interstitial spaces especially, in the oedematous regions (arrow) and inside the seminiferous tubules. Notice: signs of fibrosis (brightly red stained) in the capsule (C) and in some seminiferous tubules (st). Figs. 15-17. Testicular tissue of R+E₁₅, R+S₁₆ and R+S+E₁₇ groups showing somewhat normal appearance of collagen fibres inside the seminiferous tubules and interstitial spaces.



Figures 18-23 Photomicrographs showing distribution of PAS +ve materials in the testicular tissue of rats of the control and treated groups (PAS X 200)

Fig. 18. Normal distribution of the PAS +ve materials in the seminiferous tubules of the control group. Fig. 19. Testicular tissue of the R group showing reduced PAS +ve materials inside the seminiferous tubules with an increase in some oedematous areas in between the seminiferous tubules (*). Figs. 20-23. Testicular tissue of R+E₂₀, R+S₂₁, ₂₂ and R+S+E₂₃ groups showing somewhat normal appearance of PAS +ve materials in the testes of the mentioned groups.

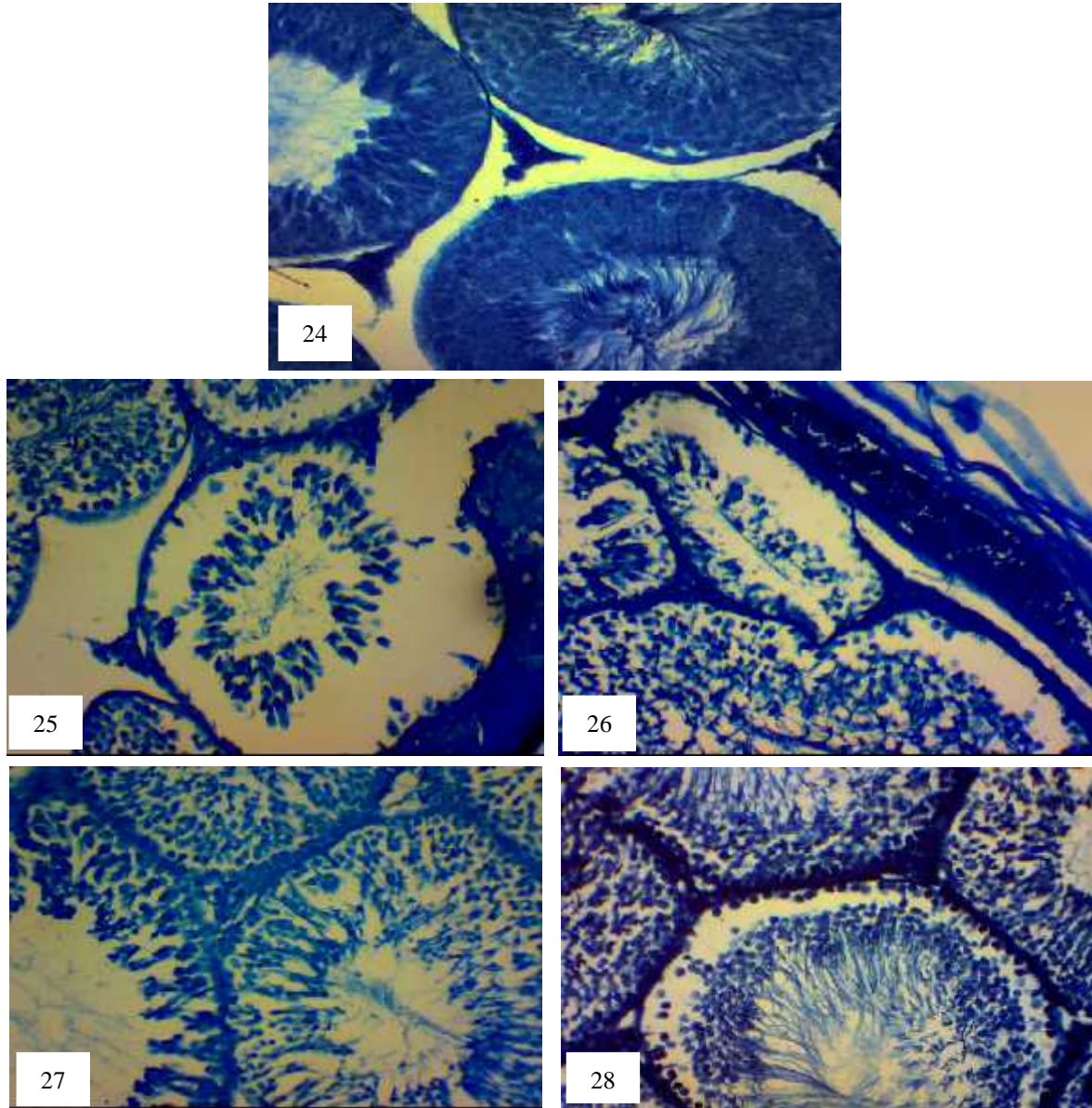
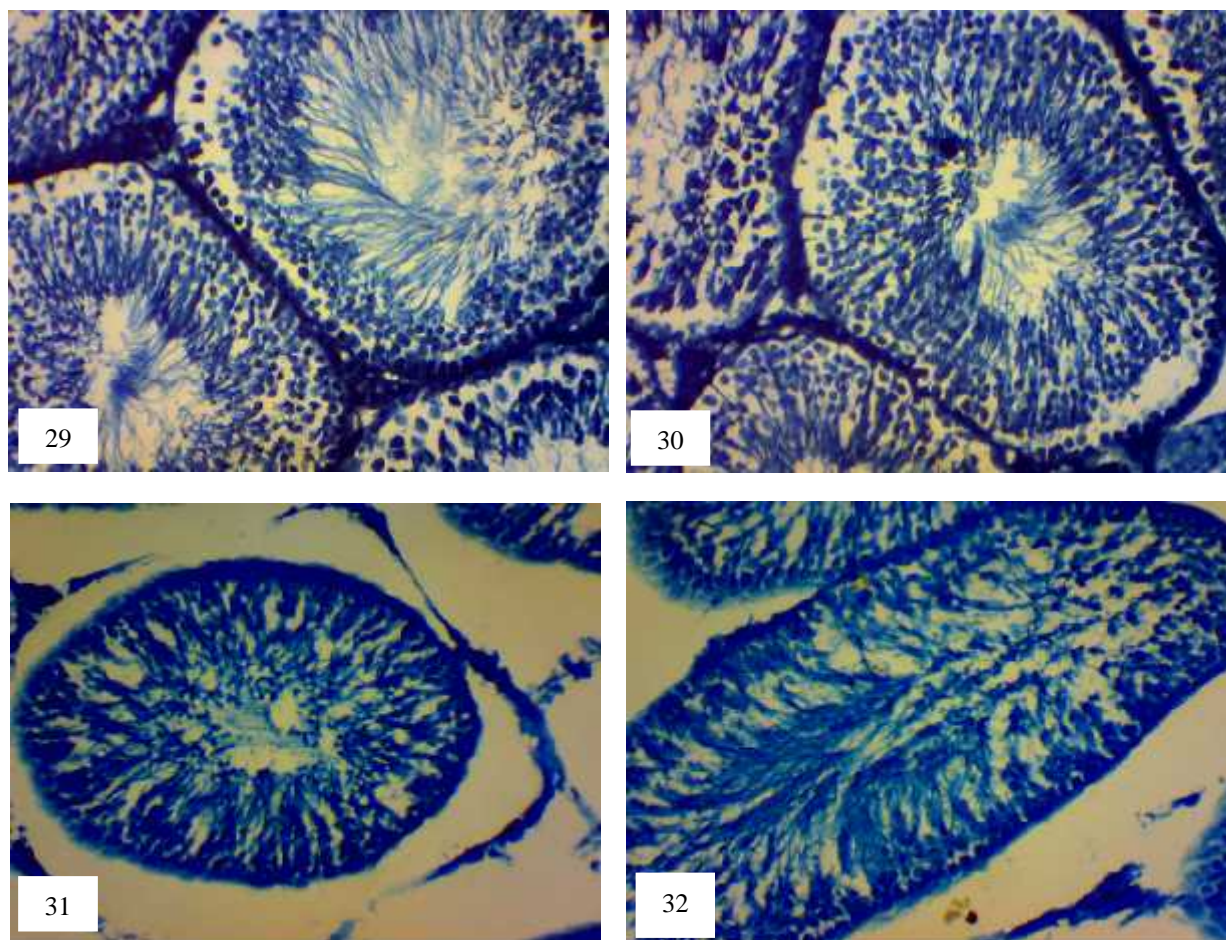


Fig. 24. Normal distribution of total protein in the testicular tissue of the control group. Figs. 25, 26. Testicular tissue of R group showing a decrease in total protein inside the seminiferous tubules with an increase in the capsule and in some interstitial spaces. Figs. 27-8. Testicular tissue of R+E₂₇, R+S₂₈ groups showing that total protein somewhat returned to its normal level in the mentioned treated groups (Mercury Bromophenol blue, X 200).



Figs. 29-32. Testicular tissue of R+S_{29, 30} and R+S+E_{31, 32} groups showing that total protein somewhat returned to its normal level in the mentioned treated groups (Mercury Bromophenol blue, X 200)

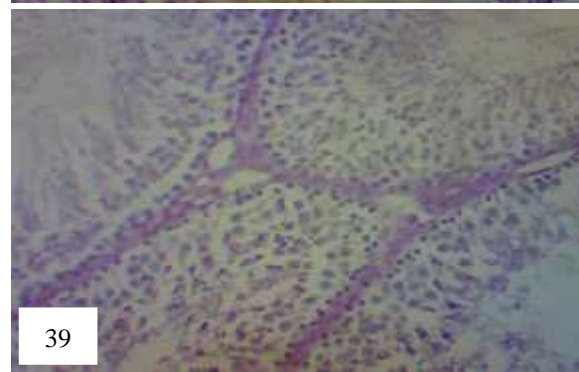
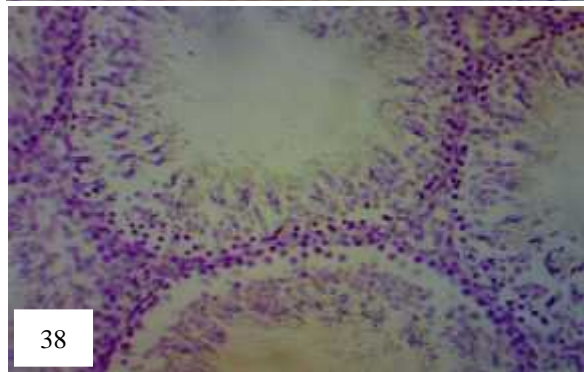
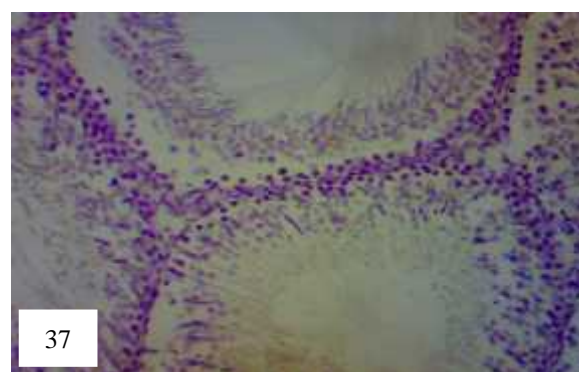
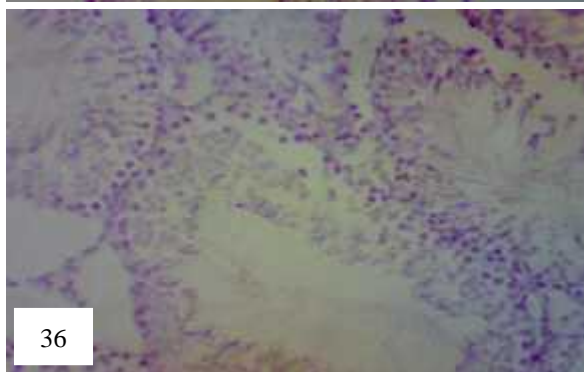
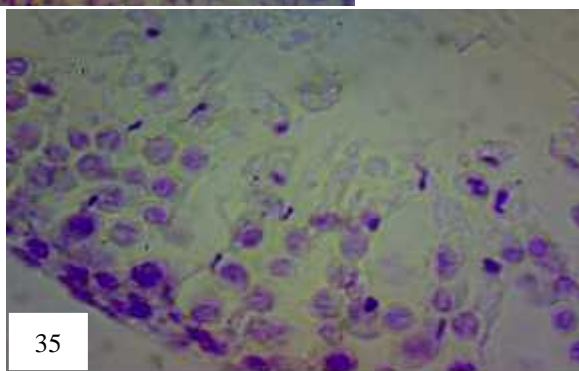
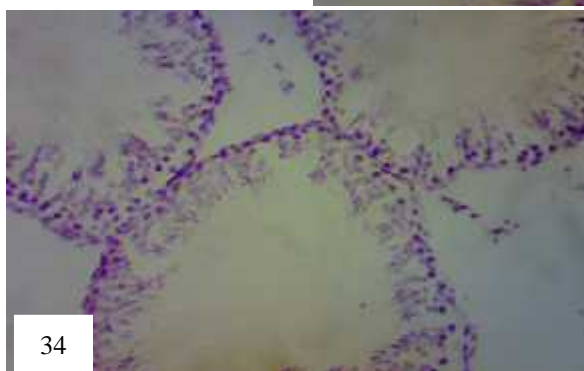
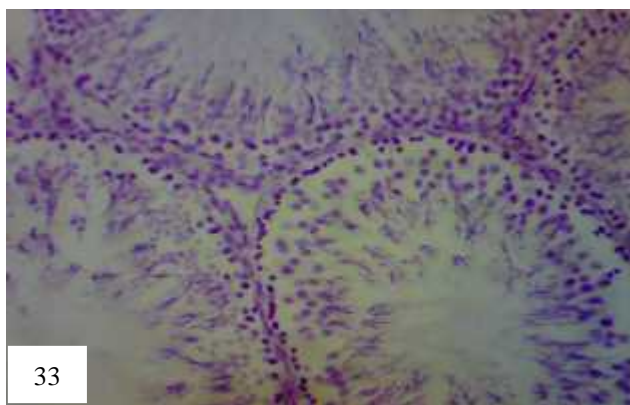


Fig. 33. Normal distribution of the DNA content in the nuclei of spermatogenic cells and Leydig cells of the control group. (X 200). Figs. 34, 35. Testicular tissue of R group showing decreased DNA content of the nuclei of spermatogenic cells and Leydig cells. (34 X 200 & 35 X 400). Fig. 36. Testicular tissue of R+E group showing a decrease of the DNA content in the nuclei of different cells of the testicular tissue. (X 200). Figs. 37-39 Testicular tissue of R+S^{37,38} and R+S+E³⁹ groups showing somewhat normal content of DNA materials in the different spermatogenic cells and Leydig cells. (X 200) (Feulgen's reaction)

reactive oxygen species and increasing antioxidant enzyme activities and prevent 950 MHz EMF-induced oxidative damage of liver and heart (Ibrahim and Gharib, 2010).

The present experiment showed an increase in collagen fibres deposition within the seminiferous tubules and Leydig cells of the irradiated rats, these results comes in line with those reported earlier by Celik et al. (2012) who declared that three months low-dose EMF exposure caused an increase in membrana propria thickness and collagen fibres contents with capillary veins extension in rat testes. More recently, Mohamed (2014) revealed that exposure of rats to 900 MHz of EMF (2h/day, 3h/week) for two months increased lung collagen fibres around walls of the bronchioles and inside the tunica intima of the blood vessels. Increased collagen deposition in the current experiment could be attributed to oxidative stress that stimulate the expression of genes involved in collagen biosynthesis (Guler et al., 2009), where increased superoxide anion formation by inhibition of superoxide dismutase (SOD) stimulates collagen production indicating a vital role of SOD and the generated reactive oxygen species in collagen accumulation (Lijnen et al., 2011). On the other hand, more or less normal distribution of collagen fibres was detected in the testicular tissues of rats treated with vitamin E and/or silymarin which may reflect the indirect anti-oxidant role of both vitamin E and silymarin.

Concerning the histochemical observations in the current work, rat testes exposed to 950 MHz of EMF radiation showed reduction of polysaccharides. A decrease in PAS +ve materials following EMFs exposure was noted earlier. Saied et al. (2010) found that electromagnetic fields from two phase square waves with 700 (MG) intensity and 1 Hz frequency was found to significantly decrease glycogen storage of rabbit liver, the authors concluded that EMFs can decrease liver glycogen stores. In addition, the decrease in carbohydrate contents in the current work may be attributed to increased stress on the organs which leading to consuming high energy in attempt to light or equalize the pressure exerted upon them (Sakr and Okdah, 2004). It may also be due to the release of hydrolytic enzymes from ruptured lysosomes under the effects of toxic agents (Farrag and Shalby, 2007).

Present results showed that male rats received vitamin E and/or silymarin showed more or less normal appearance of the PAS +ve materials, better improvement was noted in both silymarin and vitamin E administrated group, which could be attributed to both antioxidants inhibitory effect of free radicals formation (Oral et al., 2006). The current observations were confirmed with statistical analysis of optical density of PAS reaction (Table 1) where a significant decrease in PAS reaction was noted post-exposure of rats to EMF. Such decrease was also noted after vitamin E administration to rats prior to EMFs exposure. A significant increase in polysaccharides content of the testicular tissues was detected after either silymarin or both vitamin E and silymarin treatment which was more prominent in both silymarin and vitamin E treated group.

The current results also showed decreased staining affinity of the DNA as well as total protein in rat testicular tissue following EMF exposure. Such reduction was noticed before where, Aitken et al. (2005) showed that exposure of mice to 900 MHz radiofrequency electromagnetic radiation induced DNA damage to caudal epididymal spermatozoa. In the same way, Kilgallon and Simmons (2005) reported decreased semen quality with prolonged use of cell phones with negative effects on sperm motility characteristics (Fejes et al., 2005). In contrast to such findings Nikolova et al. (2005) reported no effects of radiofrequency fields on cell cycle, cell proliferation, cell differentiation, apoptosis induction, DNA synthesis and immune cell functionality.

Electromagnetic fields interfere with protein phosphorylation and modify the plasma membrane structure and interfere with the initiation of the signal cascade pathways for protein synthesis (Anan et al., 2012). The decrease in both DNA and total protein in the current work may be attributed to arrested metabolism or to use it to build up new cells or enzymes to reduce the radiation stress (Sakr and Okdah, 2004) and also disruption of lysosomal membranes under the effect of various toxicants leading to liberating their hydrolytic enzymes in the cytoplasm and resulted in marked lysis and dissolution of the target materials (Sakr and Shalaby, 2011).

The current histochemical findings showed improvement of total protein and DNA materials after vitamin E and/or silymarin administration. More obvious improvement in the DNA and protein contents of the testicular tissue was demonstrated after silymarin than after vitamin E administration. Co-administration of vitamin E with silymarin was more effective in ameliorating electromagnetic field-induced testicular damage of both DNA and total protein. Values of the mean optical density confirmed the present histochemical observations indicating the scavenging effect of silymarin or vitamin E or their co-administration on free radicals produced by testes in response to electromagnetic field toxicity.

Vitamin E supplementation played an important role in tissue formation and prevention of damage or oxidation of some tissues. It was reported earlier that the increase in the protein content may be due to the activation of the enzymes of protein synthesis (Gabry et al., 2008). In addition, vitamin E caused a significant increase of antioxidant enzymes which decreased in EMFs exposed animals (Wolf et al., 2005).

Silymarin has also been reported to have antioxidant, immunomodulatory, anti-fibrotic, anti-proliferative and antiviral properties. It also affects the synthesis of RNA and DNA. Furthermore, silymarin maintains the integrity of the cell membrane and impedes the entrance of toxic substances or xenobiotics and increases protein synthesis by stimulating RNA polymerase I activity (Vargas-Mendoza et al., 2014). Due to its phenolic nature, it is capable of donating electrons to stabilize free radicals and reactive oxygen species. Silymarin has been reported earlier to be at least ten times more potent in antioxidant activity than vitamin E (Kaur et al., 2011). Silymarin also affects intracellular glutathione, which prevents

lipoperoxidation of membranes (Karimi et al., 2011). The current improvement in DNA and protein contents after silymarin administration (either alone or in combination with vitamin E) may be attributed to its antioxidant properties by scavenging free radicals and increasing intracellular concentration of glutathione indicating its protective effect.

Co-administration of both vitamin E and silymarin to rats in the present experiment showed more ameliorating effect on the testicular tissues against EMF exposure. Such improvement may be attributed to potentiating and synergistic effect of combination supplements, implying that silymarin as a potent antioxidant intensified this beneficial effect (Roosbeh et al., 2011).

Image analysis results of the current experiment supported the histological and histochemical results where a significant decrease in both DNA and total protein contents of the testes was detected after exposure of rats to EMF. A significant increase was noted post administration of either

silymarin or co-administration of both silymarin and vitamin E. However, administration of vitamin E alone did not show a significant increase in the DNA +ve materials of the testicular nuclei.

In conclusion, the present experiment demonstrated the protective effect of silymarin and/or vitamin E against 950 MHz (EMF) induced damage in rat testes. EMR has a negative effect on the testicular structure through the induction of oxidative stress and disruption of the testicular antioxidant status. Antioxidants, such as vitamin E and silymarin ameliorated the testicular damage and confirm their importance in overcoming oxidative stress. Their protective action may be attributed to the scavenging action of both silymarin and/or vitamin E on free radicals generation. Further investigations are encouraged to explore the full potential of silymarin and/or vitamin E for the protection of testes against the electromagnetic field exposure.

5 References

- Abd El Rahman N.A., Abd El Hady A.M. and Eltahawy N.A. (2014): Silymarin and Vitamin E modulate 950MHz electromagnetic field-induced oxidative stress and hormonal changes in male albino rats. *J. Am. Sci.*, 10(9):170-176.
- Abou- Safi H.M. (2005): Role of silymarin as a protector against gamma rays hazards on ovarian function, carbohydrate and lipid metabolism during meta-estrous stage in rats. *Isotope and Radiat. Res.*, 37(5): 1234-1259.
- Achudume A., Onibere B., Aina F. and Tchokossa P. (2010): Induction of oxidative stress in male rats subchronically exposed to electromagnetic fields at non-thermal intensities. *J. Electromagnetic Analysis and Applications*, 2: 482-487.
- Aitken R.J., Bennetts L.E., Sawyer D., Wiklendt A.M. and King B.V. (2005): Impact of radio frequency electromagnetic radiation on DNA integrity in the male germline. *Int. J.Androl.*, 28(3):171-179.
- Alba M.A, Sánchez R.R., Ruíz Pérez N.J., Navarrete J.S., Paz R.F., Montoya-Estrada A. and Gómez J.J. (2008): Comparative study of the antimutagenic properties of vitamins C and E against mutation induced by norfloxacin. *B.M.C. Pharmacology*, 8(2): 1-4.
- Al-Damegh M.A.(2012): Rat testicular impairment induced by electromagnetic radiation from a conventional cellular telephone and the protective effects of the antioxidants vitamins C and E. *Clinics*, 67: 785-792.
- Anan H.H., Gawish M.F., Amer M.G. and Ibrahim N.E. (2012): Effects of low magnetic irradiation on morphology and ultrastructure of parotid glands in rats and amelioration by vitamin E. *J. Cytol. Histol.*, 3:1-3.
- Aydogan F., Atılgan H.I., Koca, G., Yumu ak, N., Aydın, E., Sadiç M., Korkmaz, M., Tuncal S. and Samim E. (2014): An evaluation of the radioprotective effect of vitamin E on the salivary glands of radioactive iodine in rats. *Turkish. J. Ear, Nose and Throat*, 24 (1): 21-29.
- Bancroft J. and Gamble A.(2008): *Theory and Practice of Histology Techniques*. 6th ed., Churchill Livingstone. New York and London: 83-92,
- Behari J. and Kesari K.K. (2006): Effects of microwave radiations on reproductive system of male rats. *Embryo Talk*, 1 (1): 81-85.
- Cao X.W., Zhao T.D., Wang C.H., Zhou Q., Li L.Q., Yao H.G., Zhang S.Q., Tang, J.T. and Wei W. (2009): Alternating magnetic field damages the reproductive function of murine testes. *Zhonghua Nan Ke Xue*, 15(6):530-533.
- Çelik S., Aridogan I.A., İzol V., Erdo an S., Polat S. and Doran S. (2012): An evaluation of the effects of long-term cell phone use on the testes via light and electron microscope analysis. *Urology*, 79(2):346-350.
- Chen H.Y., Wang S.M., Peng R.Y., Gao Y.B., Wang L.F., Zhao L., Zuo H.Y., Dong J. and Su Z.T. (2011): Long-term microwave radiation affects male reproduction in rats. *Zhonghua Nan Ke Xue*, 17(3):214-218.
- Chung M.K., Lee S.J., Kim Y.B., Park S.C., Shin D.H., Kim S.H. and Kim J.C. (2005): Evaluation of spermatogenesis and fertility in F1 male rats after in utero and neonatal exposure to extremely low frequency electromagnetic fields. *Asian J.Androl.*, 7 (2): 189-194.
- D'Angelo C. , Costantini E. , Kamal M.A. and Reale M. (2015): Experimental model for ELF-EMF exposure: Concern for human health. *Saudi Journal of Biological Sciences*, 22: 75–84.
- Dasdag S., Zulkuf A.M. and Aksen F. (2003): Whole body exposure of rats to microwaves emitted from a cell phone does not affect the testes. *Bioelectromagnetics*, (24): 182-188.
- Drury, R. and Wallington, E. (1980): *Carleton's Histological Technique*. 4th ed., Oxford. Univ. Press, New York.
- Erogul O., Oztas E., Yildirim I., Kir T., Aydur E., Komesli G., Irkilata HC., Irmak MK. and Peker A.F. (2006): Effects of electromagnetic radiation from a cellular

- phone on human sperm motility: an in vitro study. *Arch. Med. Res.*, 37(7):840-843.
- Erpek S., Bilgin M. D., Dikicioglu E. and Karul A. (2007): The effects of low frequency electric field in rat testis. *Revue Méd. Vét.*, 158 (4): 206-212.
- Farrag A.H. and Shalby S.E.M. (2007): Comparative histopathological and histochemical studies on IGR, lufenuron and profenofos insecticide albino rats. *J. Appl. Sci. Res.*, 3(5): 377-386.
- Fejes I., Zavacki Z., Szollosi J., Koloszar Daru J., Kovacs L. and Pal A. (2005): Is there a relationship between cell phone use and semen quality? *Arch. Androl.*, 5, 385-393.
- Gabry M.S., Ebrahim M.A., Hassan B.N. and Abd El-All H.F. (2008): Ultrastructural and histological studies on the ameliorative effects of some antioxidants on liver tissue of aged mice. *Egypt J. Histol.*, 31 (2):384 – 395.
- Guler G., Türközer Z., Ozgur E., Tomruk, A. and Seyhan N. (2009): Protein oxidation under extremely low frequency electric field in guinea pigs. Effect of N-acetyl-L-cysteine treatment. *Gen. Physiol. Biophys.*, 28: 47-55.
- Hales D.B., Allen J.A., Shankara T., Janus P., Buck S. and Diemer T. (2005): Mitochondrial function in Leydig cell steroidogenesis. *Ann. NY Acad. Sci.*, 1061: 120-134.
- Horiuchi S., Ishizaki Y., Okuno K., Ano T. and Shoda M. (2002): Change in broth culture is associated with significant suppression of *E. coli* death under high magnetic field. *Bioelectrochemistry*, 57: 139–144.
- Ibrahim N.K. and Gharib O.A. (2010): The Protective effect of antioxidants on oxidative stress in rats exposed to the 950 MHz electromagnetic field. *J. Rad. Res. Appl. Sci.*, Vol. 3, No.4(A):1143 -1155
- Jaarin K., Gapor M.T., Nafeeza M.I. and Fauzee A.M. (2002): Effect of various doses of palm vitamin E and tocopherol on aspirin-induced gastric lesions in rats. *Int. J. Exp. Pathol.*, 83: 295-301.
- Jacobs B. C., Dennehy G., Ramirez J., Sapp J. and Lawrence V.A. (2002): Milk thistle for the treatment of liver diseases: a systematic review and meta analysis. *Am. J. Med.*, 113: 506-515.
- Jajte J., Grzegorzczak J., Zmyslony M. and Rajkowska E. (2002): Effect of 7 mT static magnetic field and iron ions on rat lymphocytes: apoptosis, necrosis and free radical processes. *Bioelectrochemistry*, 57:107-111.
- Karimi G., Vahabzadeh M., Lari P., Rashedinia M. and Moshiri M. (2011): "Silymarin", a promising pharmacological agent for treatment of diseases. *Iran J. Basic Med. Sci.*, 14: 308-317
- Kaur A.K., Wahi A.K., kumar B., Anil Bhandari A. and Prasad N. (2011): Milk thistle (*Silybum marianum*): A review. *Int. J. Pharma. Res. and Develop.* – Online: 1-10.
- Kesari K.K. and Behari J. (2008): Comparative study of 900MHz and 2.45 GHz radiation effect on reproductive system of male rats. In: *Recent Advances and Challenges in Reproductive Health Research*. (RS Sharma, ARajanna, M Rajalakshmi. Proceedings of the conference on "Recent Advances and Challenges in Reproductive Health Research (Feb 19-21, 2007 New Delhi) ICMR Publication.
- Kesari K.K., Kumar S. and Behari J. (2010): Mobile phone usage and male infertility in Wistar rats. *Indian J. Exp. Biol.*, 48:987–992.
- Khalil A., Al-Adhammi M., Al-Shara B., Gagga M., Rawshdeh A. and Al-Shamli A. (2012): Histological and ultra-structural analyses of male mice exposed to mobile phone radiation. *J. Toxicol. Rev.*, 1: 1-6.
- Kiernan J. A. (1981): *Histological and Histochemical Methods, Theory and Practice*. Pergamon Press. New York, USA.
- Kilgallon S.J. and Simmons L.W. (2005): Image content influences men's semen quality. *Biol. Lett.*, 1, 385-393.
- Knave B. (2001): "Electromagnetic fields and health outcomes". *An Acad. of Med.*, 30 (5): 489-493.
- Kong Q. and Lin C.L.G. (2010): "Oxidative damage to RNA: mechanisms, consequences, and diseases," *Cellular and Molecular Life Sciences*, 67(11): 1817–1829.
- Kovacic P. and Somanathan R. (2010): "Electromagnetic fields: mechanism, cell signaling, other bioprocesses, toxicity, radicals, antioxidants and beneficial effects," *Journal of Receptors and Signal Transduction*, 30(4): 214–226.
- Kumar S., Kesari K.K. and Behari J. (2010): Evaluation of genotoxic effect in male wistar rats following microwave exposure. *Ind J. Exp. Biol.*, 48: 586-592.
- La vignera S., Condorelli R.A., Vicari E., D'agata R. and Calogero A.E. (2012): Effects of the exposure to mobile phones on male reproduction: A review of the literature. *J. Andrology*, 33(3):350-356.
- Lijnen P.J., Prihadi J.S., Van Pelt J.F. and Fagard R.H. (2011): Modulation of reactive oxygen species and collagen synthesis by angiotensin II in cardiac fibroblasts. *The Open Hypertension Journal*, 4: 1-17.
- Lukac N., Massanyi P., Roychoudhury S., Capcarova M., Tvrda E., Knazicka Z., Kolesarova A. and Danko J. (2011): In vitro effects of radiofrequency electromagnetic waves on bovine spermatozoa motility. *J. Environ. Sci. Health A Tox Hazard Subst. Environ. Eng.* 46(12): 1417-1423.
- Meo S.A., Arif M., Rashied S., Khan M.M., Vohra M.S., Usmani A.M., Imran M.B. and Al-Drees A.M. (2011): Hypospermatogenesis and spermatozoa maturation arrest in rats induced by mobile phone radiation. *J. Coll. Physicians Surg. Pak.*, 21:262–265.
- Mohamed A.K. (2014): The possible rescue effect of vitamin E or silymarin on lung tissues of male albino rats exposed to electro-magnetic field. *Egypt. J. Hosp. Med.*, 57: 470-481.
- Nassar S.A. (2009): Do microwaves of mobile phone affect the testicular tissue structure? (a histopathological and ultrastructural study). *Egypt. J. Hosp. Med.*, 37: 685-699.
- Nikolova T., Czyz J., Rolletschek A., Blyszczuk P., Fuchs J., Jovtchev G., Schuderer J., Kuster N. and Wobus A.M. (2005): Electromagnetic fields affect transcript levels of apoptosis-related genes in embryonic stem cell-derived neural progenitor cells. *FASEB J.*, 19: 1686-1688.
- Oral B., Guney M., Ozguner F., Karahan N., Mungan T., Comlekci S. and Cesur G. (2006): Endometrial

apoptosis induced by a 900-MHz mobile phone: preventive effects of vitamins E and C. *Adv. Ther.*, 23 (6):957-973.

Pearse, A. G. E. (1972): *Histochemistry, Theoretical and Applied*, 3rd ed., Vol. 2. Churchill Livingstone. London.

Pradhan S. C. and Girish C. (2006): "Hepatoprotective herbal drug, silymarin from experimental pharmacology to clinical medicine," *Ind. J. Med. Res.*, 124: 491–504.

Ribeiro E.P., Rhoden E.L., Horn M.M., Rhoden C., Lima L.P and Toniolo L. (2007): Effects of subchronic exposure to radio frequency from a conventional cellular telephone on testicular function in adult rats. *J. Urol.*, 177:395–399.

Roosbeh J., Shahriyari B., Akmal M., Vessal G., Pakfetrat M., RaeesJalali G.A., Afshariani R., Hasheminasab M. and Ghahramani N. (2011): Comparative effects of silymarin and vitamin E supplementation on oxidative stress markers, and

Shaarawy S. M., Tohamy A. A., Elgendy S. M.AbdElmageed Z.Y., Bahnasy A., Mohamed M.S., Kandil E. and Matrougui K. (2009): "Protective effects of garlic and silymarin on NDEA-induced rats hepatotoxicity," *Int. J. Biol. Sc.*, 5: 549–557.

Simkó M. (2007): "Cell type specific redox status is responsible for diverse electromagnetic field hemoglobin levels among patients on hemodialysis. *Ren. Fail.*, 33(2): 118–123.

Saeid N., Yusof B., Ahim H., Shamsadin A.S., Fateme H., Fatere Y. and Leili M. (2010): Influence of

electromagnetic fields of two phases square wave with low frequency on serum ALAT and ASAT levels and histochemistry of hepatocytes glycogen. *Global Veterinaria*, 5 (4): 204-208

Sakr, S.A. and Okdah, Y.A. (2004): Histological and histochemical alteration induced in the testicular tissue of mice intoxicated with benomyle. *J. Biol. Sci.*, 4(4): 498-500.

Sakr S.A. and Shalaby S. Y. (2011): Ginger extract protects metalaxyl-induced histomorphological and histochemical alterations in testes of albino mice. *J. Appl. Pharm. Sci.*, 1(10): 36-42.

Salter R., Meier R. and Brignoli R. (2001): "The use of silymarin in the treatment of liver diseases," *Drugs*, 61:2035–2063.

Uttara B., Singh A.V., Zamboni P. and Mahajan R.T. (2009): Oxidative stress and neurodegenerative diseases: A review of upstream and downstream antioxidant therapeutic options. *Curr. Neuropharmacol.*, 7(1): 65–74.

Vargas-Mendoza N., Madrigal-Santillán E., Morales-González A., Esquivel-Soto J., Esquivel-Chirino C., García-Luna M., González-Rubio Y, Gayosso-de-Lucio J. and Morales-González J. (2014): Hepatoprotective effect of silymarin. *World J. Hepatol.*, 27; 6(3): 144–149.

Wolf F.I., Torsello A., Tedesco B., Fasanella S., Boninsegna A., D'Ascenzob M., Grassib C., Azzenab G.B. and Cittadinia A. (2005): 50-Hz extremely low frequency electromagnetic fields enhance cell proliferation and DNA damage: possible involvement of a redox mechanism. *Biochim. Biophys. Acta*, 1743: 120-129