

## COMPARATIVE STUDY BETWEEN CONSERVATIVE BREAST SURGERY AND SKIN SPARING MASTECTOMY IN PATIENTS WITH MULTIFOCAL BREAST CANCER

*Osama Ali El Atrash<sup>1</sup>, Rania El Ahmady Elshekh<sup>1</sup>, Ahmed Gamal Osman<sup>1</sup>, Amr Ahmed Hassan<sup>2</sup>*

### ABSTRACT:

1Department General Surgery,  
Faculty of Medicine, Ain Shams  
University , Cairo , Egypt

#### Corresponding:

Amr Ahmed Hassan Mohamed  
Hassan.

Mobile : 01066882835

#### Email:

Amrhassen395@gmail.com

Received: 16/2/2020

Accepted: 8/3/2020

Online ISSN: 2735-3540

**Background:** Breast cancer is by far the most common cancer among women of both developed and developing countries and the leading cause of cancer death in females. The incidence of multifocal breast cancer has increased due to the improvement in imaging studies and the use of MRI. Multifocal breast cancer was previously considered a contraindication for breast conservative surgery. However, with the recent progress in the neoadjuvant systemic therapy Together with development of oncoplastic surgeries breast conservation is being increasingly performed for multifocal cases. Skin sparing mastectomy can also be used for multifocal cases with superior aesthetic results without compromising the oncological safety.

**Aim of the work:** This study aims to compare conservative breast surgery and skin sparing mastectomy in multifocal breast cancer regarding local recurrence.

**Patients and methods:** This is a prospective randomized clinical trial study conducted in Ain-Shams University Hospitals Breast surgery unit over 30 patients with minimal follow-up of 18 months. 2 groups of patients; **Group A:** composed of 15 patients that undergoing conservative breast surgery for multifocal breast cancer. **Group B:** composed of 15 patients that undergoing skin sparing mastectomy for multifocal breast cancer. An informed consent will be taken from all patients who will accept to participate.

**Results:** The percentage of local recurrence were found to be comparable in both groups. Also the aesthetic results and patients' satisfaction were similar in both groups. However, postoperative wound complications were higher in the skin sparing mastectomy group.

**Conclusion:** This study suggests that any of the two procedures can safely be done to cases with multifocal breast cancer however the cosmetic results in skin sparing mastectomy group was more superior than in the conservative breast surgery group.

**Key words:** Multifocal breast cancer, Skin sparing mastectomy, conservative breast surgery

### INTRODUCTION

Breast cancer is by far the most common cancer among women of both developed and developing countries,

accounting for 22.9% of all female cancers. It is also the leading cause of cancer death in females accounting for 13.7% of their cancer related mortality<sup>(1)</sup>.

Multifocal breast cancer defined as presence of two or more tumor foci in *one* breast quadrant while multicentricity defined as two or more tumor foci within different quadrants of the breast or in the same quadrant but at least 5 cm apart<sup>(2)</sup>.

With the advent of magnetic resonance imaging as a screening modality and preoperative procedure, the diagnosis of multifocal disease is often made preoperatively. A recent meta-analysis based on 19 studies ( $n = 2610$ ) demonstrated that MRI detected additional 16% breast cancer foci not identified by traditional exams<sup>(3)</sup>.

It has been demonstrated that multifocality really has *no bearing on the overall survival rate* for breast cancer. The same prognostic indicators that apply to other unifocal breast cancers remain the same for multifocal breast tumors<sup>(4)</sup>.

Previously, multifocal breast cancer was considered contraindication for conservative breast surgery which may compromise local control. However, recently according to available evidence, breast conserving treatment appears to be safe for small, early stage multifocal tumors without an extensive ductal or lobular in situ component<sup>(5)</sup>.

Another option of treatment is Skin-sparing mastectomy for multifocal lesions which preserves most of the overlying skin during an immediate breast reconstruction (IBR) thus leading to a superior aesthetic outcome. It also reduces the need for contralateral breast adjustment in order to achieve symmetry<sup>(6)</sup>.

However, skin sparing mastectomy increases the potential to leave residual breast tissue as achieving the ideal mastectomy flap that is thin enough to remove all breast tissue but thick enough to keep subdermal vessels and support an adequate blood supply is difficult so higher rates of locoregional recurrence after skin sparing mastectomy were initially reported

for invasive cancer but were not confirmed in a subsequent meta-analysis of locoregional recurrence<sup>(7)</sup>.

---

## PATIENTS AND METHODS:

This is a prospective randomized clinical trial study conducted in Ain-Shams University Hospitals Breast surgery unit over 30 patients with minimal follow-up of 18 months. The inclusion period was from May 2017 through January 2020

2 groups of patients; **Group A:** composed of 15 patients that undergoing conservative breast surgery for multifocal breast cancer. **Group B:** composed of 15 patients that undergoing skin sparing mastectomy for multifocal breast cancer

An informed consent will be taken from all patients who will accept to participate.

**Inclusion criteria:** Are fit for surgery. Adult female patients, age (18-60 years). Patients who have multifocal breast cancer.

**Exclusion criteria:** Patients with metastatic or locally advanced breast cancer. Previous chest wall irradiation. Breast skin involvement. Patient refusal. Recurrent breast cancer. Pregnant patients.

**All patients will be subjected to the following:**

Preoperative assessment: Full clinical history; personal history, present history, past history family history or history of the disease in the contralateral side. Full clinical examination; vital signs, body examination, complete breast and axilla examination. Routine preoperative investigations including, complete blood count, random blood sugar, liver function test, kidney function test, coagulation profile. Bilateral sonomammography, trucut Biopsy, chest x-ray and pelviabdominal ultrasonography. MRI was used in cases with lobular carcinoma and when mammography was inconclusive. Preoperative co-morbid factors such as

hypertension, Diabetes mellitus or electrolyte disturbance will be controlled when possible before surgery.

Diagnosis of multiple invasive breast cancer was performed either clinically by palpation, radiologically or at pathological examination. Multifocality was defined as the presence of different tumours within the same quadrant.

Postoperative pathological assessments included the number, location and size of the tumours removed, the total number of removed and positive lymph nodes.

**Data collection:**

Data will be collected from patient records, medical files, and interviews.

All patients were enrolled under the strict guidelines of ethical committee of Ain Shams University hospitals and gave informed consent.

**Outcome measures:**

The results of the two surgeries (skin sparing mastectomy versus conservative breast surgery) will be compared regarding: Complete excision (negative safety margins). Local recurrence. Post operative complications. Cosmetic results.

All patients were followed for a period of 2 year divided into early follow-up after for post operative wound complications then 6 and 12, 24 months for detection of recurrence and assessment of aesthetic outcome and patient satisfaction

Follow-up included: Clinical examination of breast and axilla, follow up sonomamogram for detection of any suspicious lesion and core biopsy from any suspicious lesion.

Cosmetic outcome was estimated using a scoring system which was made up from the three independent grading parties (Surgeon, Patient and MDT of the breast) based on the level of satisfaction to give an overall score for cosmetic outcome.

The cosmetic outcome score was based on multiple items that made up a check list to be evaluated by our team and the MDT of the breast for every single case, this check list:

The overall shape of the breast, The site and direction of the nipple, The volume of the breast and The skin incision shape

These elements were discussed for every single case and analyzed to give a scoring system graded from 1 to 4 as the following:

- 4 = Excellent 3 = Good
- 2 = Fair 1 = Poor

---

**RESULTS AND DATA ANALYSIS:**

**The results of the prospective study included the following:**

**Age:**

The age of the patients varied from 33 to 60 years old. The mean age for our study was 47.7. (Table 1).

Table (1): Mean age of the study.

	Mean	±SD	Minimum	Maximum
Age(years)	47.70	10	33	60

In group (I) (CBS) the age of the patients ranges from 30 - 58years with a mean age of 45.4. In group (II) (SSM) the age of the patients ranges from 35- 60years

with a mean age of 43.07 (Table 2; Figure 1).

There is no significant statistical difference between the two groups as regards their age.

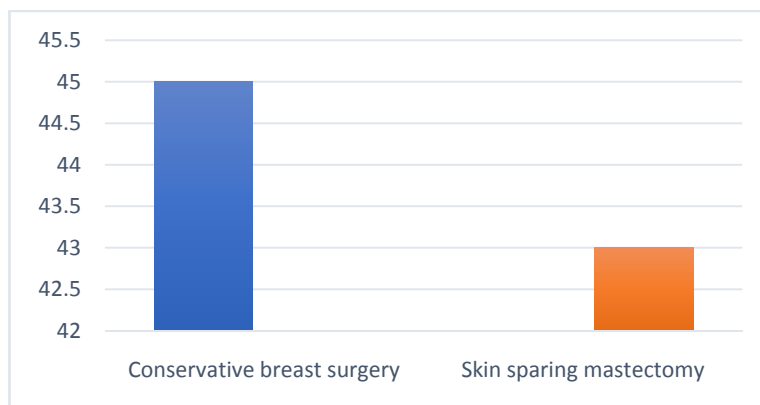


Fig (1): Age distribution in the 2 groups.

Table (2): Age difference between the two groups

Age	Groups		t-test
	Conservative Breast Surgery	Skin sparing mastectomy	P- value
Range	30 – 85	35 – 60	0.155
Mean ± SD	45.40 ± 8.42	43.07 ± 7.81	

**Size of the tumor:**

The tumor size was evaluated by breast ultrasound according to the last TNM edition (7<sup>th</sup>) by measuring the diameter of only the largest focus.

In group (I) (Conservative breast surgery) the size of the tumor ranges from

9–26 mm with mean size 17.5mm. In group (II) (Skin sparing mastectomy) the tumor size ranges from 8-33 mm with mean size 20.1mm. (Table 3; Figure 2).

There is no significant statistical difference between the two groups as regards the tumor size.

Table (3): Tumor size in the two groups.

Tumor size (mm)	Groups		t-test
	Donut Mastopexy	Inferior Pedicle Mammoplasty	P- value
Range	9 – 26	8 – 32	0.710
Mean ± SD	17.5 ± 5.23	20.1 ± 6.09	

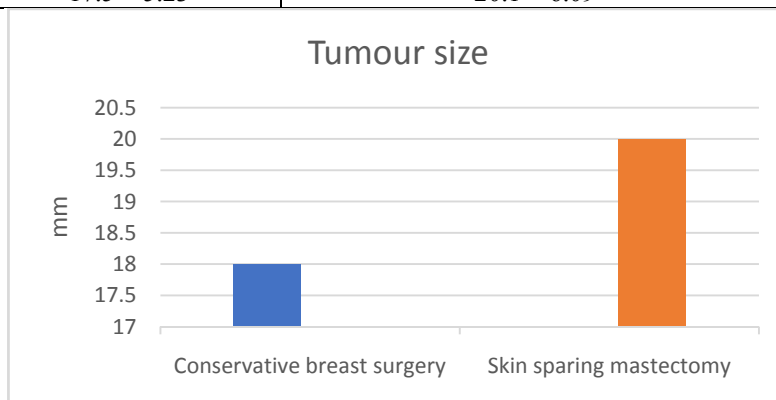


Fig (2): Tumour size between 2 groups..

**Intraoperative finding:**

from 4 – 5.5 hours with the mean time 4.65 hours.

**1. Operative Time:**

The operative time in group (I) (Conservative breast surgery) ranges from 1.5 – 2 hours with the mean time 1.2 hours. In group (II) (Skin sparing mastectomy)

There is significant statistical difference between both groups as regards the operative time, being longer in group (II) (Skin sparing mastectomy) than group (I) (conservative breast surgery).

Table (4): Difference in the operative time in the two groups.

Operative time (hrs)	Groups		t-test
	Conservative breast surgery	Skin sparing mastectomy	P- value
Range	1.5 – 2	4 – 5.5	<0.001
Mean ± SD	1.2 ± 0.32	4.65 ± 0.60	

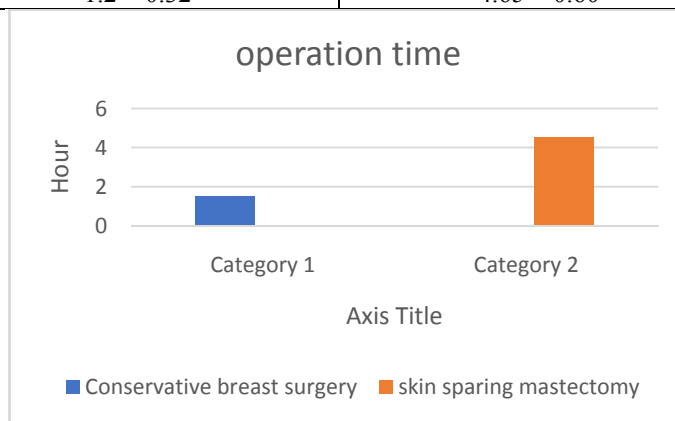


Fig (3): Post-Operative findings:

**1. Drainage Volume:**

In group (I) (conservative breast surgery) the total postoperative drainage volume ranges from 50 to 150 ml with the mean 93 ml, while in group (II) (skin sparing mastectomy) it ranges from 100 to 300 ml with the mean 226 ml.

There is significant statistical difference as regards the postoperative drainage volume between the two groups being more in group (II) (skin sparing mastectomy) than in group (I) (conservative breast surgery).

Table (5): Total drainage volume in the two groups.

Postoperative drainage volume(ml)	Groups		t-test
	conservative breast surgery	skin sparing mastectomy	P- value
Range	50 – 150	200 – 350	<0.001
Mean ± SD	93.66 ± 35.93	236.76 ± 54.52	

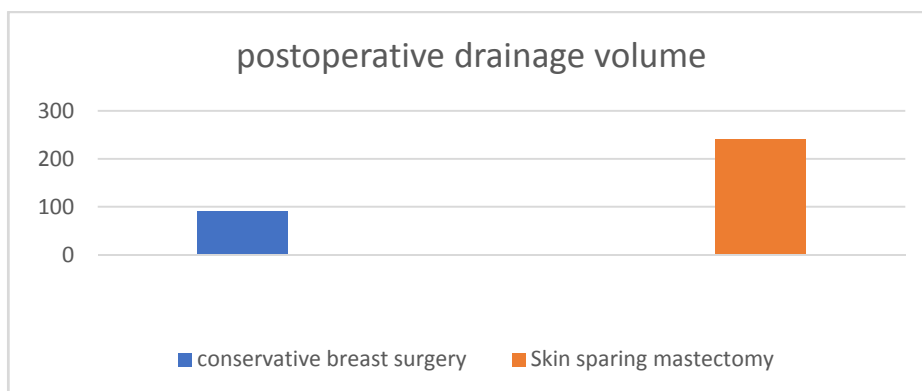


Fig (4): Post operative drainage volume.

**Hospital stay:**

As regards the hospital stay in group (I) (conservative breast surgery), patient stayed from 1 to 2 days postoperatively and from 1 to 3 days in group (II) (skin sparing mastectomy).

There is significant statistical difference between both groups as regards the postoperative hospital stay, being longer in group (II) (skin sparing mastectomy) than in group (I) (conservative breast surgery)

Table (6): Hospital stay in the two groups.

Postoperative hospital stay (days)	Groups		t-test
	conservative breast surgery	Skin sparing mastectomy	P- value
Range	1 – 2	2– 4	<0.001
Mean ± SD	1.60 ± 0.48	2.71 ± 0.70	

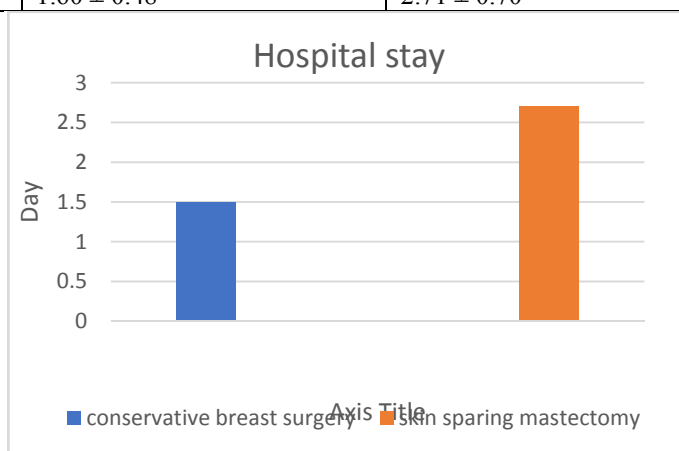


Fig (5): Hospital stay.

**Postoperative seroma:**

During the follow up period, post-operative seroma (breast or axilla) occurred only in 6 cases out of 30 with an incidence of 16.6 %, 2 cases of skin sparing mastectomy versus 4 cases of conservative breast surgery. All of them were discovered during the first week postoperative and managed conservatively. Patients were prescribed anti-edema measures together

with repeated aspiration under sterile circumstances. Seroma resolved after 3 weeks. (Table 7)

**Flap integrity:**

Viability of flap was monitored in all 30 patients in postoperative day 1 and then during the regular follow up clinical assessment.

Assessment of skin viability was monitored by any color changes appearance of necrotic patches,

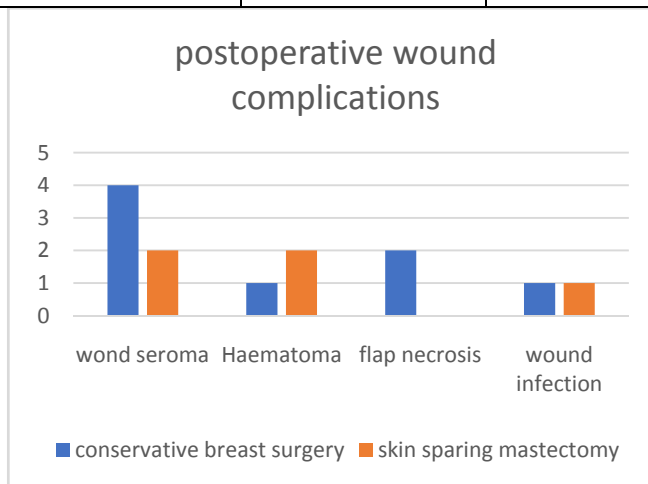
Only 2 cases of skin sparing mastectomy developed flap necrosis with an incidence of 6.6%. and was managed by debridement. No cases were recorded from the patients who underwent conservative breast surgery intervention. (Table 7)

**Wound infection:**

Among the 30 patients included, only 2 patients developed wound infection with an incidence of 6.6 %, (one in each group) They were treated by broad spectrum antibiotics and daily dressing, followed by closure with secondary sutures after 1 month. (Table 7)

Table (7): Short term postoperative complications results.

Short term complications	Number of patients with complications (out of 30 patients)	Number of skin sparing mastectomy patients	Number of Conservative breast surgery patients	P value
Seroma	6	4	2	0.06
Haematoma	3	2	1	0.79
Flap necrosis	1	2	0	0.09
Wound infection	2	1	1	0.89



**Loco-regional recurrence**

All patients had been followed after intervention regularly by the surgery and oncology team. First time after 3 months of radiotherapy, via clinical assessment and bilateral sonomammography, then by clinical assessment at an interval of 3 to 6 months and bilateral sonomammography every 6 months.

Only 2 cases in our study developed local recurrence with an incidence of 6.6 %.

The recurrence in 1 case of skin sparing mastectomy with LD flap was after 14 months of the operation, while the other case was recorded in a patient who underwent conservative breast surgery after 15months of surgery. The 2 cases were treated by No other cases in the study had local recurrence. So There is no statistical difference between the two groups as regards the local recurrence. (Table 8)

Table (8): Loco-regional recurrence results.

	Number of patients with loco-regional recurrence (out of 30 patients)	Number of skin sparing mastectomy patients	Number of Conservative breast surgery patients	P value
Loco-regional recurrence	2	1	1	0.87

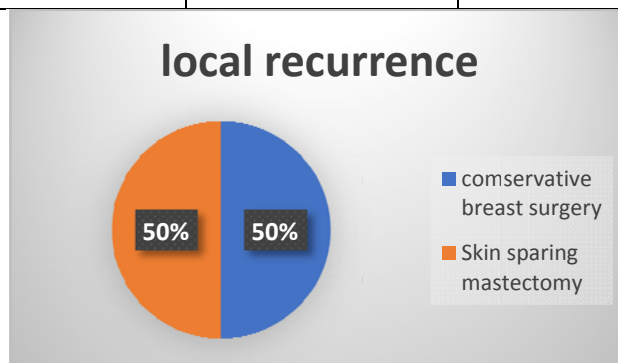


Fig (6): Local recurrence

**Cosmetic outcome:**

Cosmetic outcome was estimated using a scoring system which was made up from the three independent grading parties (Surgeon, Patient and MDT of the breast) based on the level of satisfaction to give an overall score for cosmetic outcome.

The cosmetic outcome score was based on multiple items that made up a check list to be evaluated by our team and the MDT of the breast for every single case, this check list:

The overall shape of the breast, The site and direction of the nipple, The volume of the breast and The skin incision shape

These elements were discussed for every single case and analyzed to give a

scoring system graded from 1 to 4 as the following:

- 4 = Excellent
- 3 = Good
- 2 = Fair
- 1 = Poor

In group (I)(conservative breast surgery) the number of cases given "Excellent" score was one, the number of cases given "Good" score was three. In group (II) (skin sparing mastectomy) the number of cases given "Excellent" score was eight, the number of cases given "Good" score was four. Two cases was given "Fair" score and one was "Poor".

There is a significant difference in cosmetic results between the 2 groups with more superior aesthetic results in group 2(skin sparing mastectomy)

Table (9): Cosmetic outcome.

Cosmetic outcome	Conservative breast surgery	Skin sparing mastectomy	P-value
Excellent	1 (6.6%)	8 (53%)	<0.001
Good	3 (20%)	4 (26%)	
Fair	7 (46.6%)	2 (13%)	
Poor	4 (26%)	1 (6.6%)	



## **DISCUSSION:**

Breast cancer is the most frequent carcinoma in females, diagnosed in 1.4 million women in the US every year and has been the most common cause for cancer mortality in women. Even with new progress in screening, diagnostics and surgery extra, there are still a lot left to be desired<sup>(8)</sup>.

Landmark trials have established that breast conservation therapy and mastectomy offer equivalent survival and can be viewed as equivalent treatments in early stage breast cancer<sup>(9)</sup>

Multifocal breast cancer defined as presence of two or more tumor foci in *one* breast quadrant while multicentricity defined as two or more tumor foci within different quadrants of the breast or in the same quadrant but at least 5 cm apart.<sup>(2)</sup>

Approximately 10% to 30% of patients submitted to breast conservation surgery are not satisfied with the aesthetic outcome. The main reasons are related to the tumor resection which can produce retraction and volume changes in the breast. In addition, radiation can also have a negative effect on the native breast. The main clinical aspects are related to skin pigmentation changes, telangiectasia, and skin fibrosis<sup>(10)</sup>.

Surgical techniques involving breast cancer have recently evolved in three important areas: patient recovery, oncological safety and optimal cosmetic outcome<sup>(11)</sup>.

In our study, we divided the study sample into two groups and we compared between conservative breast cancer (Group I) and skin sparing mastectomy (Group II) in treatment of early multifocal breast cancer.

In our study, there was no significant statistical difference between the two groups as regards the patients' age, with the mean age of 47.4 years (30-62 years) and 43.07 years (30-64 years) in group (I)

(conservative breast surgery) and group (II) (skin sparing mastectomy) respectively.

This was relatively lower than the mean age of the patients who participated in the study carried out by Mansell et al., 2017<sup>(12)</sup> which was 53 years. Moreover, the mean age was higher in some studies such as that carried out by Tenofsky et al., 2014<sup>(13)</sup> which was 60.9 years. The mean age of the patients was 53.3 years in the mastopexy group in the study carried out by Gennaro et al., 2011..<sup>(14)</sup>

Relatively younger age of the included patients increased the cosmetic and aesthetic demands. This made patient satisfaction a more challenging goal.

In our study there was positive first degree family history in 20% of the patients in group (I) (conservative breast surgery) and positive second degree family history in 10% of the patients in group (II) (Skin sparing mastectomy). Unfortunately BRCA gene test, which is related to significantly positive family history, was not available in our hospitals during this study.

There was significant statistical difference in both group as regards the operative time, intraoperative blood loss, hospital stay, postoperative drainage volume and days, postoperative complications and cosmetic outcome as regards patient and surgeon satisfaction. These are comparable to some studies as follow:

As regards the operative time and the intraoperative blood loss, in our study, the operative time was longer and blood loss was more in group (II) (skin sparing mastectomy) than group (I) (conservative breast surgery) with mean: 4.65 hours, and 100-350 ml (average 203.33 ml) in group (II) versus mean: 1.2 hours, and 50 -100 ml (average 75ml) in group (I).

Lambert and mokbel, 2014<sup>(15)</sup> in study of 18 patients reported mean operative time

was 3 hours (range 188-191minutes) in the skin sparing mastectomy group.

Wang et al., 2019<sup>(16)</sup> in study of 82 patients reported average operative time in the skin sparing mastectomy group was 2.5 hours (range 80-190 minutes)

The operation time depends partially on the skills of the operating seorgen and tend to be lower in specialized high volume centers.

In our study, we found that hospital stay mean 1.6 days (range 1-2 days) in group (I) (conservative breast surgery) versus 2.7days (2-4 days) in group (II) (skin sparing mastectomy).

Regarding the postoperative complications, Wang et al., 2019<sup>(16)</sup> in a total of 82 patients that underwent skin sparing mastectomy the overall rate of complications was 12.2% (10/82). Four patients developed wound dehiscence, one patient developed flap necrosis, three patients developed seroma and two patients developed wound site infection.

Razai, 2015<sup>(17)</sup> in a total of 118 patients that underwent conservative breast surgery, 27 patients had seroma(22.8%) and only 4 patients had wound infection(3.3%).

In our study patients have experienced some complication. In group (I) (conservative breast surgery), four patient formed seroma and another one had hematoma. In group (II) (skin sparing mastectomy), two patients developed seroma, one had wound infection, two had flap necrosis.

In our study we reported cosmetic outcome according to subjective patient satisfaction and subjective surgeon satisfaction to the final breast shape and it was 80% excellent and 20% good in group (I) (Donut mastopexy). While in group (II) (Inferior pedicle mammoplasty) it was excellent in 20%, good in 30%, fair in 30% and poor in 20%. The 50% in group (II) (Inferior pedicle mammoplasty) that

underwent contralateral breast surgery for symmetrization are those who were given excellent and good cosmetic result.

Ueda et al., 2013<sup>(18)</sup>, in a total of 40 patients that underwent skin sparing mastectomy technique, the cosmetic outcome was excellent in 65%, good in 25%, fair in 7.5% and poor in 2.5%.

Dewar et al., 2013<sup>(19)</sup>, in a total of 50 patients that underwent conservative breast surgery, the cosmetic outcome was 64% excellent, 30 % showed good results and 6% rated the outcome as fair.

The lower cosmetic results in our study in breast conservative surgery group may be due to the multifocality of the disease which led to more wide breast tissue excision.

In our study, there was 2 cases of local recurrence for 12 months. Only 2 cases in our study developed local recurrence with an incidence of 6.6 %. The recurrence in 1 case of skin sparing mastectomy with LD flap was after 14 months of the operation, while the other case was recorded in a patient who underwent conservative breast surgery after 15months of surgery.

Lhenaff et al., 2019<sup>(20)</sup>, reported local recurrence rate post SSM during a median of 192 months follow-up was 1.04%.

Lim et al., 2018,<sup>(21)</sup> reported a local recurrence rate of 2% Post CBS during a median of 30 months follow-up

The higher recurrence rate in our study can be explained by small sample size in our study.

### **Conclusion:**

Both BCS and SSM are oncologically safe procedure for treating multifocal tumors when used in selected patients according to a multidisciplinary decision-making process. Surgery type has no effect on recurrence rate in patients with multifocal tumors. Skin sparing mastectomy was superior regarding cosmetic results, unfortunately, at the

expense of more rate of postoperative flap necrosis.

---

## REFERENCES

1. Kurtz JM, Jacquemier J, Amalric R, Brandone H, Ayme Y, Hans D, Bressac C, Spitalier JM (2010): Breast-conserving therapy for macroscopically multiple cancers. *Ann Surg*;212:38–44.
2. Berg WA, Gilbreath PL (2011):Multicentric and multifocal cancer: Whole-breast US in preoperative evaluation. *Radiology* 214:59
3. Houssami N, CiattoS, MacaskillP, et al (2012): Accuracy and surgical impact of magnetic resonance imaging in breast cancer staging: systematic review and meta-analysis in detection of multifocal and multicentric cancer, *J Clin Oncol*, vol. 26 (pg. 3248-3258)
4. Coombs J, Boyages N, Lai NE, Kaya H et al(2010). Multifocal and Multicentric Breast Cancer: Does Each Focus Matter? *Journal of Clinical Oncology*, Vol 23:7497-7502.
5. Moran MS, Schnitt SJ, Gioliano AE et al (2014): Society of surgical oncology-american society for radiation oncology consensus guideline on margins for breast-conserving surgery with whole-breast irradiation in stage I and II invasive breast cancer. *Ann Surg Oncol* 21:704–716.
6. Simmons RM, Adamovich TL (2013): Skin-sparing mastectomy. *Surg Clin North Am.*, 83: 885-99.
7. Beer GM, Varga Z, Budi S, Seifert B, Meyer VE (2012). Incidence of the superficial fascia and its relevance in skin-sparing mastectomy. *Cancer.*; 94 (6):1619–1625.
8. Chu, K. C., Tarone, R. E., Kessler, L. G., Ries, L. A. G., Hankey, B. F., Miller, B. A., & Edwards, B. K. (2012). *Recent Trends in U.S. Breast Cancer Incidence, Survival, and Mortality Rates. JNCI Journal of the National Cancer Institute*, 88(21): 1571–1579
9. Van Maaren, M. C., de Munck, L., de Bock, G. H., Jobsen, J. J., van Dalen, T., Linn, S. Siesling, S. (2016). 10 year survival after breast-conserving surgery plus radiotherapy compared with mastectomy in early breast cancer in the Netherlands: a population-based study. *The Lancet Oncology*, 17(8): 1158–1170.
10. Volders, J. H., Negenborn, V. L., Spronk, P. E., Krekel, N. M. A., Schoonmade, L. J., Meijer, an den Tol, M. P. (2017): Breast-conserving surgery following neoadjuvant therapy-a systematic review on surgical outcomes. *Breast Cancer Research and Treatment*, 168(1): 1–12.
11. Bleicher, R. J., Ruth, K., Sigurdson, E. R., Beck, J. R., Ross, E., Wong, Y. Egleston, B. L. (2016):*Time to Surgery and Breast Cancer Survival in the United States. JAMA Oncology*, 2(3): 330.
12. Mansell, J., Weiler-Mithoff, E., Stallard, S., Doughty, J. C., Mallon, E., &Romics, L. (2017). *Oncoplastic breast conservation surgery is oncologically safe when compared to wide local excision and mastectomy. The Breast*, 32, 179–185.
13. TenofskyPL, Dowell P, Topalovski T, Helmer SD (2014): Surgical, oncologic, and cosmetic differences between oncoplastic and nononcoplastic breast conserving surgery in breast cancer patients. *Am J Surg.*; 207 (3): 398–402; discussion 02.
14. Gennaro, M., Ferraris, C., Guida, V., Tomasic, G., Carcangiu, M. L., & Greco, M. (2011): *Conservative surgery in breast cancer. Significance of resection margins. The Breast*, 10(5): 432–437
15. Lambert, K., &Mokbel, K. (2012): *Does post-mastectomy radiotherapy represent a contraindication to skin-sparing mastectomy and immediate reconstruction: An update. Surgical Oncology*, 21(2): e67–e74.

16. Wang, M., Huang, J., & Chagpar, A. B. (2019): *Is nipple sparing mastectomy associated with increased complications, readmission and length of stay compared to skin sparing mastectomy? The American Journal of Surgery.*
17. Rezai, M., Kraemer, S., Kimmig, R., & Kern, P. (2015): *Breast conservative surgery and local recurrence. The Breast, 24, S100–S107*
18. Ueda, S., Tamaki, Y., Yano, K., Okishiro, N., Yanagisawa, T., Imasato, M. Noguchi, S. (2013). *Cosmetic outcome and patient satisfaction after skin-sparing mastectomy for breast cancer with immediate reconstruction of the breast. Surgery, 143(3): 414–425.*
19. Dewar, J. A., Benhamou, S., Benhamou, E., Arriagada, R., Petit, J. Y., Fontaine, F., & Sarrazin, D (2011): *Cosmetic results following lumpectomy axillary dissection and radiotherapy for small breast cancers. Radiotherapy and Oncology, 12(4): 273–280.* Cosmetic outcome and patient satisfaction after skin-sparing mastectomy for breast cancer with immediate reconstruction of the breast. *Surgery, 143(3): 414–425.*
20. Lhenaff, M, Tunon de Lara, C, Fournier, M., Charitansky, H, Brouste, V, Mathoulin-Pelissier, S., MacGrogan, G (2019): *A single-center study on total mastectomy versus skin-sparing mastectomy in case of pure ductal carcinoma in situ of the breast. European Journal of Surgical Oncology*
21. Lim, W, Park, E.-H, Choi, S.-L, Seo, J.-Y., Kim, H.-J, Chang, M.-A., Ahn, S.-H. (2009). *Breast Conserving Surgery for Multifocal Breast Cancer. Annals of Surgery, 249(1): 87–90.*

## دراسة مقارنة بين اجراء عملية جراحة الثدي التحفظية واستئصال الثدي مع الحفاظ علي الجلد في مرضي سرطان الثدي متعدد البؤر

أسامة علي الأطرش و رانيا الأحمدى الشيخ و أحمد جمال عثمان و عمرو احمد حسان

قسم الجراحة العامة - كلية الطب جامعة عين شمس

**المقدمة:** يعد سرطان الثدي هو الأكثر انتشارا بين السيدات في العالم المتقدم والنامي علي حد سواء حيث يمثل ٢٢.٩% من حالات الإصابة بالسرطان في السيدات وهو ايضا السبب الاول للوفاة من السرطان في السيدات ويكون سرطان الثدي متعدد البؤر اذا تواجد اثنين او اكثر من البؤر السرطانية في نفس الربع من الثدي بينما يكون متعدد المراكز اذا تواجدت بؤرين او اكثر في اماكن مختلفة من الثديوم التقدم في استخدام فحص الثدي بالرنيلولي ن المغناطيسي زادت نسبة اكتشاف اورام الثدي متعددة البؤر بنسبه ملحوظه حيث تبين في احد الدراسات ان نسبة الاكتشاف لاورام الثدي متعدد البؤر زادت بنسبة ١٦% نتيجة استخدام لرنين المغناطيسي

وبينما كان سابقا جراحة الثدي التحفظية ممنوعه في سرطان الثدي متعدد البؤر حيث كانت مصحوبه بنسب اعلي لارتداد الورم السرطاني اثبتت الدراسات لاحقا امكانية اجراء جراحة الثدي التحفظيه في سرطان الثدي متعدد البؤر مع نسب ارتداد للورم مماثله للاستئصال الكامل للثدي بشرط ازالة كل البؤر السرطانية

ويعد استئصال الثدي دون الجلد من طرق العلاج الفعاله في حالات سرطان الثدي متعدد البؤر حيث يتيح اعاده بناء الثدي في نفس الوقت ويطي نتائج تجميلية مرضيه للمريضة

**الهدف من الدراسة:** الهدف من الدراسة هو مقارنة جراحة الثدي التحفظي وجراحة استئصال الثدي المحافظ علي الجلد في حالات سرطان الثدي متعدد البؤر من حيث نسب الارتجاع الموضعي للورم السرطاني

**المرضى وطرق البحث:** تم اجراء هذه الدراسة علي ٣٠ مريض من مرضي عيادة الثدي بمستشفى الدمرداش الجامعي يعانون من ورم سرطاني متعدد البؤر بالثدي وتم تقسيمهم الي مجموعتين: **المجموعة الأولى:** تتكون من ١٥ مريض خضعن لجراحة استئصال تحفظي للورم وعلاج اشعاعي تكميلي

**المجموعة الثانية:** تتكون من ١٥ مريض خضعن لجراحة استئصال للثدي محافظ علي الجلد

تم متابعه المرضى لمدة سنة ونصف لاكتشاف نسب ارتداد الورم في كلا المجموعتين والمقارنة بينهما

**النتائج:** نتائج الدراسة اظهرت الاتي:

- وجود فرق طفيف في نسبة ارتداد الورم بعد كلا العمليتين
  - تعرض مرضي المجزعه الثانية الي نسبة اعلي من مضاعفات الجرح
  - النتائج التجميلية ونسبه رضا المرضى كانت اعلي في المجموعه الثانية
- وبالتالي اظرت الدراسة انا كلا العمليتين تعد امنه من حيث استئصال الورم كاملا ونسب ارتداد الورم كما اظهرت الدراسة ان كلا العمليتين تحقق نتائج تجميلية مرضية للمرضي