

## Imaging View of Arterial Tortuosity Syndrome - Case Report

Saleh F Alqahtani<sup>1</sup>, Ahmad A Alzoani<sup>2</sup>, Mohammed A Algathradi<sup>1</sup>,  
Abdullah A Alhayani<sup>3</sup>, Metrek Almetrek<sup>4</sup>

1. College of Medicine, King Khalid University, Abha, 2. Department of Neonatology, Abha Maternity and Children Hospital, Abha, 3. Department of Pediatrics, Abha Maternity and Children Hospital, Abha, Saudi Arabia, 4. Joint Program of Postgraduate Residency Training Program of Family Medicine in Khamis Mushayte

Correspondence author: Saleh Fahad Abdullah Alqahtani, E-mail: saleh.fahad777@gmail.com

### ABSTRACT

**Background:** Arterial tortuosity syndrome is one of the autosomal recessive diseases and caused by alterations (mutations) in the *SLC2A10* gene. It is a rare disorder worldwide and in Saudi Arabia. Its prevalence is unknown. In the medical literature, about 100 cases have been reported.

**Objectives:** An approach for how to diagnose a case of arterial tortuosity in newborn.

**Material and methods:** A radiological view report of a case aged 21 days old female baby patient presented to emergency department with vomiting and fever for one week.

**Results:** She was managed in Abha Maternity and Child Hospital and referred to the tertiary center for advanced management and follow up.

**Conclusion:** Arterial tortuosity syndrome usually presents with a different set of clinical features among reported cases and its manifestations going with the mutation type.

**Keywords:** Arterial tortuosity, vomiting, fever

### INTRODUCTION

Arterial tortuosity syndrome is rare disorder worldwide and in Saudi Arabia. Its prevalence is unknown. In the medical literature, about 100 cases have been reported. Arterial tortuosity syndrome is one of the autosomal recessive diseases and caused by alterations (mutations) in the *SLC2A10* gene<sup>(1)</sup>.

Its clinical manifestations include vascular features like tortuosity and elongation of the major arteries, pulmonary artery stenosis, pulmonary hypertension and non-vascular connective tissue related symptoms like a hernia, dysmorphic facial features and joint and skin laxity<sup>(2)</sup>.

Also, ventricular hypertrophy could be seen regularly. Many patients have an enormous face with micrognathia<sup>(3)</sup>.

In 1967, Ertugrul described the first case of this diseases, and then numerous cases have been reported, but the exact nature of Arterial tortuosity syndrome is unknown<sup>(3,4)</sup>.

**The study was done after approval of ethical board of King Khalid university.**

### CASE DESCRIPTION

A 21-days-old female baby patient presented to emergency department with vomiting and fever since one week, she was born at full term gestation spontaneously via vaginal rout at 28/3/2017. The baby was vigorous at birth with

good tone, regular respiration and a heart rate >100 pulses per minute, no resuscitation was required.

Baby admitted to Abha Maternity and Children Hospital from the Emergency Department at the age of 21 days due to frequent projectile vomiting that continued for one week before admission. The baby was dehydrated and irritable. There was a history of fever. After admission to side room abdominal ultrasound was done which confirmed the diagnosis of pyloric stenosis, so baby shifted to Neonatal Intensive Care Unit for surgical intervention.

Pyloromyotomy was carried out on 27/4/2017, and no post-operative complications reported.

After surgery a computed tomography angiography was done which showed significant tortuosity of the focal aorta and coarctation beyond the branching of the left common carotid artery and left subclavian artery (aortic arch diameter = 7 mm and the descending aorta diameter = 4 mm). Also, there was early branching of the pulmonary arteries with short pulmonary trunk and narrowing of the left pulmonary artery at its bifurcation from the pulmonary trunk. Besides, there was multiple collaterals in the right upper arm at the site of contrast injection. Moreover, there was Pectus excavation of the sternum (Figure 1).

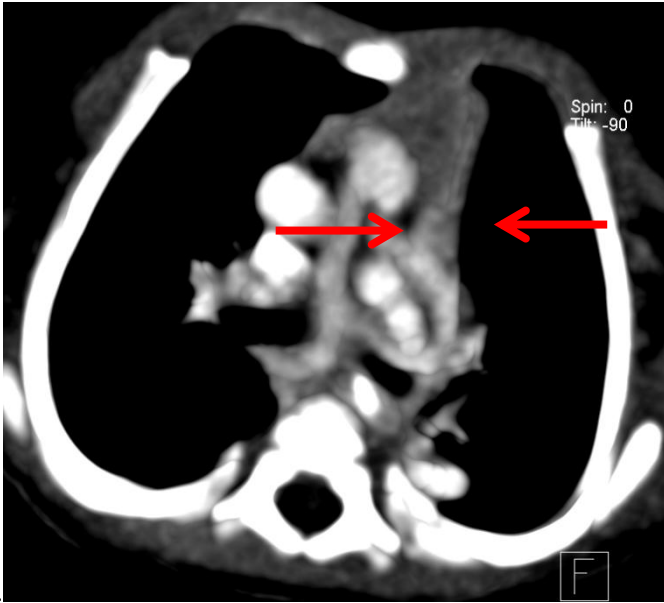


Fig 1 a

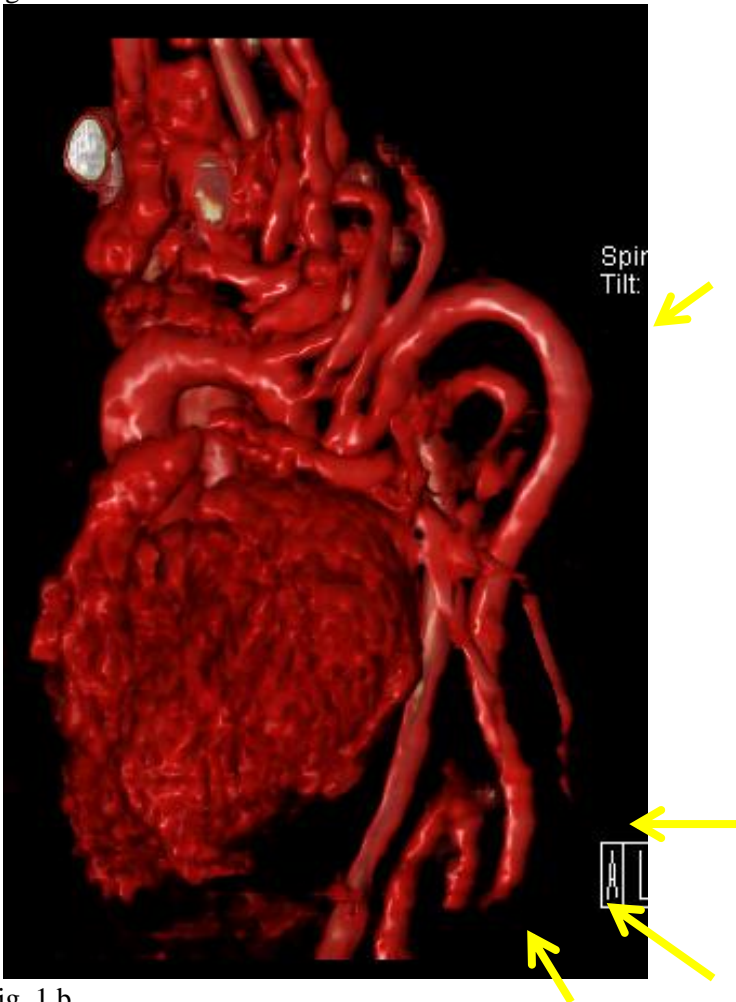

Fig. 1 b

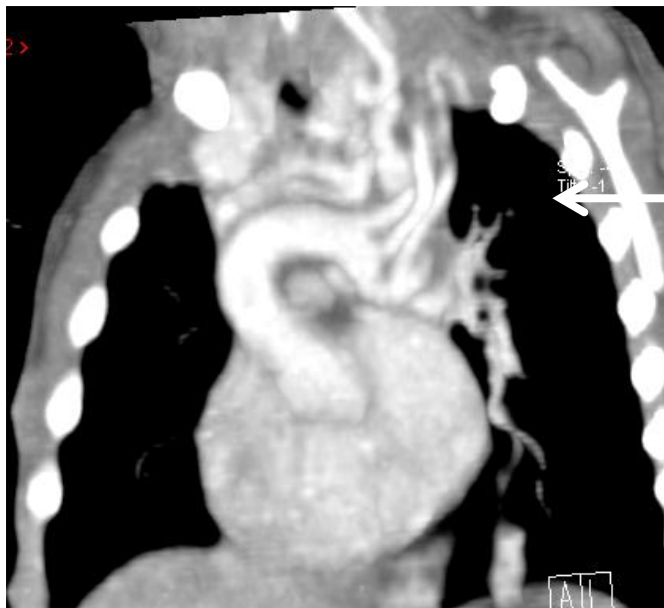


Fig 1c

**Figure 1(a,b,c):** 3D, axial and oblique coronal enhanced CT images demonstrate redundancy and tortuosity of the aortic arch and descending aorta (yellow arrows), pulmonary arteries (red arrows) and neck arteries (white arrow)

## DISCUSSION

Arterial tortuosity syndrome presents with a personalized different set of clinical features. Its manifestation depends on the mutation type. Literature showed that the most common presentation in all children is tortuous artery<sup>(3, 5, 6)</sup>. There was not available gene analysis in the local and national hospital for our case, but the characteristic angiographic feature showed significant tortuosity of the aorta, focal coarctation beyond the branching of the left common carotid artery and left subclavian artery which is giving a clue to the diagnosis of Arterial tortuosity syndrome and diagnosis seemed reasonable. In the past, this syndrome ascribed to the 20q13.1 gene but newly evidence approved the role of another gene in the mutation<sup>(7, 8)</sup>. Some literatures indicated the presence of an elongated typical face micrognathia and high palate which was not features in our case<sup>(3, 9, 10)</sup>.

Wessels et al. concluded that approximately 41 percent of the patient died in first five years of life, but there is one case that presented in 51 years old in addition to one child presented with pyloric stenosis at the age of one month<sup>(3, 8)</sup> and here by, it is usually miss diagnosed within other connective tissue disorders. Callewaert et al. reported 16 cases of Arterial tortuosity syndrome in the 12 families that two cases were presented with stroke (18 and 23 month years old)<sup>(11)</sup>.

The interventional radiological management of syndrome is going with its consequences. For

example, repair of peripheral pulmonary stenosis or aortic arterial aneurysm. In the present case, our management was like conservative due to the consequence and patient need. Asymptomatic arterial tortuosity does not need to any intervention unless in the cases of stenosis or aneurysm that needs to a specific intervention. Follow up of the patients for the complications, and for if the pulmonary stenosis becoming worse, appropriate intervention should be done.

## CONCLUSION

In conclusion, Arterial tortuosity syndrome usually presents with a different set of clinical features among reported cases and its manifestations going with the mutation type. The most common presentation is a tortuous artery, and more report of this rare case can help to better diagnosis of arterial tortuosity syndrome.

## ACKNOWLEDGMENT

We thank the Abha Maternity and Child Hospital for facilitating the follow up of the child in this report.

## CONFLICT OF INTEREST

There was no conflict of interest.

## REFERENCES

1. **Reference G (2017):** Arterial tortuosity syndrome [Internet]. Genetics Home Reference.

- Available from:  
<https://ghr.nlm.nih.gov/condition/arterial-tortuosity-syndrome>.
2. **Naunheim M, Walcott B, Nahed B, MacRae C, Levinson J and Ogilvy C(2011):** Arterial Tortuosity Syndrome with Multiple Intracranial Aneurysms. *Archives of Neurology*, 68(3): 369-71.
  3. **Callewaert B, De Paepe A and Coucke P(2014): Arterial Tortuosity Syndrome.** In: Adam, M.P., Ardinger, H.H., Pagon, R.A., et al., editors. *Gene Reviews®* [Internet]. Seattle (WA): University of Washington, Seattle; 1993-2017. Available from: <https://www.ncbi.nlm.nih.gov/books/NBK253404/>
  4. **ERTUGRUL A (1967):** Diffuse Tortuosity and Lengthening of the Arteries. *Circulation*, 36(3): 400-407.
  5. **Ritelli, M, Drera B, Vicchio M, Puppini G, Biban P, Pilati, M et al. (2009):** Arterial tortuosity syndrome in two Italian paediatric patients. *Orphanet Journal of Rare Diseases*, 4(1): 20.
  6. **Loup O, Daubeney P, Saggar A, Rubens M, Naqvi N and Ghez O (2013):** Severe Arterial Tortuosity in an Asymptomatic Infant With Coarctation. *Circulation: Cardiovascular Imaging*, 6(3): 487-490.
  7. **Lee Y, Huang H, Chang C, Cheng C and Chen Y (2010):** Mitochondrial GLUT10 facilitates dehydroascorbic acid import and protects cells against oxidative stress: mechanistic insight into arterial tortuosity syndrome. *Human Molecular Genetics*, 19(19): 3721-3733.
  8. **Castori M, Ritelli M, Zoppi N, Molisso L, Chiarelli N, Zaccagna F, Grammatico P and Colombi M (2012):** Adult presentation of arterial tortuosity syndrome in a 51-year-old woman with a novel homozygous c. 1411+ 1G> A mutation in the SLC2A10 gene. *American Journal of Medical Genetics Part A.*, 158(5): 1164-9.
  9. **Coucke P(2003):** Homozygosity mapping of a gene for arterial tortuosity syndrome to chromosome 20q13. *Journal of Medical Genetics*, 40(10): 747-751.
  10. **Faiyaz Ul. Haque M, Zaidi S, Wahab A, Eltohami A, Al-Mureikhi M, Al-Thani, G., et al.(2008):** Identification of a p.Ser81Arg encoding mutation in SLC2A10 gene of arterial tortuosity syndrome patients from 10 Qatari families. *Clinical Genetics*, 74(2): 189-193.
  11. **Callewaert B, Willaert A, Kerstjens-Frederikse W, De Backer J, Devriendt K, Albrecht B, et al.(2008):** Arterial tortuosity syndrome: clinical and molecular findings in 12 newly identified families. *Human Mutation*, 29(1): 150-158.