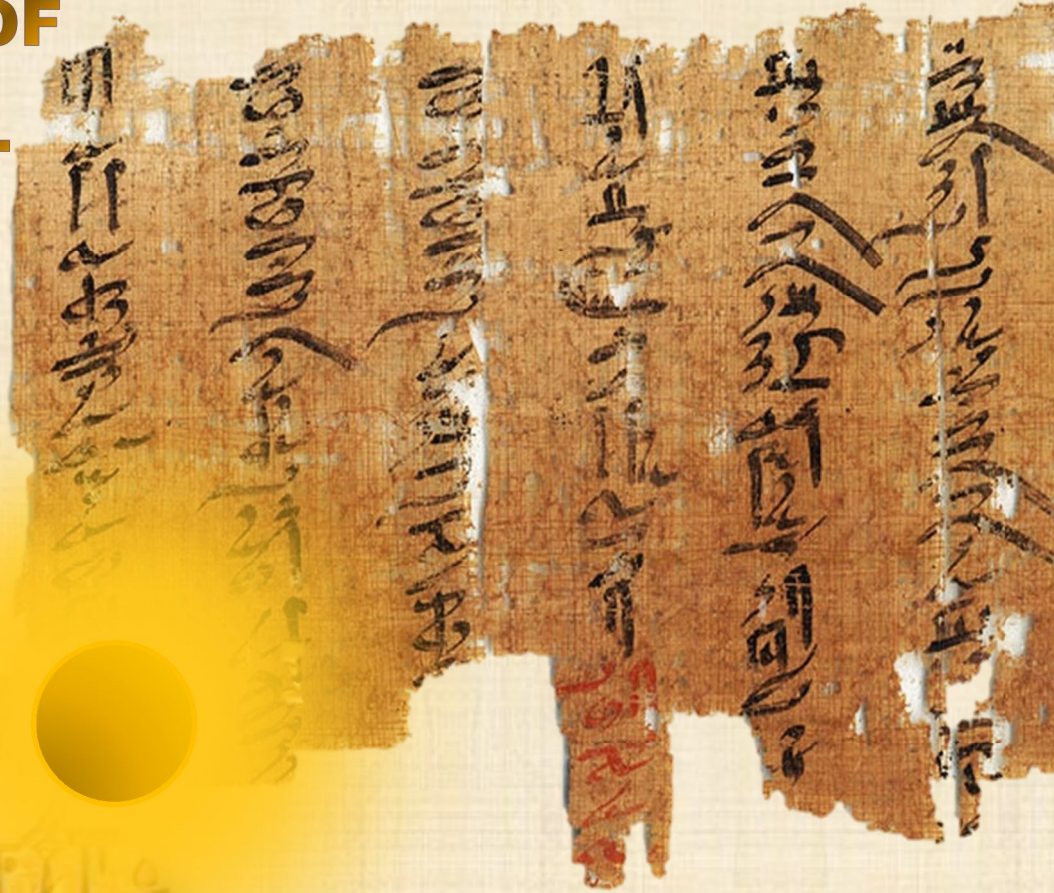


IJMA

INTERNATIONAL JOURNAL OF MEDICAL ARTS



VOLUME 2, ISSUE 4, AUTUMN 2020)



<http://ijma.journals.ekb.eg/>

Print ISSN: 2636 - 4174

Online ISSN: 2682 - 3780



Available online at Journal Website
<https://ijma.journals.ekb.eg/>
Main subject [Surgery [Ophthalmology]]*



Original article

Evaluation of The Efficacy of Argon Laser in Treatment of Xanthelasma Palpebrarum using Ultrasound Biomicroscopy

Essam Khalaf Mohamed^[a]; Ahmed Mahmoud Amin^[b], Mohamed Abdel Hamid Abou El-Enin^[b]

Ophthalmology Department, Police Hospital, Ministry of Interior, Egypt ^[a].

Department of Ophthalmology, Faculty of Medicine, Al-Azhar University, Egypt^[b].

Corresponding author

Ahmed Mahmoud Amin

Email: ophth.ahmedamin@gmail.com

Received at: June 07, 2020; Revised at: July 04, 2020; Accepted at: July 06, 2020

DOI: [10.21608/IJMA.2020.106840](https://doi.org/10.21608/IJMA.2020.106840)

ABSTRACT

Background: Xanthelasma palpebrarum [XP] is the most common of the xanthomas with asymptomatic, symmetrical, bilateral, soft, yellow, polygonal papules around the eyelids. The surgical laser offers an extremely elegant and powerful solution to this problem.

Aim of the work: To evaluate the efficacy of Argon Laser in treatment of xanthelasma palpebrarum, based on ultrasound biomicroscopy [UBM]. Preoperatively, full history and clinical examination had been carried out.

Patients and Methods: The study included 45 eyelids of 27 patients [13 males and 14 females] presenting with xanthelasma lesion. They underwent single session treatment of XP by Argon Laser, which had been performed on an outpatient basis. Postoperative UBM had been used to ensure eradication of the lesion. Follow up of the patient every 2 weeks in the first month then after 6 months].

Results: The UBM was successfully used preoperatively to determine the maximal lesion thickness that can be effectively safely eradicated in only single session. The therapy was well tolerated, and all lesions responded to the therapy in only single session. There were no functional or relevant aesthetic complications. The cosmetic outcome was considered to be excellent in 80% and good in 6.7% of the cases. The study included 45 eyelids, 36 [80.0%] of them had excellent, 3 [6.7%] had good, 2 [4.4%] had satisfactory and only 4 [8.9%] patients had poor cosmetic outcome. There were no recorded recurrent cases [0.0%] in the present study.

Conclusion: Argon laser photocoagulation [single session] represents an alternative treatment in selected cases. It is easy to be performed well tolerated by the patients. In addition, UBM was important to determine the maximal lesion thickness that can be eradicated safely in only one session.

Keywords: Xanthelasma palpebrarum; Argon Laser; Ultrasound Biomicroscopy; Xanthomas; Eyelid.

This is an open access article under the Creative Commons license [CC BY] [<https://creativecommons.org/licenses/by/2.0/>]

Please cite this article as: Mohamed EK, Amin AM, Abou El-Enin MA. Evaluation of The Efficacy of Argon Laser in Treatment of Xanthelasma Palpebrarum using Ultrasound Biomicroscopy. IJMA 2020; 2 [4]: 763-769 [Article in Press]. DOI: 10.21608/IJMA.2020.106840

* Main subject and any subcategories have been classified according to research topic.

INTRODUCTION

The medical term Xanthelasma palpebrarum [XP] is composed of two words. Xanthelasma, derived from ancient Greece where "xanthos" means yellow and "elesma" means plate. *Palpebrarum* is a Latin word that means "near or related to the eyelid." It is a lipid-rich deposition, mainly cholesterol. It is mostly semisolid yellowish deposits that are commonly found along the corners of the upper and lower eyelids. XP is the commonest cutaneous presentation of xanthoma. The epidermis is spared and the papillary dermis as well. It is characterized by soft, yellowish papules and plaques that occur more commonly near the inner canthus of the eyelid more often at the upper eyelid. Lesions are usually symmetrical. There might be one or multiple lesions^[1-3].

Xanthelasma palpebrarum is a benign condition that never leads to serious consequences, but it is cosmetically bothersome, and most of the patients are unhappy about their image, and seek medical advice. Patients visit reconstructive surgery units, dermatology offices, and ophthalmology clinics looking for permanent solutions. Unfortunately, the recurrence rate of Xanthelasma is high despite the treatment mode. Furthermore, it is important to treat the underlying medical conditions like hyperlipidemia, liver diseases, diabetes, and thyroid disorders^[4].

Xanthelasma was found to be associated with dyslipidemia. Thus, we recommend patients with xanthelasma to check their lipid profile and receive diet control and lipid-lowering medications for lipid abnormalities^[5].

Several methods can be used to treat xanthelasma palpebrarum, including simple surgical excision^[6], cryotherapy^[7], chemical peeling with trichloroacetic acid, with risk of irritation and pain^[8], and laser treatment. Different types of laser were tried using carbon dioxide laser^[9], argon laser^[10], KTP [Potassium titanyl phosphate] laser^[11], erbium: YAG [Neodymium-doped Yttrium Aluminum Garnet] laser^[12] and pulsed dye laser^[13].

In this study we used argon laser in treatment of xanthelasma in only a single session which appeared safe with low risk of scarring. Tissue coagulation via laser therapy is achieved when light is absorbed by tissue chromophores corresponding

to the laser's specific wavelength of light. Three of the major chromophores in the skin are melanin, hemoglobin and cellular water^[14].

As the chromophore absorbs light, thermal energy is released and absorbed by the surrounding tissue, thereby causing tissue destruction^[14].

In the case of xanthelasma, it is postulated that the thermal energy damages the perivascular foam cells leading to their destruction. In addition, the coagulation of hyper-permeable vessels within the dermis could theoretically lead to blockage of further lipid leakage into the tissue and thus prevent recurrence^[13].

Ultrasound biomicroscopy is an easy, non-invasive test used to visualize normal eyelid structures. It can be used in the diagnosis and follow-up of eyelid problems. The normal upper eyelid structures showed no significant differences based on age or gender^[15], fatty tissue appears hypoechoic on ultrasound so xanthelasma appears mostly hypoechoic^[16].

AIM OF THE WORK

To evaluate the efficacy of Argon Laser in treatment of xanthelasma palpebrarum, based on ultrasound biomicroscopy [UBM].

PATIENTS AND METHODS

A prospective, non-randomized, non comparative study had been carried out at El-Sayed Galal Hospital, between September 2018 and June 2020.

The study protocol adhered to the codes of declaration of Helsinki and had been approved by the ethics board of Al-Azhar University.

The study included 45 eyelids of 27 patients presenting with xanthelasma lesion. Patients were 13 males and 14 females. The average age was 56 years [range 39–66 years].

The **Inclusion criteria** were: patients with xanthelasma. On the other side, any patient with any chronic skin disease had been **excluded** from the study.

Mobile photos had been taken using mobile iPhone X. In addition, UBM had been used preoperatively to measure the dimensions and depth of the lesion as shown in figure 1. Preoperatively, full history and examination [general & local] had been carried out. In addition, the patient signed an

informed consent after counseling about the technique, risks, benefits and alternatives of the procedure.

Xylocaine gel had been applied to the surface of the lesion followed by local infiltration anesthesia of lidocaine 2%. Argon laser machine [visulas 532 vite from ZEISS] had been used. The Laser settings were: power [1000 mW], spot size [500 micron], duration of pulse [0.2-0.4 seconds] and wave length [500 nm].

The procedure had been done on an outpatient basis. Margin of the skin lesion had been outlined with a pen. The boundary between the abnormal and normal tissue had been firstly outlined by the laser. Then, the abnormal tissue had been gradually removed. The skin in the area of the lesion had been manually stretched to prevent surrounding tissue damage. Special attention had been paid to the margins of the lesion in order to prevent recurrence. Inevitable overlap of laser burns had been performed in our technique for complete eradication of the lesion and had been ensured by disappearance of all fatty tissue [yellowish in color] and appearance of normal healthy tissue [bright red in color] which was the end point as shown in figure 3.

All these steps were performed in only a single session, we could remove lesion up to 1.50 mm in depth. During the procedure an eye protector was applied so as not to cause any damage to the treated eye. Postoperative treatment composed of Hyalo4 Control Cream [Hyaluronic acid, sodium salt 0.2 % & silver sulfadiazine 1%] twice daily for 2 weeks. The crust which had formed fallen within 7–14 days and newly formed layer of skin was seen as shown in figure 4. Ultrasound biomicroscopy used post-operatively to be sure from complete eradication of the lesion and follow up as shown in figure 5, mobile photos were taken afterwards to evaluate the cosmetic outcome [follow up of the patient every 2 weeks in the first month then after 6 months, photos taken after complete healing of the lesion].

Cosmetically, the results rating from poor to excellent, means the skin of the lesion returned normal as the rest of the surrounding skin, good means the skin of the lesion returned nearly normal as the rest of the surrounding skin, satisfactory means the skin of the lesion had acceptable color and poor means there were new scar

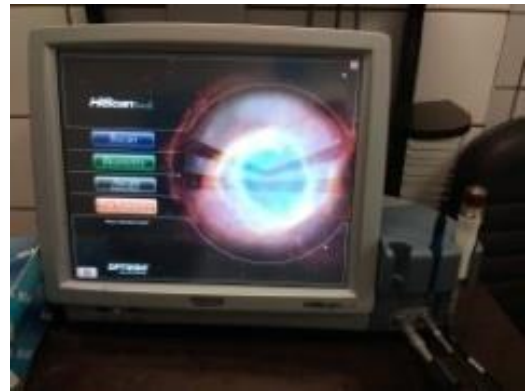

Figure [1] Ultrasound Biomicroscopy, [upper] OPTIKON Hiscantouch made in Italy, [lower] UBM probe

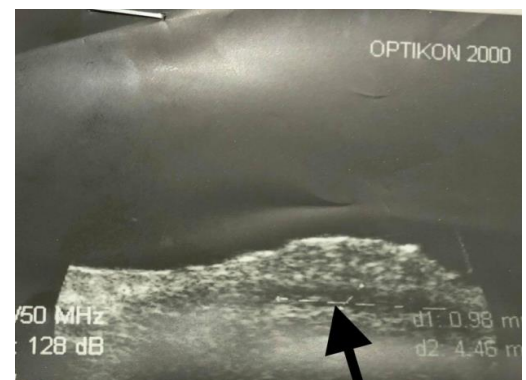


Figure [2]: UBM of xanthelasma preoperative, d1 [0.98mm] is thickness; d2 [4.46mm] is from side to side

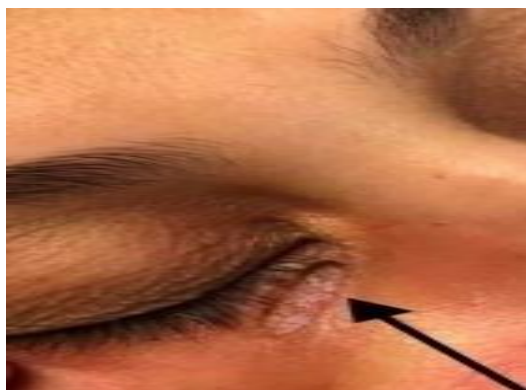

Figure [3]: Appearance of normal healthy tissue [bright red in color] immediately after laser.

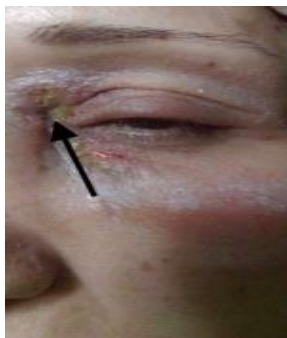

Figure [4]: Crust formation formed within 2:4 days after laser

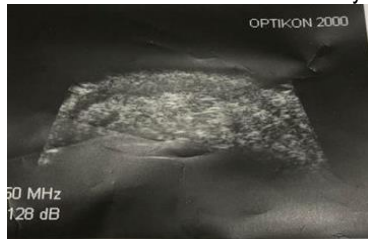


Figure [5]: UBM postoperative

RESULTS

In the current work, 45 eyelids [here each eye lid was treated as a separate patient] were included, 18 of them [40.0%] were for males and 27 [60.0%] were for females. The smoking history was absent among

33 [73.3%], mild among one [2.2%), moderate among another one [2.2%] and heavy smoking had been reported among 10 [22.2%]. Hyperlipidemia were reported among 9 [20.0%], diabetes mellitus reported among 15 [33.3%]; the skin complexion was fair among 31[68.9%], medium [2; 4.4%] and medium dark [12; 26.7%]; the patient body mass index was within normal among 18[40.0%] and overweight reported among 27[60.0%] [Table 1].

A complete removal of the xanthelasma lesions was achieved in all cases and all cases performed in only a single session. Xanthelasma recurred in zero eyes, 8–12 months after treatment.

The cosmetic outcome was poor in four patients, two were satisfactory, three were good and thirty six were excellent in cosmetic outcome. Three patients showed mild erythema, nine showed hypo-pigmented lesions and thirty three patients showed no pigmentation .Seven patients had mild scar, two had heavy scar and thirty six had no scar. The maximum lesion thickness could be removed was 1.50mm, the minimum lesion was 0.02mm.

Table [1] Patient characteristics

		Count [45 eyelids]	%
Sex	Male	18	40.0%
	Female	27	60.0%
Smoking	No	33	73.3%
	Mild	1	2.2%
	Moderate	1	2.2%
	Heavy	10	22.2%
Hyperlipidemia		9	20.0%
Diabetes		15	33.3%
Hypertension		16	35.6%
Skin complexions	Fair	31	68.9%
	Medium	2	4.4%
	Medium dark	12	26.7%
	Normal	18	40.0%
	Overweight	27	60.0%

Table [2]: Summarizes all results of the patients. The cosmetic result, pigmentation, scar and recurrence

		Statistics	
		n.	%
Cosmetics outcome	Poor	4	8.9%
	Satisfactory	2	4.4%
	Good	3	6.7%
	Excellent	36	80.0%
Pigmentation	No	33	73.3%
	Hypo pigmented	9	20.0%
	Erythema	3	6.7%
Disfigurement scar	No	36	80.0%
	Yes	2	4.4%
	Mild	5	11.1%
	Hypotrophic scar	2	4.4%
Recurrence	Yes	0	0.0%
	No	45	100.0%

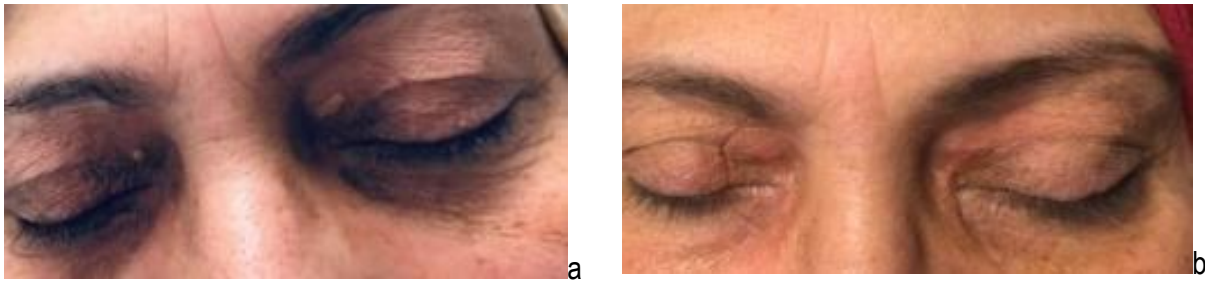


Figure [6]: Effect of Argon laser treatment [bilateral]; a: Xanthelasma before treatment, b: after 1 month of argon laser therapy

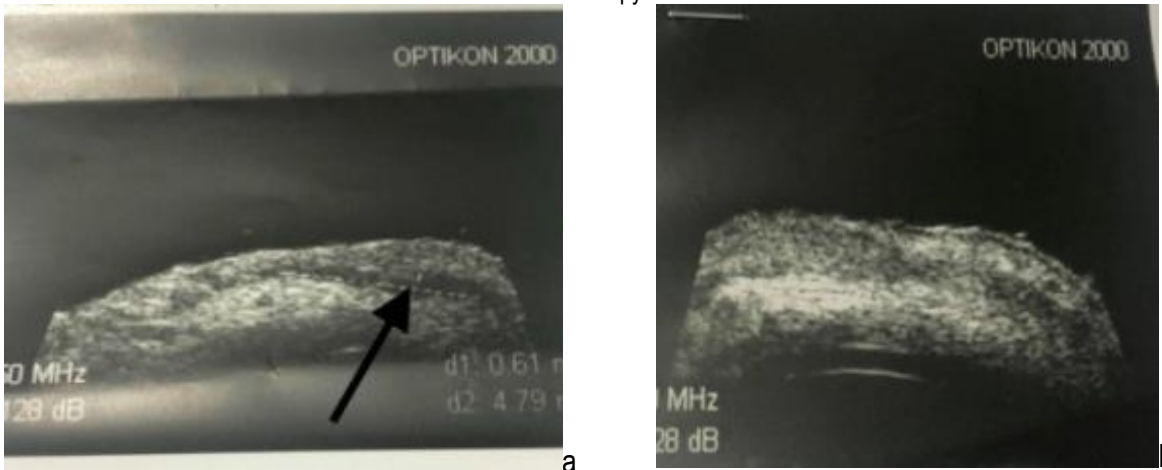


Figure [7]: Ubm changes. A: hypoechoic lesion [arrow] before laser d1 [0.61mm] is thickness, d2 [4.79mm] is from side to, b: complete disappearance after laser

DISUCSSION

The classical treatment of xanthelasmas is surgical excision; this method is associated with a concrete risk of scarring, especially when recurrent xanthelasmas are treated. The scars could lead to ectropion or facial asymmetry. On the other hand argon laser treatment has no risk of ectropion or facial asymmetry. This lesion could bleed significantly due to close spatial association of the foam cells with the vessel walls; Recurrence after surgical excision is not infrequent [17].

Mendelson and Maason^[18] gave 40% recurrence rate after the first excision and 60% after the second in their 92 patients. When four eyelids were involved they had an 80% recurrence rate, most recurred in the first year and the rate declined each year to up to 10 years thereafter.

Very extensive lesions may not be operable at all. Furthermore, for the treatment of relapses, the surgical approach may not be repeatable in contrast to argon laser technique which can be repeated if needed. On the other hand, the chemical cauterization of xanthelasmas with trichloroacetic acid or its derivatives has not proven satisfactory.

The depth of tissue penetration by the chemicals is hardly controllable; the risk of damage to the conjunctiva or sclera is high [18]; in our study we can detect the depth of the lesion by using UBM.

In the present study we measured the depth of the lesion using UBM and we can control the level of tissue penetration and stop at the end point; fortunately, due to their superficial location, xanthelasmas are ideal target for laser therapy. It is presumed that the caloric energy that originates from the coagulation of the vessels within the upper corium leads to damage of the perivascular foam cells in the lesion. The coagulation of the pathologically hyperpermeable vessels would lead to a block of the leakage of lipids into the tissue and thereby prevents recurrence. The precise photo ablation and coagulation of the skin's strata allow a gentle and bloodless ablation of the lesions [19].

The histological changes of xanthelasma after argon laser therapy are consistent with a superficial photocoagulation of the upper skin levels to a depth of 1 mm of dermis, preserving dermal appendages and aiding in the rapid healing of the wound [20].

As xanthelasma is usually confined to the

superficial reticular layer of the dermis, defects created by laser burn that do not extend deeper than this layer can heal without scarring. Hintschich reported 12 recurrences out of 32 treated lesions within the first 12–16 months after argon laser therapy [19]. This may be due to uncontrolled risk factors or due to incomplete removal of the lesion.

After the treatment of xanthelasma with the argon laser, the treated area showed a bluish tinge. About 1–2 weeks after the treatment, the lesions were completely relieved without any scarring or dyspigmentation. Hintschich described the cosmetic outcome as good or very good in 80% of cases with argon laser treatment [19]. There are different types of laser that can be used for treatment of xanthelasma. Raulin and his co-workers reported series of 52 periorbital xanthelasma treated with ultra-pulsed carbon dioxide laser, all lesions were removed completely with a single laser treatment. As regard for side effects, only transient pigment changes [4% hyperpigmentation, and 13% hypopigmentation] with no visible scarring was observed. Three patients [13%] developed a recurrence of xanthelasma [13].

In the present study we also used single laser session but in contrast to Raulin there were no recurrent cases had recorded. Also, Saif treated 25 patients with carbon dioxide with promising results. Most of patients got satisfactory cosmetic appearance. In 5 lids some pigmentary [5.7%] changes and 8 [9.1%] lids had recurrence [21]. Berger and Kopera employed KTP laser [532 nm] for first time with 85.7% of cases showed respectable reduction in xanthelasma after 1–3 KTP laser sessions without side effects, also 70% of their patients tolerated treatment without any analgesia [11]. The use of dye laser [585 nm] was described by Gosepath and Mann who divided treatment in 4–5 successive sessions, high patient acceptance with absence of complication was reported [22].

Erbium: YAG laser which was used in this study, is an instrument that allows surface removal of skin with minimum heat effect, only operative inside the skin without involving the melanocytes and blood vessels. It is characterized by a wave length 2.94 μm that corresponds to maximum absorption of water. Since approximately 77% of skin consists of water, this absorption was the optimal condition for the

removal effect. When the energy administered reaches the removal threshold, the water vaporizes at ultrasonic speed, removing the tissue with the sound phenomenon of a sharp bang [12].

Borelli and Kaudewitz treated 33 xanthelasma lesions with erbium: YAG laser with promising results as all lesions were removed without hyperpigmentation or scarring. Also [12], Mannino and colleagues reported good esthetic results in 30 female patients, 70 xanthelasmas treated with erbium:YAG laser without leaving scars and/or dyspigmentation. [23]

Kaufman and Hibst treated 9 xanthelasmas in 4 patients with erbium: YAG laser using spots with a diameter 2000 micron and energy of 315 mJ. Only in 2 patients particularly extensive lesions, atrophic scars remained after 4 months [24].

Drnovsek-Olup and Vedlin reported that in 32 xanthelasmas of 8 patients treated with erbium: YAG laser and with average follow up of 3 months, an optimum results were achieved in 100% of patients. For all the lesions, one single session of treatment was sufficient. [25]

In line with our study, Basar et al. [26] and Abdelkader and Alashry [27] used argon laser for treatment of xanthelasma palpebrarum.

In the present study we achieved 100% clearance with 0.0% recurrence rate and achieved 80.0% of excellent cosmetic outcome, while Abdelkader and Alashry [27] achieved 100% of clearance with 0.0% recurrence rate and achieved “excellent” results among 71.4%. Basar et al. [26] achieved 100% of clearance with 6 cases recurred [duration of follow up was 8-12 months] and achieved “good” results 85% of cases.

Conclusion: Argon laser can be a good alternative to other lines of treatment of xanthelasma palpebrarum, It is safe, has a low risk of visible scarring and interestingly in our study with tight control of risk factors by an internist as well as by the clearly defined laser treatment end point, no residual or recurrent lesions were encountered up to 12 months.

Financial and Non-Financial Relationships and Activities of Interest

None

REFERENCES

1. **Osaki TH, Osaki MH.** Management of Diffuse Xanthelasma Palpebrarum Using Trichloroacetic Acid Application to Reduce Lesions Followed by Surgical Excision. *Aesthet Surg J.* **2019** Jan 1;39(1):NP6-NP8. doi: 10.1093/asj/sjy268.
2. **Ren J, Zeng LY, Chen MH.** Treatment of Grade I and II types of xanthelasma palpebrarum with intralesional heparin sodium. *Dermatol Ther.* **2018** Nov; 31[6]: e12723. doi: 10.1111/dth.12723.
3. **Laftah Z, Al-Niimi F.** Xanthelasma: An Update on Treatment Modalities. *J Cutan Aesthet Surg.* **2018** Jan-Mar; 11[1]:1-6. doi: 10.4103/JCAS.JCAS_56_17.
4. **Al About AM, Al About DM.** Xanthelasma Palpebrarum. In: *Stat Pearls [Internet]. Treasure Island [FL]: Stat Pearls Publishing; 2020* Jan.2020 Jun 29. PMID: 30285396.
5. **Wang KY, Hsu KC, Liu WC, Yang kC, Chen LW.** Relationship Between Xanthelasma Palpebrarum and Hyperlipidemia. *Ann Plast Surg* **2018** Feb; 80[2S Suppl 1]: S84-S86. doi: 10.1097/SAP.0000000000001310.
6. **Lee HY, Jin US, Minn KW, Park YO.** Outcomes of surgical management of xanthelasma palpebrarum. *Arch Plast Surg* **2013**; 40[4]:380-6. doi: 10.5999/aps. 2013. 40. 4.380
7. **Laftah Z, Al-Niimi F.** Xanthelasma: An Update on Treatment Modalities. *J Cutan Aesthet Surg.* **2018** Jan-Mar;11(1):1-6. doi: 10.4103/JCAS.JCAS_56_17.
8. **Mourad B, Elgarhy LH, Ellakkawy HA, Elmahdy N.** Assessment of efficacy and tolerability of different concentrations of trichloroacetic acid vs. carbon dioxide laser in treatment of xanthelasma palpebrarum. *J Cosmet Dermatol.* **2015**;14(3):209-15. doi: 10.1111/jocd. 12148.
9. **Li D, Lin SB, Cheng B.** CO₂ Laser Treatment of Xanthelasma Palpebrarum in Skin Types III-IV: Efficacy and Complications After 9-Month Follow-Up. *Photobiomodul Photomed Laser Surg.* **2019** Apr; 37 (4): 244-247. doi: 10.1089/photob.2018.4580.
10. **Abdelkader M, Alashry SE.** Argon laser versus erbium:YAG laser in the treatment of xanthelasma palpebrarum. *Saudi J Ophthalmol.* **2015** Apr-Jun; 29(2): 116-20. doi: 10.1016/j.sjopt.2014.09.017.
11. **Berger C., Kopera D.** KTP laser coagulation for xanthelasma palpebrarum. *J Dtsch Dermatol Ges.* **2005**; 3:775-779. [DOI: 10.1111/j.1610-0387. 2005. 05746.x].
12. **Heng JK, Chua SH, Goh CL, Cheng S, Tan V, Tan WP.** Treatment of xanthelasma palpebrarum with a 1064-nm, Q-switched Nd:YAG laser. *J Am Acad Dermatol.* **2017** Oct;77(4):728-734. doi: 10.1016/j.jaad. 2017. 03. 041.
13. **Sakhiya J, Sakhiya D, Dedakiya A, Gupta R, Khambhati R, Sidhhpura P, Daruwala F, Dudhatra N.** Retrospective Analysis of the Efficacy of 10,600nm Carbon Dioxide Laser Ablation for Small Congenital Melanocytic Nevi in Adults. *J Clin Aesthet Dermatol.* **2019** Apr;12(4): E61-E63.
14. **Forbat E, Al-Niimi F.** Nonvascular uses of pulsed dye laser in clinical dermatology. *J Cosmet Dermatol.* **2019** Apr 19. doi: 10.1111/jocd.12924.
15. **Demirci H, Nelson CC.** Ultrasound biomicroscopy of the upper eyelid structures in normal eyelids. *Ophthalmic Plast Reconstr Surg.* **2007** Mar-Apr;23(2):122-5. doi: 10.1097/IOP.0b013e31802f2074.
16. **Ihnatsenka B, Boezaart AP.** Ultrasound: Basic understanding and learning the language. *Int J Shoulder Surg.* **2010** Jul;4(3):55-62. doi: 10.4103/0973-6042.76960.
17. **Yang Y, Sun J, Xiong L, Li Q.** Treatment of xanthelasma palpebrarum by upper eyelid skin flap incorporating blepharoplasty. *Aesthetic Plast Surg.* **2013** Oct; 37(5): 882-6. doi: 10.1007/s00266-013-0195-0.
18. **Mendelson BC, Masson JK.** Xanthelasma follow-up on results after surgical excision. *Plast Reconstr Surg* **1976**; 58: 535- 538.
- 19- **Hintschich C.** Argon laser coagulation of xanthelasmas. *Ophthalmologe* **1995**; 92: 858-861. PMID: 8563438.
20. **Eedy DJ.** Treatment of xanthelasma by excision with secondary intention healing. *Clin Exp Dermatol.* **1996**; 21: 273-275. doi: 10.1111/j.1365-2230. 1996.tb 00092.x.
21. **Saif MYS.** Xanthelasma palpebrarum treatment by CO₂ laser. *Bull Ophthalmol Soc Egypt* **2007**; 100:791-794.
22. **Gosepath K, Mann W.** Der gepulstefarbstoff laser zur behind lung gutartiger oberflächennährgefa Bmi B bildurger. *Laryngo-Rhino-Otol.* **1995**; 74:500-503. DOI: 10.1055/s-2007-997788. [German; English abstract].
23. **Mannino G., Papale A., De Bella F., Mollo R.** Use of Erbium: YAG laser in the treatment of palpebral xanthelasmas. *Ophthalmic Surg Lasers.* **2001**; 32:129-133. PMID: 11300634.
24. **Kaufmann R., Hibst R.** Pulsed Erbium:YAG laser ablation in cutaneous surgery. *Lasers Surg Med.* **1996**; 19:324-330.].[DOI: 10.1002/[SICI]1096-9101[1996]19:3<324::AID-LSM7>3.0.CO;2-U].
- 25 **Drnovsek-Olup B., Vedlin B.** Use of Erbium: YAG laser for benign skin disorders. *Lasers Surg Med.* **1997**; 21:13-19. doi: 10.1002/[sic]1096-9101[1997]21:1<13::aid-lsm 3> 3.0.co;2-0].
26. **Basar E, Oguz H, Ozdemir H, Ozkan S, Uslu H.** Treatment of xanthelasma palpebrarum with argon laser photocoagulation. Argon laser and xanthelasma palpebrarum. *Int Ophthalmol.* **2004** Jan;25(1):9-11. doi: 10.1023/b: inte.0000018523.55861.6c.
27. **Abdelkader M, Alashry SE.** Argon laser versus erbium: YAG laser in the treatment of xanthelasma palpebrarum. *Saudi J Ophthalmol,* **2015**; 29: 116-120. doi: 10.1016/j.sjopt.2014.09.017.

International Journal

<https://ijma.journals.ekb.eg/>

Print ISSN: 2636-4174

Online ISSN: 2682-3780

of Medical Arts