



ASSESSMENT OF INTERNAL FIXATION OF PARASYMPHYSEAL MANDIBULAR FRACTURES USING ONE MINIPLATE WITH BRIDLE WIRE

Mojamel A Al-Affari *, Bahaa El Din A Tawfik **, Ahmed H El Feky**

ABSTRACT

Objective: This study was designed to assess the internal fixation of parasymphiseal fractures (PFs) using one miniplate with Bridle wire (BW) **Subjects and Methods:** The study was conducted on 10 patients (3 females and 7 males) divided randomly in two groups each one contains five patients. The patients' ages ranged from 18 to 40 years. In Group I (fixation done by Single miniplate with BW), the mean age at the time of surgery for group (I) was (25.4) years. While in Group II (fixation done by 2 miniplates), the ages ranged from 18 to 48 years with the mean age at the time of surgery was (30.8) years. All patients were recalled for follow-up at 2-day, 1 week, 2 weeks, 1 month and then monthly for 6 months after fracture fixation for to evaluate the occlusion, soft tissue dehiscence, exposure of the plate, mobility of segment, signs and symptoms of infection and pain will be evaluated according to the American association of Maxillofacial surgery (AAOMS). Periodontal status of adjacent teeth used for wiring will be evaluated. Post-operative Radiographs i.e. Orthopantomogram (OPG) will be taken at one week after the surgical procedure then 3 and 6 months. **Results:** There was no statically significant difference between the groups, only the operative time was highly significant in group I, the effect of BW applicated inter dentally in group I was transient in nature which disappeared after its removal. **Conclusion:** The fixation of PFs by single miniplate combined by BW performed adequate fixation also reduce the operative time and cost effective.

Key Words: Internal fixation, mandibular parasymphiseal fracture, bridle wire

INTRODUCTION

The mandible is one of the most commonly fractured bone in the facial skeleton. Symphyseal and parasymphiseal fractures (PFs) of the mandible have been reported to occur with a frequency of 9% to 57%⁽¹⁻³⁾. The treatment of mandibular fractures (MFs) should be guided by several principles, reduction of the anatomical position, fixation, immobilization of the fracture to facilitate healing, optimal and early restoration of function (rehabilitation)⁽⁴⁻⁶⁾.

Fixation of MFs has changed from maxillomandibular fixation (MMF) with or without internal wire fixation to internal plate and screw fixation without MMF^(7,8).

Champy and co-workers^(9,10) described a zone of tension in the alveolar part of the mandible and a zone of compression on the lower border. This information allowed ideal lines for mandibular internal fixation to be identified along the physiological tension lines. The placement of monocortical miniplate high in the mandible has been considered to neutralize tension or spreading forces along alveolar border. Also to distribute the compression forces along the inferior border of the mandible. Intraoral placement avoids external scars and potential injury to marginal mandibular branch of the facial nerve while allowing simultaneous fracture reduction and fixation and exact occlusal adjustment.

* Dentist, Yemeni Ministry of Health.

** Assistant Professor of Oral and Maxillofacial Surgery, Faculty of Dental Medicine, Boys, Cairo, Al-Azhar University.

In the mandible a line drawn at the base of the alveolar process corresponds to the line of tension where monocortical plates and screws can be fixed. In the parasymphysis region, another line is drawn near the lower border to neutralize the tension forces ^(11,12).

Although two plates have been used successfully for fracture fixation anterior to the mental foramen. A modification occasionally used for fractures in close proximity to the mental foramen to avoid trauma to the nerve. Instead of two miniplates, only one miniplate supplemented with loop wiring which include two or more teeth on both sides of the fracture line ^(13,14).

This modification may reduce the surgical trauma that may affect the mental nerve as well as injury to the roots of anterior teeth. Moreover it could reduce the duration of surgery and finally, cheaper. A factor that initiate the present study.

PATIENTS AND METHODS:

Ten patients aged between 18 – 48 years old with PFs were included in this study. The patients were selected among those attending the outpatient clinic of Oral and Maxillofacial Department at Sayed Galal Hospital, Al Azhar University. They suffered from PFs and seeking treatment. A thorough clinical evaluation was performed and initial diagnosis confirmed with panoramic radiograph. Each patient signed an informed written consent having all details about the procedure.

Eligibility criteria:

- Inclusion criteria:
 - a) Patients should have recent single PFs.
 - b) Patient have all the teeth.
- Exclusion criteria:
 - a) Edentulous patients.
 - b) Infection anywhere of the mandible.

- c) Comminuted fracture.
- d) Fractures with soft tissue loss.
- e) Gunshot fracture.
- f) Patient with multiple fractures.

Preoperative assessment:

Clinical evaluation:

Patients will be evaluated for the location, type and number of fractures, presence of tooth in fracture line, time elapsed between the presentations of the patient after trauma.

Radiographic evaluation:

Panoramic radiographs were taken to define the fracture margins, displacement of the segment. It is also useful in examining the existing dentition, presence of impacted teeth with respect to the fracture, alveolar process and position of the mandibular canal in relation to the intended position of the screws.

Patients were divided randomly into two groups according the technique of fixation.

Group I: The mean of fixation was single miniplate with bridle wire.

Group II: The mean of fixation was two miniplates.

Each patient was informed about the details of this procedure and sign written consent.

Surgical procedure:

Patients were hospitalized and operated under general anesthesia. The MMF was done using Ivy loop or arch bar. The intraoral approach will be utilized to expose the fracture. The fracture segments aligned and reduced by using bony clamp.

Miniplate was fixed with 7mm screws at the lower border of the mandible, a BW will be applied (tension band) for 4-6 weeks in group I, Fig (1).

while in the group II two miniplates one in lower border and the other in the upper border of the mandible (sub apical region).

After placement of the plates and the screws, the IMF was removed in both groups and the occlusion was checked for discrepancies and stability. The incision was closed using 3-0 Vicryl: Ethicon incorporated company, US.suture. Each patient was received 2gm of antibiotic intraoperative and continue at oral dose Augmentin GlaxoSmithKline Company, New Cairo, Cairo, Egypt for 4 days post operatively, anti-inflammatory and analgesics Brufen (Abbott Company, Sheraton, Cairo, Egypt) was prescribed after surgery, and continue on soft diet for 4 weeks.

Postoperative assessment:

All patients were evaluated clinically at intervals of 2-day, Fig. (2), 1 week, 2 weeks, 1 month and then monthly for 6 months. Evaluation of occlusion, soft tissue dehiscence, exposure of the plate, mobility of segment, signs and symptoms of infection and pain will be evaluated according to the American association of Maxillofacial surgery ⁽¹⁵⁾. Periodontal status of adjacent teeth used for wiring was evaluated. Postoperative radiograph was taken for each patient at 1st week, 3 and 6 months. The status of reduction and alignment of bone segments was observed for each patient. This was assessed using a score from 1 to 3 as described by Malhorta et al ⁽¹⁶⁾.

Score 3: Radiological evidence of precise anatomic reduction in the fracture site.

Score 2: Reduced fractures that were slightly displaced but had a satisfactory occlusion.

Score 1: Poorly reduced fractures that required a second operation to correct poor alignment and unacceptable occlusion. The data was collected and statistically analyzed using statistical package for social sciences (SPSS) software program V21.

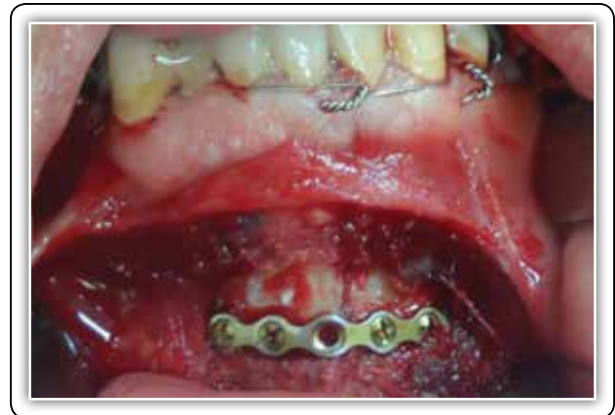

Fig (1) Fixation with single miniplate with BW.

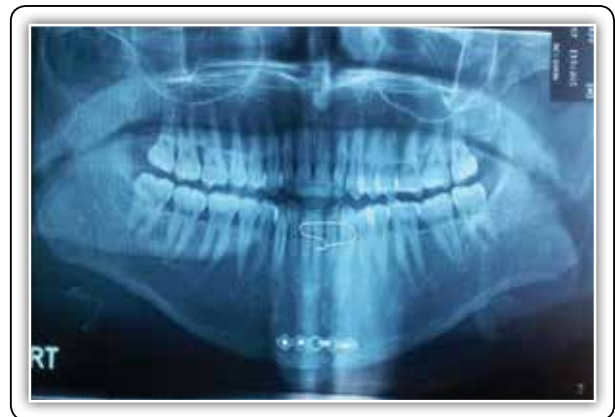

Fig (2): Two days post-operative OPG single miniplate with BW.

RESULTS

There were no clinically relevant differences between the 2 groups. The patient age was 26.5 ± 7.3 years in G I and 29.75 ± 10 years in G II ($P = 0.573$). Concerning the causes, there were no significant differences regarding the cause of PFs, the predominant cause was RTA, followed by IPV. The left side PFs were predominant in Group I with a percent of 80% (4:1) while in Group II, left side represent 60% and the right-side incidence was 40% (3:2).

Outcomes: The time elapsed from incision to closure was 24.10 min for the G I and 34.40min for G II. Overall average operating time was 25 minutes in group I and 35 minutes in group.

P value was highly significant as indicated by t-test ($p < 0.01$), Fig. (3).

Clinical results:

The occlusion of the patients was evaluated at 2nd day of operation, one week, 2 week, 4week, 6 week, 2 month, three and six months postoperatively. Fig Two patients in G I who developed a slight degree of malocclusion. After one week, this malocclusion disappeared, and only one patient in G II developed a slight degree of malocclusion. After one month, there were not any occlusal disturbance in any patient of the study. The results showed statically no significant ($p > 0.05$). between both groups at evaluation time.

Soft tissue dehiscence/exposure of plates:

The wound was been evaluated immediately after closure and then a day other day till the day of suture removal at seventh day. No wound healing disturbance was recorded in the patients of G I at different appointments. There was no case of wound dehiscence, loosening of plate and screw, and exposure of plate. One patient of G II showed partial wound dehiscence 1 week postoperatively, which healed uneventfully, with satisfactory results at 6-month follow up.

Mobility of segments:

In all patients of two groups, there was no fracture segment mobility noted post-operatively. Upper border or lower border splaying was not seen in either group.

Sign/symptoms of infection over the fracture site

No signs of infection in all the 10 cases of 2 groups during their stay in the hospital, no further observation of infection in all patients during the rest of follow-up period.

Edema:

During the first post-operative week, all cases showed normally expected post-surgical edema. During the follow-up periods no swelling was observed in all the cases of the two groups.

Pain:

During of the first post-operative week, all patients of 2 groups suffered from the usual expected post-operative pain, which had decreased in severity within three to seven days, this pain was controlled by the use of analgesics as previously mentioned.

By the end of the second post-operative week spontaneous pain was disappeared in all cases of 2 groups. At the first post-operative month during function was noticed in on case of group (I) and two cases in group (II), Fig. (4).

Periodontal status assessment:

Showed that, modified gingival index and bleeding index on probing were changed, these indices values rose significantly to peak values during the period when BW is in place, monitored parameters had totally reversed within two weeks after BW removal. these effects observed were transient in nature which disappeared after removal of BW, Fig. (5).

Radiographic results:

All the patients of the 2 groups showed a radiographic score of 3 revealing properly reduced fracture bony segments and properly aligned inferior border without step deformity at different appointments. Table shows the relation of degree of displacement pre and at different intervals postoperatively, Fig. (6).

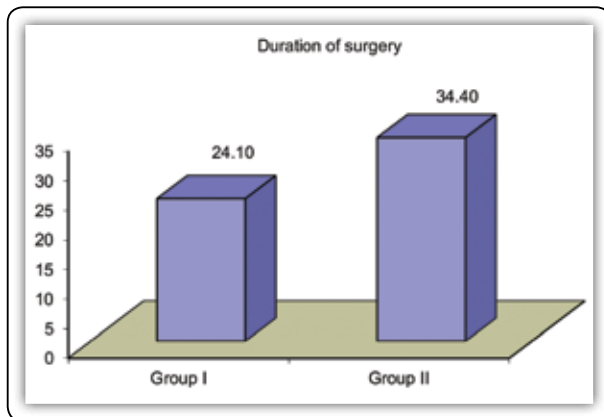


Fig (3): Showing Column chart comparing duration of surgery mean values between both groups.

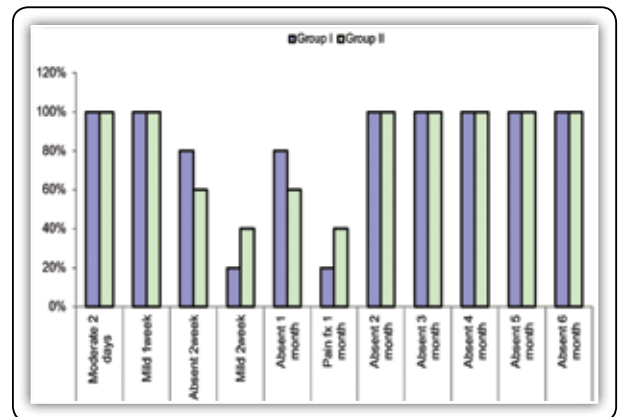


Fig (4): Showing frequency of clinical pain follow up in patients of group (I) and (II) from 2 day to 6-month post operatively.

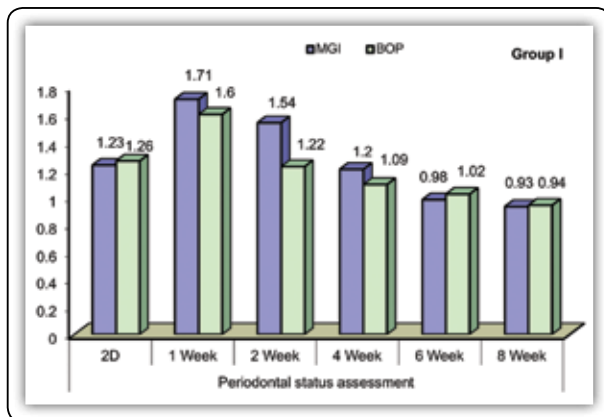


Fig. (5): Showing the effect of bridle wire on periodontium during 8 weeks.

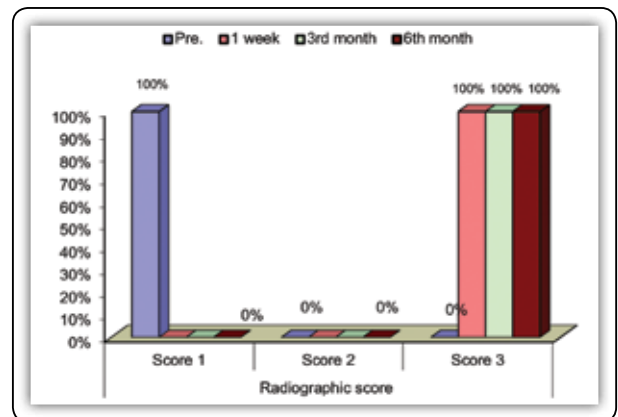


Fig (6): Representing radiographic reduction at different intervals.

DISCUSSION

The mandible is the second most commonly fractured part of the maxillofacial skeleton. The anterior region of the mandible represents the central horizontal part of the mandible, it is bounded bilaterally by vertical lines just distal to the mandibular canine teeth, including those that run in the midline of the mandible. AMFs represent a considerable entity of mandibular injuries (17).

Champy et al. proposed the intraoral application of monocortical miniplates to treat MFs. They showed that miniplates achieve the goal of osteosynthesis by neutralizing undesirable tensile forces while retaining favorable compressive forces

during function. Champy and colleagues determined “the ideal line of osteosynthesis” in the mandible, where miniplate fixation is the most stable (18).

The use of two miniplates is associated with many complications, therefore, the efforts to find the alternates of recommended procedure of double mini plate fixation are continuing (19). Saluja et al. in a survey reported that 38% of Indian oral and maxillofacial surgeons were in favor of using single miniplate for PFs while 62% use two miniplates. 42% of maxillofacial surgeons accepted that lower arch bar can be used as a tension band (20). Therefore, we decided to use BW as tension band with single miniplate as an alternative to double miniplates.

The average operating time required for single miniplate combined with BW was 24.10 min ranging from 20 min to 28 min it was highly significant ($p < 0.01$) and the operating time required for the placement of the two miniplate in group of control was 34.40 min ranging from 30min to 38 min. These findings were similar to the results of Rohan R et al. Who found that Two plate fixations take more time and longer operation time exposes the bone to a higher bacterial contamination ⁽²¹⁾

The occlusion of patients was checked preoperatively and during the follow-up stages after surgery. Preoperative examination revealed moderate occlusal discrepancy in seven patients (70%) and mild degree of malocclusion in three patients (30%). After reduction and internal fixation in group I, two patients developed postoperative moderate occlusion and the three patients developed postoperative mild occlusal discrepancy at the 2nd postoperative day. While all cases of group II developed postoperative mild occlusal discrepancy at the 2nd postoperative day, patients of this group return to their normal anatomic occlusion post-operatively in the first postoperative week. This occlusal postoperative discrepancy maybe due to the gross soft tissue and muscle dissection occurred in cases of moderately displaced fracture that required a prolonged time of soft tissue exposure and dissection to properly reduce the fractured segments with subsequent a higher degree of postoperative pain and edema. This muscle injury resulted in a cusp to cusp relationship. This complication was self corrected by the end of the 1st week in two patients, the resolution of the edema after the application of hot fomentation and administration of anti-edematous drugs. The results of this study regarding the occlusion was highly significant by the end of the first month follow up periods. This was in accordance with Kumar S et al ⁽²²⁾. who found that occlusion discrepancies were not noticed in any patients treated by miniplates.

The wound healed perfectly in the present study without disturbance. This might be as a result of the clear and strict instructions given to the patients in

addition to the continuous monitoring and irrigation of the wounds at every day till the complete healing of the wound and removal of sutures. Only in one case of group II observed with partial wound dehiscence and treated adequately with daily irrigation and antibiotic medication, this is in agreement with Khalifa et al ⁽²³⁾. who found that no problems of wound healing, swelling, discoloration, or discharge were seen during follow-up periods expect in one patient of control group treated by 2 miniplates that showed slight wound dehiscence with exposure of the upper plate started at the second post-operative week.

Preoperatively, as regard to clinical stability, patients in the two groups showed mobility of the fractured segments. After ORIF, no mobility of the fractured segments was found. Adequate rigidity and stability of the fractured segments was achieved in all the cases, There were no material related failures are detected such as plate fracture or loosening of hardware. The Results of the present study is in accordance with Zakaullah S et al ⁽²⁴⁾. Helmy A et al ⁽²⁵⁾. As they reported that there was no segment mobility, nonunion or malunion.

In this study we that, All patients of 2 groups suffered from the usual expected post-operative pain, which had decreased in severity within three to seven days, this pain was controlled by the use of analgesics. Two weeks post op, spontaneous pain was disappeared in all patients of 2 groups. One case of group I and two cases in group (II) suffered from pain during function in the end of the first month, this symptom gradually disappeared. Sixth month post-operatively, all patients showed normal painless function. This was in accordance with Agarwal M et al ⁽²⁶⁾. That perform a clinical study to compare the efficacy of the 3D miniplates to standard miniplates in the osteosynthesis of mandibular symphysis and PFs. He found that, there were significant decrease in pain during follow up period between 1st week to one month, and no pain was observed in follow up after 3rd month in any group.

Panoramic radiographs was done for each patients preoperatively revealed a gap distance between the segments at the step deformity along the inferior border of the mandible that was less than 2 mm in 6 patients (60%) while the remaining three patients showed a degree of displacement more than 2 mm (40%). Immediate and final postoperative radiographs revealed no displacement at all in patients of the current study. Due to the proper application of intra operative IMF and the proper placement of the bone plates, all fractures appeared to be well reduced. Postoperative radiographs showed excellent reduction in all cases, with alignment of the osseous borders of the mandible. These results were highly significant at all postoperative periods in our study. A result of this study is in accordance with study of Malhorta et al ⁽¹⁶⁾ and Khalifa et al ⁽²³⁾.

The parameters used to determine the periodontal health status were GI, Loe and Silness ⁽²⁷⁾, BOP, Saxer and Miihleman ⁽²⁸⁾. Periodontal assessment in this study showed that, MGI and BOP were changed, these indices values rose significantly to peak values during the period when BW is in place, monitored parameters had totally reversed within two weeks after BW removal. The application of the BW causes trauma to the gingiva, acts as a constant irritating factor, causing inflammation, and difficulty in maintaining oral hygiene. Moreover, these effects observed were transient in nature which disappeared after removal of BW one week later. This result is in agreement with that of Bienengraber et al ⁽²⁹⁾. performed a clinical study and animal experiments. In the patients, an AB was used. He concluded that induced gingivitis heals after AB removal.

CONCLUSION

The fixation of PFs with single miniplate with BW provides good stability of fracture fragments, the BW is effective, rapid, and easily used. The use of single miniplate with BW reduced significantly the operating time and therefore the time of anesthesia, also has no deleterious effect on the healing of soft tissue wounds. Fixation by single miniplate with BW is also cheaper than fixation of two miniplate.

REFERENCES

1. Richardson M, Hayes J, Jordan R, Puckett A, Fort M. Biomechanical Evaluation of a Mandibular Spanning Plate Technique Compared to Standard Plating Techniques to Treat Mandibular Symphyseal Fractures. *Surg Rest Pract.* 2015; 16:1-7.
2. Madsen M, McDaniel C, Haug R. A Biomechanical Evaluation of Plating Techniques Used for Reconstructing Mandibular Symphysis/ Parasympysis Fractures. *J Oral Maxillofac Surg* 2008; 66:2012-19.
3. Hirani N, Pujara N. Comparison of Open Reduction and Internal Fixation in Case of Symphysis and Parasympysis Mandible Fracture. *Inter J Sci and Res* 2002; 60: 167-70.
4. Kai H, Tenhulzend D. Compression Osteosynthesis of Mandibular Fractures: A Retrospective Study. *J Oral Maxillofac Surg.*1985;43:585-09 .
5. Burm J, Hansen J. The Use of Microplates for Internal Fixation of Mandibular Fractures. *Plast Reconstr Surg.* 2010 ; 125:1485-92.
6. Rahim A, Warraich R. Mandibular Fracture Osteosynthesis: A comparison of three techniques. *Pakistan Oral & Dental Journal.* 2002; 29:201-6.
7. Chrcanovic B. Locking versus non-locking plate fixation in the management of mandibular fractures: a meta-analysis. *Int. J. Oral Maxillofac. Surg.* 2014; 43:1243-50.
8. Farooq P, Mohsin M, Bashir S, Zaroo M, Wani A, Rasool A. Should wiring be replaced by miniplating of mandibular fractures even in poor developing countries? *Int Surg J.* 2016; 3:1585-92.
9. Marentette L. Miniplate osteosynthesis of mandible fractures. *Head and neck surgery,* 1995;6: 86-08.
10. Bolourian R, Lazow S, Berger J. Transoral 2.0-mm Miniplate Fixation of Mandibular Fractures Plus 2 Weeks' Maxillomandibular Fixation: A Prospective Study. *J Oral Maxillofac Surg.* 2002; 60:167-70.
11. Saluja H, Kini Y, Mahindra U, Kharkar V, Rudagi B, Dehane V. A comparative evaluation of different treatment modalities for parasympysis fractures: a pilot study. *Int. J. Oral Maxillofac. Surg.* 2012; 41: 906-11.
12. Abdullah W. The use of a single titanium microplate in displaced pediatric parasympyseal mandibular fractures. *The Saudi Dental Journal.* 2009; 21: 95-100.

13. Niederdellmann H, Akuamo-boateng E. Internal fixation of fractures, *Int. J. Oral Surg.* 1978; 7: 252-05.
14. Saluja H, Dehane V, Kini Y, Mahindra U, Gaikwad P. Use of Miniplates in Parasymphysis Fractures: A Survey Conducted Among Oral and Maxillofacial Surgeons of India. *J. Maxillofac. Oral Surg.* 2013; 12: 312-04.
15. Laughlin R, Block M, Wilk R, Malloy R, Kent J. Resorbable Plates for the Fixation of Mandibular Fractures: A Prospective Study. *J Oral Maxillofac Surg* 2007; 65:89-96.
16. Malhorta K, Sharma A, Giraddi G, Shahi A. Versatility of Titanium 3D Plate in Comparison with Conventional Titanium Miniplate Fixation for the Management of Mandibular Fracture. *J Oral Maxillofac surg.* 2012; 11:284-90.
17. El-Mahallawy Y, Al-Mahalawy H. Herbert Cannulated Bone Screw Osteosynthesis in Anterior Mandibular Fracture Treatment: A Comparative Study with Lag Screw and Miniplate. *J Oral Maxillofac Surg.* 2018; 19: 1-25.
18. Champy M, Kahn JL. Fracture lines stability as a function of internal fixation system: An in vitro comparison using a mandibular angle model (discussion). *J Oral Maxillofac Surg.* 1995; 53:791-801.
19. Singh P, Kishore K, Goel M. Management of Mandibular Symphysis and Parasymphysis Fractures Using a Single Mini Plate with Erich Arch Bar: Our Experience. *J K SCI.* 2017; 19: 117-23.
20. Saluja H, Dehane V, Kini Y, Mahindra U. Use of miniplates parasymphysis Fractures: A survey conducted among oral and maxillofacial surgeons of India. *IJHNS* 2012; 3:8-10.
21. Rohan R , Keerthi R, Vaibhav N, Ghosh A, Katee K. Single Miniplate Fixation for Mandibular Symphysis and Parasymphysis Fracture as a Viable Alternative to Conventional Plating Based on Champy's Principles: A Prospective Comparative Clinical Study. *J. Maxillofac. Oral Surg.* 2017; 16:113-17.
22. Kumar S, Gattumeedhi SR, Sankhla B, Garg A, Ingle E, Dagli N. Comparative evaluation of bite forces in patients after treatment of mandibular fractures with miniplate osteosynthesis and internal locking miniplate osteosynthesis. *Journal of International Society of Preventive & Community Dentistry.* 2014; 4:26-31.
23. Khalifa M, El-Hawary H, Hussein M. Titanium Three Dimensional Miniplate versus Conventional Titanium Miniplate in Fixation of Anterior Mandibular Fractures. *Life Science Journal* 2012; 9:1006-10.
24. Zakaullah S, Kotrashetti S, Maiya R. Management of mandibular fractures using 1.3 mm low profile titanium miniplates. *Inter J Dent Clin.* 2011; 30:24-05.
25. Helmy M, Ezz M, Mekhemer S, El-Hawary H. Assessment of 1.5 Mm Low Profile Titanium Miniplate As a Tension Band in Treatment of Mandibular Parasymphyseal Fractures. *Glob J Oto.* 2017; 4:1-5.
26. Agarwal M, Meena B, Gupta D, Tiwari A, Jakhar S. A prospective randomized clinical trial comparing 3D and standard miniplates in treatment of mandibular symphysis and parasymphysis fractures. *J Oral maxillofac Surg.* 2014; 13:79-83.
27. Loe, H. Silness, J. Periodontal disease in pregnancy. I Prevalence and severity. *Acta Odont Scand.* 1963; 21:533-51.
28. Saxer, U, Miihleemann H. Motivation und AufklhLrung, *Schweiz Monatsschr Zahnheilkd.* 1975; 85:905-19.
29. Bienengraber V, Soni'o'eberg I, Wilken J. Clinical studies and animal experiments on the effect of wire splinting on the marginal part of the periodontium. *Dtsch. Stomatol.* 1973; 23: 86-94.