

Role of Neuroendoscopy in Management of Intraventricular Lesions

Shehab Mohamed El Khadrawy, Mohamed Ahmed Ellabab, Ahmed Mohamed Alzebak
Department Neurosurgery, Elhussin University Hospital, Cairo, Egypt.
ahmedalzebak@icloud.com

ABSTRACT

Objective: Intraventricular (IV) lesions are easily being approached with the endoscope through the ventricular system, because intraventricular tumors often cause cerebrospinal fluid (CSF) pathway obstruction and hydrocephalus. The aims of endoscopy in intraventricular tumors are usually the restoration of CSF pathway obstruction, clarification of the histology, and if possible, a complete tumor removal.

Methods: Twenty five consecutive cases with IV lesions were removed or biopsied with or without ETV and septum pellucidostomy. Patient information was retrospective entered into a database. Outcomes were evaluated by life table analysis.

Results: Twenty five patients had completed with ETV in 16 cases; six cases by cyst fenestration, seven cases tumor biopsy 10 cases cyst removal, two cases hematoma were evacuated. 16 cases improved post-operative (clinical and radiological), three cases needed VP shunt, Three cases with same clinical as pre-operative, One case presented with paresis, Two cases operated microscopically after one year.

Conclusions: The advantages of the endoscopic approach are minimal dissection and brain retraction. Reach to the target is rapid. The method of choice for removal of colloid cysts, arachnoid cysts and restore CSF pass way obstructed by lesions at the same operation.

Keywords: Arteriovenous malformation, Cerebrospinal fluid, Endoscopic third ventriculostomy, External ventricular drain, Intra cranial pressure, Intraventricular hemorrhage, Ventriculoperitoneal, Aqueduct of Salvias.

INTRODUCTION

Intraventricular lesions are easily approached with the endoscope through the ventricular system. Moreover, because intraventricular tumors often cause cerebrospinal fluid (CSF) pathway obstruction, resulting in ventricular dilation, sufficient space for maneuvering with the endoscopes is available. However, even in patients with narrow ventricles, the lesions may be approached accurately and safely with the aid of neuronavigation^(1, 2). The aims of endoscopy in intraventricular tumors are usually the restoration of CSF pathway obstruction, clarification of the histology, and if possible, a complete tumor removal⁽³⁾.

Advantages of the endoscopic approach are an improved visualization and illumination in the depth of the ventricles as well as less brain tissue dissection and retraction.

The endoscopic tumor surgery was limited to tumor biopsy, mostly performed after an endoscopic third ventriculostomy (ETV) in patients presenting with tumor-related obstructive hydrocephalus^(4, 5).

Another alternative procedure in management of ventricular tumors is stereotactic biopsy procedure. But it has a high risk of sampling error because of migration of tumor from target after puncture of ventricle and (CSF) drainage. It never contributes to treat of obstructed hydrocephalus.

Hydrocephalus should be treated beside tumor. One of treatment options is ventriculoperitoneal shunting (VP shunting). But it contributes to dissemination of some tumors such as pineoblastoma and germ cell tumors into peritoneal cavity⁽⁶⁾.

AIM OF THE WORK

The aim of this study was retrospectively evaluating of the role and outcome of use of endoscope in intraventricular lesions in term of: Diagnostic of the deep lesions. Management of increased ICP. Excision of lesions as much as possible.

PATIENTS AND METHODS

This retrospective study was carried on 25 successive patients who sought medical advice in 2016, 2018 in Alhussien University Hospital and Alexandria University Hospital. The inclusion criteria were patients with Intraventricular lesions (tumors, colloid cyst, arachnoid cyst and hge) with or without hydrocephalus. **The study was approved by the Ethics Board of Al-Azhar University.**

Lesions were removed or biopsied with or without ETV and septum pellucidostomy.

Then Clinical and radiological assessment of the patients were performed pre operation and immediate after surgery, one month, two months and four months after surgery for assessment of patient clinical, lesions recurrence for total

removed lesions, hydrocephalus and patency of the ventriculostomy

Exclusion criteria: Arteriovenous malformation (AVM). Aneurysm.

Operative technique used in this study:

GAAB and LOTTA rigid endoscopic systems were used (Karl Storz, GmbH, Tutlingen, Germany) for intraventricular visualization,

We carried out 20 cases right sided Kocher Burr Hole, four cases left sided burr hole (1 glioma

case + metastatic case + two colloid cyst) and one case One case operated left Keen's point.

Two burr hole technique in three cases (germ cell tumor, normal sample and teratoma) cases of pineal region tumor.

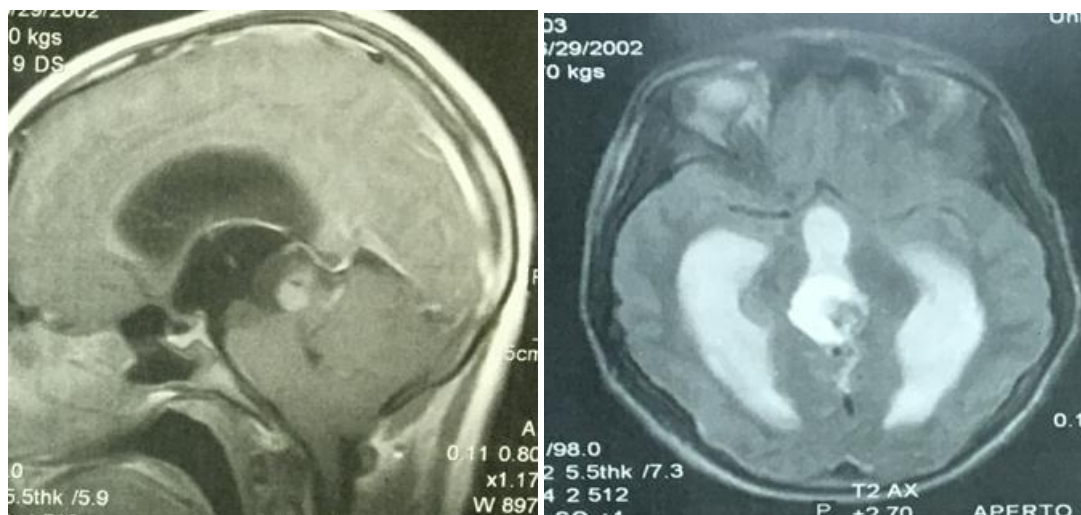
External ventricular drain was left in three cases (two IVH and one colloid cyst) for the following reasons: For measuring of the intracranial pressure, usually left closed. Safeguard against acute hydrocephalus and sudden death.

CASE PRESENTATIONS

Case 1 (germ cell tumor)

Male case 15 years complaining of headache, gait disturbance and six CN palsy. Past history by his mother of scrotal swelling since three years and relieve by chemotherapy.

MRI brain showing pineal region tumor with cystic component occluded the opening of Aqueduct of Salvia (AS) and causing hydrocephalus.



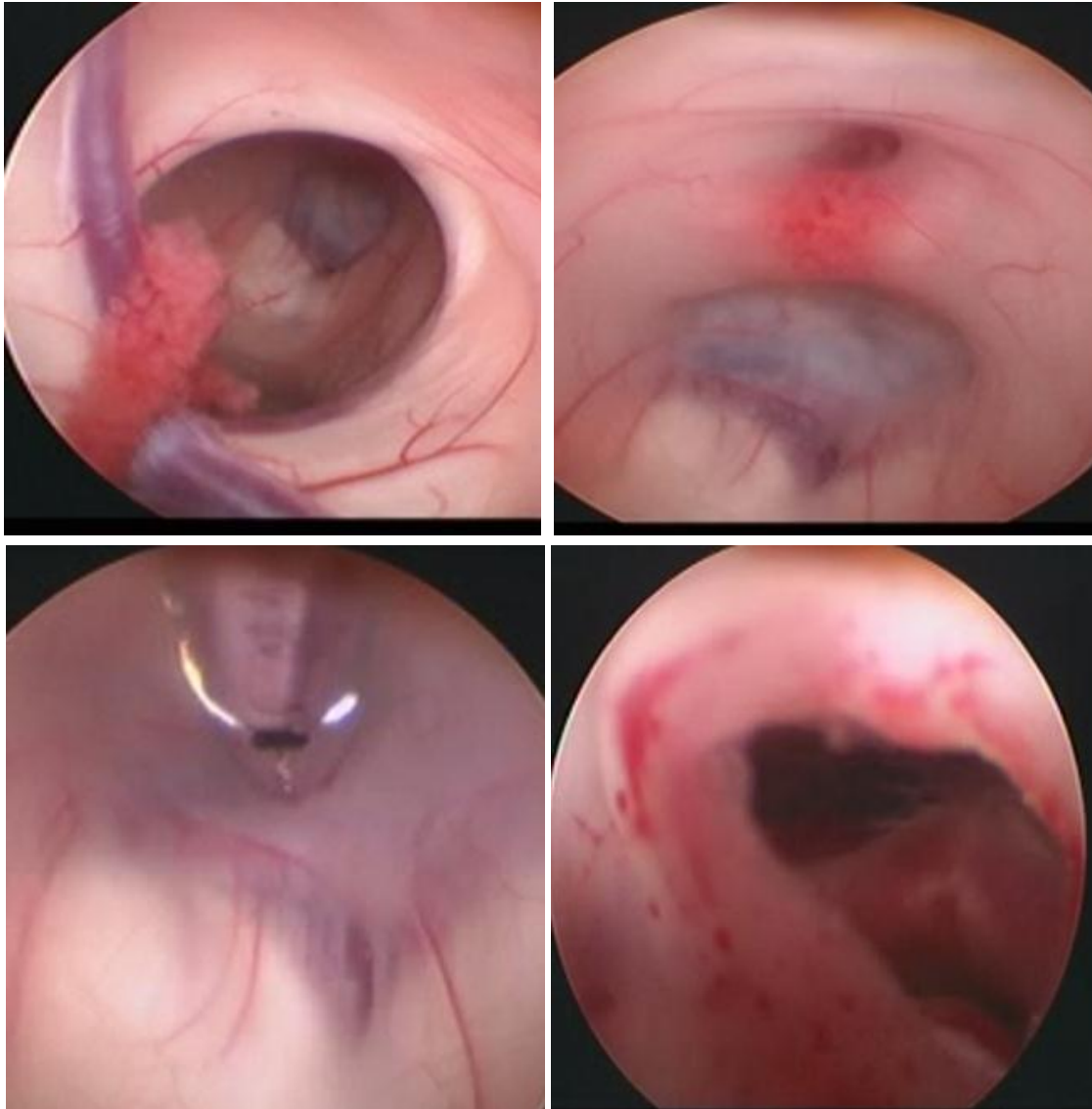
MRI pre operative in germ cell tumor

Pre operation taken a blood sample of alpha fetoprotein and HCG, the result was high. Case planned for ETV, CSF sample and tumor biopsy

Operative technique

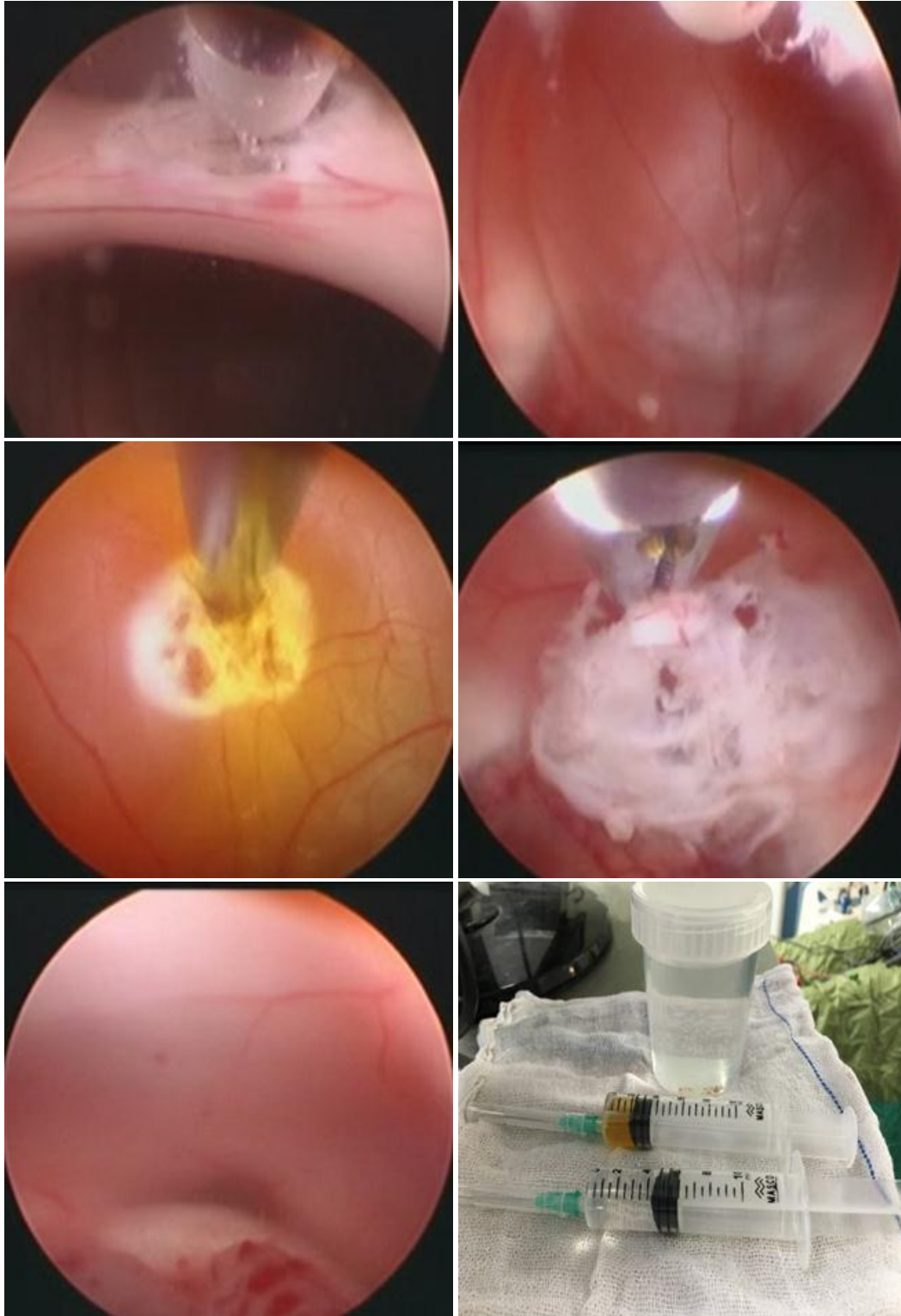
After induction general anesthesia case supine position with head elevation 30 degree mark on mid line and coronal suture Rt side linear skin 1st burr hole 1 cm pre coronal for ETV. After introduced endoscope into ventricle identification foramen of Monro, TSV and septal vein and take CSF for analysis of tumor seeding then introduce in to 3rd vent. To see optic chiasma, infundibulum, tuber cinerium and mammillary body.

At pre mammillary recess site of stoma by grasping forceps and wide stoma by ballooning. Then inspection of pre pontine cistern no adhesion presented.

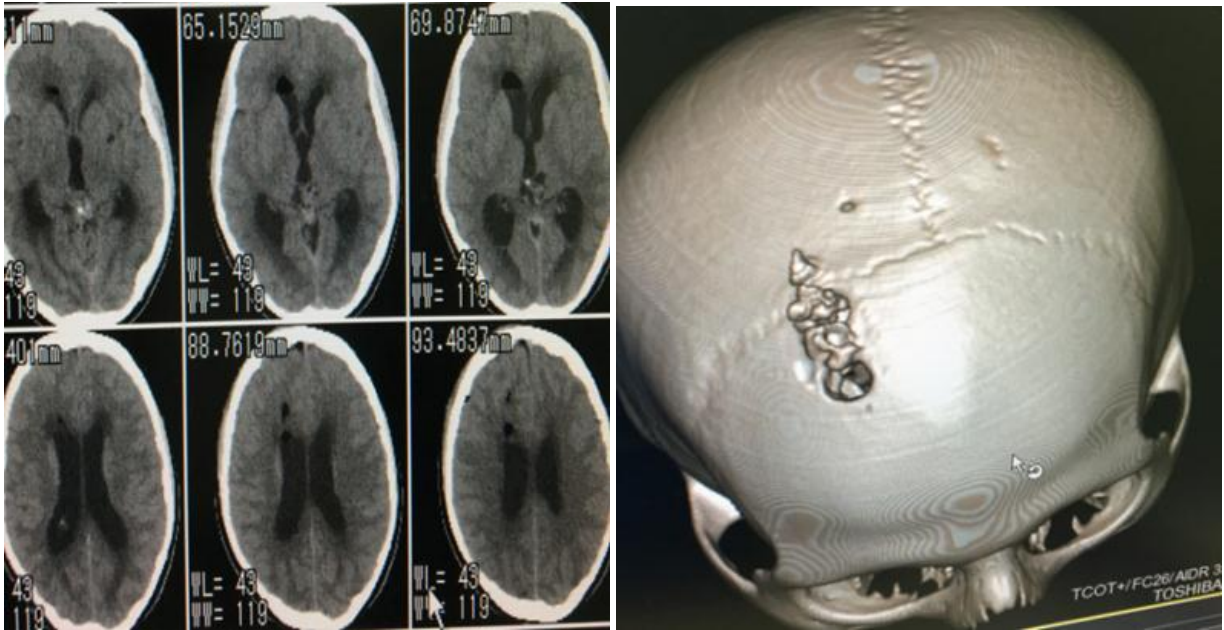


Intra Operative view in pineal tumor

After ETV we introduced endoscope through new burr hole 4 cm anterior to burr hole of ETV to 3rd ventricle to posterior part and notified inter thalamic adhesion and dissected by bipolar. Then identification of tumor in place coagulated the surface of cystic part and insertion decq for aspirate its content for analysis and take multiple sample by biopsy forceps for analysis until AS opened. Some minor bleeding controlled by coagulation and compression by tip of bipolar.

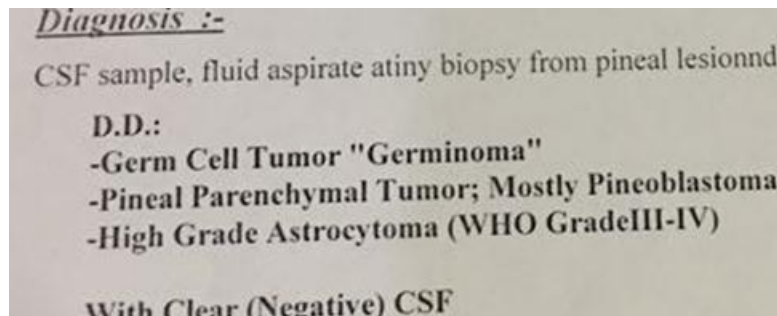


Operative technique and biopsy in pineal tumor
After surgery CT scan done relieve hydrocephalus and case complain.



Post operative CT in pineal tumor case

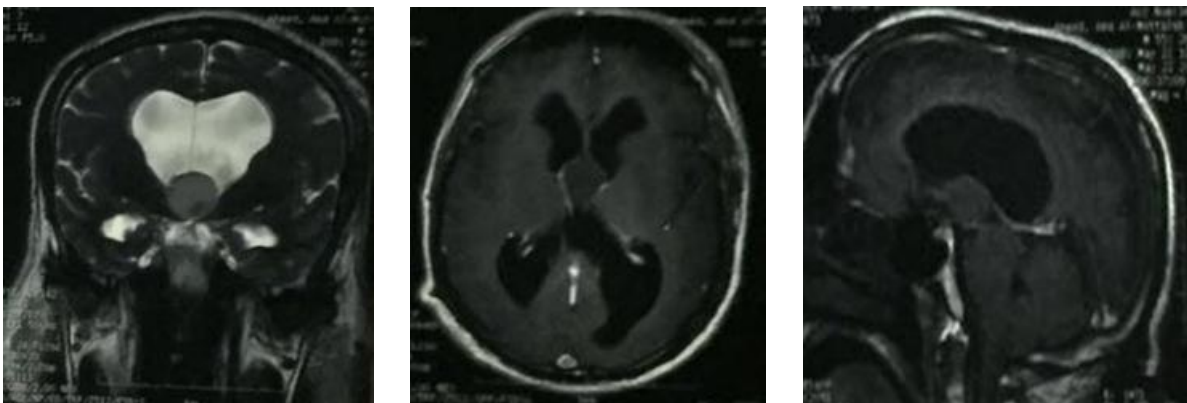
Sample result is germ cell tumor and CSF sample is free then case referral to oncologist for chemotherapy.



Biopsy result in pineal tumor

Case 2 (3rd ventricular colloid cyst)

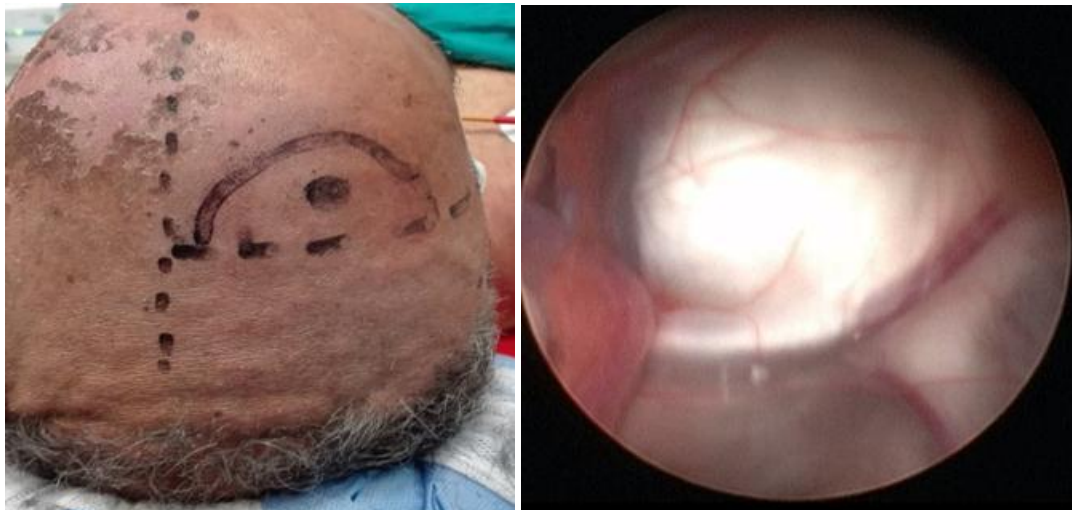Male case 60 years complaining of headache, manifestation of increase ICP attack of DLC since 1 month, CT scan showing 3rd ventricular hypodense cystic lesion and MRI isointense cystic lesion in 3rd ventricle in TW1 and TW2 about 1cm x 1,5 cm size deviated to RT side with hydrocephalus.



Pre operative MRI in colloid cyst case

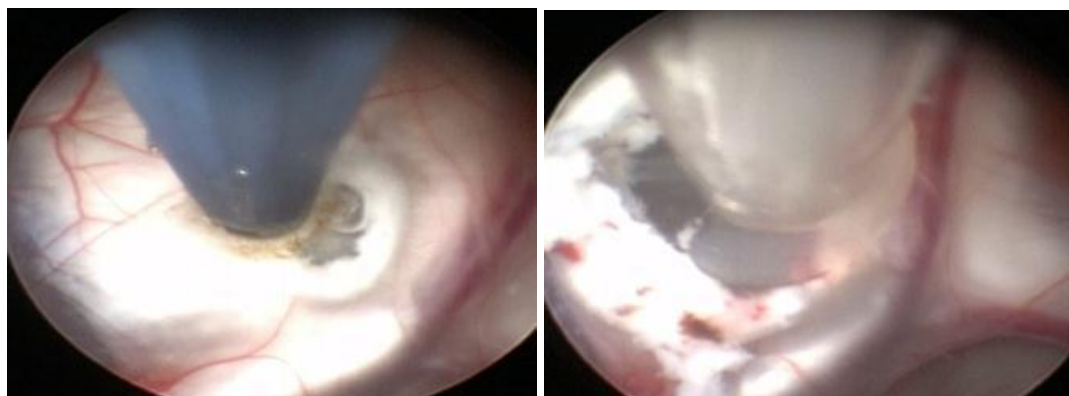
We underwent seven cases of colloid cyst five cases right Kocher burr hole and two cases left side. 3 cm off mid line and 1 or 2 cm anterior to coronal suture according to site in imaging.

The track created by ventricular needle and followed by the endoscopic tracker and sheath. The tracker was removed and the rigid lens scope was introduced inside the lateral ventricle. Identification of the anatomical landmarks and the colloid cyst at the foramen of Monro.



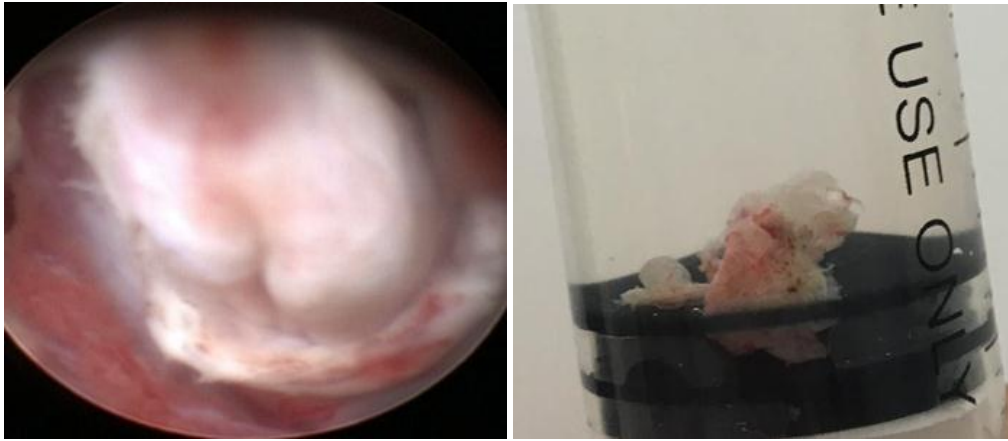Position and operative view in colloid cyst case

Sometimes the cyst was totally obscured by the choroid plexus that needed coagulation and removal for proper cyst visualization. We coagulated choroid plexus routinely in all cases to decrease incidence of bleeding by manipulation. Vessels on the cyst wall coagulated and the cyst capsule was punctured using an endoscopic scissors or punched in place using endoscopic forceps. Evacuation of the cyst content was carried out by intermittent controlled suction through 6F Neleton catheter introduced into the cyst cavity.



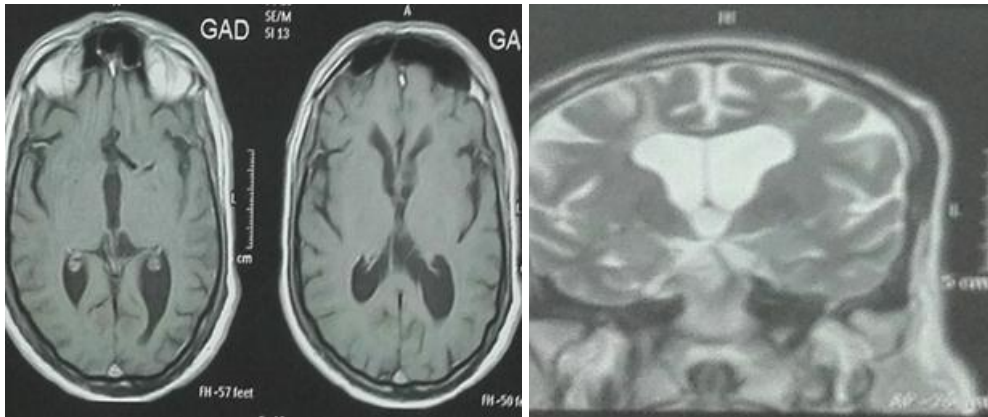
Evacuation of cyst content in colloid cyst

After completing evacuation of the colloid material, the whole cyst capsule was grasped and then peeled gently with the aid of an endoscopic grasper. Venous bleeding when occurred after capsule removal was always successfully controlled by irrigation alone or aided by Fogarty balloon tamponading at the edge of the foramen of Monro. In some cases we used dry field technique by suctioning of all bloody CSF. By using this technique, we assured better visualization of clot could be formed on bleeding site.



Removal of colloid cyst

After operation case complain was relieved and cyst sample result showed colloid cyst with no metaplasia after three months MRI follow up done no cyst.



Post operative MRI of colloid cyst

RESULTS

25 patients presented to Alhussin University Hospitals and Alexandria University Hospitals during the period from 2016 to 2018.

Ages ranged from 6 months to seventy eight years (mean age was 29.22 years)

14 patients were males and 11 patients were females.

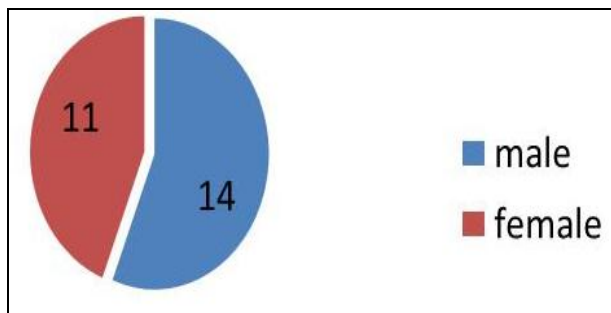


Figure (1): Number of cases according to sex.

More than half cases lesions located in third ventricle, 11 cases in anterior part of 3rd ventricle 44%, six cases in posterior part of 3rd ventricle 24%, one case upper surface of Aqueduct 4%. Four cases in lateral ventricle 16%. One case posterior fossa 4% and two cases of IVH in both lateral and 3rd ventricle 8%.

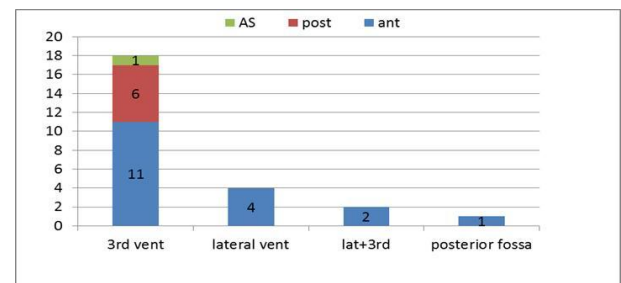


Figure (2): Number of cases according to locations of lesions.

23 cases associated with hydrocephalus 92%, two cases not associated hydrocephalus 8%.

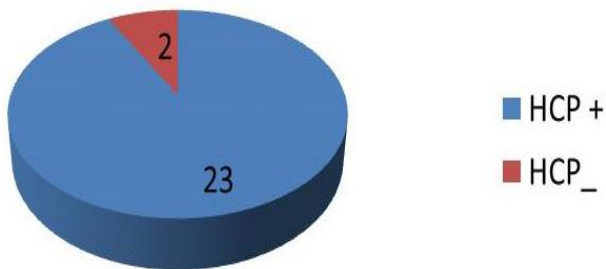


Figure (3): Number of cases according to hydrocephalus.

ETV done in 16 cases 64% and nine cases not needed ETV 36%. Six cases operated by cyst fenestration with ventricle 24%. Seven cases tumor biopsy 28%. 10 cases cyst removal 36% six of them without ETV 24%. Two cases hematoma evacuated 8%. One case septum septostomy 4% of colloid cyst with ETV and one case Aqueductoplasty 4% of upper surface AS lesion with ETV.

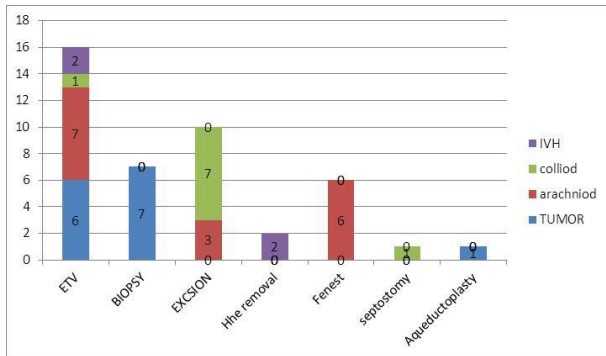


Figure (4): Number of cases according to procedure done in each pathology.

We carried out 20 cases right sided Kocher Burr Hole, four cases left sided burr hole (1t glioma case + metastatic case + two colloid cyst) and one case One case operated left Keen`s point.

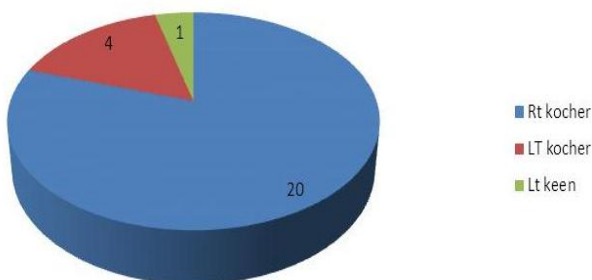


Figure (5): Number of cases according to site of burr hole.

Arachnoid cyst in nine cases 36% (five in 3rd, three in lateral and one in posterior fossa). Seven cases colloid cyst 28%. Seven cases of tumor 28% (two metastatic, one germ cell tumor, one teratoma,

one glioma, one choroid plexus papilloma and one normal biopsy). Two cases of IVH 8%.

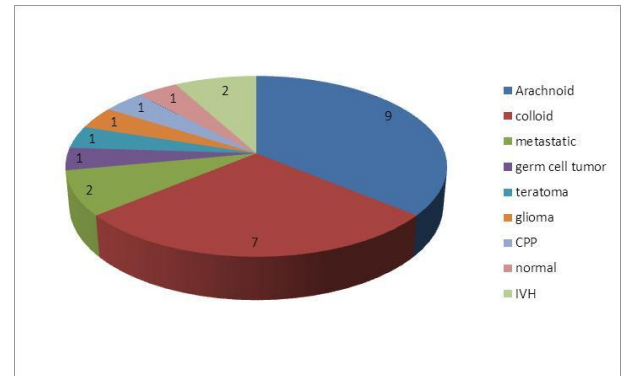


Figure (6): Number of cases according to pathology.

16 cases improved post operation; clinically and radiologically (64%). Three case needed VP shunt 12% two of them ETV fail due to cases less than 1 year and stoma were patent, other case need shunt the case DLC after surgery within 48 hours. Three cases were with same clinical as pre-operative 12%. One case presented with paresis 4%. Two cases operated microscopically case of teratoma and case of recurrent colloid cyst 8%.

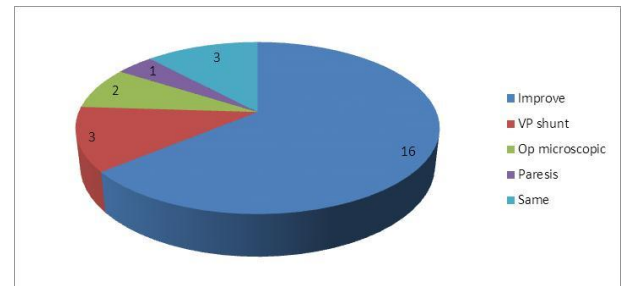


Figure (7): Number of cases according to outcome

DISCUSSION

Epidemiological Data

The medical literature indicates that 80% of patients with colloid cysts are between 30 and 60 years of age, in **Thiam**⁽¹⁵⁾ study within age group which matches the population in **our series** from (28-63 years).⁽¹⁰⁾

Yurtseven et al.⁽¹⁸⁾ underwent 18 cases of IV tumors age from (2-68) years, 15 males and 3 females.

Our series seven cases of IV tumors aged from (.5-78) years.

Clinical Data

The leading symptoms in patients with colloid cysts are headache, vomiting, gait

disturbance, syncopal attack and visual failure which matched with **our patients (all cases) symptoms**. The risk of sudden death occurred as a complication of colloid cysts was nil with our patients^(14, 16).

Our series of tumors with increase ICP all cases plus seizure in one case, hemiparesis, and CN palsy 3, 6. One case associated with scrotal swelling.

Therapeutic Aspects

In the past, microsurgical resection was deemed the gold standard in the treatment of patients with colloid cysts, with the use of either a transcortical-transventricular or transcallosal⁽¹⁰⁾ approach. The former approach has sometimes carried rather high operative morbidity and mortality rates.

The transcallosal approach that is favored nowadays saves the cortex but can endanger bridging veins, the sinus, and the pericallosal arteries and may also traumatize the fornix.

Gutierrez-Lara *et al.*⁽⁹⁾ first performed freehand puncture and aspiration of a colloid cyst in 1975, and **Bosch *et al.***⁽⁷⁾ performed the first stereotactic aspiration of a colloid cyst in 1978. The long term results after the use of this Technique also showed a high recurrence rate⁽¹¹⁾, mainly because of the remaining intact cyst wall after aspiration.

During the past decade, the endoscopic treatment of colloid cysts has gained increasing importance. In 1983, **Powell *et al.***⁽¹³⁾ reported the first successful endoscopic aspiration of a colloid cyst.

The development of refined instruments such as rigid endoscopes with smaller diameter and high resolution, special microinstruments, and in combination with neuronavigation has improved the endoscopic technique dramatically and has led to relatively low complication rates.

Whether some remnants may be left in place to reduce the surgical risk remains a matter of debate. **Pollock and Huston**⁽¹²⁾ emphasized that colloid cysts have a relatively low risk of considerable growth, which is a potential cause of obstructive hydrocephalus. This condition is known to be a major reason for the sudden death syndrome⁽⁸⁾.

Hellwig *et al.*⁽²¹⁾ this is another report on endoscopic treatment of colloid cysts of the third

ventricle reflecting the experience of a skilled group. The following points:

1. The use of neuronavigation techniques may be of great help.
2. At the end of the procedure, an intraoperative ventriculography should be performed.
3. Leave temporary ventricular drainage.

Margetis and Souweidane⁽²⁰⁾ underwent 67 colloid cases with three recurrences and two shunt dependent. In **our study** we operated seven cases colloid cyst and we had one recurrence case reoperated successfully with using of the microscopic technique with no any mortality or morbidity recorded and the time of surgery were from (90-135) minutes according to difficulty of cyst and experience of surgeon.

A major problem in the endoscopic management of lesions was hemostasis. Therefore, all procedures must be performed in concert with continuous irrigation. Fortunately, most bleeding stopped spontaneously after few minutes. In significant bleeds, hemostasis can be achieved by means of bipolar diathermy or dry field technique.

Two of our patients experienced major bleeds, but no procedure had to be abandoned for this reason.

Yurtseven *et al.*⁽¹⁸⁾ study they did 18 cases of IV tumors biopsy pathological diagnosis 100% and he able to treat non communicating hydrocephalus in nine cases by ETV and septostomy in three cases.

The location of tumors seven pineal, four hypothalamic, four lateral ventricles, two thalamic and one tectal. And tumor seeding to CSF in three cases which ended with irradiation therapy.

Two burr hole done in seven cases with pineal tumors.

The subsequent management radiotherapy, chemotherapy and observation for on case of tectal low grade small glioma.

Our study 16 cases ETV, one case aqueductoplasty and three cases were shunting 1st one was due to acute hydrocephalus post operatively in one major bleeding case, 2nd 6 months with CPP high failure rate of ETV and 3rd case was arachnoid cyst with 8 months case ETV was patent but failed and ended with shunt.

We failed in one case to diagnose and treat hydrocephalus. Two burr hole were done in three cases.

Cases with IVH **In our series:** we underwent two cases, age (56-59), both were males, Pre op. GCS (6-7), post-operative GCS same, Graeb score pre op. (8-10), post (4-6) and causes of IVH hypertension.

Some study recommended injection of urokinase like **Basaldella et al.** ⁽¹⁷⁾ to improve the outcome of cases which **not done in our study**.

Our series (nine cases of intraventricular arachnoid cyst (eight supratentorial in lateral and 3rd ventricle _ one infratentorial), ranged age was from (5- 67) years, only one case 67yr female LT thalamic cyst. Four cases males and five females.

Pradilla and Jallo ⁽¹⁹⁾ underwent nine cases with arachnoid cyst (eight supratentorial in suprasellar, lateral and 3rd ventricle) and one infratentorial. All cases in pediatric age group and the presentation matched with our study were increased ICP, seizure, hemiparesis, cognitive decline and visual problem.

All cases operated with cyst fenestration and ETV in cases with suprasellar cyst.

CONCLUSION

The advantages of the endoscopic approach are minimal dissection and brain retraction. Access to the target is rapid. The endoscopic view enables excellent visualization of the lesion and surrounding structures. With the aid of endoscopes with different angles of view and working through an operating sheath protects the surrounding brain.

We consider endoscopic the method of choice for removal of colloid cysts, arachnoid cysts and restore CSF pass way obstructed by lesions at same operation.

And have limited role in cases of intraventricular tumors because total excision are risky, so biopsy only done for these cases.

REFERENCES

- Schroeder HW, Wagner W, Tschiltshke W et al. (2001):** Frameless neuronavigation in intracranial endoscopic neurosurgery. *Journal of neurosurgery*, 94(1): 72-79.
- Souweidane MM (2005):** Endoscopic surgery for intraventricular brain tumors in patients without hydrocephalus. *Neurosurgery*, 57 (4):312-318.
- Gaab MR and Schroeder HW (1998):** Neuroendoscopic approach to intraventricular lesions. *J Neurosurg.*, 88(3): 496-505.
- Fukushima T (1978):** Endoscopic biopsy of intraventricular tumors with the use of a ventriculofiberscope. *Neurosurgery*, 2(2): 110-113.
- Oka K, Yamamoto M, Nagasaka S et al. (1994):** Endoneurosurgical treatment for hydrocephalus caused by intraventricular tumors. *Childs Nerv Syst.*, 10(3):162-6.
- Schild SE, Schiethauer BW, Schomberg PJ et al. (1993):** Pineal parenchymal tumors. *Clinical, Pathologica & Therapeutic aspect: cancer*, 72(3): 870-80.
- Bosch DA, Rähn T, Backlund EO (1978):** Treatment of colloid cysts of the third ventricle by stereotactic aspiration. *Surg Neurol.*, 9(1):15-18.
- Büttner A, Winkler PA, Eisenmenger W et al. (1997):** Colloid cysts of the third ventricle with fatal outcome: A report of two cases and review of literature. *Int J Legal Med.*, 110(5):260-266.
- Gutierrez-Lara F, Patino R, Hakim S (1975):** Treatment of tumors of the third ventricle: A new and simple technique. *Surg Neurol.*, 3(6):323-325.
- Mathiesen T, Grane P, Lindgren L et al. (1997):** Third ventricle colloid cysts: A consecutive 12-year series. *J Neurosurg.*, 86(1):5-12.
- Mathiesen T, Grane P, Lindquist C et al. (1993):** High recurrence rate following aspiration of colloid cysts in the third ventricle. *J Neurosurg.*, 78(5):748-752.
- Pollock BE and Huston J (1999):** Natural history of asymptomatic colloid cysts of the third ventricle. *J Neurosurg.*, 91(3):364-369.
- Powell MP, Torrens MJ, Thomson JL et al. (1983):** Isodense colloid cysts of the third ventricle: A diagnostic and therapeutic problem resolved by ventriculscopy. *Neurosurgery*, 13(3):234-237.

14. **Tamura Y, Uesugi T, Tucker A *et al.* (2013):** Hemorrhagic colloid cyst with intraventricular extension. *J Neurosurg.*, 118(3): 498-501.
15. **Sribnick EA, Dadashev VY, Miller BA *et al.* (2014):** Neuroendoscopic colloid cyst resection: a case cohort with follow-up and patient satisfaction. *World Neurosurg.*, 81 (3):584-593.
16. **Carrasco R, Pascual JM, Medina-López D *et al.* (2012):** Acute hemorrhage in a colloid cyst of the third ventricle: a rare cause of sudden deterioration. *Surg Neurol Int.*, 3(2):24.
17. **Basaldella L, Marton E, Fiorindi A *et al.* (2012):** External ventricular drainage alone versus endoscopic surgery for severe intraventricular hemorrhage: a comparative retrospective analysis on outcome and shunt dependency. *Neurosurg Focus*, 32(4): 4.
18. **Yurtseven T, Erşahin Y, Demirtaş E *et al.* (2003):** Neuroendoscopic biopsy for intraventricular tumors. *min-Minimally Invasive Neurosurgery*, 46(5): 293-299.
19. **Pradilla G and Jallo G (2007):** Arachnoid cysts: case series and review of the literature. *Neurosurgical Focus*, 22(2): 1-4.
20. **Margetis K and Souweidane MM (2013):** Endoscopic treatment of intraventricular cystic tumors. *World Neurosurgery*, 79(2): 19-21.
21. **Hellwig D, Bauer BL, Schulte M *et al.* (2003):** Neuroendoscopic treatment for colloid cysts of the third ventricle: the experience of a decade. *Neurosurgery*, 52(3): 525-533.