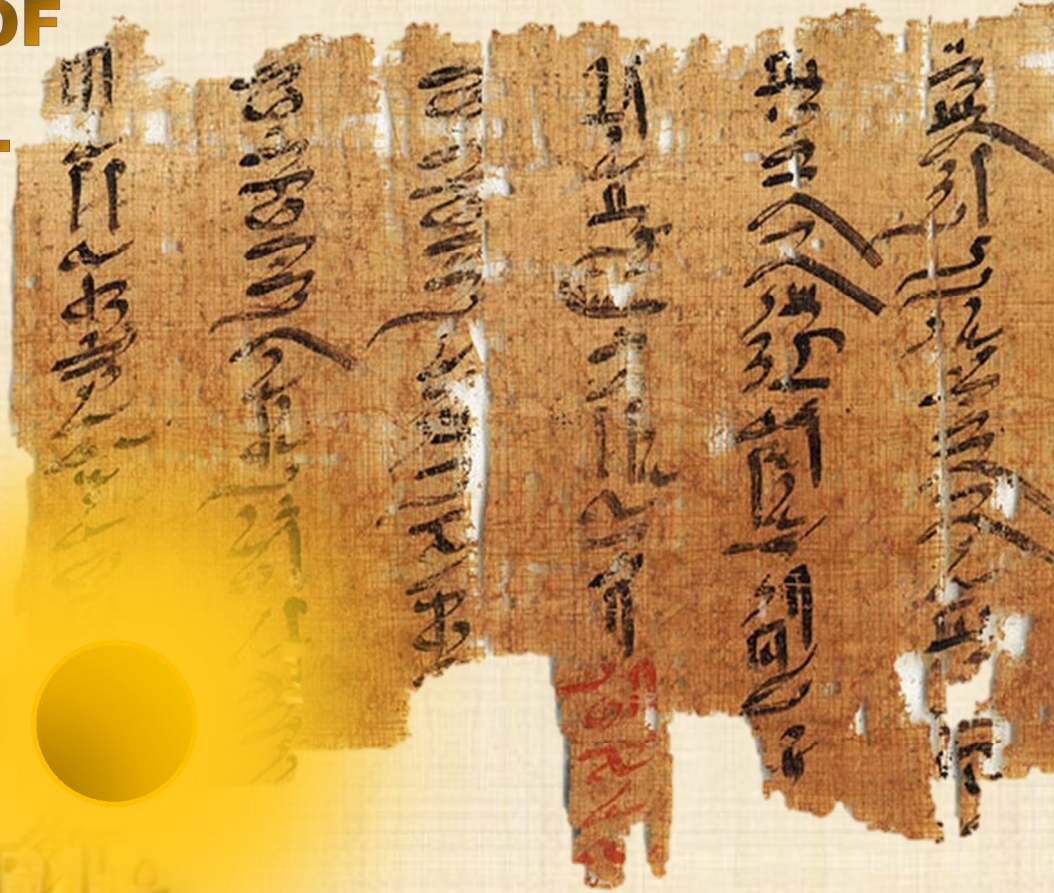


# IJMA

# INTERNATIONAL JOURNAL OF MEDICAL ARTS



VOLUME 2, ISSUE 4, AUTUMN 2020)



<http://ijma.journals.ekb.eg/>

**Print ISSN: 2636 - 4174**

**Online ISSN: 2682 - 3780**



Available online at Journal Website  
<https://ijma.journals.ekb.eg/>  
Main subject [Surgery [Orthopedics]]\*



## Original article

# Surgical Treatment of Lumbar Spinal Canal Stenosis by Laminectomy and Posterolateral Fusion

Mahmoud Gamal Mahmoud Ebrahim, Samir Ahmed Elshoura, Mohamed Abdallah Hassan

Department of Orthopedic Surgery, Damietta Faculty of Medicine, Al-Azhar University, Egypt.

### Corresponding author

Mahmoud Gamal Mahmoud Ebrahim  
Email: [mgs00360@gmail.com](mailto:mgs00360@gmail.com)

Received at: December 26, 2019; Revised at: August 17, 2020; Accepted at: August 19, 2020

DOI: [10.21608/ijma.2020.21393.1062](https://doi.org/10.21608/ijma.2020.21393.1062)

## ABSTRACT

**Background:** Lumbar spinal stenosis is a common spinal disease, which lead to neural compression leading to pain, limitation of individuals function and reduced the quality of life.

**Aim of the work:** To evaluate the results of surgical treatment of lumbar spinal canal stenosis [LCS] by laminectomy and instrumented posterolateral Fusion.

**Patients and Methods:** A prospective study had been conducted at Orthopedic Surgery Department [Al-Azhar University Hospital, Damietta] to evaluate the outcomes of treatment of lumbar canal stenosis by laminectomy and posterolateral fusion. This study included 15 patients, and the average follow up was 6 months from December 2018 to May 2019. Pain, clinical and radiological outcomes had been assessed. Preoperatively, all patients had been evaluated clinical and radiologically. In addition, lab investigations had been performed to assess the patient.

**Results:** The study included 15 patients [10 females and 5 males], their age ranged between 30-55 years [mean age 42.8 years]. The surgical outcome [according to Odom Criteria] revealed that, excellent outcome reported among 26.7%, and 40% had good outcome, fair outcome among 26.7% and poor outcome among 6.7%.

**Conclusion:** Laminectomy with instrumented posterolateral fusion is a good surgery to treat degenerative lumbar canal stenosis, with reasonable outcome.

**Keywords:** Degenerative; Lumbar; Spinal Canal; Stenosis; Laminectomy; Posterolateral Fusion.

This is an open access article registered under the Creative Commons, ShareAlike 4.0 International license [CC BY-SA 4.0] [<https://creativecommons.org/licenses/by-sa/4.0/legalcode>]

Please cite this article as: Ebrahim MGM, Elshoura SA, Hassan MA. Surgical Treatment of Lumbar Spinal Canal Stenosis by Laminectomy and Posterolateral Fusion. IJMA 2020; 2 [4]: 805-810. DOI: [10.21608/ijma.2020.21393.1062](https://doi.org/10.21608/ijma.2020.21393.1062)

\* Main subject and any subcategories have been classified according to research topic.



## INTRODUCTION

Lumbar spinal stenosis [LSS] is a common and disabling, well-recognized spinal disorder that generally occurs in the sixth decade of life, although it can occur in younger individuals. Degenerative lumbar stenosis including, hypertrophy/calcification of ligamentum flavum, intervertebral disc bulge, facet joint hypertrophy, cause neural compression in the vertebral canal, lateral recess, or intervertebral foramen, leading to pain, limitation of individuals function, and decreased quality of life<sup>[1]</sup>.

LCS can be classified according to anatomy [central, lateral or foraminal stenosis], and according to its cause [primary and secondary stenosis] Primary stenosis is caused by congenital narrowing of the spinal canal<sup>[2]</sup>.

Secondary stenosis can occur mostly from chronic degeneration, which leads to instability vertebral body. Other causes of secondary stenosis include rheumatoid diseases, osteomyelitis, tumors, trauma, and, in rare cases, Epidural lipomatosis [Cushing disease] or iatrogenic cortisone application<sup>[3]</sup>.

Decompression by laminectomy and instrumented spinal fusion is one option for the management of degenerative stenosis of the lumbar spine, which was resistant to conservative management<sup>[4]</sup>.

Lumbar laminectomy is considered necessary with this criterion; All other reasonable sources of pain have been excluded, radiological studies [X-Ray, CT or MRI] indicate nerve root compression that corresponds to the clinical findings of the specifically affected nerve root, Member has failed at least 6 weeks of conservative management, Daily activities was restricted by continuous pain radiating from the back down to the lower limb, Presence of neurological affection [e.g., positive straight leg raising test, sensory loss, reflex change, weakness] persist on examination and correspond to the specifically affected nerve root<sup>[5]</sup>.

Here, we presented our experience in management of spinal canal stenosis.

## AIM OF THE WORK

This study designed to evaluate the outcome of surgical treatment for lumbar spinal canal stenosis by laminectomy and posterolateral fusion.

## PATIENTS AND METHODS

This is a prospective study, which included 15 patients who mainly complained from low back pain with associated sciatica and claudication due to degenerative lumbar spinal canal stenosis.

All patients with degenerative lumbar canal stenosis, their age ranged between 30 and 55 years, from both sexes, were invited to participate in the current study. On the other hand, patients who had previous lumbar surgery, pathological spine conditions [e.g., tumors or infections] or out of the age range were excluded from the study.

The study protocol had been approved by the institutional research and ethics review board. In addition, we followed the ethical codes of Helsinki Declaration regarding research conduct principles.

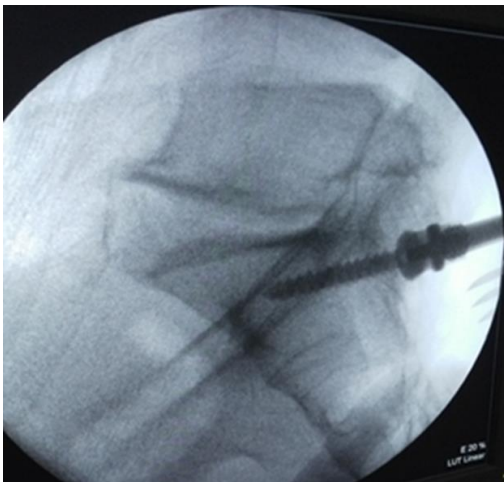
Preoperative evaluation consisted of inquiry about all medical history data; the characteristics of low back pain, radiculopathy and stenotic manifestations [e.g., neurogenic claudication, intermittent pain radiating to the lower limb, pain worsened with long standing, activity and lumbar extension, relieved by sitting, supine position, and lumbar flexion]. In addition, a detailed clinical examination [general and local examinations] and standard lab investigations had been performed. The radiological evaluation consisted of plain x-ray and magnetic resonance imaging [MRI].

### Surgical technique:

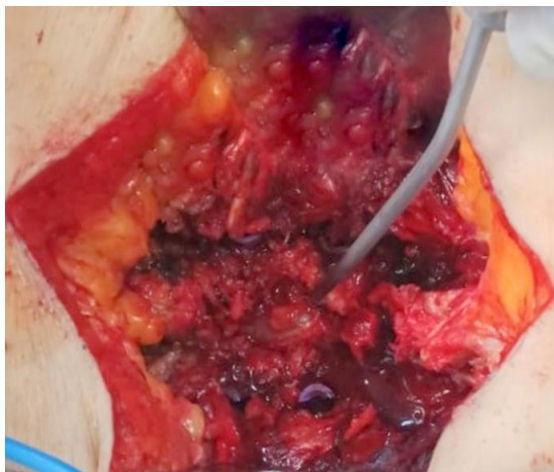The patient was placed in a prone position after general anesthesia, maintaining the lumbar lordosis by positioning on a padded spinal frame, and then posterior midline approach was used. The paraspinal muscles were elevated to expose the spine to the tips of the transverse processes, after reaching facets and transverse processes of targeted levels, the entry point for pedicular screw was identified [at the intersection of transverse process with facet], then the awl was inserted at its entry point which was confirmed by fluoroscopy to create pedicle tract in both cranial-caudal directions [parallel to the superior endplate] and mediolateral direction according to lumbar level [L1 has 5-degree medial convergence, L2:10 degree, L3: 15 degrees, L4:20 degree, L5:25 degrees]. This was followed by the insertion of the pedicular probe and confirmed also by fluoroscopy. Filler was inserted after removal of the pedicular probe to assess walls all around the hole to ensure

the adequate position of the screw in the pedicle. The tapping of the hole was done then the screw was inserted. Fluoroscopy was used to assess the final position of the screw<sup>[6]</sup> [figure 1].

The pedicular screws were inserted on both sides of the lumbar vertebrae with the application of rods and tightening of screws over the rods, and then laminectomy had been performed [figure 2]. Then the graft was finally applied at posterolateral gutters over decorticated facets joints and transverse processes.



**Figure [1]:** Final position of the pedicular screw by fluoroscopy



**Figure [2]:** Laminectomy

### Post-operative care and follow up:

All patients had been evaluated clinically at discharge and six months post-operative. The evaluation was according to **Odom's criteria**<sup>[7]</sup> for the evaluation of the outcome. The outcome is **excellent** if all preoperative symptoms relieved and abnormal finding improved. It is **good** if there was a minimum persistence of preoperative symptoms and

abnormal finding unchanged or slightly improved. It is **fair** if there was definite relief of some preoperative symptoms, others unchanged or slightly improved. Finally, it is **poor** if symptoms and signs unchanged or exacerbated.

The radiological outcome had been carried out by the evaluation of fusion after 6 months. Fusion was defined by bony trabecular bridging across the graft, no detectable motion on flexion/extension radiographs and no gaps at the fusion site.

Data analysis: The collected data, either quantitative or qualitative, had been coded and fed to computer software program [SPSS] version 16 [SPSS Inc., USA] and presented in mean±standard deviation for quantitative and frequency and percentages for qualitative data. Groups compared by one-way analysis of variance if quantitative and Chi square if qualitative. P value < 0.05 was considered significant.

## RESULTS

The current work included 15 patients [5 males and 10 females]. The mean age was 42.8±6.0 years [ranging between 30 and 55 years]. There were 7 housewives, 4 workers, 2 farmers, and 2 employees. The operated levels were: L3-4-5 in 6 patients, L4-5-S1 in 5 patients and L5-S1 in 4 patients.

**Clinical outcome:** At 6 months postoperatively and according to **Odom's criteria**<sup>[7]</sup>, the clinical outcome was excellent for 4 patients [26.7%], good for 6 patients [40.0%], fair for 4 patients [26.7%] and fair outcome had been reported only for one patient [6.7%] [Table 1].

The accepted results according to operative satisfaction [an umbrella term that included all categories except the "Poor" category] had been achieved in 93.3% of studied populations.

The postoperative complications reported in overall 3 patients [20.0%], two patients [13.3%] had postoperative wound infection, which had been treated by good antibiotic coverage with daily dressing [the infection had been resolved in both patients with conservative treatment]. In addition, one patient [with poor outcome; 6.6%] had postoperative residual radiculopathy [Figure 3].

Radiologically, fusion had been achieved in 11 patients [73.3%] after 6 months and in 4 patients [26.7%] fusion not completed.

In the current study, the clinical outcome was significantly associated with young age. In addition, it was associated with operative acceptance, less

complications, and higher radiological fusion [Table 2].

**Table [1]:** Clinical outcome [6 months postoperative] according to Odom's criteria.

	n.	%
Excellent	4	26.7
Good	6	40
Fair	4	26.7
Poor	1	6.7
Total	15	100

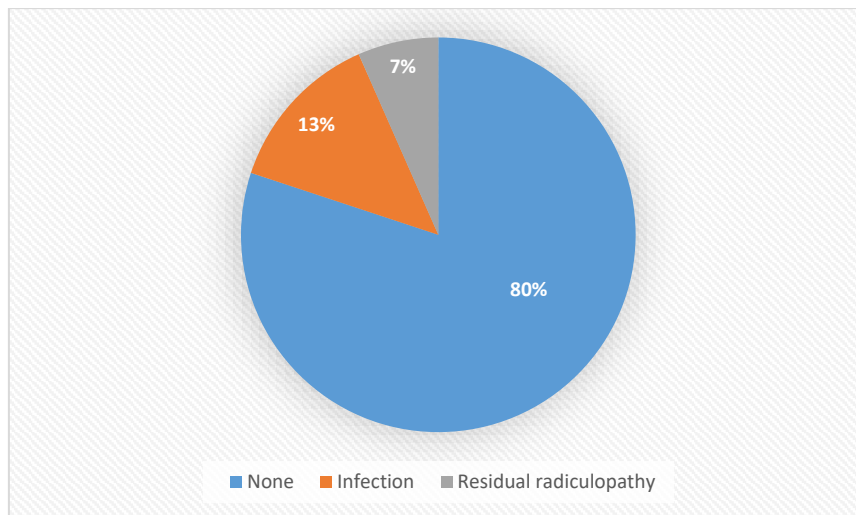


Figure [3]: Post-operative complications

**Table [2]:** Association between clinical outcome and other variables

Variables	Excellent	Good	Fair	Poor	Test	p
Age	37.00±5.29; 30-42	42.29±2.93; 39-48	47.67±2.52; 45-50	55.0	<b>8.82</b>	<b>0.003*</b>
Sex	Male	2[50.0%]	3[42.9%]	0[0.0%]	2.78	0.42
	Female	2[50.0%]	4[57.1%]	3[100.0%]		
Occupation	Housewife	1[25.0%]	3[42.9%]	3[100.0%]	9.98	0.35
	Worker	2[50.0%]	1[14.3%]	0[0.0%]		
	Farmer	1[25.0%]	1[14.3%]	0[0.0%]		
	Employee	0[0.0%]	2[28.6%]	0[0.0%]		
Level	L3-4-5	1[25.0%]	4[57.1%]	1[33.3%]	7.49	0.28
	L4-5-S1	3[75.0%]	1[14.3%]	1[33.3%]		
	L5-S1	0[0.0%]	2[28.6%]	1[33.3%]		
Operative Acceptance	Accepted	4[100.0%]	7[100.0%]	3[100.0%]	15.00	0.002*
	None	0[0.0%]	0[0.0%]	0[0.0%]		
Complications	None	4[100.0%]	7[100.0%]	1[33.3%]	24.16	<0.001*
	Infection	0[0.0%]	0[0.0%]	2[66.7%]		
	Resid.radiculopathy	0[0.0%]	0[0.0%]	0[0.0%]		
Radiological fusion	Achieved	4[100.0%]	7[100.0%]	0[0.0%]	15.00	0.002*
	None	0[0.0%]	0[0.0%]	3[100.0%]		

### DISCUSSION

In our study, 15 patients completed the study. There was great variability of the sample size in the previous studies. For example **Mori et al.**<sup>[7]</sup> included 32 patients, **Boissiere et al.**<sup>[8]</sup> recruited 39 patients,

**Hoy et al.**<sup>[9]</sup> had 48 participants, **Ghasemi**<sup>[10]</sup> had 65 patients, **Levin et al.**<sup>[11]</sup> had 118 participants, **Al Barbarawi et al.**<sup>[12]</sup> included 30 patients and finally, **Audit et al.**<sup>[13]</sup> completed their study with 17 cases.

The small sample size in the current study was an inevitable [due to high rate of refusal to participate

[11 eligible patients refused to participate] and strict selection criteria, when compared to previous studies]. This is evident for example from the wide variation in patient age distribution.

For example, [mean age in the current work was 42.8 years], while **Costa et al.**<sup>[14]</sup> reported a mean age of 77.8 years, **Schaeren et al.**<sup>[15]</sup> reported mean age of 66.53 years.

In **Mori et al.**<sup>[7]</sup>, mean age at the time of surgery was 68 years.

**Hoy et al.**<sup>[9]</sup> reported a mean age of 49.3 years and finally, **Audit et al.**<sup>[13]</sup> reported that, the mean age in their study was 54.2 years. The cause of diversity in ages belongs to two factors: first, the advanced anesthetic tools in spine surgeries. Second, is the selection of age over 75 years old as **Costa and coworkers**<sup>[14]</sup> who confined their study for patients over the age of 75 years.

In the current work, there was female sex predominance. This is comparable to **Mori et al.**<sup>[7]</sup>, who included 5 males and 27 females.

In addition, **Schaeren et al.**<sup>[15]</sup> recruited 6 males and 30 females, while **Costa et al.**<sup>[14]</sup> performed their study with 22 males and 31 females.

In the current work, the outcome evaluation had been conducted according to **Odom's criteria**<sup>[6]</sup>. The accepted results of Odom's criteria were seen in 93.3% of studied patients.

In **Son et al.**<sup>[16]</sup>, the results were excellent for 35.3%, good for 41.2%, and fair for 23.5% at the 6-month follow-up, and **Kang**<sup>[17]</sup> achieved 90.25% success rate.

In addition, **Silvers et al.**<sup>[18]</sup> compared two groups of patients with lumbar spinal canal stenosis and reported that patients undergoing laminectomy decompression and fusion had good outcomes than those treated with laminectomy decompression alone.

However, the mode of assessment on **Hoy et al.**<sup>[9]</sup>, **Jalalpour et al.**<sup>[19]</sup> and **Ghasemi**<sup>[10]</sup> was modified Oswestry Low Back Pain Disability Index [ODI]<sup>[20]</sup>.

In this study, lumbar stenosis treated with decompression by laminectomy had a good clinical outcome and the additional instrumentation add more benefit to the surgical outcome by improving post-operative back pain, reducing the use of

analgesics and improving quality of life. In addition, the radiological [Fusion rate] was 73.3% after 6 months of follow up.

**Hoy et al.**<sup>[9]</sup> reported fusion rate of 88% after follow up two years post-operative However fusion in this study is still inferior to the reported study which may be due to the larger number of patients in the reported study [48 patients] compared to this study [15 patients].

**Al Barbara et al.**<sup>[12]</sup>: reported fusion rate 90% after 7 years of follow up.

**Jabalpur et al.**<sup>[19]</sup> reported fusion rate 80% after two years follow up. **Levin et al.**<sup>[11]</sup> reported a fusion rate 84%.

In the current work, there were 3 complications among 15 patients [superficial infection [2 patients] and residual radiculopathy [1 patient]].

**Jabalpur et al.**<sup>[19]</sup> reported two dural lesions [that were sutured with no squealae]. The L5 nerve root was cut in one patient with no postoperative neurologic consequence.

**Ghasemi**<sup>[10]</sup> reported infection [2 cases], dural tear [3 cases] and nerve root injury [1 case].

The clinical outcome was associated with younger patient age. Thus, could be attributed to the fact that, those patients had the less degenerative changes and the healing power is usually excellent in younger patients.

A limiting step of the current study represented by small number of included patients [which was an inevitable due to high rate of refusal to participate [11 eligible patients refused to participate in the study], and definite selection criteria. However, the current work represented an initial clinical experience and adds to literature about the efficacy and safety of laminectomy and posterolateral fusion for treatment of lumbar spinal canal stenosis. Another one unique feature of the current study is the development of degenerative lumbar canal stenosis among relatively younger patients.

#### **Financial and Non-Financial Relationships and Activities of Interest**

Authors declare that, there was no competing interest.

The study funded completely by the authors themselves; and all of them exert equal contribution.



## REFERENCES

1. **Sengupta DK, Herkowitz HN.** Degenerative spondylolisthesis: review of current trends and controversies. *Spine [Phila Pa 1976]*. **2005** Mar 15;30[6 Suppl]: S71-81. doi: 10.1097/01.brs.0000155579.88537.8e.
2. **Rahimizadeh A, Soufiani H, Williamson WL, Rahimizadeh S, Amirzadeh M, Karimi M.** Intermittent penile erection in lumbar spinal stenosis: Report of four new cases and review. *Surg Neurol Int*. **2019** Oct 25; 10: 209. doi: 10.25259/SNI\_368\_2019.
3. **Kim K, Mendelis J, Cho W.** Spinal Epidural Lipomatosis: A Review of Pathogenesis, Characteristics, Clinical Presentation, and Management. *Global Spine J*. 2019 Sep;9[6]:658-665. doi: 10.1177/2192568218793617.
4. **Abdu WA, Sacks OA, Tosteson ANA, Zhao W, Tosteson TD, Morgan TS, Pearson A, Weinstein JN, Lurie JD.** Long-Term Results of Surgery Compared with Nonoperative Treatment for Lumbar Degenerative Spondylolisthesis in the Spine Patient Outcomes Research Trial [SPORT]. *Spine [Phila Pa 1976]*. **2018**; 43 [23]: 1619-1630. doi: 10.1097/BRS.0000000000002682.
5. **Caralopoulos IN, Bui CJ.** Minimally invasive laminectomy in spondylolisthetic lumbar stenosis. *Ochsner J*. **2014** Spring; 14[1]:38-43. PMID: 24688331.
6. **Broekema AEH, Molenberg R, Kuijlen JMA, Groen RJM, Reneman MF, Soer R.** The Odom Criteria: Validated at Last: A Clinimetric Evaluation in Cervical Spine Surgery. *J Bone Joint Surg Am*. **2019** Jul 17;101 [14]:1301-1308. doi: 10.2106/JBJS.18.00370.
7. **Mori K, Nishizawa K, Nakamura A, Imai S.** Short-Term Clinical Result of Cortical Bone Trajectory Technique for the Treatment of Degenerative Lumbar Spondylolisthesis with More than 1-Year Follow-Up. *Asian Spine J*. **2016** Apr;10[2]:238-44. doi: 10.4184/asj.2016.10.2.238.
8. **Boissiere L, Perrin G, Rigal J, Michel F, Barrey C.** Lumbar-sacral fusion by a combined approach using interbody PEEK cage and posterior pedicle-screw fixation: clinical and radiological results from a prospective study. *Orthop Traumatol Surg Res*. 2013 Dec;99[8]:945-51. doi: 10.1016/j.otsr.2013.09.003.
9. **Høy K, Bünger C, Niederman B, Helmig P, Hansen ES, Li H, Andersen T.** Transforaminal lumbar interbody fusion [TLIF] versus posterolateral instrumented fusion [PLF] in degenerative lumbar disorders: a randomized clinical trial with 2-year follow-up. *Eur Spine J*. **2013** Sep; 22 [9]:2022-9. doi: 10.1007/s00586-013-2760-2.
10. **Ghasemi AA.** Transforaminal lumbar interbody fusion versus instrumented posterolateral fusion In degenerative spondylolisthesis: An attempt to evaluate the superiority of one method over the other. *Clin Neurol Neurosurg*. **2016** Nov;150:1-5. doi: 10.1016/j.clineuro.2016.08.017.
11. **Levin JM, Tanenbaum JE, Steinmetz MP, Mroz TE, Overley SC.** Posterolateral fusion [PLF] versus transforaminal lumbar interbody fusion [TLIF] for spondylolisthesis: a systematic review and meta-analysis. *Spine J*. **2018** Jun;18[6]:1088-1098. doi: 10.1016/j.spinee.2018.01.028.
12. **Al Barbarawi MM, Audat ZM, Allouh MZ.** Analytical comparison study of the clinical and radiological outcome of spine fixation using posterolateral, posterior lumbar interbody and transforaminal lumbar interbody spinal fixation techniques to treat lumbar spine degenerative disc disease. *Scoliosis*. **2015** May 27;10:17. doi: 10.1186/s13013-015-0040-0.
13. **Audat Z, Moutasem O, Yousef K, Mohammad B.** Comparison of clinical and radiological results of posterolateral fusion, posterior lumbar interbody fusion and transforaminal lumbar interbody fusion techniques in the treatment of degenerative lumbar spine. *Singapore Med J*. **2012** Mar; 53[3]:183-7. PMID: 22434292.
14. **Costa F, Ortolina A, Tomei M, Cardia A, Zekay E, Fornari M.** Instrumented fusion surgery in elderly patients [over 75 years old]: clinical and radiological results in a series of 53 patients. *Eur Spine J*. **2013** Nov;22 Suppl 6[Suppl 6]:S910-3. doi: 10.1007/s00586-013-3021-0.
15. **Schaeren S, Broger I, Jeanneret B.** Minimum four-year follow-up of spinal stenosis with degenerative spondylolisthesis treated with decompression and dynamic stabilization. *Spine [Phila Pa 1976]*. **2008** Aug 15; 33[18]: E636-42. doi: 10.1097/BRS.0b013e 31817 d2435.
16. **Son S, Lee SG, Park CW, Kim WK.** Minimally invasive multilevel percutaneous pedicle screw fixation for lumbar spinal diseases. *Korean J Spine*. **2012** Dec;9[4]:352-7. doi: 10.14245/kjs.2012.9.4.352.
17. **Kang H:** Clinical outcomes and cost analysis for unilateral versus bilateral pedicle screw fixation in two levels during minimally invasive transforaminal lumbar interbody fusion [MIS-TLIF]: A comparative analysis. *Int J Clin Exp Med*. **2016**; 9 [6]: 11566-11573.
18. **Silvers HR, Lewis PJ, Asch HL.** Decompressive lumbar laminectomy for spinal stenosis. *J Neurosurg*. **1993** May;78[5]:695-701. doi: 10.3171/jns.1993.78.5.0695.
19. **Jalalpour K, Neumann P, Johansson C, Hedlund R.** A Randomized Controlled Trial Comparing Transforaminal Lumbar Interbody Fusion and Uninstrumented Posterolateral Fusion in the Degenerative Lumbar Spine. *Global Spine J*. **2015** Aug;5[4]:322-8. doi: 10.1055/s-0035-1549033.
20. **Smeets R, Köke A, Lin CW, Ferreira M, Demoulin C.** Measures of function in low back pain/disorders: Low Back Pain Rating Scale [LBPRS], Oswestry Disability Index [ODI], Progressive Isoinertial Lifting Evaluation [PILE], Quebec Back Pain Disability Scale [QBPDS], and Roland-Morris Disability Questionnaire [RDQ]. *Arthritis Care Res [Hoboken]*. **2011** Nov ;63 Suppl 11:S158-73. doi: 10.1002/acr.20542.

# International Journal

<https://ijma.journals.ekb.eg/>

Print ISSN: 2636-4174

Online ISSN: 2682-3780

# of Medical Arts