

TWO DIFFERENT TECHNIQUES FOR ALVEOLAR RIDGE EXPANSION

Ahmed Elmetwally Abdelhamid¹, Walid Ahmed Ghanem², Naglaa Lotfy Dabees³

DOI: 10.21608/dsu.2020.16421.1008

Manuscript ID: DSU-1908-1008

KEYWORDS

Implant, maxillary ridge expansion, osteotome, screwexpander.

ABSTRACT

Aim: To evaluate the efficacy of two different techniques for maxillary alveolar ridge expansion, the osteotome and screwexpander. **Patients and methods:** This study was carried out on 16 healthy male patients received 16 implants. Average age 40 years. Each patient has partial edentulous maxilla with bone width not less than 4 mm and height not less than 10 mm. The patients were divided into two equal groups. In group I, implant site was prepared by osteotomes of increasing diameter to reach the planned osteotomy width, group II, implant site was prepared by expansion screws of increasing diameter to reach the planned osteotomy width. Clinical evaluation was done 24 hours postoperatively for edema, wound dehiscence, pain and signs of infection and regular checkups were done weekly during the first month. Radiographic evaluation using CBCT was done after 3 and 9 months postoperatively to measure bone density around inserted implants and vertical bone loss. Implant stability was measured by using Osstell ISQ device for all the implants of the two groups after 6 months (before loading) and after 9 months. **Results:** Radiographic evaluation showed significant higher bone density and lesser vertical bone loss around the inserted implants in group I than in group II after 3 and 9 months. Also, implant stability measurements at six and nine months showed highly significant values in group I more than in group II. **Conclusion:** Maxillary alveolar ridge expansion with osteotome is superior to screwexpander regarding to bone density and osseointegration.

INTRODUCTION

Dental implant is one of the most successful treatment modalities that has a successful rate exceeds ninety percent. Despite of this high successful rate, dental implant designs, surgical techniques and loading protocols have improved a lot during past decades to permit faster osseointegration and higher bone maintenance.⁽¹⁾

Alveolar bone resorption after tooth extraction or avulsion occurs more rapidly during the first years. Extraction of anterior maxillary teeth usually results in a progressive loss of bone mainly from the labial side.² The loss is estimated to be 40-60% throughout the first 3 years and decreases to 0.25-0.5% gross annual loss thereafter. Also, the presence of bone fenestration or dehiscence during extraction could increase the post-extraction alveolar re-modeling, leading to an even more severe buccal concavity after healing. The reason for resorption of alveolar

• E-mail address:
walid_dent@yahoo.com

1. BDS, Mansoura University, Master in Oral and Maxillofacial surgery, Faculty of Dentistry, Suez Canal University.
2. Professor of Oral and Maxillofacial Surgery, Faculty of Dentistry, Suez Canal University
3. Professor of Radiodiagnosis, Faculty of Medicine, Tanta University

bone has been thought to be due to disuse atrophy, localized inflammation, decreased blood supply or prosthesis pressure.^(3,4)

This resorption process creates a shorter and narrower ridge; moreover the net result of this resorptive pattern is the relocation of the alveolar ridge to a more palatal/lingual position, making the dental implant a difficult process.⁽⁵⁾ In these cases, lateral augmentation of the alveolar ridge is required before implant insertion. Many techniques have been suggested for ridge widening, including guided bone regeneration (GBR), autogenous bone graft, alveolar ridge splitting, alveolar ridge expansion and combinations of these techniques.⁽⁶⁾

GBR is a procedure that utilizes a barrier membrane with or without bone grafts or/and bone substitutes.⁽⁷⁾ The main limitations of GBR are the risk of membrane exposure followed by infection, an unpredictable rate of bone resorption after the reconstructive or regenerative procedure(s) and placement of implants and additional cost.⁽⁸⁾ Autogenous bone graft is another treatment modality to increase the alveolar ridge width, but the need to harvest bone from extra-oral or intraoral sites which might lead to increased morbidity is a main disadvantage of this method.⁽⁹⁾ Alveolar ridge splitting is a sensitive technique with a high risk of buccal bone plate fracture and separation during procedure.⁽¹⁰⁾

Alveolar ridge expansion using just initial drilling then osteotomes or screwexpanders of gradually increasing diameter is another technique that expands the ridge by controlled expansion and condensation in a stepwise manner with simultaneous implant placement.⁽¹¹⁾ The objective of this approach is to preserve the existing soft bone through pushing the buccal bony plates of the alveolar ridge laterally with a little trauma while simultaneously producing an accurately shaped osteotomy. This approach takes the benefit of the softer bone quality found in maxillary type III and type IV bone via

relocating the alveolar bone rather than losing the treasured bone by drilling.⁽¹²⁾

The aim of this study was to evaluate the efficacy of two different techniques for maxillary alveolar ridge expansion, the osteotome and screwexpander.

PATIENTS AND METHODS

This study was carried out on sixteen male patients received sixteen dental implants. The patients were divided into two equal groups. In group I, implant site was prepared by osteotomes, while in group II, implant site was prepared by screwexpanders.

The patients were selected from the outpatient clinic, Oral and Maxillofacial Surgery Department, Faculty of Dentistry, Suez Canal University. The inclusion criteria were edentulous maxilla with bone width not less than 4 mm and height not less than 10 mm, good oral hygiene condition, healthy patients with no medical history of any systemic disease that would contraindicate implant surgery or might complicate the healing process, cooperative patients who agreed to follow oral hygiene protocol throughout the study and coming at fixed intervals for follow up. The exclusion criteria were patients with periapical pathology related to future planned implant site or neighboring teeth, patients have bad oral hygiene or smoking habits, patients with parafunctional habits such as bruxism and clenching, patient with abnormal occlusal relationship that may complicate the future restoration, patients with uncontrolled systemic disease as liver cirrhosis, diabetes mellitus and renal failure. Severe atrophic maxilla with insufficient height and/or width.

All the patients were given the necessary information about the procedure and they gave their approval to participate in a written informed consent. This study was done according to the Declaration of Helsinki.

Preoperative phase:

Preoperative CBCT was taken for each patient to evaluate the presence of sufficient bone width and height. All patients were instructed to administer oral rinse Orovex (Chlorhexidine Gluconate 0.1% manufactured by Macro Group Pharmaceuticals) three times per day, one week before surgery and oral prophylactic antibiotic Augmentin 1gm tablet. (Amoxicillin 875mg. and Clavulanic acid 125mg. manufactured by Glaxowellcome) twice daily, one day prior to the surgery.

Operative phase:

Each patient was asked to take oral antibiotic (Augmentin 1gm.) one hour prior to the surgery. All the surgical procedures were performed under local anesthesia using Ubistesin Forte (Articane HCL 4% manufactured by 3M). A mid-crestal incision was made and enveloped flap was reflected exposing the alveolar bone at the site of implant placement. The pilot hole was drilled using a twist drill of 1.8 mm diameter to the planed depth.

For group one, implant site was prepared by osteotomes of increasing diameter to reach the planned osteotomy width. The first osteotome which has diameter gradually increasing from 2 mm to 2.7mm was inserted into the osteotomy site and manually rotated with gentle pressure apically so that the osteotome proceeded into the bone. At each 2-3 mm depth a pause of 30 to 60 seconds was allowed. Once the final length was reached a pause of 1 to 2 minutes was allowed before removing the osteotome and inserting the next one.

For group two, implant site was prepared by screwexpanders of increasing diameter to reach the planned osteotomy width. The first screwexpander which has diameter gradually increasing from

1.8mm to 2.6mm was inserted into the osteotomy site and proceeded into the bone with finger rotation until resistance was reached, then continued by the use of wrench. At each one turn a pause of 30 to 60 seconds was allowed. Once the final length was reached a pause of 1 to 2 minutes was allowed before removing the screw and inserting of the next one.

Implant was inserted (Dentium Superline was used, manufactured by Dentium, Korea) and the incision was sutured using an interrupted matters suture.

Postoperative care and follow up:

Oral regimen of Augmentin 1gm/12hours was continued for five days postoperatively and Orovex mouth wash was described 3 times per day after the first day. Patients were viewed 24 hours after surgery to evaluate the presence of postoperative complications as delayed bleeding, redness, edema, swelling at surgical site, wound dehiscence, pain or implant looseness. After one week all stitches were removed. Regular follow ups were done weekly during the first month then after 3, 6 and 9 months postoperatively.

CBCTs were done on intervals of three and nine months postoperatively to measure bone density around inserted implants and mean vertical bone loss mesially and distally.

In order to measure vertical bone loss using CBCT software, a line was drawn from the highest point adjacent to the implant on the alveolar crest (point A) perpendicular to the implant axis, then the lowest point located at the bone loss depth was determined as point B. A third point (point C) was determined by drawing a perpendicular line from point B to the above mentioned line. The distance

between B and C points was representative of the vertical bone loss.

Implant stability was measured for all the implants of the two groups after 6 and 9 months postoperatively by using Osstell ISQ device. All implants with implant stability values equal to or more than 65 ISQ were loaded after 6 months postoperatively using temporary cement, and final prosthesis cementation was done after 9 months postoperatively. All gathered data for the two investigated groups were statistically analyzed by using t.test.

The hypothesis: There is different effect between two methods of maxillary alveolar ridge expansion, osteotome and screwexpander.

The null hypothesis: No difference.

RESULTS

There were no complications during the surgical procedures except for one case in group I where buccal plate fractured (green stick) but primary implant stability was achieved, enabling successful completion of the procedure combined with guided bone regeneration. On the first day postoperatively no bleeding, erythema or wound dehiscence were observed, mild pain or discomfort and mild edema were observed in four patients of group II and two patients of group I, but pain and edema were resolved after 48 hours by following medication regimen. All the patients continued the follow up period without any signs of infection.

After 3 months the mean and standard deviation measures of bone density around the inserted implants in group I showed significant increase more than group II where the mean and standard deviation were (1726.5±177.73) in group I and (1458.0±107.29) in group II and p. value =0.001.

Also after 9 months, the mean and standard deviation measures of the bone density around the inserted implants in group I showed significant increase more than group II where the mean and standard deviation were (1868.63 ± 236.42) in group I and (1648.25±141.29) in group II and p. value =0.040. (Tab 1).

For vertical bone loss, after 3 months the mean and standard deviation measures of the average vertical bone loss of the inserted implants showed significantly lesser amount of vertical bone loss in group I than in group II where the mean and standard deviation were (0.73±0.10 mm) in group I and (0.87±0.11 mm) in group II and p. value=0.023. Also after 9 months, the mean and standard deviation measures of the average vertical bone loss of the inserted implants showed significantly lesser amount of vertical bone loss in group I than in group II where the mean and standard deviation were (0.85 ±0.16 mm) in group I and (1.09±0.16 mm) in group II and p.value=0.008.(Tab1)

Implant stability measurements were done for all cases after six months (at loading) and nine months (post-loading) and measures were analyzed using t.test. After 6 months, the mean and standard deviation measures of the implant stability quotient of the inserted implants in group I showed significant increase more than group II where the mean and standard deviation were (71.25±2.12) in group I and (67.75±2.12) in group II and p. value =0.005. Also after 9 months, the mean and standard deviation measures of the implant stability quotient of the inserted implants in group I showed significant increase more than group II where the mean and standard deviation were (75.13±2.99) in group I and (71.25±2.12) in group II and p. value =0.010. (Table 1) (Figure 1,2).

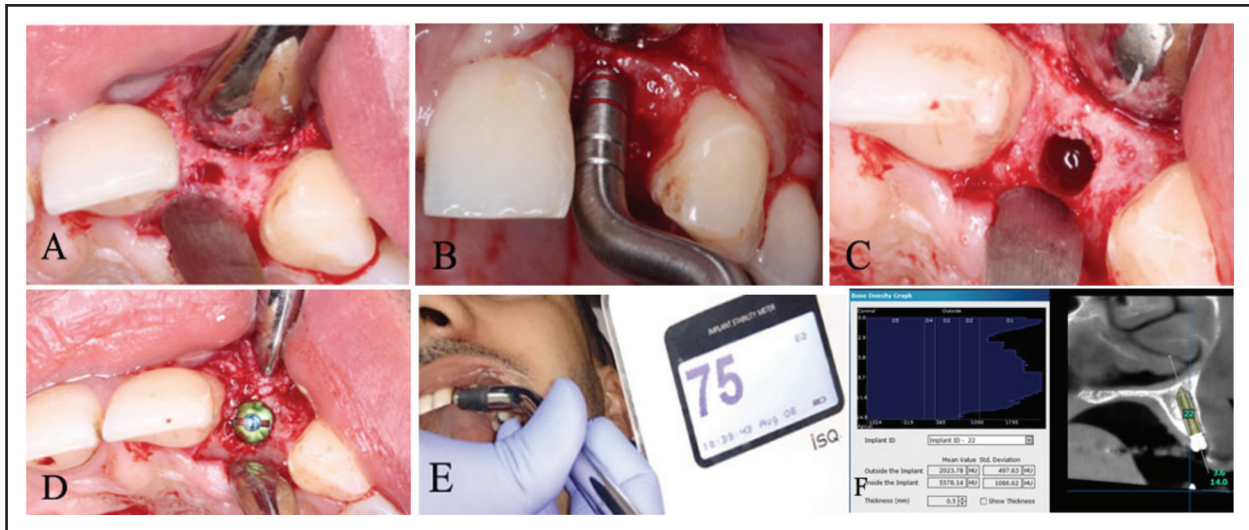


Fig. (1) Showing: (A) alveolar ridge of missing maxillary left lateral incisor after initial drilling by pilot drill 1.8mm. (B) ridge expansion by using osteotome.(C) alveolar ridge bone after expansion.(D) implant after insertion into the expanded area and sealed with cover screw.(E) measurement of implant stability by using Osstell device.(F) bone density reading around inserted implant after nine months.

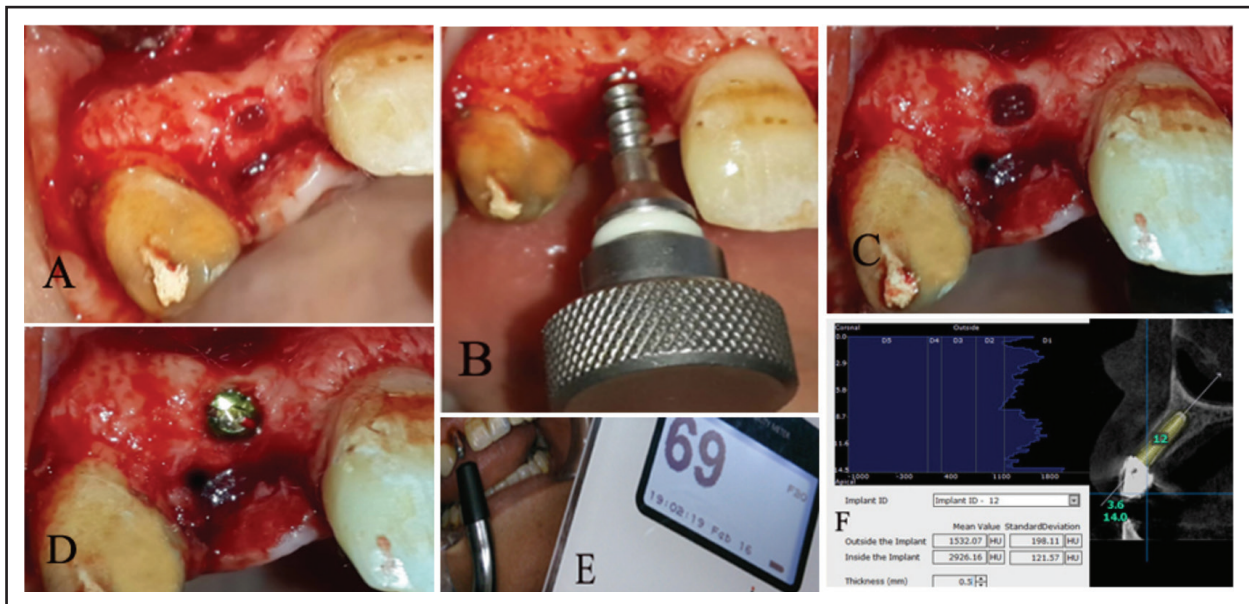


Fig. (2) Showing: (A) alveolar ridge of missing maxillary right lateral incisor after initial drilling by pilot drill 1.8mm. (B) ridge expansion by using screw expander. (C) alveolar ridge bone after expansion.(D) implant after insertion into the expanded area and sealed with cover screw. (E) measurement of implant stability by using Osstell device.(F) bone density reading around inserted implant after nine months.

Table (1) Showing bone density, vertical bone loss and ISQ measures for group I and group II during study intervals.

			Group I	Group II	t. test	p. value
Bone density	After 3 months	Range	1383 – 1929	1300 – 1612	13.381	0.001*
		Mean ± SD	1726.5 ± 177.73	1458.0 ± 107.29		
	After 9 months	Range	1396 – 2156	1503 – 1933	5.119	0.040*
		Mean ± SD	1868.63 ± 236.42	1648.25 ± 141.29		
Vertical bone loss	After 3 months	Range	0.63 – 0.94 mm	0.77 – 1.10 mm	6.550	0.023*
		Mean ± SD	0.73 ± 0.10 mm	0.87 ± 0.11 mm		
	After 9 months	Range	0.71 – 1.20 mm	0.93 – 1.41 mm	9.579	0.008*
		Mean ± SD	0.85 ± 0.16 mm	1.09 ± 0.16 mm		
Implant stability	After 6 months	Range	68 – 74	65 – 71	10.889	0.005*
		Mean ± SD	71.25 ± 2.12	67.75 ± 2.12		
	After 9 months	Range	71 – 79	69 – 75	8.910	0.010*
		Mean ± SD	75.13 ± 2.99	71.25 ± 2.12		

DISCUSSION

Alveolar ridge less than 5 mm in width requires an augmentation procedure to receive endosseous implant with healthy peri-implant bone of 1.5-2mm.⁽¹³⁾ Bone expansion was developed by **Tatum**⁽¹⁴⁾ and reintroduced by **Bruschi and Scipioni**⁽¹⁵⁾. Bone expansion technique using osteotomes or finger screwexpanders, was introduced to increase the bone width by exerting lateral compression which in turn increases bone density and primary stability of dental implant.

In the present study, the effect of using osteotomes and screwexpanders for maxillary ridge expansion on bone density, implant stability and crestal bone loss was evaluated.

Fanuscu et al⁽¹⁶⁾ published a study on the effect of surgical technique on peri-implant bone in which comparison was made between bone expansion

technique and conventional drilling technique, and showed that implants inserted using bone expansion technique have higher peri-implant bone density. Also, **Mario et al**⁽¹⁷⁾ conducted a study on teeth replacement in the esthetic zone with ridge expansion osteotomy that showed via CT scan a significant increase in bone density using osteotome technique. This is agrees with our study results in which the mean measures of the bone density around the inserted implants using osteotomes showed via CBCT a significant increase after three and nine months.

Azfar and Mark⁽¹²⁾ conducted a study on using finger screwexpanders for placement of endosseous dental implants and concluded that this technique increases bone density and leads to an enhanced osseointegration of dental implants. This is similar to our study results that also showed a significant increase in bone density using finger screwexpanders.

Latheef et al⁽¹⁸⁾ published a study on the effect of ridge expansion of narrow partially edentulous ridges on implant stability using osteotomes. They found that implant stability gradually increased over the study period on all the aspects. **Kreissel et al**⁽¹⁹⁾ in a similar study evaluating the implant stability in expanded ridges also concluded that the application of the screw-shaped spreaders significantly increased ISQ values over the study period. This is in agreement with our study results in which implant stability values increased over the study period for both groups, but higher values were seen in group I.

In disagreement with this study, **Padmanabhan and Gupta**⁽²⁰⁾, they conducted a study to compare implant stability among the implants placed with osteotome technique and using conventional procedures. They reported the significant higher stability of implants placed using conventional drilling technique than with osteotome technique on the day of surgery. However, after six months, no statistically significant difference was found in stability between both groups.

Latheef et al⁽¹⁸⁾ conducted a study to evaluate the effect of ridge expansion using osteotome on crestal bone loss and found that the mean bone loss in all cases was below 0.8 mm. **Javier et al**⁽²¹⁾ published a study on ridge expansion using screwexpanders and found that bone loss was higher and short term survival rates of implants were slightly lower than those reported by the recent meta-analysis addressing expansion with Summers osteotomes. These results are in agreement with the present study results, crestal bone loss was evaluated three months (pre-loading) and nine months (post-loading) postoperatively using CBCT, where group II showed slightly higher crestal bone loss than group I. This might have attributed to bone injury caused by sharp threads of the screw expanders.

Ridge expansion using osteotomes requires strict control on the direction and amount of force exerted

during insertion and removal to avoid buccal bone plate fracture. During the present study, there were no complications during the surgical procedures except for one case of the osteotome group where buccal plate was fractured and bone graft and membrane were placed, the fracture might have attributed to uncontrolled excessive force during osteotome insertion. **Roni et al**⁽²²⁾ reported buccal plate fracture at six sites (4.9%) during his study. Also, **Latheef et al**⁽¹⁸⁾ reported two cases of buccal bone fracture during his study and attributed that to the technique of osteotome removal which was more buccal.

CONCLUSION

Maxillary alveolar ridge expansion with simultaneous implant placement can be done successfully using either osteotomes or finger screwexpanders, but osteotomes are superior to finger screwexpanders regarding bone density and osseointegration.

REFERENCE

1. Morinaga K., Kindo H., Sato A., Watazu A., Matsuura M.: Chronological changes in the ultrastructure of titanium-bone interfaces: analysis by light microscope, transmission electron microscopy, and micro-computed tomography. *Clin Implant Dent Relat Res.* 2009; 11:59-68.
2. Cawood JJ., Howell RA.: A classification of the edentulous jaws. *Int J Oral Maxillofac Surg.* 1988; 17:232-236.
3. Ashman A., Rosenlicht J.: Ridge preservation: addressing a major problem in dentistry. *Dent Today.* 1993; 12:80-84.
4. Ashman A.: Postextraction ridge preservation using synthetic alloplast. *Implant Dent.* 2000; 9:168-176.
5. Pinho MN., Roriz VL., Novaes AJ., Taba M., Grisi F., de Souza S.: Titanium membranes in prevention of alveolar collapse after tooth extraction. *Implant Dent.* 2006; 15: 53-61.
6. Ioannis P., Georgios V., Sotirios B., Lampros Z.: Ridge splitting technique for horizontal augmentation and immediate implant placement. *Balk J Dent Med.* 2014; 18:41-47.

7. Jie L., David Gk.: Mechanisms of guided bone regeneration; a review. *The Open Dent J.* 2014; 8:56-65.
8. Chiapasco M., Abati S., Romeo E., Vogel G.: Clinical outcome of autogenous bone blocks or guided bone regeneration with e-PTFE membranes for the reconstruction of narrow edentulous ridges. *Clin Oral Implants Res.* 1999; 10:278-288.
9. Dragoo MR., Sullivan HC.: A clinical and histological evaluation of autogenous iliac bone grafts in humans on external root resorption. *J Periodontol.* 1973; 44: 614-625.
10. Federica D., Giulio C., Andrea S.: Localised maxillary ridge expansion with simultaneous implant placement: a case series. *British J Oral Maxillofac.* 2009; 47:535-540.
11. Young-Kyun K., Su-Gwan K.: Horizontal ridge expansion and implant placement using screws: a report of two cases. *J Korean Assoc Oral Maxillofac Surg.* 2014; 40:233-239.
12. Azfar AS., Mark S.: Lateral Bone Condensing and Expansion for Placement of Endosseous Dental Implants: A New Technique. *J Oral Implantology.* 2006; 32:87-94.
13. Sujata G., Shankar I.: Bone Manipulation Techniques. *Int J Clin Implant Dent.* 2009; 1:22-31.
14. Tatum H.: Maxillary and sinus implant reconstructions. *Dent Clin North Am.* 1986; 30:207-229.
15. Scipioni A., Bruschi GB., Calesini G.: The edentulous ridge expansion technique: a five-year study. *Int J Periodontics Restorative Dent.* 1994; 14:451-459.
16. Fanuscu MI., Chang TL., Akca K.: Effect of surgical techniques on primary implant stability and peri-implant bone. *J Oral Maxillofac Surg.* 2007;65:2487-2491.
17. Mario S., Luigi G., Alfredo D., Gianpaolo P.: Single-tooth replacement in the esthetic zone with ridge expansion osteotomy: a clinical report and radiographic results. *J of Oral Implant.* 2008;35:219-222.
18. Latheef S., Sridhar M., Vivekanand S., Srinivas P., Naga N., Krishna P., Susmita A., Rahul T.: The effect of ridge expansion on implant stability in narrow partially edentulous ridges – a preliminary clinical study. *J Clin Diagnost Resear.* 2016; 10:28-33.
19. Kreissel P., Kölpin F., Graef F., Wichmann M., Karl M.: Effect of rotating osteotomes on primary implant Stability-an in vitro investigation. *J Oral Implantol.* 2013; 39:52- 57.
20. Padmanabhan TV., Gupta RK.: Comparison of crestal bone loss and implant stability among the implants placed with conventional procedures and using osteotome technique: a clinical study. *J Oral Implantol.* 2010;26:475-484.
21. Javier M., Lopez-Valverde A., Diego RG.: A retrospective study of the risk factors for ridge expansion with self-tapping osteotomes in dental implant surgery. *Int J Oral Maxillofac Impl.* 2012; 27:203-210.
22. Roni K., Nissan J., Tal H.: Combined osteotome-induced ridge expansion and guided bone regeneration simultaneous with implant placement: a biometric study. *Clin Impl Dent Relat Res.* 2014; 16:691-704.