

COMPARATIVE STUDY BETWEEN TWO DIFFERENT BONE GRAFTS FOR ENHANCING OSTEO-INTEGRATION OF IMMEDIATE IMPLANT

Amr Abdelnasser Kamel¹ Walid Ahmed Ghanem², AbdelBadee Abdallah Abdel Mabood³

DOI: 10.21608/dsu.2020.18382.1016

Manuscript ID: DSU-1912-1016

KEYWORDS

*Alloplastic bone grafts-
Immediate placement-CBCT-
Implant stability.*

ABSTRACT

Introduction: Osseointegration around dental implant is the key word of implant stability and bone grafts have a big share for enhancing osseointegration. **Aim:** To evaluate the efficacy of two different types of bone graft, the (OsteonII) and (Biogen). **Patients and methods:** This study was carried out on fifteen healthy male patients with average age from 20 to 40 years old. 15 immediate dental implants were divided into (group1) immediate placement of 6 dental implant into fresh extracted bony socket with bone graft OsteonII, (group 2) immediate placement of 6 dental implant with bone graft BioGen and in, (group 3) immediate placement of 3 dental implant into fresh extracted bony socket without bone graft. Clinical examination was done for all patients before surgery. Radiographic evaluation using CBCT was done after 2 weeks and 3, 6 months postoperatively to measure bone density around inserted implants and vertical bone loss. **Results:** Radiographic evaluation showed significant higher bone density and lesser vertical bone loss around the inserted implants in group II than group I after two weeks, 6 and 9 months. Also, implant stability measurements at six and nine months showed higher values in group II than in group I. **Conclusion:** immediate implant placement can be done successfully using either OsteonII or BioGen bone grafts but, BioGen are superior with using immediate dental implant than OsteonII regarding bone density and implant stability around implant.

INTRODUCTION

Dental implants may be an option for people who have lost a tooth. Candidates for dental implant involve good health. Bone type of jaw is important to know, specially the bone grafts may be made from hydroxyapatite, a naturally occurring mineral (main mineral component of bone), made from bioactive glass. Hydroxyapatite is a synthetic bone graft used now due to osteoconduction, hardness, and acceptability by bone. Calcium carbonate is another type of bone graft, but it is completely resorbable in short time and makes the bone easily broken⁽¹⁾. The effect of both can be finally achieved by using tricalcium phosphate in combination with hydroxyapatite giving us the effect of both, osteoconduction and resorbability⁽²⁾.

After extraction of any teeth, Reduction of the alveolar bone occurs in the first 6 months to 2 years an estimate of 25% to 40% decrease in

- E-mail address:
amr.abdelnasser@hotmail.com
- 1. Master in Oral and Maxillofacial surgery, Faculty of Dentistry, Suez Canal University.
- 2. Professor of Oral and Maxillofacial surgery, Faculty of Dentistry, Suez Canal University.
- 3. Assistant Professor of Oral and Maxillofacial surgery, Faculty of Dentistry, Suez Canal University.

labio-palatal width occurs in the first year³. Limited time of surgical procedures is very important for patient psychology⁽⁴⁾. Osseointegration never be achieved until the implant must be sterile, compatible, used un harmful procedure, initial stability is very important and must be measured, and non-functionally loaded during healing period². Bone grafts used in implant is very useful step to enhance osteointegration⁽⁵⁾.

Using bone grafts is very effective to maintain ridge diameter, so 6 to 12 months healing period is needed after extraction. Some research workers, using a regenerative therapy which became apparent in a different observation period after immediate implant placement. The degree of bone grafting required for enhancing enough amount of bone around implant varies according to the amount of bone loss in different cases where there is a need to change the entire arch form and/or jaw relationship⁶. Many techniques and materials used in grafting procedures, many of which may be used in combination. The surrounding host bone and bone graft interaction is very important. Although some grafts will act merely as space fillers, the ideal graft will be osteoconductive and, osteoinductive to promote de novo bone formation remote from the host bone even within noncalcified tissues. Bone morphogenetic proteins and other bone-promoting factors have this latter property^(7, 8).

PATIENTS AND METHODS

This study contains fifteen fixtures in fifteen patients. The patients were divided into three unequal groups. In group I (6 implant), Osteon II bone graft was used around dental implant, while in group II (6 implant), Biogen bone graft was used around dental implant site and group III (3 implant) used without one graft. The patients were selected from the outpatient clinic. All patients were physically healthy

and have good oral hygiene condition and given the necessary information about the procedure and a written informed consent for approval to participate are necessary. This study was done according to the Declaration of Helsinki.

Preoperative phase:

Preoperative CBCT was taken for each patient to evaluate the presence of sufficient bone width and height. All patients were instructed to administer oral rinse three times per day, one week before surgery, oral prophylactic antibiotic and Clavulanic acid twice daily, one day prior to the surgery.

Operative Phase:

The patients were asked to take antibiotic tablet one hour prior surgery, patients were asked to thoroughly rinse with a disinfectant solution before procedure. All the surgical procedures were performed with local anesthesia using Ubistesin Forte 1:100.000. Anesthesia was administered to the patient a few minutes before surgery. A gingival incision was made using bard parker No3 with blade #15 exposing the tooth or remaining root to be extracted. The tooth was extracted atraumatically using the periosteal elevator. The periosteal elevator was applied around the tooth to be extracted to cut and tear the periodontal ligaments. The socket was thoroughly degranulated by curettage and proper irrigation with saline to eliminate all the connective tissue tags or periodontal ligaments remnants. The root diameter was measured by using caliber to determine the diameter (mesio-distal and bucco-palatal) and the gauge depth to determine the depth of the fresh extracted bony socket to select the appropriate implant. The implant should be as wide as permissible to allow maximum bone engagement with minimum thickness of facial and palatal walls not less than 1 mm. Primary stability achieved when the fixture extend

3to 4 mm beyond root apex. **Dentium** (www.dentium.com) implant system was used.

For **test group one**, the surrounding space in between fixture and the bone was condensed by (Osteon II), in **test group two**, the surrounding space in between fixture and the bone was condensed by (Biogen) and the **third Control group**, without any bone graft.

Interdental papillae mesial and distal to each implant were sutured in an interrupted matters suture using resorbable suture material.

Postoperative care and follow up:

Oral regimen of Augmentin 1gm/12hr was continued for five days postoperatively and after the first 24 hours patients were instructed to use mouth wash 3 times per day. Patients were viewed 24 hours after surgery.

Clinical Evaluation: Patients were viewed 24 hours after surgery to evaluate clinically the presence of delayed bleeding or post-operative complications as redness, edema, swelling at surgical site, wound dehiscence, pain, discomfort or implant looseness.

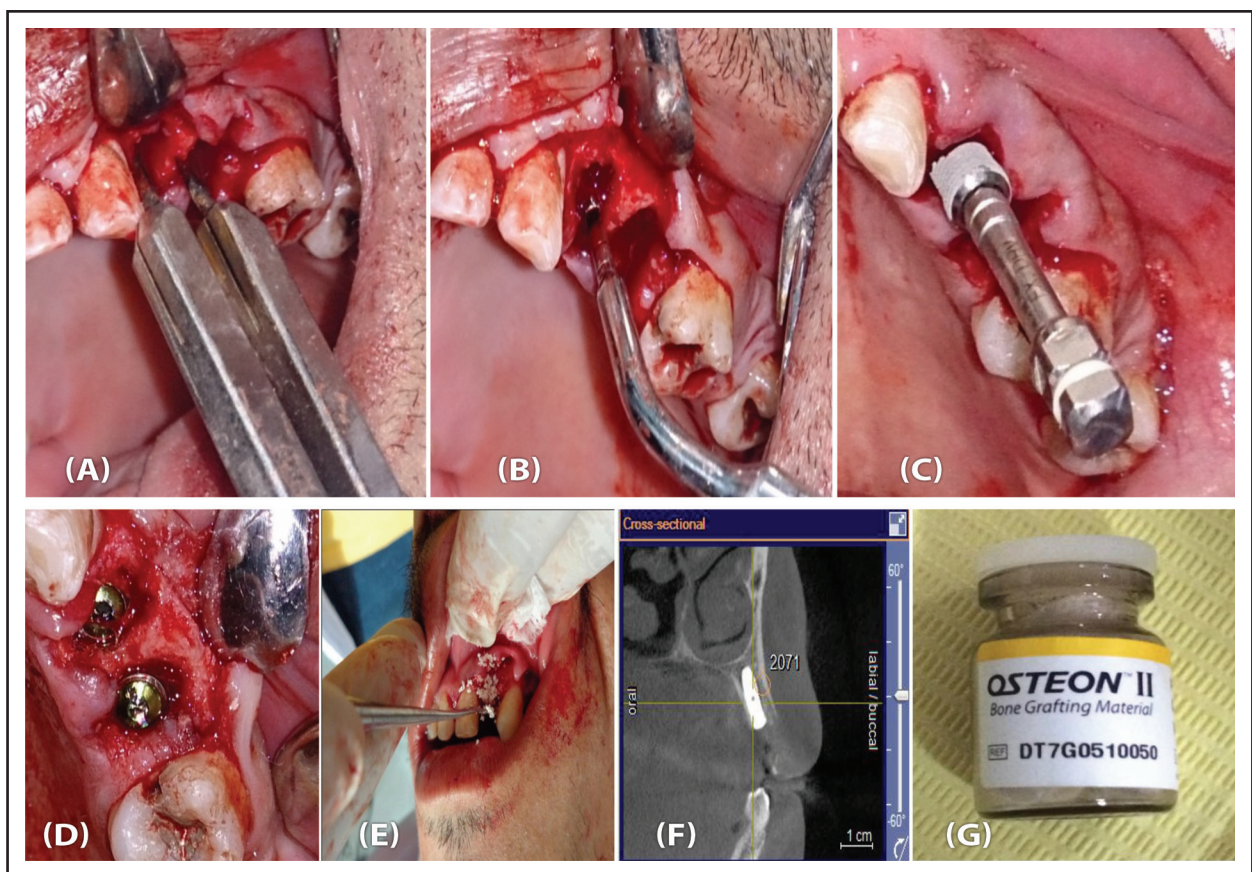


Fig. (1), (OsteonII) showing: (A)measuring the width of alveolar ridge of missing maxillary left first& second 2.2mm. (B) measuring the depth after initial drilling by pilot drill. (C)insertion of implant in alveolar ridge. (D) implant after insertion and sealed with cover screw. (E) application of osteon II bone graft around inserted implant. (F) CBCT bone density reading after nine months.

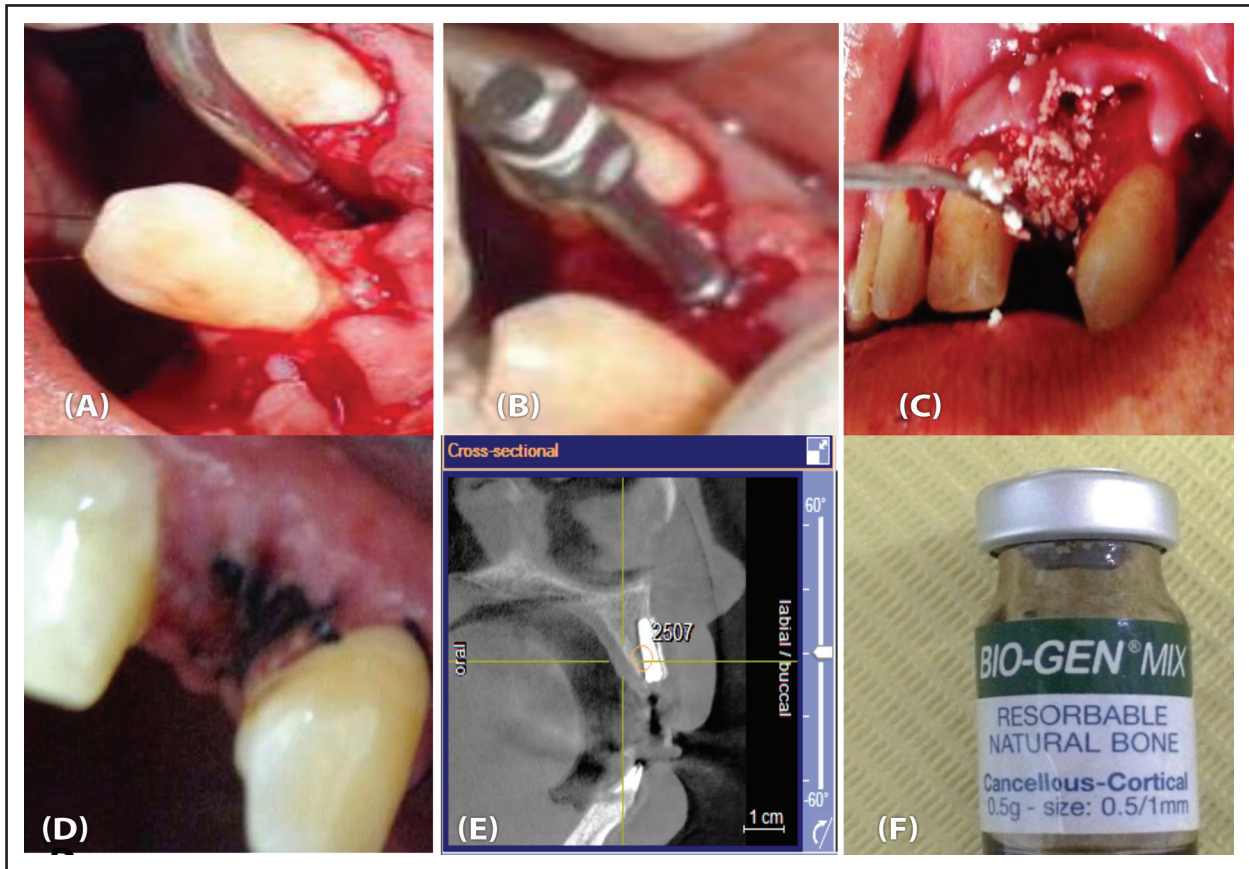


Fig. (2), (BioGen) showing: (A) measuring the depth after initial drilling by pilot drill.(B) insertion of implant in alveolar ridge. (C) implant sealed with cover screw and BioGen bone graft. (D) post operative suturing. (E) CBCT bone density reading after nine months.

After one week all stitches were removed. Regular clinical examination follow ups were done weekly during the first month then after 3, 6 and 9 months postoperatively.

Radiographic evaluation: Standardized digital orthopantomogram was done immediately postoperative. CBCT was done on intervals of two weeks, three and six months postoperatively.

The CBCT was used to detect the following: Bone density around implant and Marginal bone loss.

Implant Stability: (Osstell ISQ) was used to

measure the implant stability on intervals of three and six months for all implants postoperatively. Implant stability was measured for all the implants of the two groups after 6 and 9 months postoperatively by using Osstell ISQ device. All implants with implant stability values equal to or more than 65 ISQ were loaded after 6 months postoperatively. All gathered data for the three investigated groups were statistically analyzed by using T-test.

The hypothesis: There is difference between two different types of bone graft around dental implant. **The null hypothesis:** No difference.

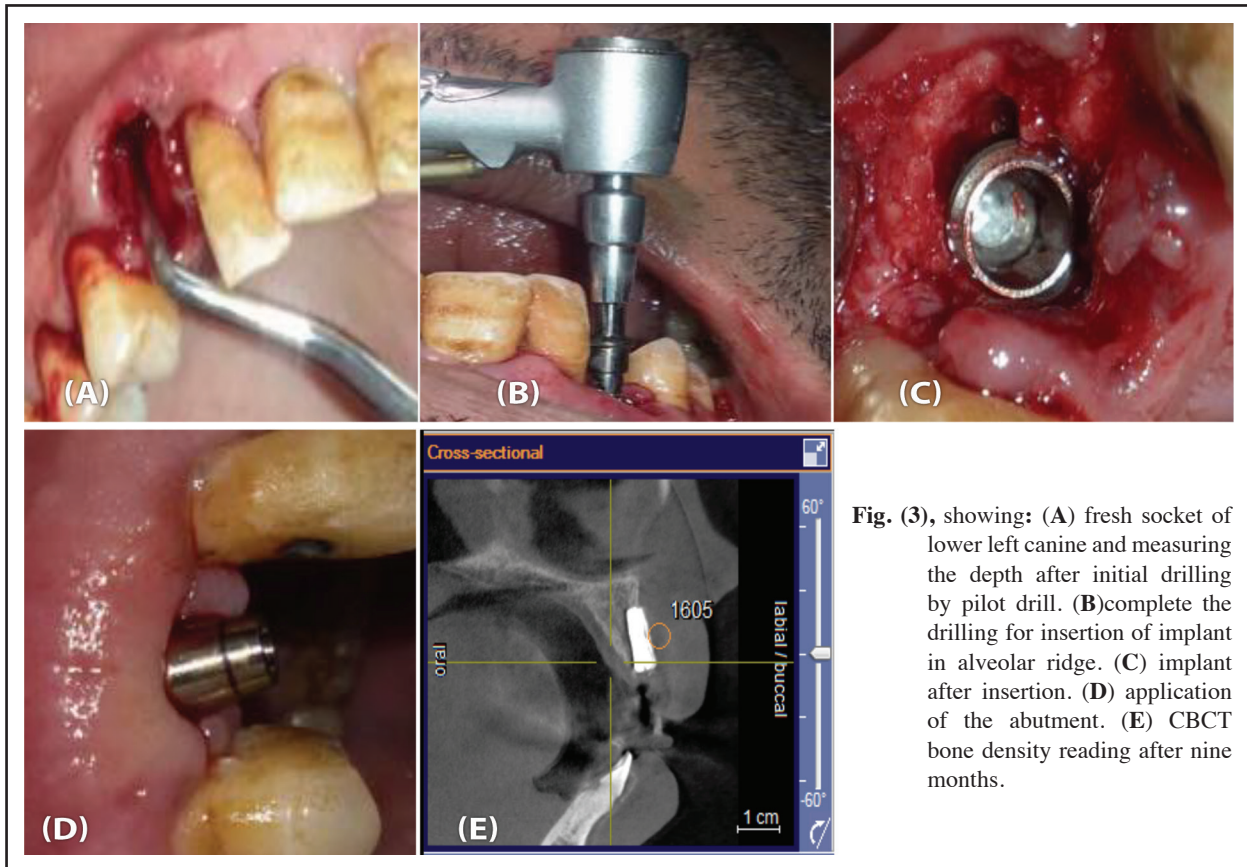


Fig. (3), showing: (A) fresh socket of lower left canine and measuring the depth after initial drilling by pilot drill. (B) complete the drilling for insertion of implant in alveolar ridge. (C) implant after insertion. (D) application of the abutment. (E) CBCT bone density reading after nine months.

RESULTS

All the patients showed no signs or symptoms of pain, tenderness, redness or inflammation of soft tissue around the inserted implant site through the whole study. Normal healing process of the soft tissue and bone around the implant was observed throughout the study.

Clinical evaluation: On the first day postoperatively minimal or no edema, pain, swelling and discomfort were reported in three cases of group I and one case of group II, but pain and edema were resolved after 48 hours by following medication regimen. No signs of infection, gingivitis or peri-implantitis.

Radiographic evaluation: Bone density was recorded using cone beam x ray around inserted im-

plant insertion after 2 weeks, 3 months and 6 months postoperatively.

After 2 weeks: Mean and standard deviation measures density around inserted implant in test group 1 was (1098.33 ± 31.89) and in test group 2 was (1635.667 ± 205.9) while in control group was (970.83 ± 60.53) (table 5).

After 3 months: Mean and standard deviation measures the bone density around the inserted implant in test group 2 showed significant increase more than test group 1 and control group according to statistical data analysis (ANOVA) where the mean and standard deviation were (1468.33 ± 47.92) in test group 1 and (1801.667 ± 113.2) in test group 2 and (1193.00 ± 88.67) is the result of control group. $P = 0.001$.

6 months after : The mean and standard deviation measures the bone density around the inserted implant in test group2 showed highly significant increase more than test group 1 and control group according to statistical data analysis (ANOVA) where the mean and standard deviation were (1650 ± 29.66) in test group1 and (2597.5 ± 111.3) in test group 2 and (1381.67±61.78) in control group = 0.001 (table 1).

The bone density increased steadily in all groups from the base line after two weeks postoperatively to the six months. The measurements of the bone density were higher in the test group (2) because the mean increasing in bone density in group 2 is about 73% from the base line to the 6months and about 60% in group 1 and 29% in control group.

Table (1) Showing bone density, vertical bone loss and ISQ measures for test group I, II and control group III during study intervals.

			Group I	Group II	GroupIII	t.test	P.value
Bone density	After 2 weeks	Range	1205-880	1635--960	970-605	23.338	0.001
		Mean ± SD	1098.33±31.89	1458.0 ± 107.29	970.83±60.53		
	After 6 months	Range	1396 – 2156	1503 – 193.93	214.22_251.4	62.565	0.001
		Mean ± SD	1868.63 ± 236.42	1648.25 ± 141.29	1205-1220		
Vertical bone loss	After 2 weeks	Range	0.63 – 0.85 mm	0.77 – 1.10 mm	1.22-152mm	1.550	0.018
		Mean ± SD	1635.667±205.9	1468.33±214.6	1224±261.2		
	After 6 months	Range	0.71 – 1.20 mm	0.93 – 1.41 mm	1.63_1.91mm	0.579	0.008
		Mean ± SD	0.85 ± 0.16 mm	1.09 ± 0.16 mm	1.25±0.16mm		
Horizontal Gab	After 2 weeks	Range	78 – 84	85 – 89	89_93	10.889	0.005
		Mean ± SD	71.25 ± 2.12	67.75 ± 2.12	61.24±2.12		
	After 6 months	Range	71 – 79	69 – 75	61_69	8.910	0.001
		Mean ± SD	75.13 ± 2.99	71.25 ± 2.12	67.11±1.85		

DISCUSSION

Cavallaro et al⁽¹⁰⁾ concluded that when the treatment planned for extraction (and potential immediate implant therapy), teeth should be extracted in the most atraumatic manner possible. Forces should be applied with low velocity and high duration to minimize trauma to the adjacent hard tissues. This agrees with the surgical protocol that was applied in the present study and the importance of using forces with low velocity in all the three groups so, no signs or symptoms of pain, tenderness, redness, inflammation of soft tissue around the inserted implant site or implant looseness was detected.

Ewers⁽¹¹⁾ used BioGen bone graft results similar to the autogenous bone graft. Evaluations of graft materials showed the formation of new bone. This study showed that BioGen is able to enhance osseointegration in 6 more months.

Kumar et al⁽¹²⁾ immediately placed implant after tooth removal and using BioGen bone material without guided bone regeneration techniques. All peri-implant bone defects completely disappeared six months after implant placement. They concluded that bone remodeling of implants placed in fresh extraction sockets showed a healing pattern with new bone apposition around the implant neck, with no horizontal or vertical bone resorption. This agrees with the using of BioGen bone grafting material that was applied in test group 2 of the present study which confirmed by CBCTX-ray and the clinical evaluations, the present study showed that BioGen bone graft is really able to enhance bone healing around inserted implant where the mean bone density of BioGen around the implant after six months showed highly significant increase compared to the results of control group.

Fugazzotto⁽¹³⁾ conducted a study to evaluate the effect of immediate placement of dental implants in conjunction with OsteonII bone grafting material.

The study was concluded that local grafting did not disturb the course of Osseointegration for immediate placement of dental implants if primary stability was reached. Also, the presence of bone graft increases the regeneration of bone around the inserted implant. These results agree with the results of the current study as bone density curve of OsteonII is even increasing after 6 months about 60%.

Schopper et al⁽¹⁴⁾ conducted a study on the hypothesis that the porous OsteonII could be used as a suitable biomaterial of sinus grafting in severely atrophic maxillae. After 7 months bone formation was evident within the pores of the particles proving that the biomaterial is suitable for grafting in severely atrophic maxillae.

Goldstein⁽¹⁵⁾ conducted a study with the aim to maintain effect of OsteonII in maxillary sinus graft healing. They concluded that after 6 months, the density of bone trabecula and corresponded cancellous bone was good, graft resorption was minimal indicating the affinity of the graft to induce more bone remodeling and increasing in density. This agrees with the statical and clinical results of the present study where BioGen bone grafts hewed highly significant increasing in bone density around the inserted implant more than OsteonII and showed complete resorption of bone substitute while Osteon II showed in complete resorption of bone substitute, so BioGen bone graft is more effective than OsteonII.

CONCLUSIONS

Using bone grafting materials in immediate placement dental implant can be done successfully using either Biogen or OsteonII, but Biogen are superior to finger OsteonII regarding bone density and osseointegration.

REFERENCE

1. Albrektsson T, Branemark P, Hansson H, Lindstrom J. Osteointegration titanium implants. *Acta Orthop Scand*. 1981; 5:159-162.
2. Schwartz-Arad D, Gulayev N, Chaushu G. Immediate versus non-immediate implantation for full-arch fixed reconstruction following extraction of all residual teeth: a retrospective comparative study. *J Periodontol*. 2000;71(6):923-928. doi:10.1902/jop.2000.71.6.923
3. Barzilay I, Graser GN, Iranpour B, Natiella JR. Immediate implantation of a pure titanium implant into an extraction socket: report of a pilot procedure. *Int J Oral Maxillofac Implants*. 1991;6(3):277-284.
4. Hansson HA, Albrektsson T, Branemark PI. Structural aspects of the interface between tissue and titanium implants. *J Prosthet Dent*. 1983;50 (1):108-113. doi:10.1016/0022-3913(83)90175-0.
5. Adell R, Eriksson B, Lekholm U, Branemark PI, Jemt T. Long-term follow-up study of osseointegrated implants in the treatment of totally edentulous jaws. *Int J Oral Maxillofac Implants*. 1990;5(4):347-359.
6. Carlsson RA & Persson AL. Morphologic changes of the mandible after extraction using dentures. A longitudinal, clinical and cephalometric study covering 5 years. *Review*. 1967;18: 27-54.
7. Lazarra RJ. Immediate placement into extraction sites: surgical and restorative advantages. *Inter J Perio Resto Dentistry*. 1989;9 :333-343.
8. Lindhe J, Berglundh T, Ericsson I, Liljenberg B, Marinello C. Experimental breakdown of peri-implant and periodontal tissues. A study in the beagle dog. *Clin Oral Implants Res*. 1992;3(1):9-16. doi:10.1034/j.1600-0501.1992.030102.x
9. Branemark PI, Hansson BO, Adell R, Breine U, Lindstrom J, Hallen O, Ohman A. Osseointegrated implants in the treatment of the edentulous jaw. Experience from a 10-year period. *Scand J Plast Reconstr Surg Suppl*. 1977;16:1-132.
10. Cavallaro JS, Greenstein G, Tarnow DP. Clinical pearls for surgical implant dentistry: Part 3. *Dent Today*. 2010;29(10) 134- 139.
11. Ewers R: Maxilla sinus grafting with marine algae derived bone forming material: a clinical report of long-term results. *J Oral Maxillofac Surg*. 2005; 63:12-18.
12. Kumar P, Vinitha B, Fathima G. Bone grafts in dentistry. *J Pharm Bioallied Sci*. 2013;5(Suppl 1):S125-S127. doi:10.4103/0975-7406.113312
13. Fugazzotto P. Guided Bone Regeneration at Immediate Implant Insertion and Loading: A Case Report. *Implant dent*. 2004; 13: 223-227. 10.1097/01.id.0000136911.90515.e4.
14. Schopper CE, Artzi Z, Moses O, Gelernter, I. Healing of bone dehiscence defects at delayed immediate implant site primarily closed by a rotated palatal flap following extraction. *International Journal of Oral & Maxillo fac Implants*. 2003; 15:550-558.
15. Goldstein M, Boyan BD, Schwartz Z. The palatal advanced flap: a pedicle flap for primary coverage of immediately placed implants. *Clin Oral Implants Res*. 2002;13(6):644-650. doi:10.1034/j.1600-0501.2002.130611.x