

Supratentorial Cavernous Malformations: Surgical Management and Outcome

AMR MOHSEN, M.D.; AHMED ASEM, M.D. and WALEED ABBASS, M.D.

The Department of Neurosurgery, Faculty of Medicine, Cairo University

Abstract

Background: Cavernous malformations are common vascular malformations composed of thin-walled sinusoids with no intervening brain parenchyma.

Aim of Study: To evaluate the outcome of surgical resection of supratentorial cavernous malformations.

Patients and Methods: 12 patients with supratentorial cavernous malformations operated upon in the period from June 2014 to December 2016 in Cairo University Hospitals were retrospectively studied for surgical outcomes including extent of excision, improvement of symptoms and development of complications. Pre-operative CT and MRI were performed in all patients in addition to angiography when the diagnosis was doubtful. Patients were followed-up clinically and radiologically for 1 year after surgery.

Results: The study included 6 males and 6 females with an average age of 34.6 years. The lesion was frontal in 4, temporal in 4, parietal in 3 and occipital in 1 patient. Epilepsy was the most common presenting symptom occurring in 6 patients. Total resection was achieved in 11 (91.7%) patients. Total resection of the surrounding hemosiderin-stained brain was achieved in 9 (75%) patients. Improvement of pre-operative symptoms was achieved in 11 (91.7%) patients. Post-operative complications occurred in 2 (16.6%) patients.

Conclusions: Surgical excision of symptomatic supratentorial cavernous malformations provides good control of pre-operative symptoms and has a low rate of morbidity and mortality. The aim of surgery should always be total excision of the malformation.

Key Words: Cavernous malformation – Hemosiderin ring – Microsurgery – Total resection.

Introduction

CAVERNOUS malformations (also known as cavernomas, cavernous angiomas) are common vascular lesions that may arise in the cerebrum, brain stem, spinal cord and cranial or spinal nerves affecting approximately 1:200 of the general pop-

ulation [1,2]. They are composed of thin-walled sinusoids with no intervening brain parenchyma. Cavernous malformations (CMs) may be single or multiple. They may be asymptomatic or may present with seizures, intracranial hemorrhage, focal neurological deficits or manifestations of increased intracranial tension [3].

CMs are angiographically occult. MRI is the investigation of choice for their diagnosis. T1 and T2 weighted images, gradient echo sequence, susceptibility weighted images and functional MRI are used for diagnosis and for intraoperative navigation during surgery for deeply seated lesions [4]. In T2-weighted images, they usually show a core of mixed signal intensity with a marked hypointense peripheral rim which is related largely to various stages of hemorrhage [5]. T1-weighted images may show a core of mixed signal intensity. Contrast enhancement may be present in some cases. CT scan of the brain may show a small focus of hemorrhage or calcification suggestive of an underlying cavernous malformation [4].

Supratentorial cavernous malformations account for nearly 80% of all CMs. They are more commonly located in the frontal and temporal lobes. Seizures are the most common presenting symptoms probably due to repeated microhemorrhage resulting in hemosiderin deposition and gliosis in the surrounding brain tissue [6,7].

Abbreviations:

CM : Cavernous malformation.
CT : Computerized tomography.
cm : centimetre.
DVA : Developmental venous anomaly.
EEG : Electroencephalography.
GTC : Generalized tonic clonic.
ICP : Intracranial pressure.
MRI : Magnetic resonance imaging.

Correspondence to: Dr. Amr Mohsen, The Department of Neurosurgery, Faculty of Medicine, Cairo University

Microsurgery is indicated in patients with intractable epilepsy, patients with neurological deficits and patients with manifestations of increased ICP. Lesions larger than 1cm even if asymptomatic may also be considered for surgical intervention [8]. Stereotactic radiosurgery (SRS) may be considered for deeply located CMs in eloquent brain areas as surgery here carries high risk of neurological morbidity [4]. Small (less than 1cm) asymptomatic lesions may be managed conservatively.

The aim of our study was to evaluate the outcome of microsurgical resection of supratentorial cavernous malformations as regards extent of resection of the lesion and the surrounding hemosiderin stained brain, improvement of presenting symptoms and incidence of postoperative complications.

Patients and Methods

This retrospective study included 12 patients with supratentorial CMs operated upon by microsurgical resection in the period from June 2014 to December 2016 in the Neurosurgery Department, Faculty of Medicine, Cairo University. Inclusion criteria included single lesions, larger than 1cm, presenting with recent hemorrhage, uncontrolled epilepsy, neurological deficits or manifestations of increased ICP and in surgically accessible location. Exclusion criteria included multiple lesions, small asymptomatic CMs, brain stem lesions, lesions involving the thalamus, basal ganglia or ventricular system, patients unfit for general anesthesia and those who refused surgical intervention.

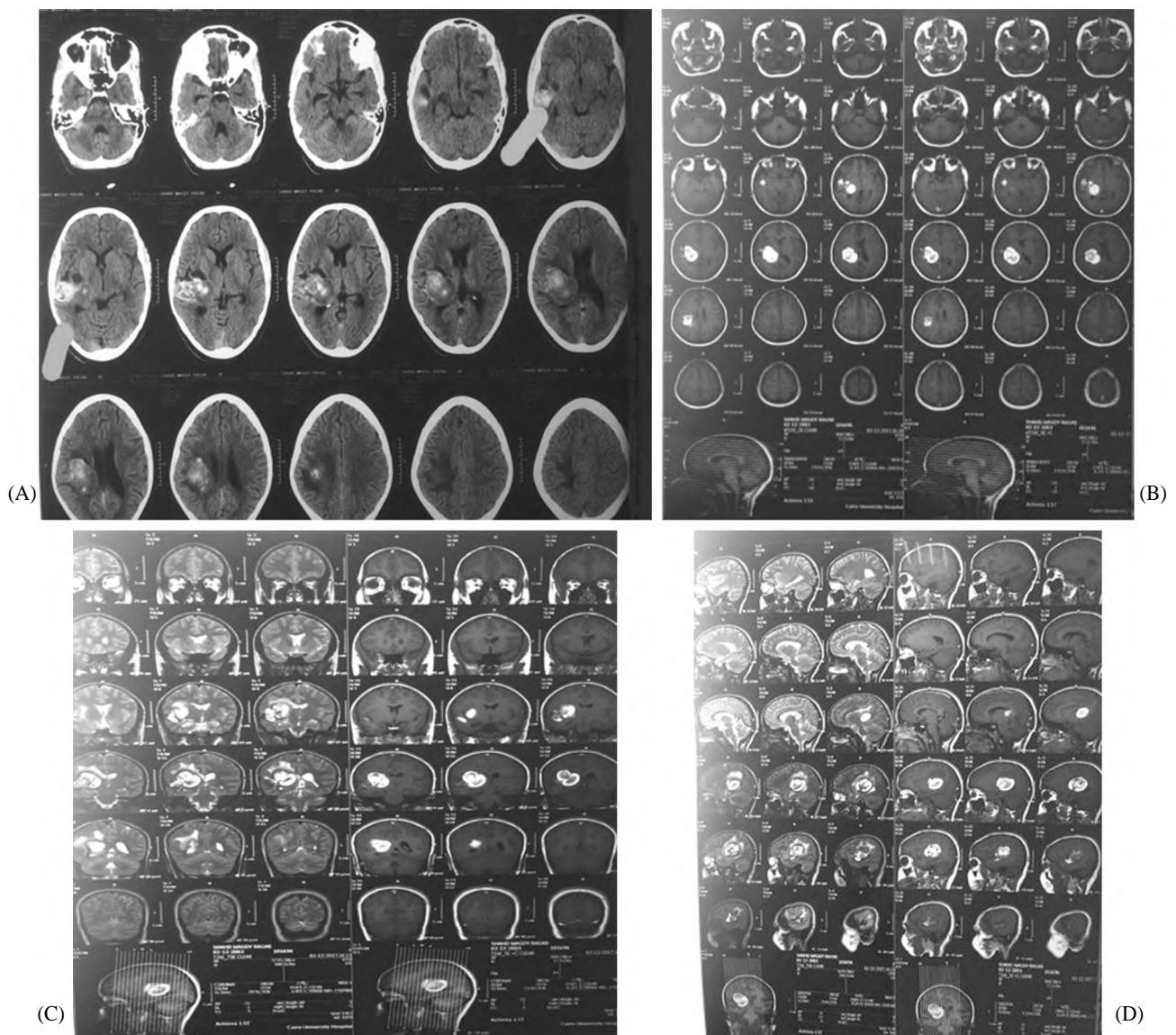


Fig. (1): Preoperative CT (a) and MRI in the axial (b), coronal (c) and sagittal (d) planes of a deep right parietal CM with recent hemorrhage in a 16 year old male patient.

Data collected included age and gender of the patients, history taking and complete general and neurological examination, presenting symptoms, location and size of the lesion. CT and MRI of the brain were performed preoperatively in all patients. MRI was used to assess the location and size of the lesion, single or multiple, surrounding hemosiderin ring, presence of hemorrhage and whether it is recent or remote. Angiography was performed in some cases when the diagnosis was doubtful and to detect any associated vascular malformations (eg developmental venous anomaly or DVA). Electroencephalography (EEG) was performed in patients presenting with seizures.

Surgical technique: The operation was performed under general anesthesia. Patient's head was placed in a three-pin Mayfield skull clamp and positioned according to the location of the malformation. Small craniotomy overlying the lesion was done with the help of neuronavigation in small or deep lesions. After opening of the dura and arachnoid dissection, the lesion was usually approached through a transsulcal approach. The aim of surgery was total excision of the lesion and, whenever possible, total removal of the surrounding hemosiderin ring. In lesions located in the mesial

temporal lobe presenting with epilepsy, lesinectomy was also associated with amygdalohippocampectomy. Care was taken when cauterizing veins draining the lesion and any associated DVA was preserved. After removal of the lesion and surrounding hemosiderin stained brain, meticulous hemostasis was performed and the wound was closed in layers leaving a subcutaneous drain that was removed after 24 hours. Intraoperative MRI was not used in any case as it is not available in our institute.

Postoperatively, patients were hospitalized for 3-7 days before discharge. Patients were followed up for at least 1 year following surgery. Patients were followed clinically during hospital stay and then monthly for 1 year to detect improvement of preoperative symptoms and the development of any postoperative complications. In patients presenting with epilepsy, the Engle's classification [9] was used to assess the seizure outcome. CT or MRI were performed within 48 hours after surgery to show extent of resection of the lesion and surrounding hemosiderin ring and to exclude postoperative hemorrhage or severe edema. Another MRI was performed at 1 year follow-up to exclude recurrence. The diagnosis was confirmed by histopathological examination.

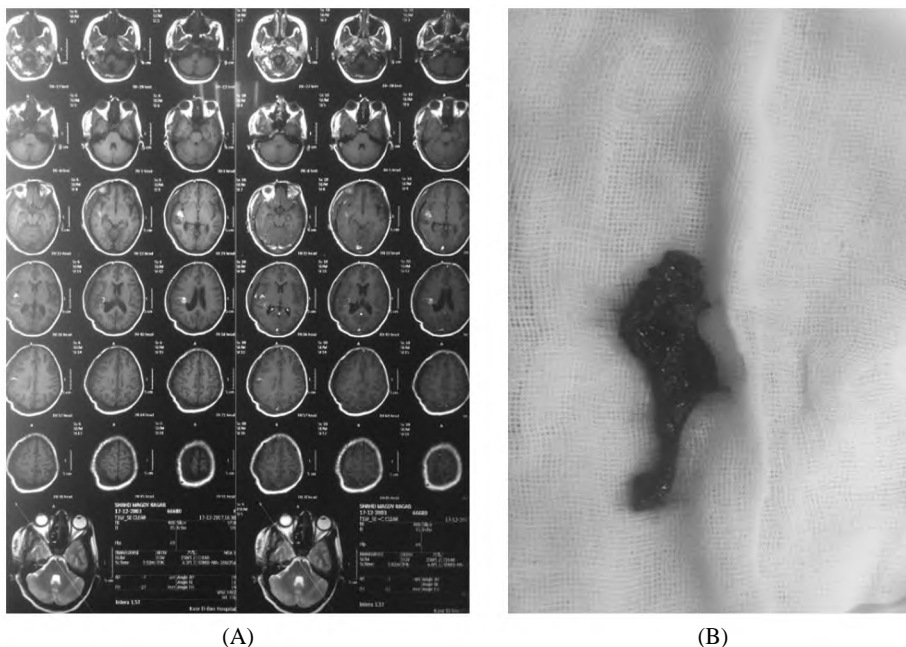


Fig. (2): (a) Follow-up MRI T1 of the patient in Fig. (1) after resection of the CM and evacuation of hematoma. An associated DVA was identified and managed conservatively, (b) part of the resected lesion.

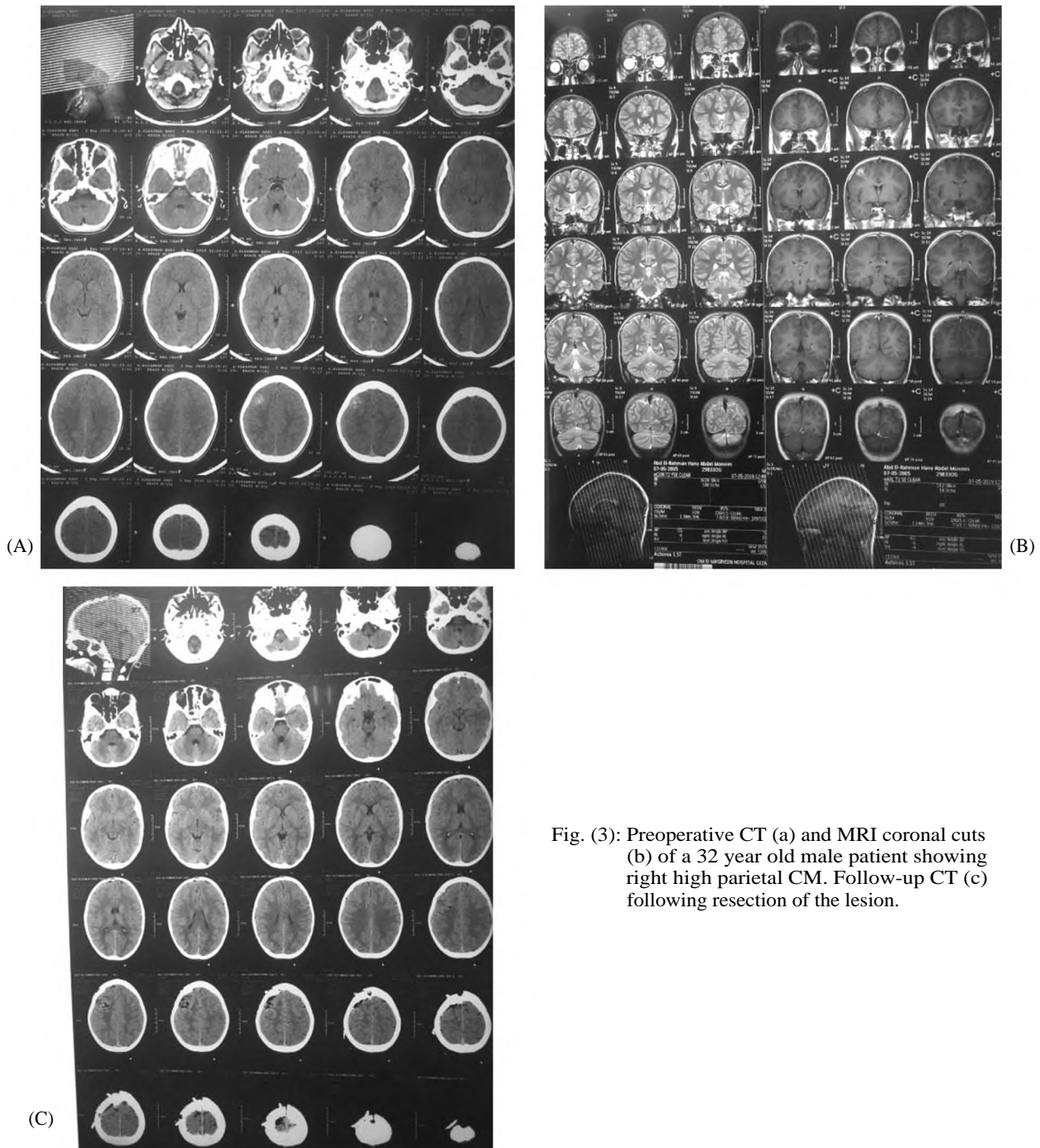


Fig. (3): Preoperative CT (a) and MRI coronal cuts (b) of a 32 year old male patient showing right high parietal CM. Follow-up CT (c) following resection of the lesion.

Results

This study included 12 patients with supratentorial CMs operated upon by microsurgical resection. 6 (50%) males and 6 (50%) females whose age ranged from 16-52 years with a mean age of 34.6 years. The lesion was solitary in all patients. The site of CM was frontal in 4 (33.3%), temporal in 4 (33.3%), parietal in 3 (25%) and occipital in 1 (8.3%). Among the 4 cases located in the temporal

lobe, 2 (50%) were neocortical and 2 (50%) were mesiotemporal that required amygdalohippocampectomy in addition to lesionectomy. The lesion was located in the right hemisphere in 8 (66.7%) cases while 4 (33.3%) cases were located in the left hemisphere. The diameter of the lesion was less than 2cm (1-2cm) in 5 (41.7%) patients and larger than 2cm (2-6cm) in 7 (58.3%) patients (Table 1).

Table (1): Patient's characteristics.

	Number	Percentage
<i>Sex:</i>		
Male	6	50
Female	6	50
<i>Age (years)</i>		
	Range	Mean
	16-52	34.6
<i>Location:</i>		
Frontal	4	33.3
Temporal	4	33.3
Parietal	3	25
Occipital	1	8.3
<i>Side:</i>		
Right	8	66.7
Left	4	33.3
<i>Diameter:</i>		
<2cm	5	41.7
>2cm	7	58.3

As regards presenting symptoms, uncontrolled epilepsy (epilepsy not controlled by 2 or more antiepileptic drugs of more than 1 year duration) was the presenting symptom in 6 (50%) patients, focal neurological deficit (hemiplegia/paresis and 6th nerve palsy) were present in 4 (33.3%) patients while severe headache uncontrolled by analgesics was the presenting symptom in 2 (16.6%) patients. In the 6 patients presenting with epilepsy, 4 (66.7%) had complex partial seizures while 1 (16.7%) had simple partial seizures and 1 (16.7%) suffered from generalized tonic clonic (GTC) convulsions.

Regarding the extent of CM resection, gross total resection was achieved in 11 (91.7%) cases while in 1 (8.3%) case, the resection was subtotal and a reoperation was performed to remove the residual part of the lesion. Total removal of the surrounding hemosiderin stained brain was achieved in 9 (75%) cases whereas only partial or subtotal removal occurred in 3 (25%) patients (Table 2). As regards improvement of preoperative symptoms following surgery, 4 (66.7%) of the 6 patients presenting with epilepsy became seizure free (Engel class 1), 1 (16.7%) became almost seizure free (Engel class 2) and 1 (16.7%) had worthwhile improvement (Engel class 3) at 1 year follow-up. None of the patients was classified as Engel class 4 (no worthwhile improvement or seizures getting worse). In patients presenting with neurological deficits, 3 (75%) showed postoperative improvement whereas the deficit persisted in 1 (25%) patient. Both patients presenting with headache showed marked improvement during the follow-up period.

Table (2): Extent of resection of the lesion and surrounding hemosiderin ring.

	Total resection	Subtotal resection
Cavernous malformation	11 (91.7%)	1 (8.3%)
Hemosiderin ring	9 (75%)	3 (25%)

None of our patients died during the follow-up period. No major complications were encountered. Only 2 minor complications were recorded in the 12 patients (16.6%), transient hemiparesis in 1 patient and superficial wound infection in another. Both cases were managed conservatively.

Discussion

Cavernous malformations of the brain are well circumscribed vascular lesions characterized by reddish purple multi-lobular appearance resembling a mulberry [10,11]. Around 80% are located in the supratentorial region and may cause a variety of symptoms including fits, neurological deficits and headache or may be asymptomatic. The annual risk of seizures is 1.5% per person per year and around 41-59% of cerebral CMs will present with epilepsy [12]. The annual bleeding rate is approximately 1.9% per lesion per year [13]. Our study included 12 patients with supratentorial CMs who were operated upon by microsurgical resection. Indications for surgery were either uncontrolled fits, acute or progressive neurological deficit or marked manifestations of increased ICP. Asymptomatic and accidentally discovered lesions were excluded from our study.

In 2/3 of the patients in our study, the location was either in the frontal or temporal lobe. The presenting symptoms varied according to the location of the CM. In temporal lobe lesions, the most common presenting symptom was complex partial seizures (75%) while in frontal lobe lesions, 3 types of seizures (GTC, simple partial and complex partial) were encountered in 1 patient each. All 3 cases with parietal lesions presented with focal neurological deficits whereas the only occipital lesion presented with headache uncontrolled by analgesics. Overall and regardless of location, epilepsy was the most common presenting symptom occurring in 50% of patients which is similar to many other studies and is most probably related to blood breakdown products epileptogenic potential [11]. Focal neurological deficits occurred mainly in patients with recent hemorrhage while headache was more commonly associated with larger space occupying lesions. Although in the literature the CMs have no side predilection [14], 66.7% of our

cases were located in the right hemisphere. This is probably due to the small number of patients in our study which makes this a bias rather than a true statistical finding.

In our study an associated developmental venous anomaly was found intraoperatively in 1 (8.3%) patient. A DVA is composed of enlarged veins draining radially into a single distal vein giving the "caput medusa" appearance [3]. In this patient, the DVA was not detected preoperatively because the patient didn't perform a cerebral angiography prior to surgery. The anomaly was not surgically approached as this could result in massive edema in the region drained by the anomaly. In the literature, the association of CM with DVA has ranged from as low as 6% to as high as 100% [11,15,16].

Gross total excision of the CM, as evidenced by follow-up MRI, was achieved in 91.7% of our patients while in 1 (8.3%) patient the excision was subtotal and the patient required reoperation to remove the residual part. In this patient, the lesion was deep parietal in an eloquent brain area. According to Porter and colleagues, complete removal of the lesion is an essential goal of surgical excision of CM to avoid rebleeding and this was the indication for reoperation for this patient. Regarding the hemosiderin stained brain surrounding the lesion, total removal of the hemosiderin ring was achieved in 75% of cases. All 3 cases with subtotal resection of hemosiderin ring were deep lesions in eloquent brain areas. This together with the absence of intraoperative MRI in our institute made total removal of the hemosiderin stained difficult and carries high risk of morbidity. We believe that the use of awake craniotomy, intraoperative neurophysiological monitoring and intraoperative MRI would result in more favorable outcome regarding resection of the lesion as well as the hemosiderin stained brain. The removal of the hemosiderin ring is of particular concern in patients presenting with epilepsy. Some authors have shown better results in epilepsy control with complete removal of the hemosiderin ring [19,18,20] while others have shown no statistically significant difference when comparing complete with incomplete removal of hemosiderin ring [21,22]. We believe removal of the stained brain should always be attempted when the lesion is superficial and in non-eloquent brain area while caution should be taken when the lesion is deep or in eloquent location.

All patients presenting with epilepsy in our series (6 patients) showed postoperative improvement in fits frequency where 4 became seizure

free, 1 showed marked decline in fits frequency and 1 had a slight improvement at 1 year follow-up. All patients were still on antiepileptic drugs as our policy was to start withdrawal of antiepileptics when the patient has been seizure free for at least one year with favorable EEG and MRI results. Many studies have shown similar favorable results concerning seizure control following surgical resection of supratentorial CMs [2,4,11,23]. On the other hand, the study by Fernandez and colleagues [7] showed no significant difference regarding seizure outcome when comparing surgically with medically treated patients. 75% of patients presenting with focal neurological deficits in our study improved postoperatively and the 2 patients presenting with headache also improved during the follow-up period.

In our study none of the patients died during the follow-up period and there were no cases of severe complications. Only 2 patients (16.6%) showed minor complications where 1 patient suffered from transient hemiparesis which was mostly related to marked postoperative edema and improved within 10 days with dehydrating measures while the other showed superficial scalp wound infection and was conservatively managed. This low rate of complications agrees with the literature which states that microsurgical resection of supratentorial CMs is a safe procedure with low rate of morbidity and mortality.

The main limitation in this study is the small number of cases which doesn't allow proper statistical analysis. Longer follow-up period is recommended to detect long term outcome and the possibility of withdrawal of antiepileptic drugs for patients presenting with epilepsy. We also recommend, whenever available, the use of neuronavigation for proper localization of deep and small lesions and the use of intraoperative MRI to ensure complete removal of the lesion and thus avoid the need for reoperation if a part of the CM is not removed.

Conclusion:

Microsurgical resection of supratentorial cavernous malformations is a safe procedure with good results regarding control of epilepsy or other presenting symptoms, preventing the risk of hemorrhage from the lesion with a low rate of morbidity and mortality. The aim of surgery should always be complete excision of the lesion and (if possible) complete excision of the surrounding hemosiderin stained brain particularly in patients presenting with uncontrolled epilepsy.

References

- 1- RIGAMONTI D., HADLEY M.N., DRAYER B.P., JOHNSON P.C., HOENIG-RIGAMONTI K., KNIGHT J.T. and SPETZLER R.F.: Cerebral cavernous malformations: Incidence and familial occurrence. *New England Journal of Medicine*, 319: 343-347, 1988.
- 2- BAUMANN C.R., ACCIARRI N., BERTALANFFY H., DEVINSKY O., ELGER C.E., LO RUSSO G., COSSU M., SURE U., SINGH A., STEFAN H., HAMMEN T., GEORGIADIS D., BAUMGARTNER R.W., ANDERMANN F. and SIEGEL A.M.: Seizure outcome after resection of supratentorial cavernous malformations: A study of 168 patients. *Epilepsia*, 48 (3): 559-563, 2007.
- 3- GROSS B.A. and DU R.: Diagnosis and treatment of vascular malformations of the brain. *Curr. Treat. Options Neurol.*, 16: 279, 2014.
- 4- MOUCHTOURIS N., CHALOUHI N., CHITALE A., STARKE R.M., TJOUMAKARIS S.I., ROSENWASSER R.H. and JABBOUR P.M.: Management of cerebral cavernous malformations: From diagnosis to treatment. *Scientific World Journal*, 808314, 2015.
- 5- BARKER C.S.: Magnetic resonance imaging of intracranial cavernous angiomas: A report of 13 cases with pathological confirmation. *Clin. Radiol.*, 48 (2): 117-121, 1993.
- 6- CHAHINE L. and BERG M.: Clinical reasoning: Cerebral cavernous malformations. *Neurology*, 72: 44-49, 2009.
- 7- FERNÁNDEZ S., MIRÓ J., FALIP M., COELLO A., PLANS G., CASTAÑER S. and ACEBES J.J.: Surgical versus conservative treatment in patients with cerebral cavernomas and non refractory epilepsy. *Seizure*, 21 (10): 785-788, 2012.
- 8- ZOTTA D., Di RIENZO A., SCOGNA A., RICCI A., RICCI G. and GALZIO R.J.: Supratentorial cavernomas in eloquent brain areas: Application of neuronavigation and functional MRI in operative planning. *J. Neurosurg Sci.*, 49 (1): 13-19, 2005.
- 9- ENGEL J. and RASMUSSEN T.B.: Outcome with respect to seizures. In J. Engel (Ed) *Surgical treatment of epilepsies*. 2nd ed. Raven Press, New York, pp. 609-621, 1993.
- 10- RUSSEL D. and RUBINSTEIN L.: Tumours and hamartomas of the blood vessels. In: *The pathology of tumours of the nervous system*. Fourth edn. Arnold, London, pp 126-145, 1977.
- 11- BERTALANFFY H., BENES L., MIYAZAWA T., ALBERTI O., SIEGEL A.M. and SURE U.: Cerebral cavernomas in the adult. Review of the literature and analysis of 72 surgically treated patients. *Neurosurg Rev.*, 25 (1-2): 1-53, 2002.
- 12- COHEN D.S., ZUBAY G.P. and GOODMAN R.R.: Seizure outcome after lesionectomy for cavernous malformations. *J. Neurosurg.*, 83: 237-242, 1997.
- 13- LABAUGE P., BRUNEREAU L., LEVY C., LABERGE S. and HOUTTEVILLE J.P.: The natural history of familial cerebral cavernomas: A retrospective MRI study of 40 patients. *Neuroradiology*, 42: 327-332, 2000.
- 14- HAHN M., ASCHOFF A. and KUNZE S.: 667 histologically verified cavernomas of the CNS (37 personal cases). Review of localisation, symptoms and signs, diagnosis, and results of operative treatment. *Adv Neurosurg.*, 19: 122-126, 1999.
- 15- AMIN-HANJANI S., OGILVY C.S., OJEMANN R.G. and CROWELL R.M.: Risks of surgical management for cavernous malformations of the nervous system. *Neurosurgery*, 42: 1220-1227, 1998.
- 16- PORTER R.W., DETWILER P.W., SPETZLER R.F., LAWTON M.T., BASKIN J.J., DERKSEN P.T. and ZABRAMSKI J.M.: Cavernous malformations of the brainstem: Experiences with 100 patients. *J. Neurosurg.*, 90: 50-58, 1999.
- 17- PORTER P.J., WILLINSKY R.A., HARPER W. and WALLACE M.C.: Cerebral cavernous malformations: Natural history and prognosis after clinical deterioration with or without haemorrhage. *J. Neurosurg.*, 87: 190-197, 1997.
- 18- BAUMANN C.R., SCHUKNECHT B., LO RUSSO G., COSSU M., CITTERIO A., ANDERMANN F. and SIEGEL A.M.: Seizure outcome following resection of cavernous malformations is better when surrounding hemosiderin stained brain is also removed. *Epilepsia*, 47: 563-566, 2006.
- 19- ENGLT D.J., HAN S.J., LAWTON M.T. and CHANG E.F.: Predictors of seizure freedom in the surgical treatment of supratentorial cavernous malformations. *J. Neurosurg.*, 115 (6): 1169-1174, 2011.
- 20- BERNOTAS G., RASTENYTE D., DELTUVA V., MATUKEVICIUS A., JASKEVICIENE V. and TAMASAUSKAS A.: Cavernous angiomas: An uncontrolled clinical study of 87 surgically treated patients. *Medicina (Kaunas)*, 45 (1): 21-28, 2009.
- 21- CASAZZA M., BROGGI G., FRANZINI A., AVANZINI G., SPREAFICO R., BRACCHI M. and VALENTINI M.C.: Supratentorial cavernous angiomas and epileptic seizures: Preoperative course and postoperative outcome. *Neurosurgery*, 39: 26-32, 1996.
- 22- ZEVEGARIDIS D., VAN VELTHOVEN V., EBELING U. and REULEN H.J.: Seizure control following surgery in supratentorial cavernous malformations: A retrospective study of 77 patients. *Acta Neurochir Wien*, 138: 672-677, 1996.
- 23- STEFAN H. and HAMMEN T.: Cavernous haemangiomas, epilepsy and treatment strategies. *Acta Neurologica Scandinavica*, 110: 393-397, 2004.

الوحمات الدموية بالمخ التدخل الجراحي ومخارجاته

أجريت هذه الدراسة بغرض دراسة نتائج التدخل الجراحي الميكروسكوبي فى حالات الوحمات الدموية بالمخ وقد تم إجراء الجراحة على اثنى عشر حالة تعاني من وحمات دموية بالمخ فى الفترة من يونيو ٢٠١٤ حتى ديسمبر ٢٠١٦ فى عمليات جراحة المخ والأعصاب بكلية الطب جامعة القاهرة. وقد تم متابعة الحالات إكلينيكية وعن طريق أشعة الرنين المغناطيسى لمدة سنة على الأقل بعد إجراء الجراحة وذلك لمتابعة التحسن الإكلينيكى ومتابعة حدوث أى مضاعفات إلى جانب متابعة نسبة إزالة الوحمة الدموية والجزء المحيط بها.

وقد أظهرت نتائج البحث أن الجراحة الميكروسكوبية لإزالة الوحمات الدموية هى طريقة آمنة وفعالة لإزالة الوحمة بالكامل وتؤدي إلى تحسن ملحوظ فى الأعراض الإكلينيكية للمريض إلى جانب تجنب المريض خطورة حدوث نزيف بالمخ إذا لم يتم إزالتها وكذلك تم إظهار أن نسبة حدوث مضاعفات مصاحبة للجراحة هى نسبة قليلة وتكون فى الغالب مضاعفات مؤقتة ويمكن أن تتحسن بالعلاج التحفظى.