

Clippless Laparoscopic Cholecystectomy Using Ultrasonic Dissection

HAMED A. ELBADAWY, M.D.*; MAHMOUD M. SALAMA, M.Sc.** and GAD Y. MEKKI, M.D.*

The Department of General Surgery, Faculty of Medicine for Girls, Al-Azhar* and Ain Shams** Universities, Cairo, Egypt

Abstract

Background: The surgical removal of the gallbladder, or cholecystectomy, is one of the more commonly performed procedures by general surgeons. Cholecystectomy represents the most common biliary tract procedure and the second most common surgical procedure overall.

Aim of Study: To evaluate the role of Harmonic scalpel in laparoscopic cholecystectomy in closure of cystic duct and artery and its complications.

Patients and Methods: This prospective randomized study was conducted at El-Zahra University Hospital, Cairo, Egypt, on 100 consecutive patients between March 2017 and October 2019 with chronic calculous cholecystitis. Patient selection for the study was based on clinical diagnosis, ultrasonographic examination findings, laboratory investigations. All patients of the study were subjected to laparoscopic cholecystectomy using the harmonic scalpel for hemostasis and for sealing of the cystic duct without using any ligatures or clips.

Results: The operative time in patients of the study ranged between 40-105min with a mean operative time of 55.4 ± 15.6 min. In our patients post-operative bleeding occur in two cases (2%) which was minimal and stopped spontaneously, wound infection in 3 patients (3%), bile leak was present in one case (1%), which stop spontaneously after 5 days.

Conclusion: The use of ultrasonic technology in the closure of the cystic duct has proven to be as safe and effective as the commonly used simple metal clips. Neither minor nor major bile leaks attributed to the use of ultrasonic technology were encountered throughout the study period.

Key Words: *Clippless laparoscopic cholecystectomy – Harmonic scalpel.*

Introduction

THE surgical removal of the gallbladder, or cholecystectomy, is one of the more commonly performed procedures by general surgeons. Cholecystectomy represents the most common biliary tract

procedure and the second most common surgical procedure overall [1]. Laparoscopic cholecystectomy has become the gold standard and preferred technique for the procedure [2]. Currently, the placement of surgical clips is the most commonly used technique of cystic duct occlusion [2]. Clips, however, have the potential to result in complications such as a bile leak of the cystic duct stump. This can be due to a displaced clip, to necrosis of the cystic dump stump due to an incorrectly placed clip initially followed by a second clip distally, or to a clip placed too proximal to the common bile duct causing entrapment or injury [3]. Therefore, the use of a single instrument for exposure, dissection, and occlusion of both the cystic duct and artery would decrease these potential complications associated with clip placement and increase efficiency in the operating room [4]. One of the more recent trends in laparoscopic research has focused on vessel sealing instruments that utilize alternative energy sources. In laparoscopic cholecystectomy, there is a potential for benefit with these new instruments in exposure, dissection, and occlusion of the cystic duct and artery [3]. Several alternative energy sources have been used in laparoscopic cholecystectomy for cystic duct occlusion with varying success. Early studies focused on the use of ultrasonic coagulating shears and electro-thermal bipolar vessel sealers. The Harmonic scalpel has become one of the more widely used instruments [5].

Patients and Methods

This prospective randomized study was conducted at El-Zahra University Hospital, Cairo, Egypt, on 100 consecutive patients between March 2017 and October 2019 with chronic calculous cholecystitis were included in this study. Patient selection for the study was based on clinical diagnosis,

Correspondence to: Dr. Mahmoud M. Salama,
[E-Mail: dr.mahmoudsalama80@yahoo.com](mailto:dr.mahmoudsalama80@yahoo.com)

ultrasonographic examination findings, laboratory investigations.

Inclusion criteria: All of patients with chronic calcular cholecystitis were included in our study.

Exclusion criteria: Patients with choledocholithiasis, patients with perforated gall bladder, patients with acute cholecystitis, patients with liver cirrhosis (coarse pattern), previous abdominal operation, patients unfit for surgery, pregnant woman and suspicion of gallbladder malignancy based on ultrasonography and subsequent Computed Tomography (CT) findings.

All patients of the study were subjected to laparoscopic cholecystectomy using the harmonic scalpel for hemostasis and for sealing of the cystic duct without using any ligatures or clips.

All patients in the study were subjected to thorough history and clinical examination and laboratory investigation include complete blood picture, coagulation profile e.g., prothrombin time, activity, and INR, liver function tests e.g. liver enzymes as AST, ALT, bilirubin level either total or direct, kidney function tests as blood urea and serum creatinine, blood chemistry: Include, blood glucose level, gamma glutamyle transferase (γ -GT), Alkaline Phosphatase (AP) and abdominal ultrasonography.

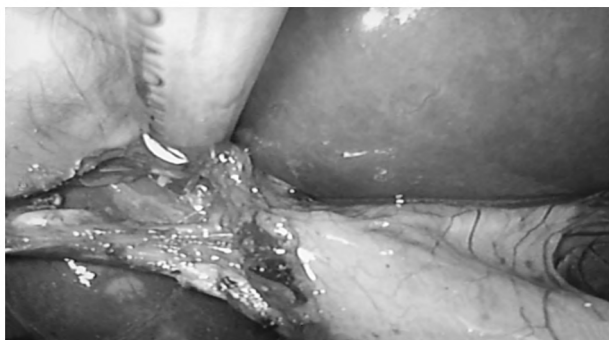

Fig. (1): Coagulation and cutting of cystic artery.

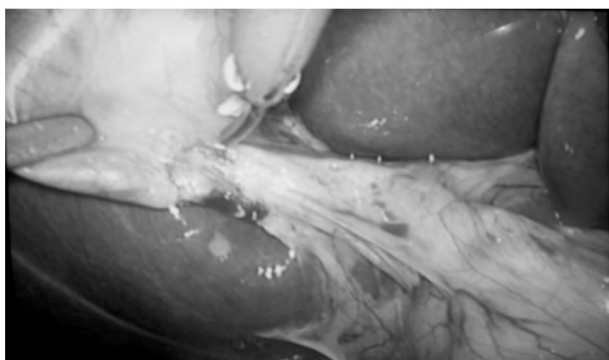


Fig. (2): Dissection of Calot's triangle.

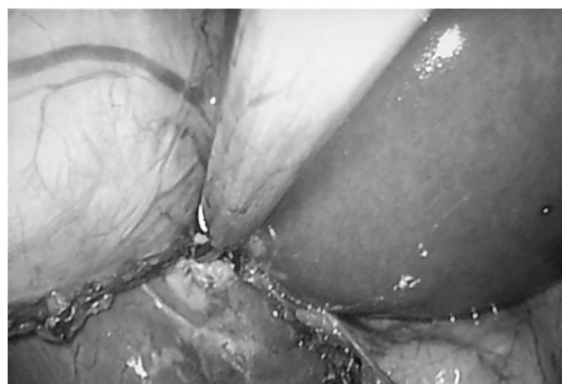

Fig. (3): Dissection of gall bladder from its bed.

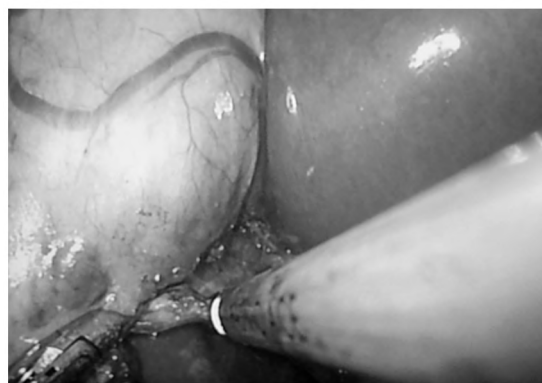

Fig. (4): Coagulation and cutting of cystic duct.



Fig. (5): Harmonic used for sealing and dissection of structures during operation.

Results

This was a randomized prospective study conducted on 100 patients admitted to the General Surgery Department at El-Zahraa University Hospital, Al-Azhar University and diagnosed as chronic calcular cholecystitis.

Pre-operative assessment of the patients:

The age of the patients of the study ranged between 32-55 years with a mean age of 43.5 ± 9.6

years (Table 1). 73 of the patients were females (73%) while 27 were males (27%) with a male to female ratio of 1:2.7 (Table 1).

Table (1): Demographic data of patients of the study.

Variable	Value
<i>Age (years):</i>	
Range	32-55 years
Mean ± S.D	43.5±9.6 years
<i>Sex:</i>	
Male (n, %)	27 (27%)
Female (n, %)	73 (73%)
Male to female ratio	1:2.7

Fifteen patients of the study (15%) had diabetes mellitus in association with gallstone, 28 patients (24%) had hypertension, 10 patients (10%) had ischemic heart disease and 40 patients (40%) had dyslipidemia and the statistical analysis revealed that there was no statistical significance difference between patients regarding associated medical problems (risk factors) (Table 2).

Table (2): Risk factors in patients of the studied group.

Risk factor	No	%	$\chi^2 - p$ -value
Diabetes mellitus	15	15	0.231 (NS)
Hypertension	28	28	
Ischemic heart disease	10	10	
Dyslipidemia	40	40	

Intraoperative assessment:

The operative time in patients of the study ranged between 40-105min with a mean operative time of 55.4±15.6min (Table 3).

Blood loss during the procedure in our patients ranged between 50-100ml with a mean volume of blood loss of 65 ± 12ml (Table 3).

Bleeding was from omentum and controlled by harmonic scalpel.

Table (3): Intraoperative assessment of patients of the studied group.

Variable	Range	Mean ± SD
Operative time	40-105	55.4±16.6
Blood loss	50-100	65±12

Intraoperative complications in our study were little and limited to gall bladder perforation in 3 cases (3%) while 1 case of our patients (1%) converted from laparoscopic to open cholecystectomy due to dense adhesion at calot's triangle with no statistical significance difference signifying any of them (Table 4).

Table (4): Intraoperative complications in patients of the studied group.

Risk factor	No	%	$\chi^2 - p$ -value
Bile duct injury	0	0	0.333 (NS)
Gall bladder perforation	3	3	
Conversion to open operation	1	1	

Post-operative course:

In our patients post-operative bleeding occur in two cases (2%) which was minimal and stopped spontaneously, wound infection in 3 patients (3%), bile leak was present in one case (1%), which stop spontaneously after 5 days, (Table 5).

Table (5): Post-operative complications in patients of the studied group.

Variable	No	%	$\chi^2 - p$ -value
Bleeding	2	2	0.462 (NS)
Wound infection	3	3	
Bile leak	1	1	

Early discharge "Day 1" occurred in 96 (96%) patient and 3 patients discharged on day 3 post-operatively (3%) and one patient (1%) in day 5 post-operative with significant difference in discharging cases in day one post-operatively ($p=0.021$) (Table 6). The total hospital stay ranged between 1-5 days with a mean period of 1.58 ±0.4 day (Table 6).

Table (6): Post-operative discharging day and total hospital stay in patients of the studied group.

Variable	No	%	$\chi^2 - p$ -value
<i>Post-operative discharge day:</i>			
Day 1	96	96	0.021 (S)
Day 3	3	3	
Day 5	1	1	
<i>Total hospital stay:</i>			
Range	1-5 days		
Mean ± S.D	1.58±0.4 day		

Discussion

Laparoscopic Cholecystectomy (LC) is the gold standard for the treatment of gallstone disease. Conventionally, during LC, titanium clips are used for sealing the cystic duct and the cystic artery before dividing them. There have been reports of clip dislodgement, which poses an increased risk of bile leakage [6].

While using electrocautery; there is excess smoke production and an increased risk of lateral tissue damage. Due to the transmission of energy

through the titanium clips, there is also an increased risk of gallbladder (GB) perforation. Slipped titanium clips also act as a nidus for stone formation. The harmonic scalpel can seal vessels of up to 5 mm thickness without an increased risk of leakage [7].

With the advent of minimally invasive surgery (laparoscopic surgery), undoubtedly, it's the cholecystectomy procedure which reaped maximum advantage by avoiding a subcostal incision thus bringing down morbidity remarkably. Statistics show that laparoscopic cholecystectomy is one of the commonly done elective surgeries probably due to increasing incidence of gallstone disease and more and more surgeons getting trained and acquainted with laparoscopy [8].

A key step in the performance of this surgery is the dissection of Calot's triangle to isolate cystic artery and cystic duct in order to divide these key structures safely. The division of cystic artery with power sources like bipolar coagulation and Harmonic Scalpel (HS) has been described. With the increased incidence of the procedure, even rare complications like clip migration are becoming more frequent. Consequently, this very commonly performed surgery has started to lure in litigations against surgeons. Thus, it is only reasonable to explore alternatives of clip for cystic duct closure. One of the simplest alternatives was use of HS [9].

The use of the harmonic scalpel in LC has been accepted by many surgeons. It is mainly used for the dissection of Calot's triangle and the lifting of the GB from the liver bed. However, the cystic duct and cystic artery are divided after the application of conventional clips due to a fear of cystic artery and cystic duct leakage. The harmonic scalpel, which seals up to 5mm thickness of luminal structures (vessels), can be used to divide both cystic duct and artery and has been shown as a safe method in a few studies [7].

The safety of the harmonic scalpel as a vessel-sealing device in a high-pressure system, such as the superior, inferior mesenteric arteries and veins, has already been established. Considering the fact that the biliary tract is a low-pressure system and the thickness of the cystic duct and artery is usually less than 5mm except in cases having previous cholecystitis/cholangitis episodes that lead to inflammatory changes, the harmonic scalpel can be safely used. The harmonic scalpel also produces less smoke and minimizes blood loss. There is also a decreased risk of GB perforation [10]. Harmonic scalpel is a multifunctional instrument. It replaces

four instruments routinely used in the laparoscopic cholecystectomy, namely, the dissector, clip applicator, scissors, and electrosurgical hook or spatula. Its use, therefore, prevents the frequent blind extraction and reinsertion of these different instruments with the subsequent avoidance of time loss.

Lastly activation of the Harmonic shear does not form smoke, although mist may be generated by vibration, therefore allowing the surgeon to work in a clear operative field throughout the operation, use of electrosurgery causes smoke formation in the abdominal cavity and decreases visibility. Moreover, smoke must be evacuated by opening the valves of the trocars, thus causing repeated loss of the pneumoperitoneum and a subsequent loss of time [11].

Effective sealing of the cystic-duct stump by the harmonic shears has been confirmed histologically by Huscher and colleagues [12].

All morphologic changes were found within 1.5mm of the cutting edge, and the airtight pressure of the sealed cystic duct was calculated to be higher than 320mmHg. Wise and fellows demonstrated that simple titanium clips applied to the cystic duct could not be displaced by a pressure of 300mm Hg [13].

However, the literature provides various examples of cystic-duct leakage due to inadequate closure of the duct due to mismatch of the clip arms, necrosis of the duct at the site of clipping, or slippage of the clips off the end of the duct and migration into the biliary tract [14].

Attri and his colleagues, [15], found in their study that the mean age was 41.4 years with a female predominance which was in agree with what we found in our results.

Nishant and his colleagues, [9], found in their study that the mean age was 42.66 years with a female predominance (90%) which run in lines with our results.

Dyslipidemia, hypertension, diabetes mellitus and ischemic heart diseases were the risk factors of gall stone disease in our group.

Intraoperatively; the operative time was about an hour which is decrease with the increase in experience in doing this procedure (improvement in the learning curve).

Venkatapuram and Sateesh, [8], found in their study that the operative time ranged between 70-80min which is prolonged than that in our cases

(55.4min); they said that the operative time was prolonged due to either the need for additional port or to convert to open cholecystectomy.

Operating time was significantly reduced with the use of Harmonic scalpel in LC as found by Jain and coworkers, (2011), 50 ± 9.36 and in the study of Kadil and his colleagues, (2010), 52.14 ± 9.8 both run in line with our results [16].

Also, Mahabaleshwar and his colleagues, (2012), and Mukesh and coworkers, [17], found an operative time near what we found in our results.

Rajnish and his colleagues, [7], in their study found that the operative time was 64.3 ± 8.5 which was longer compared with what we found in our results.

The blood loss during the procedure and is affected by the presence of adhesions and degree of inflammation in the felid.

In their studies, Jain and coworkers, [10] and Kandil and colleagues, [16], observed a significant reduction in blood loss which run in line with our results.

Also, Rajnish and his colleagues, [7], found in his study that there was no intraoperative bleeding or injury to adjacent structures was encountered which was in agreement with our results.

Comparing the additional cost incurred due to the use of the harmonic scalpel, the clinically insignificant blood loss carries a questionable advantage [7].

El-Mallah and his colleagues, [18], found in their study that the mean blood loss with the use of Harmonic scalpel was 64.2ml which run in line with what we found in our study.

Complications during the procedure were little in the form of gall bladder perforation and so the conversion rate to conventional open cholecystectomy was in a very minority of cases (1%).

Venkatapuram and Sateesh, [8], in their study found that the conversion rate was (2.5%) which disagree with our results.

The harmonic scalpel reduces the lateral thermal spread and decreases the risk of GB perforation. Kandil and colleagues, [16], showed that the risk of GB perforation was 7.1 % with the use of harmonic scalpel which is about double what we found in our results.

Mukesh and his coworkers, [19], found in their study that the use of harmonic scalpel didn't affect the incidence of gall bladder perforation as a complication during operation which conflicting with what we found in our results.

Mahabaleshwar and his colleagues, [17], found in their study that intraoperative complications increase the risk of GB perforation.

Also, Rajnish and his colleagues, [7], found a 20% incidence of gall bladder perforation which conflicting with what we found in our study and explained the reason due to the experience of surgeons and experience in handling conventional electrocautery and harmonic scalpel instruments.

El-Shoura and his colleagues, [20], found in their study that there was no incidence of conversion into open cholecystectomy in their group when use harmonic scalpel which disagree with our results, also, they found 9.3% incidence of gall bladder perforation which also conflicting with our results.

Attri and his colleagues, [15], found 6.2% gall bladder perforation intraoperatively which disagree with our results.

El-Mallah and his colleagues, [18], found in their study an incidence of 7.5% gall bladder perforation with the use of harmonic scalpel and no case of conversion into open cholecystectomy which conflicting with what we found in our study.

During the post-operative period bile leak was present in (1%) and wound infection in 3%.

The risk of SSI depends on various factors, such as duration of surgery, spillage of bile, intra-abdominal collection due to post-operative bile leak, retrieval of GB through the port, presence of drain, and comorbidities such as diabetes. Rajnish and his colleagues, [7], found in their study that 10% of patients with the use of harmonic scalpel had developed superficial SSI and both patients were diabetic which was triple the incidence we found.

Al-Shoura and his colleagues, [20], found 2.6% skin infection in his cases and 1.3% incidence of bile leak with the use of harmonic scalpel which run in lines with our results.

Wills and Crawford, [3], found in their study that the bile leak was present in 1.8% in patients of their study which was in agreement with what found in our results.

Attri and his colleagues, [15], found bile leak in 0.8% of their patients, 1.7% of patients had port site infection which run in lines with what we found in our results.

Most of the patients were discharged in the first post-operative day and the total hospital stay was very short (mean 1.58 day).

Attri and his colleagues, [15], found in their study that the mean total hospital stay was 1.42 days which was in agreement with what we found in our results.

Al-Shoura and his colleagues, [20], found in their study that the mean total hospital stay was 1.62 days which was in agreement with what we found in our results.

Huscher and colleagues [21] stated that the blades were first applied more proximally for a few seconds to achieve a simple sealing of the lumen, then they were applied a few millimeters distal to the previous application site, holding the grasp until the division of the duct was accomplished.

Conclusion:

The use of ultrasonic technology in the closure of the cystic duct has proven to be as safe and effective as the commonly used simple metal clips. Neither minor nor major bile leaks attributed to the use of ultrasonic technology were encountered throughout the study period. The use of ultrasonic technology in the laparoscopic cholecystectomy provides a superior alternative to the currently used high frequency monopolar technology, as it is associated with a shorter operative time, lower incidence of gall bladder perforation, better control of oozing from dissected tissue allowing the surgeon a clearer discrimination of anatomy, lower incidence of biliary leak and shorter hospital stay.

References

- 1- LEE M.K. and VOLLMER C.M.: Postcholecystectomy problems. In Jarnagin, W.R. (ed.). Blumgart's Surgery of the Liver, Biliary Tract and Pancreas. 6th ed. Philadelphia: Elsevier, p.p. 633-41, 2017.
- 2- HARIBHAKTI S.P. and MISTRY J.H.: Techniques of laparoscopic cholecystectomy: Nomenclature and selection. *J. Minim. Access. Surg.*, 11 (2): 113-8, 2015.
- 3- WILLS E. and CRAWFORD G.: Clipless Versus Conventional Laparoscopic Cholecystectomy. *J. Laparoendosc Adv. Sur. Tech.*, 23 (3): 237-9, 2013.
- 4- SWANSTROM L.L.: "Clipless" cholecystectomy: Evolution marches on, even for lap chole. *World J. Surg.*, 35: 824-5, 2011.
- 5- KAVLAKOGLU B., PEKICICI R. and ORAL S.: Clipless cholecystectomy: Which sealer should be used? *World J. Surg.*, 35: 817-23, 2011.
- 6- VAN DIJK A.H., VAN ROES SEL S., De REUVER P.R., et al.: Systematic review of cystic duct closure techniques in relation to prevention of bile duct leakage after laparoscopic cholecystectomy. *World J. Gastrointest. Surg.*, 10 (6): 57-69, 2018.
- 7- RAJNISH K., SURESHKUMAR S., ALI M.S., et al.: Harmonic Scalpel-Assisted Laparoscopic Cholecystectomy vs. Conventional Laparoscopic Cholecystectomy-A Non-randomized Control Trial. *Cureus*, 10 (1): e2084-e2093, 2018.
- 8- VENKATAPURAM M.R. and SATEESH S.: Control of cystic artery during laparoscopic cholecystectomy: Clips versus ultrasonic energy devices which is better? *Int. Surg. J.*, 4: 3844-8, 2017.
- 9- NISHANT K., BHUTIA P., SINGH V.K., et al.: Can Clipless Division of Cystic Duct be Performed Safely Using Harmonic Scalpel? *J. Clin. Diag. Res.*, 13 (6): PC01-PC04, 2019.
- 10- JAIN S.K., TANWAR R., KAZA R.C., et al.: A prospective randomized study of comparison of clipless cholecystectomy with conventional laparoscopic cholecystectomy. *J. Laparoendosc. Adv. Surg. Tech.*, 21: 203-8, 2011.
- 11- RAMOS A.C., RAMOS M.G., GALVÃO-NETO M.P., et al.: Total clipless cholecystectomy by means of harmonic sealing. *ABCD. Arquivos Brasileiros de Cirurgia Digestiva*, 28: 53-6, 2015.
- 12- HUSCHER C.G., LIRICI M.M., Di PAOLA M., et al.: Laparoscopic cholecystectomy by ultrasonic dissection without cystic duct and artery ligation. *Surg. Endosc.*, 17: 442-51, 2007.
- 13- WISE UNGER S., GLICK G.L. and LANDEROS M.: Cystic duct leak after laparoscopic cholecystectomy. A multi-institutional study. *Surg. Endosc.*, 10: 1189-93, 1996.
- 14- REIS L.D.: Surgical clips incorporated into a duodenal ulcer: A rare complication after elective laparoscopic cholecystectomy. *Endoscopy*, 32 (1): S3, 2004.
- 15- ATTRI M.R., KUMAR I.A., MIR I.N., et al.: Clipless laparoscopic cholecystectomy: Our experience. *Intl. J. Contemp. Med. Res.*, 6 (5): E44-E46, 2019.
- 16- KANDIL T., NAKEEB A.E. and HEFNAWY E.E.: Comparative study between clipless laparoscopic cholecystectomy by harmonic scalpel versus conventional method: A prospective randomized study. *J. Gastrointest. Surg.*, 14: 323-8, 2010.
- 17- MAHABALESHWAR V., KAMAN L., IQBAL J., et al.: Monopolar electrocautery versus ultrasonic dissection of the gallbladder from the gallbladder bed in laparoscopic cholecystectomy: A randomized controlled trial. *Can. J. Surg.*, 55: 307-11, 2012.
- 18- EL-MALLAH S.I., SOLTAN H., ABDO ZAID N., et al.: Comparative study between the conventional laparoscopic cholecystectomy and clipless cholecystectomy using a harmonic scalpel. *Menoufia Med. J.*, 28: 54-61, 2015.

- 19- MUKESH K.S., VIJAYATA S., MOHINDER K.G., et al.: Triple ligation technique of clipless laparoscopic cholecystectomy: A spanner especially for complicated cholecystitis. Int. J. Adv. Med., 4: 1358-63, 2017.
- 20- EL-SHOURA A.A., SABER S.A. and EL-SHORA O.A.: Efficacy of harmonic scalpel in total clipless laproscopic cholecystectomy. Int. J. Med. Res. Health Sci., 5 (2): 29-35, 2016.
- 21- HUSCHER C.G., LIRICI M.M., Di PAOLA, M., et al.: Laparoscopic cholecystectomy by ultrasonic dissection without cystic duct and artery ligation. Surg. Endosc., 17: 442-51, 2007.

إستئصال المرارة بالمنظار بدون إستخدام الدبابيس وبإستخدام مشرط الموجات الصوتية النشطة

تعتبر حصوات المرارة من أكثر أمراض الجهاز المرارى شيوعاً ونسبة حدوثها تتراوح بين ١٠٪ إلى ١٥٪ معظم من السيدات ومعظمها لا ينتج عنها أعراض.

ويعد المنظار الجراحى هو الحل الأمثل لإستئصال المرارة فى المرضى الذين يعانون من أعراض حصوات المرارة.

ويتم إستئصال المرارة بالمنظار الجراحى عن طريق إستخدام بعض الآلات الخاصة مثل الخطاف الكهربائى والمقص التشرىحى أو إستخدام تكنولوجيا التردد العالى أحادى القطب وربط القناة والشريان المرارى بإستخدام المشبك المعدنى إلا أن بعض التقارير أشارت إلى حدوث إصابات للأنسجة ومضاعفات مع إستخدام هذه الآلات.

ولقد صمم مشرط الموجات النشطة الهارمونك كأداة آمنة بديلة للكى الكهربائى لتشريح الأنسجة وتم إستخدامه فى الأغراض الطبية منذ نحو عشر سنوات.

وهذه الطريقة المبتكرة كان لها العديد من المميزات مثل تقليل الحرارة والدخان الناتج عن الكى الكهربائى التقليدى وتقليل إصابة الأنسجة وتقصير وقت العملية.

وقد أجريت هذه الدراسة على ١٠٠ مريض يعانون من حصوات بالحويصلة المرارية وتم فيها إستخدام مشرط الموجات الصوتية النشطة الهارمونيك كبديل لجهاز الكى الكهربائى والدبابيس حيث إستخدم مشرط الموجات الصوتية النشطة الهارمونيك لغلق وقطع كلا من قناة المرارة وشريان المرارة وفصلها عن الكبد دون الحاجة لآى آلة أخرى.

لم يحدث أى مضاعفات من إستخدام مشرط الموجات الصوتية النشطة الهارمونيك ووجدنا أنه بديل آمن وفعال وأكثر تفوقاً من حيث قصر مدة الجراحة وأقل فى معدل حدوث ثقب فى المرارة وتحسين السيطرة على الدخان مما يسمح للجراح برؤية أكثر وضوحاً وقصر مدة الإقامة بالمستشفى.