

Hybrid Approach as a Bailout for Treatment of Combined Iliac and Common Femoral Artery Lesions: "Is It Fit for Purpose?"

EL-SAYED A. ABD EL-MABOOD, M.D.*,** and AHMED FOUAD AHMED, M.D.*

The Department of General Surgery, Benha University* and Vascular Surgery Department, Benha Insurance Hospital**

Abstract

Background: Open surgery of multilevel lower limb arterial disease has high morbidity. For treatment of such complex anatomy; Hybrid technique can provide durable and less invasive procedures tailored to medically high risk patients.

Aim of Study: To evaluate hybrid management of symptomatic combined iliac and common femoral artery lesions.

Patients and Methods: Prospective study was performed on 26 cases with symptomatic combined iliac and common femoral artery lesions. Hybrid approach was performed for all patients; open surgery for common femoral artery lesions and endovascular interventions for other lesions. Follow-up was 12 months.

Results: All patients passed uneventful intra-operative course without technical failure; After the first month, primary patency was reported in 26 patients (100%) and limb salvage in 24 cases (92.3%). After 6 months; primary patency was observed in 24 cases (92.3%) and limb salvage in 22 patients (84.6%). After 12 months; primary patency was noticed in 18 patients (69.3%) and limb salvage in 20 patients (76.9%). Secondary patency was restored in 6 patients (23.1%).

Conclusions: Hybrid approach; endovascular intervention for iliac and/or infrainguinal arterial lesions as an adjunct to open surgical repair of common femoral artery lesions, play a great role as a bailout for treatment of symptomatic combined iliac and common femoral artery lesions with satisfactory patency and limb salvage rates and allow effective, minimal invasive and durable therapeutic options especially in high risk patients.

Key Words: Hybrid management – Combined aortoiliac and common femoral artery lesions – Outcomes.

Introduction

ENDOASCULAR intervention is used for short simple arterial lesions in multilevel lower limb occlusive disease while surgery is used in long lesions. Hybrid approach was first documented in early 1990s for multilevel lesions [1,2].

Correspondence to: Dr. El-Sayed A. Abd El-Mabood, The Department of General Surgery, Benha University and Vascular Surgery Department, Benha Insurance Hospital

Hybrid surgery is standard for multilevel lower limb arterial disease, Examples of multilevel revascularization are common femoral artery endarterectomy and iliac artery stenting or infrainguinal bypass started below iliac artery or superficial femoral artery (SFA) stenting. These interventions are carried out in one stage, despite every case anatomy has a role in deciding of single stage or more than one stage intervention [2-5].

Endovascular procedure has less peri-procedural morbidity and mortality so it is increasingly used to treat arterial occlusive disease in many countries; Peripheral Arterial Disease (PAD) is increasingly treated by physicians who cannot offer surgical intervention [6-9].

Endovascular treatment options become the first-line management of lower limb PAD in many instances with improved ankle to brachial index in these patients. Balloon angioplasty and stents expand the scope of patients who are eligible for treatment of arterial occlusive disease. Several newer techniques are developing that substantially increase the spectrum of treatment options. Endovascular techniques are most useful in high risk cases for open surgery and especially in focal short segment disease [10-12].

Selection of best way of revascularization of (PAD) depends on balance between risk and durability [13,14].

Complicated common femoral artery (CFA) aneurysm is another problem that can be treated using hybrid technique; open surgery to excise common femoral artery aneurysm and repair by interposition graft followed by endovascular intervention to manage associated proximal and distal occlusive lesions [15].

Aim of the study to assess hybrid approach as a bailout for treatment of symptomatic combined iliac and CFA lesions.

Patients and Methods

The current study was performed after approval from local ethical committee of Benha University and Benha Insurance Hospitals and obtaining written fully informed patients consent. Patients undergoing treatment by hybrid approach for symptomatic combined iliac and common femoral artery lesions, at the Vascular Surgery Department, Benha University and Benha Insurance Hospitals were included in this study from March 2016 till March 2020; the enrollment duration was 3 years and follow-up duration was 1 year.

This prospective study was conducted on 26 cases with symptomatic combined iliac and CFA lesions. All cases underwent detailed clinical evaluation, laboratory assessment, Arterial Duplex, CT Angiography scan and cardiac assessment by echo Doppler. Hybrid approach was performed for all patients; open surgery for common femoral artery lesions and endovascular interventions for other lesions.

Patients included in this study were suffering from symptomatic combined iliac and common femoral artery lesions; Target lesions have $\geq 60\%$ stenosis or Chronic Total Occlusion (CTO), Rutherford class (3 to 6) and fit for regional anesthesia.

But patients excluded from this study who were suffering from Failed lesion crossing, Arteritic lesions, Thrombophilia, Life expectancy < 1 year, If there were contraindications of contrast, Cerebral Vascular Disease (CVD); who require interventional management first, Inability to comply with the follow-up schedule (as mental disability) or Patient has had prior ipsilateral bypass or endarterectomy.

Procedure:

Patients were admitted one day before the intervention and were given 300 mg loading dose of oral clopidogrel at least 1 day before or during the procedure. All interventions were done in angio suite (Philips; Allura X per FD 20/722028164), C-arm image intensifier with road mapping was used. Patients were placed in supine position. Both groins were prepared using antiseptic solution povidone iodine (10%). Hybrid approach was performed under Spinal anesthesia for open surgery of common femoral artery lesions and local anesthesia for endovascular interventions for other lesions femoral.

The femoral vessels were exposed first through longitudinal or oblique incisions. The proximal extent of dissection was circumferential control of distal external iliac artery and extended distally to include circumferential control of proximal SFA and profunda femoris arteries.

Then the endarterectomy began in CFA, after division and ligation of veins crossing anterior surface of profunda femoris artery, femoral arteriotomy was performed beyond the posterior atheroma tongue extending a variable distance into the first or second part of profunda femoris artery. Tacking sutures may be carried out at the distal endpoint and arteriotomy was closed with a vein or synthetic patch. This patch was used to serve as access for further endovascular intervention of other lesions.

Access to the target iliac lesion was done by transbrachial puncture with using long sheath (better) or retrograde ipsilateral common femoral artery puncture through the patch or contralateral femoral puncture and performing a crossover technique. But Access to the target distal lesion was done by antegrade ipsilateral common femoral artery puncture through the patch.

Angiography was done to confirm data obtained preoperatively using nonionic low osmolar dye diluted to 50% with normal saline. Iliac and distal lesions were identified. A guidewire was positioned through the lesion; a 0.035 hydrophilic guide wire (standard type; (Terumo, Tokyo, Japan) for stenosis and stiff type; (Terumo, Tokyo, Japan) for CTO supported by an angled-tip angiographic catheter (Bernstein 4F or 5F) (Merit Medical, South Jordan, Utah, U.S.A.).

Then a balloon catheter (Admiral xtreme, Invatec S.p.A. Roncadelle (BS), Italy) of suitable diameter (3mm for tibial, 4 or 5mm for popliteal, 5 or 6mm for SFA, 7mm for EIA or 8 or 9mm for CIA) and length, was introduced over the wire to the distal extent of the lesion. The balloon was inflated till any waist has been abolished then deflated and should be re-inflated with overlaps until the whole lesion had been dilated. The inflation time was standardized; 3 minutes with heparinized saline injection after deflation. The balloon was withdrawn completely. Angiography was done to assess the result.

Then in patients of associated iliac lesions, routine stenting was done using (Visi-Pro, balloon-expandable peripheral stent system 7-9mm according to target lesion diameter) (ev3, Plymouth, MN,

U.S.A.) stents. But in patients of SFA stenotic lesions, Indications for stenting were Elastic recoil (If the balloon was inflated fully, but the stenosis persists), A flow-limiting dissection (If prolonged balloon inflation was performed but the dissection persists). So stent (Protégé Everflex self-expanding stent 5 or 6mm) (ev3, Plymouth, MN, U.S.A.) insertion was done selectively as a bailout.

The stent diameter and length were selected according to baseline CT scan estimate. The stent should cover the lesion and 2 to 5mm of normal artery proximally and distally. Stents were deployed at least 1cm below origin of profunda femoral artery and 3cm above upper border of intercondylar fossa of femur.

Associated popliteal and tibial lesions were treated only by routine angioplasty. The technical result was assessed by digital subtraction angiography. Manual compression was applied for (number of sheath multiplied by 3 minutes (6F X 3=18) and mobilization was delayed for 6-12 hours.

Post-operative follow-up:

I- Medications: All patients were maintained on dual anti-platelet agents (acetyl salicylic acid 75mg forever) and (clopidogrel 75mg for at least 2 months). If patients were in need for oral anti-coagulant, aspirin only was added. Cases underwent foot care comprising dressings, minor debridement, limited amputations [up to transmetatarsal amputation (TMA)] and appropriate footwear.

II- Schedule: Clinical follow-up consisted of assessment of pulse and healing of ulcer or amputation site or infection resolution. Clinical outcomes, patency rates and complications following the procedure were reported. All patients were re-examined after one week to check for access site and operative bed complications and to confirm patency. All patients were followed for one year with regular visits at 1,6 and 12 months. Follow-up was in the form of clinical examination and duplex US ± CT angiography if needed in cases of absent or diminished pulse or recurrence of symptoms.

Statistical analysis: Data were analyzed using SPSS version 16 soft ware (Spss Inc, Chicago, ILL Company) and Microstat W software (India, CNET Download.com). Means of continuous variables were compared by appropriate parametric or non parametric tests. Categorical variables were compared using Chi Squared test or the Fischer exact test. Results are expressed as medians, percentages and as means ± SD.

Results

The study was performed on 26 cases of symptomatic combined iliac and common femoral artery lesions. The mean age was 62.4±7.31 (52-74) years old; 12 patients (46.2%) were between 56-60 years old and 18 patients (69.3%) were males. Most patients 14 (53.8%) were ASA II. Table (1).

Table (1): Patients' demographic data.

Data		Findings Number (%)
Age (years)	Strata	
	50-55	6 (23.1%)
	56-60	12 (46.2%)
	>60	8 (30.7%)
		62.4±7.31 (52-74)
Gender	Females	8 (30.7%)
	Males	18 (69.3%)
American Society of Anesthesiologists grade (ASA):	ASA I	8 (30.7%)
	ASA II	14 (53.8%)
	ASA III	4 (15.4%)

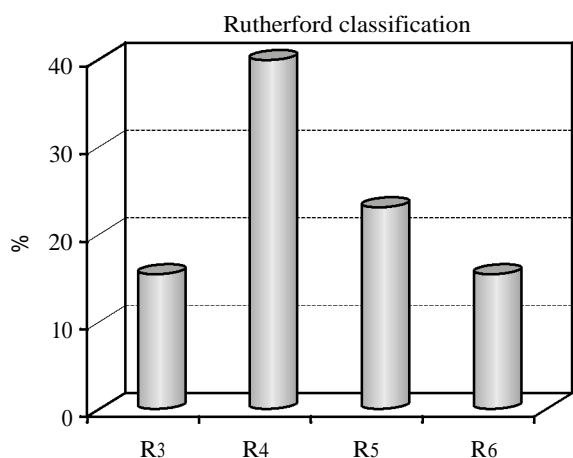
Data are presented as numbers; percentages & ranges are in parenthesis.

By giving concern to risk factors; smoking was observed in 20 patients (76.9%) and near half the patients clinically presented by ischemic rest pain (R5) in 12 patients (46.2%) depending on Rutherford classification. Duration of symptoms (weeks) was 3.96±2.32 (3-6). Table (2), Graph (1).

Table (2): Risk factors and clinical presentation (Rutherford category).

Data		Findings Number (%)
Risk factors & co-morbidities	Diabetics	16 (61.4%)
	Hypertensive	10 (38.4%)
	Smokers	20 (76.9%)
	Hyperlipidemia	18 (69.3%)
Clinical presentation (Rutherford category)	R3: Severe claudication	4 (15.4%)
	R4: Ischemic rest pain	12 (46.2%)
	R5: Minor tissue loss, ulceration	6 (23.1%)
	R6: Major tissue loss, gangrene.	4 (15.4%)
Duration of symptoms (weeks)		3.96±2.32 (3-6)

More than one risk factor & co-morbidity was observed in one patient. Data are presented as numbers; percentages & ranges are in parenthesis.



Graph (1): Risk factors and clinical presentation (Rutherford category).

As regard to lesion characteristic; all patients had common femoral artery occlusion. In addition to another associated lesions; iliac and/or superficial femoral artery (SFA) lesions mainly stenosis in 14 cases (53.8%) and 8 patients (30.7%) respectively. Table (3).

Table (3): Lesion characteristics.

Data		Findings Number (%)
Common femoral artery lesions	Occlusion	26 (100%)
Associated lesions	<i>Iliac artery:</i>	
	Occlusion	6
	Stenosis	14
	Total	20 (76.9%)
	<i>SFA:</i>	
	Occlusion	2
	Stenosis	8
	Total	10 (38.4%)
	<i>Popliteal artery:</i>	
	Occlusion	2
	Stenosis	4
	Total	6 (23.1%)
	<i>Tibial arteries:</i>	
Single vessel	2 (7.8%)	
Two vessels	16 (61.4%)	
Three vessels	8 (30.7%)	

More than one associated lesion was observed in one patient. Data are presented as numbers; percentages & ranges are in parenthesis.

All patients passed uneventful intra-operative course without technical failure; Common femoral artery lesions were treated by endarterectomy and patch closure in addition to iliac artery stenting through antegrade (cross over or brachial) or retrograde access. Superficial femoral artery (SFA) lesions were treated either by Stenting in 8 patients

(30.7%) or Femoropopliteal bypass in two patients (7.8%) but all Popliteal and infrapopliteal lesions were treated by Angioplasty. Table (4).

Table (4): Operative data.

Data		Findings Number (%)
Common femoral artery lesions	Endarterectomy + patch closure	26 (100%)
Associated lesions	Iliac Angioplasty and Stenting	20 (76.9%)
	<i>SFA:</i>	
	Angioplasty ± Stenting	8 (30.7%)
	Femoropopliteal bypass	2 (7.8%)
	Popliteal Angioplasty	6 (23.1%)
	Tibial Angioplasty	4 (15.4%)

More than one procedure was observed in one patient. Data are presented as numbers; percentages & ranges are in parenthesis.

There was no procedure related mortality during. After the first month, primary patency was reported in 26 patients (100%) and limb salvage was achieved in 24 cases (92.3%) because a case had above knee amputation due to spreading infection despite successful revascularization thus decreasing the overall success rate. Debridement procedures and foot sparing amputations (Toe and Ray amputation) were done for 6 patients (23.1 %).

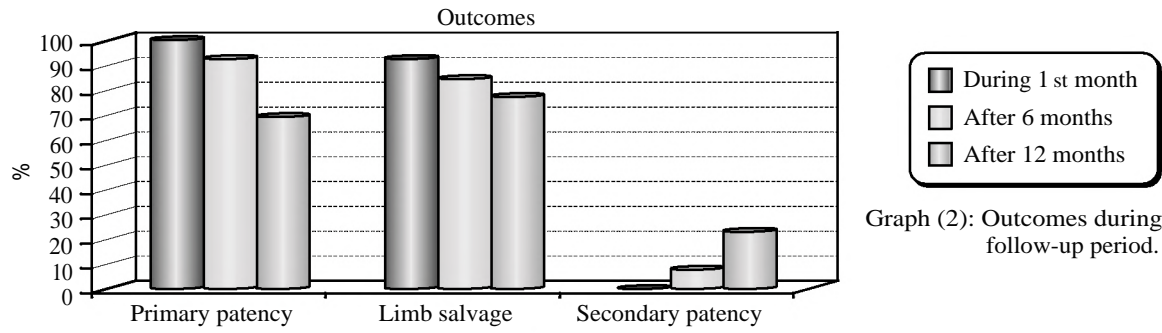
After 6 months; primary patency was found in 24 cases (92.3%) and limb salvage in 22 patients (84.6%); this was due to acute thrombosis of popliteal and infrapopliteal arteries; a trial of thrombolytic therapy was applied to restore patency but it was unsuccessful and below knee amputation was done.

After 12 months; primary patency was noticed in 18 patients (69.3%) and limb salvage in 20 patients (76.9%). Secondary patency was restored in 6 patients (23.1 %) by SFA stenting in two patients and femoropopliteal bypass in four patients. During SFA stenting; thrombosis with trash was observed and these patients had above knee amputation. Table (5), Graph (2).

Table (5): Outcomes during the follow-up period.

Outcomes	Primary patency N (%)	Limb salvage N (%)	Secondary patency N (%)
During 1 st month	26 (100%)	24 (92.3%)	0 (0%)
After 6 months	24 (92.3%)	22 (84.6%)	2 (7.8%)
After 12 months	18 (69.3%)	20 (76.9%)	6 (23.1%)

Data are presented as numbers; percentages & ranges are in parenthesis.



Graph (2): Outcomes during the follow-up period.

These all data were shown in the following pictures:

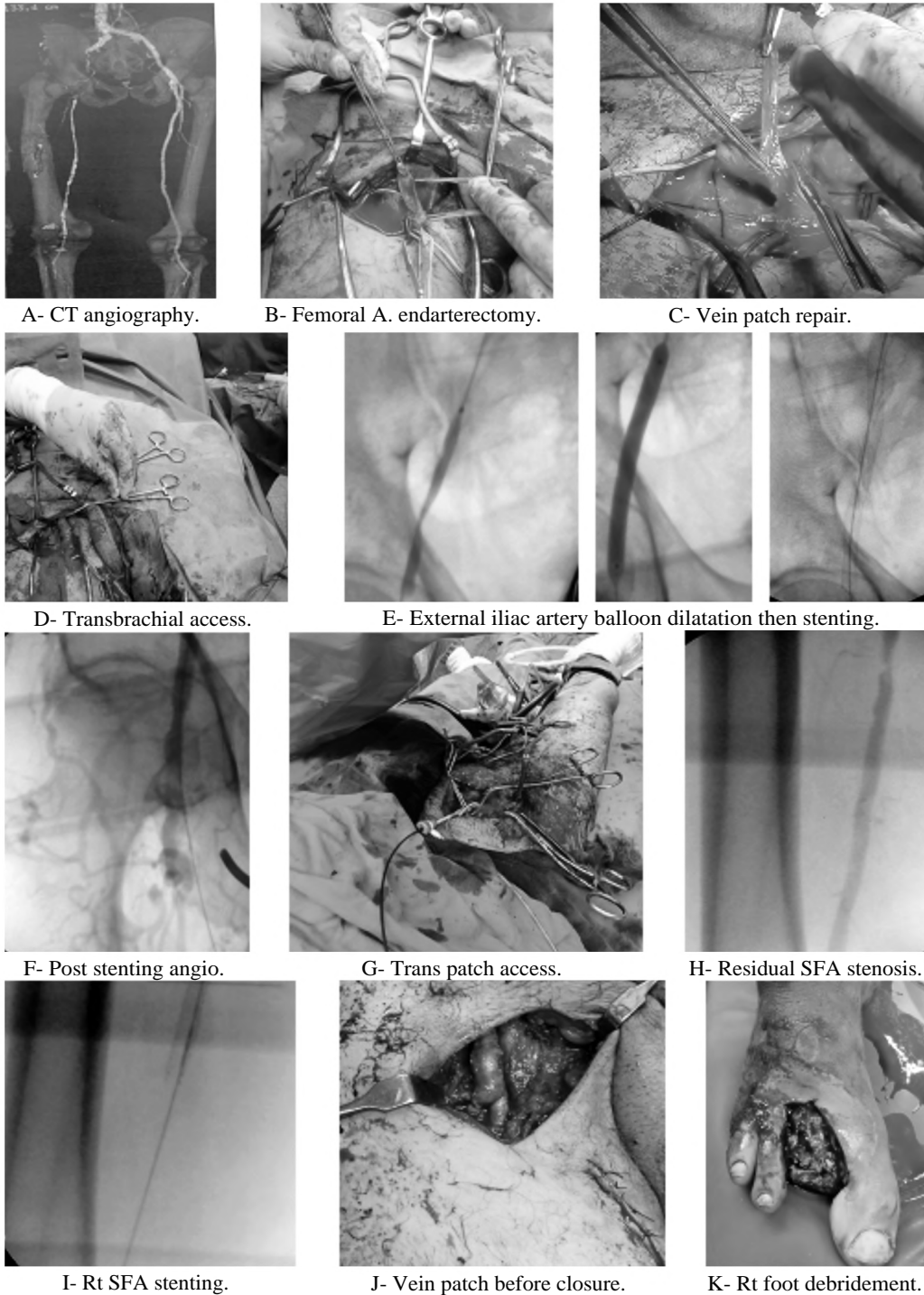


Fig. (1): Steps of hybrid approach of Rt L.L. multilevel lesions.

Discussion

Open surgery of multilevel lower limb arterial disease has high morbidity. For treatment of such complex anatomy; Hybrid technique can provide durable and less invasive procedures tailored to medically high risk patients [5].

The study was performed on 26 cases of symptomatic combined aortoiliac and common femoral artery lesions. The mean age was 62.4 ± 7.31 (52-74) years old; 12 patients (46.2%) were between 56-60 years old; these results were comparable to that mentioned by Zou et al. [16]; Mean age of their cases was 69.2 years (range, 49-88). Aging is very strong risk factor for PAD [17-19].

In this study; 18 patients (69.3%) were males; as reported by Zou et al. [16]; who examined gender in 40 patients having multilevel lower limb ischemia including femoral bifurcation and found similar result 27 patients (67.5%) were men. But less than that observed by Joh et al. [5]; male to female ratio in 76 patients was 67:9 (88.2%); this depends upon the fact that men are heavy smokers.

By Giving concern to risk factors; smoking was observed in 20 patients (76.9%); Smoking is the most dangerous risk factor for progression of PAD and more likely to require amputation or vascular intervention. This was comparable to Zou et al. [16] and Chen et al. [20] study; (67%) and (78.9%) respectively. But more than mentioned by Joh et al. [5]; (33.3%).

The indications of revascularization; near half the patients of the current study clinically presented by ischemic rest pain (R5) in 12 patients (46.2%); it was found that they were near similar to study done by Joh et al. [5]; 10/21 patients (47.6%) of his hybrid group complained rest pain. But they were more than a study on 40 patients done by Zou et al. [16] who reported in his study; rest pain in (28%), tissue loss in (36%) and claudication in (36%).

CFA lesions were managed by endarterectomy and patch closure in addition to iliac artery stenting and/or SFA lesions were treated either by Stenting or Femoropopliteal bypass in two patients (7.8%) but all Popliteal and infrapopliteal lesions were treated by Angioplasty. This complex repair is similar to study done by Dosluoglu et al. [21] who describes the double PAGA (prearteriotomy guidewire access) procedure where inflow and outflow diseases are crossed with wire after femoral vessel exposure but before endarterectomy. Endovascular repair was performed 1st to manage

both inflow and outflow lesions then proceeding to finish by femoral endarterectomy. Also this complex repair was evaluated by Cotroneo et al. [22]; they carried out femoral endarterectomy and/or bypass repair concomitant with endovascular intervention for both inflow and outflow [23].

Femoral artery open endarterectomy has low morbidity and high patency, and can be performed together with any other endovascular intervention. Many studies stated that endarterectomy at the level of the FB is effective and durable procedure [16,24].

In femoral endarterectomy; femoral arteriotomy was performed beyond the atheromatous plaque of profunda femoris artery; this is due to correction of significant profunda femoris artery disease at the time of femoral endarterectomy is clinically important; adequate profunda femoris artery perfusion acts as the backdoor to delay appearance of severe recurrent limb ischemia [25].

As regard to post intervention outcomes; there was no procedure related mortality. Primary patency was reported in 26 patients (100%), 24 patients (92.3%) and 18 patients (69.3%) After the first month, 6 months and 12 months respectively. This outcome was near similar to that reported by Zou et al. [16]; the primary patency rate at 12 months was (64%) and Matsagkas et al. [26]; the primary patency rate after the first month in 37 patients was (97.3%). Limb salvage rate was mentioned in the current study in 12 patients (92.3%), 11 patients (84.6%) and 10 patients (76.9%) After the first month, 6 months and 12 months respectively. This result was less than that mentioned in the study 60 patients done by Antoniou et al. [27] who observed limb salvage was (90%) at 6 months and Matsagkas et al. [26]; who reported limb salvage was (94.6%) at 12 months. Secondary patency in this study was restored in 6 patients (23.1%) so secondary patency rate was (76.9%) at 12 months which was near similar to Zou et al. [16]; who mentioned secondary patency rate at 12 months was (78%).

The hybrid procedure has several benefits; No delay in complete vascular repair of affected limb, short hospital stay and no access site complications because target artery is approached through the operative field [28].

Conclusions: Hybrid approach; endovascular intervention for iliac and/or infrainguinal arterial lesions as an adjunct to open surgical repair of common femoral artery lesions, play a great role as a bailout for treatment of symptomatic combined iliac and CFA lesions with satisfactory patency

and limb salvage rates and allow effective, minimal invasive and durable therapeutic options especially in high risk patients.

References

- 1- NELSON P.R., POWELL R.J. and SCHERMERHORN M.L.: Early results of external iliac artery stenting combined with common femoral artery endarterectomy. *J. Vasc. Surg.*, 35: 1107-1113, 2002.
- 2- DOSLUOGLU H.H. and CHERR G.S.: Pre-arteriotomy guidewire access (PAGA). A crucial maneuver for securing inflow and/or outflow in patients with bulky iliofemoral occlusive disease undergoing combined (open / endovascular) procedures. *Eur. J. Vasc. Endovasc. Surg.*, 32: 97-100, 2006.
- 3- TIMARAN C.H., PRAULT T.L. and STEVENS S.L.: Iliac artery stenting versus surgical reconstruction for TASC (TransAtlantic Inter Society Consensus) type B and type C iliac lesions. *J. Vasc. Surg.*, 38: 272-278, 2003.
- 4- SCHANZER A., OWENS C., CONTE M. and BELKIN M.: Superficial femoral artery percutaneous intervention is an effective strategy to optimize inflow for distal origin bypass grafts. *J. Vasc. Surg.*, 45: 740-743, 2007.
- 5- JOH H., JOO S. and PARK H.: Simultaneous hybrid revascularization for symptomatic lower extremity arterial occlusive disease in *Experimental and Therapeutic Medicine*, 7: 804-810, DOI: 10.3892/etm.2014.1513, 2014.
- 6- JONES W., DOLOR R. and HASSELBLAD V.: Comparative effectiveness of endovascular and surgical revascularization for patients with peripheral artery disease and critical limb ischemia: Systematic review of revascularization in critical limb ischemia. *Am. Heart J.*, 167 (4): 489-498 [e487], 2014.
- 7- MELTZER A., SEDRAKYAN A., ISAACS A., CONNOLLY P., SCHNEIDER D. and Vascular Study Group of Greater New York: Comparative effectiveness of peripheral vascular 4884 intervention versus surgical bypass for critical limb ischemia in the Vascular Study Group of Greater New York. *J. Vasc. Surg.*, 64 (5): 1320-1326.e2, 2016.
- 8- ABU DABRH A., STEFFEN M. and ASI N.: Bypass surgery versus endovascular interventions in severe or critical limb ischemia. *J. Vasc. Surg.*, 63 (1): 244-253.e11, 2016.
- 9- PATEL S., BIASI L. and PARASKEVOPOULOS I.: Comparison of angioplasty and bypass surgery for critical limb ischemia in patients with infrapopliteal peripheral artery disease. *Br. J. Surg.*, 103 (13): 1815-1822, 2016.
- 10- MEHAFFEY J., HAWKINS R. and FASHANDI A.: Lower extremity bypass for critical limb ischemia decreases major adverse limb events with equivalent cardiac risk compared with endovascular intervention. *J. Vasc. Surg.*, 66 (4): 1109-1116.e1, 2017.
- 11- DARLING J.D., McCALLUM J.C. and SODEN P.A.: Results for primary bypass versus primary angioplasty/stent for lower extremity chronic limb-threatening ischemia. *J. Vasc. Surg.*, 66 (2): 466-475, 2017.
- 12- DANIEL G., TIMUR P. and JESSICA M.: Percutaneous angioplasty with or without stenting for lower extremity occlusive disease in current therapy in vascular surgery and endovascular surgery 5th ed. By Stanley et al., 2 (5): 537-539, 2014.
- 13- ADAM D., BEARD J. and CLEVELAND T.: Bypass versus angioplasty in severe ischemia of the leg (BASIL): Multicentre randomized controlled trial. *Lancet*, 2: 23-36, 2008.
- 14- NORGREN L., HIATT W., DORMANDY J. and TASC II Working Group: Inter-society consensus for the management of peripheral arterial disease. *Int. Angiol.* Jun., 26 (2): 81-97, 2007.
- 15- BAKOYIANNIS C.N., TSEKOURAS N.S., ECONOMOPOULOS K.P. and BASTOUNIS E.A.: A hybrid approach using a composite endovascular and open graft procedure for a symptomatic common femoral aneurysm extending well above the inguinal ligament. *J. Vasc. Surg.*, 48: 461-4, 2008.
- 16- ZOU J., XIA Y., YANG H., MAI H. and ZHANG X.: Hybrid Endarterectomy and Endovascular Therapy in Multilevel Lower Extremity Arterial Disease Involving the Femoral Artery Bifurcation. *Int. Surg.*, 97: 56-64, 2012.
- 17- MATTHEW A. and ANDREW W.: *Infrainguinal Disease, Endovascular Therapy; Rutherford's vascular surgery and endovascular therapy 9th by Anton N.S. and Bruce A.P.; Printed in China*, 2 (110): 4839-4, 2018.
- 18- NEHLER M., DUVAL S. and DIAO L.: Epidemiology of peripheral arterial disease and critical limb ischemia in an insured national population. *J. Vasc. Surg.*, 60 (3): 686-695.e682, 2014.
- 19- DIEHM C., KAREEM S. and LAWALL H.: Epidemiology of peripheral arterial disease. *VASA Zeitschrift fur Gefasskrankheiten*, 33 (4): 183-189, 2004.
- 20- CHEN T., HUANG C. CHEN P., LEE C. SHIH C. and CHEN M.: Endovascular and Hybrid Revascularization for Complicated Aorto-Iliac Occlusive Disease: Short-Term Results in Single Institute Experience. *Acta Cardiol. Sin.*, 34: 313-320; Doi: 10.6515/ACS.201807-34(4).20180301A, 2018.
- 21- DOSLUOGLU H., LALL P. and CHERR G.: Role of simple and complex hybrid revascularization procedures for symptomatic lower extremity occlusive disease. *J. Vasc. Surg.*, 51: 1425-1435.e1, 2010.
- 22- COTRONEO A., IEZZI R. and MARANO G.: Hybrid therapy in patients with complex peripheral multifocal steno-obstructive vascular disease: Two-year results. *Cardiovasc. Intervent. Radiol.*, 30: 355-361, 2007.
- 23- THOMAS S.D., LENNOX A.F. and VARCOE R.L.: Hybrid Techniques for the Treatment of Critical Limb Ischemia. *Endovascular Today*, 48-54, 2015.
- 24- EARNSHAW J.J.: Surgical options for treatment of profunda femoris. In: Greenhalgh R.M., ed. *towards Vascular and Endovascular Consensus*. London: Biba Medical., 431-438, 2005.
- 25- JOSEPH L. and MILLS S.: *Infrainguinal Disease, Surgical Treatment; in Rutherford's vascular surgery and endovascular therapy 9th by Anton N.S. and Bruce A.P.; Printed in China*, 2 (109): 4764-4765, 2018.

- 26-MATSAGKAS M., KOUVELOU G. and ARNAOULOGLOU E.: Hybrid procedures for patients with critical limb ischemia and severe common femoral artery atherosclerosis. *Ann. Vasc. Surg.*, 25: 1063-1069, 2011.
- 27- ANTONIOU G.A., SFYROERAS G.S. and KARATHANOSANOS C.A.: Hybrid endovascular and open treatment of severe multilevel lower extremity arterial disease. *Eur. J. Vasc. Endovasc. Surg.*, 38: 616-622, 2009.
- 28- SCHNEIDER P.A.: Iliac angioplasty and stenting in association with infrainguinal bypasses: Timing and techniques. *Semin. Vasc. Surg.*, 16: 291-299, 2003.

التدبير الهجين كأجراء إنقاذي للآفات الحرقفية والأعراض الشريانية الفخذية المشتركة وهل هذا مناسب للغرض

الهدف: تقييم التدبير الهجين للآفات الحرقفية والأعراض الشريانية الفخذية المشتركة.

المرضى وطرق العلاج: تم إجراء دراسة مستقبلية على ٢٦ حالة مع أعراض الحرقفية وآفات انسداد الشريان الفخذي المشترك. تم تنفيذ النهج الهجين لجميع المرضى. جراحة مفتوحة لآفات الشريان الفخذي الشائعة والتدخلات داخل الأوعية الدموية للآفات الأخرى. كانت المتابعة ١٢ شهراً.

النتائج: اجتاز جميع المرضى الاداء الجراحي دون فشل فني، بعد الشهر الأول، تم الإبلاغ عن سالكية أولية في ٢٦ مريضاً (١٠٠٪) وإنقاذ الأطراف في ٢٤ حالة (٩٢.٣٪). بعد ٦ شهور و لوحظت سالكية أولية في ٢٤ حالة (٩٢.٣٪) وإنقاذ الأطراف في ٢٢ مريضاً (٨٤.٦٪). بعد ١٢ شهراً، لوحظت سالكية أولية في ١٨ مريضاً (٦٩.٣٪) وإنقاذ الأطراف في ٢٠ مريضاً (٧٦.٩٪). تم استعادة سالكية ثانوية في ٦ مرضى (٢٣.١٪).

الاستنتاجات والخلاصة: النهج الهجين ويشمل التدخل داخل الأوعية الدموية للآفات الشريانية الحرقفية عن طريق القسطرة التداخلية من تحت الجلد والفتح والإصلاح الجراحي للآفات الشريانية الفخذية الشائعة، يلعب دوراً كبيراً كإنقاذ لعلاج أعراض الحرقفية المشتركة والآفات الشريانية الفخذية بمعدلات مقبولة ومنتعشة للأطراف ويسمح خيارات علاجية فعالة وطفيفة التوغل ودائمة خاصة في المرضى المعرضين لخطورة عالية.