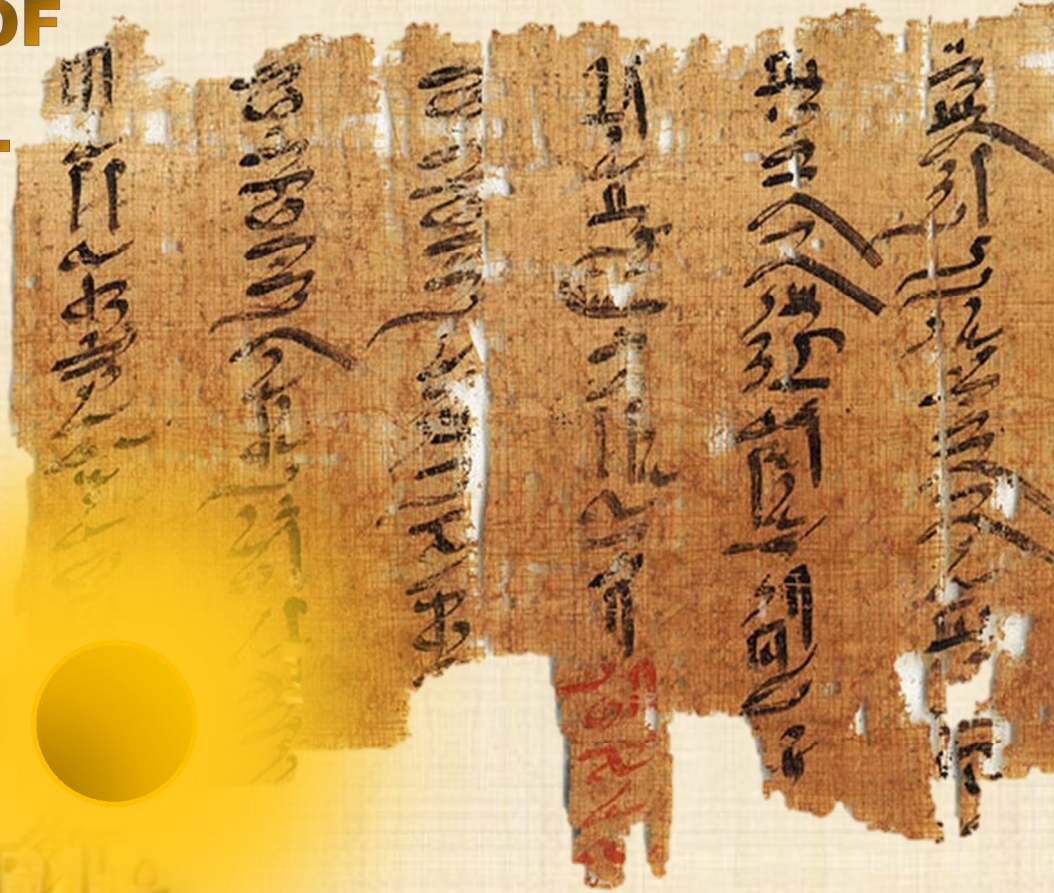


# IJMA

# INTERNATIONAL JOURNAL OF MEDICAL ARTS



VOLUME 2, ISSUE 4, AUTUMN 2020)



<http://ijma.journals.ekb.eg/>

**Print ISSN: 2636 - 4174**

**Online ISSN: 2682 - 3780**



Available online at Journal Website  
<https://ijma.journals.ekb.eg/>  
Main subject [Surgery [Obstetrics and Gynecology]]\*



## Original article

### Combined Uterine Artery Ligation, Segmental Myometrial Resection and Intrauterine Balloon to Control Bleeding from Placenta Previa Accreta during Caesarean Section

Asmaa Ibrahim Mohamed<sup>[a]</sup>; Rashed Mohamed Rashed<sup>[b]</sup>; Mohamed Galal Nasr<sup>[b]</sup>; Alaa Eldin Mahmoud Megahed<sup>[b]</sup>

Department of Obstetrics and Gynecology, Moutobes Central hospital, Ministry of Health, Egypt <sup>[a]</sup>.  
Department of Obstetrics and Gynecology, Damietta Faculty of Medicine, Al-Azhar University, Egypt <sup>[b]</sup>.

#### Corresponding author

Asmaa Ibrahim Mohamed  
Email: [asmaaqabr100@gmail.com](mailto:asmaaqabr100@gmail.com)

Received at: December 30, 2019; Revised at: September 05, 2020; Accepted at: September 05, 2020

DOI: [10.21608/ijma.2020.21455.1066](https://doi.org/10.21608/ijma.2020.21455.1066)

## ABSTRACT

**Background:** Morbidity attached placenta [MAP] remain a major surgical problem for obstetricians due to severe hemorrhage and its incidence had been continually increased due to increased rate of cesarean deliveries.

**Aim of the work:** To evaluate the safety and efficacy of a conservative intervention for management of placenta accreta.

**Patients and Methods:** Forty-eight, pregnant females with a confirmed diagnosis of placenta previa accreta had been scheduled for elective cesarean delivery had been included. All females had been screened by full history taking, clinical examination, ultrasound and laboratory investigations. Blood loss, operative time, need for transfusion and need for other surgical interventions represented the main outcome and other complications were documented.

**Results:** The blood loss [ml] ranged between 850 to 1300 ml; the mean values were  $1082.29 \pm 105.89$  ml. The operative time ranged between 60 to 130 minutes; the mean values were  $87.92 \pm 19.35$  minutes. There was significant decrease of post-partum hemoglobin when compared to corresponding pre-partum values [ $9.29 \pm 0.76$  vs  $10.71 \pm 0.54$  mg/dl respectively]. Four patients [8.3%] need ICU admission, and nine patients [18.75%] need blood transfusion. However, no patients need further surgical intervention or developed DIC. In addition, no mortality had been reported in the current work.

**Conclusion:** Combined uterine artery ligation, partial segmental myometrial resection and intrauterine balloon as a conservative treatment modality of placenta previa accreta is safe and effective.

**Keywords:** Placenta; Caesarean; Accreta; Previa; Hemorrhage.

This is an open access article registered under the Creative Commons, ShareAlike 4.0 International license [CC BY-SA 4.0] [<https://creativecommons.org/licenses/by-sa/4.0/legalcode>]

Please cite this article as: Mohamed MI, Rashed MR, Nasr MG, Megahed AM. Combined Uterine Artery Ligation, Segmental Myometrial Resection and Intrauterine Balloon to Control Bleeding from Placenta Previa Accreta during Caesarean Section. IJMA 2020; 2[4]: 880-885. DOI: [10.21608/ijma.2020.21455.1066](https://doi.org/10.21608/ijma.2020.21455.1066)

\* Main subject and any subcategories have been classified according to research topic.

## INTRODUCTION

Placenta previa is an abnormal placentation, which usually presented as a third-trimester painless bleeding. It is usually defined when placenta become abnormally near or cover the cervical internal os<sup>[1]</sup> and in obstetrics, fetomaternal complications usually occurred<sup>[2]</sup>.

Placenta accreta appears to be a result of endometrial damage or uterine scarring. Furthermore, a recurrent complication is the invasion of placental villi beyond the decidua basalis, which causes the development of Placenta accreta spectrum [accreta [abnormally adherent placenta], placenta increta [abnormally invasive placenta] and advanced form of advanced invasive placenta [placenta percreta]<sup>[3]</sup>.

The placenta accreta incidence has been increased as a results of higher cesarean delivery rates; its incidence is about 1 in 731 deliveries<sup>[4]</sup>.

It could be unexpectedly associated with hazardous complications [e.g., intractable postpartum hemorrhage [PPH], hysterectomy, multiple organ dysfunction and even death<sup>[5]</sup>.

Standard surgical intervention is not clear, although many trials revealed better outcome with a planned hysterectomy of the cesarean hysterectomy before the beginning of labor or bleeding<sup>[6]</sup>.

We propose that, conservative management with combined uterine artery ligation, partial segmental myometrial resection and intrauterine balloon could represent an effective and safe alternative for management of placenta accreta. We suggested that, this combined maneuver will be associated with low complications rate [e.g., blood loss, need for ICU admissions, etc..] and maneuver related mortality.

## AIM OF THE WORK

The current work had been designed to evaluate the efficacy and safety of combined uterine artery ligation, partial segmental myometrial resection and intrauterine balloon as a conservative treatment for placenta accrete.

## PATIENTS AND METHODS

The current observational, prospective study had been carried out by the Department of Obstetrics and Gynecology, Damietta Faculty of Medicine [Al-Azhar University]. Forty-eight, eligible pregnant females who had a confirmed diagnosis of placenta accreta and had been scheduled for elective cesarean delivery had been included.

To be included, females must be confirmed for placenta previa accreta and had single fetus. On the other side, exclusion criteria were: multiple gestations, known bleeding disorder, known risk factors for PPH, hypertensive disorders of pregnancy, antepartum hemorrhage [APH] or delivery by emergency cesarean section.

The study protocol had been approved by the IRP [institutional review board] for its ethical and design considerations. In addition, the study and its impacts had been explained for all females, who had been signed an informed consent. Then all females had been screened by full history taking and clinical examination. In addition, Lab investigation had been carried out [complete blood count and coagulation profile]. An abdominal ultrasound [routine] had been performed to confirm the gestational age, confirm the diagnosis and assess the condition. Preoperative hemoglobin [Hb] assessment had been carried out and 4-6 blood units and fresh frozen plasma had been cross matched for each case before planned cesarean section.

Elective cesarean deliveries had been performed between 36-37weeks of gestation according to established guidelines. The surgical procedure had been performed as described elsewhere <sup>[7]</sup>, but with the following points kept in mid: the incision of the uterus had been carried out high away from the placenta. The placenta had been left in place not removed after delivery. Then, bilateral uterine artery ligation [BUAL] had been carried out and placenta then removed. Then, a selected partial myometrial resection had been performed to reduce lower uterine segment space. Foleys catheter no 20, had been placed intrauterine and the lower end was passed through the cervical canal.

The primary outcome: the intraoperative blood loss, operative time, need for blood transfusion,

and the need for other surgical interventions as cesarean hysterectomy. Blood loss had been measured by collection of amounts of blood in the suction's bottles and weight of intra- and post-operative blood towels. The operative time had been calculated as onset of skin incision to skin closure.

The secondary outcome: the change in pre- and post-partum hemoglobin. Postoperative assessment included pulse, blood pressure, complete blood count [CBC], development of disseminated intravascular coagulation [DIC], intensive care unit [ICU] admission and the need for re-laparotomy.

**Statistical methods:**

Sample size calculation: To be clinically significant, it had been proposed that combined uterine artery ligation, segmental myometrial resection and intrauterine balloon could reduce intraoperative blood loss by 50%. Accordingly, we need to study 24 patients in each group to be able to reject the null hypothesis at the power of 80% and the type one error probability of 0.05. In addition, the collected data had been statistically analyzed by IBM SPSS software package version 20.0. [Armonk, NY: IBM Corp, USA]. Categorical data were expressed in frequency and percentages and descriptive data [mean ± standard deviation] had been calculated for numerical data. Pre- and postoperative data had been compared by the paired samples [t] test. P value < 0.05 had been considered significant.

**RESULTS**

In the current study, patient age ranged between 20 and 40 years; the mean age 28.10±4.79 years. The gravidity ranged between 2 and 5 [3.21 ± 0.94 mean ±SD]; parity ranged

between 1 and 4 [1.94 ± 0.89 mean±SD]; the mean number of previous cesarean deliveries was 1.79±0.87 [ranged between 1 and 4]. In addition, the mean pulse, systolic BP and diastolic BP were [84.69 ± 6.33, 101.0 ± 6.27 and 66.85 ± 5.64 respectively] [Table 1].

In addition, 58.3% of studied females were housewives, 52.1% were from rural area, and 58.3% had been subjected to spinal anesthesia and 41.7% of general anesthesia [data not tabulated].

The preoperative diagnosis of placenta centralis was complete centralis among 14.6%, centralis anterior among 8.3%, centralis posterior among 41.7%, complete centralis anteroposterior among 2.1%, incomplete centralis anterior among 4.2%, incomplete centralis posterior among 2.1% and marginalis anterior among 27.1% [Table 2]. The intraoperative blood loss [ml] ranged between 850 to 1300 ml; the mean values were 1082.29± 105.89 ml. In addition, the operative time ranged between 60 to 130 minutes; the mean values were 87.92±19.35 minutes [table 3].

As regard pre-partum hemoglobin, it ranged from 9.6 to 11.50 g/dl, while post-partum hemoglobin ranged between 8 to 11 g/dl; with significant decrease of post-partum when compared to corresponding pre-partum values [9.29± 0.76 vs 10.71±0.54 mg/dl respectively] [Table 4].

Four patients [8.3%] need ICU admission, and nine patients [18.75%] need blood transfusion. However, no patients need further surgical intervention or developed DIC. In addition, no mortality had been reported in the current work.

**Table [1]:** Descriptive data of studied females

Variable	Statistics		
	Mean ±SD	Minimum	Maximum
Age	28.10 ± 4.79	20	40
Gravidity	3.21 ± 0.94	2	5
Parity	1.94 ± 0.89	1	4
No of previous CS	1.79 ± 0.87	1	4
GA at delivery	36.48 ± 0.74	35	38
Pulse	84.69 ± 6.33	75	95
Systolic BP	101.0 ± 6.27	80	110
Diastolic BP	66.85 ± 5.64	60	80

**Table [2]:** Distribution of the studied cases according to preoperative diagnosis [n = 48]

Preoperative diagnosis	No.	%
Complete centralis	7	14.6
Centralis anterior	4	8.3
Centralis posterior	20	41.7
Complete centralis antero-posterior	1	2.1
Incomplete centralis anterior	2	4.2
Incomplete centralis posterior	1	2.1
Marginalis anterior	13	27.1

**Table [3]:** Descriptive analysis of the studied cases according to Intraoperative blood loss and operative duration [n = 48]

	Min. – Max.	Mean ± SD.
Intraoperative blood loss [ml]	850.0 – 1300.0	1082.29 ± 105.89
Operative duration [min]	60.0 – 130.0	87.92 ± 19.35

**Table [4]:** Comparison between pre-partum and post-partum according to hemoglobin

		Pre-partum	Post-partum	Paired [t]	p
Hemoglobin	Min. – Max.	9.60 – 11.50	8.0 – 11.0	11.359	<0.001*
	Mean ± SD.	10.71 ± 0.54	9.29 ± 0.76		

## DISCUSSION

Results of the current research revealed a favorable outcome of the investigated procedure. The combination of more than hemostatic measure before removal of placenta could explain the excellent outcome in the current study. These results agree with Zhao *et al.*<sup>[8]</sup>, Tskhay *et al.*<sup>[9]</sup> and Sanad *et al.*<sup>[10]</sup> regarding patient age, gravidity, parity and residence.

Pinas-Carrillo *et al.* showed that the commonest placental localization was anterior previa in 29 cases [58.0%]<sup>[7]</sup>. This is comparable to the current study [placenta centralis posterior [41.7%] followed by marginalis anterior [27.1%]]. The planned delivery with CS at 35 to 37 weeks in the current work, is comparable to the practice of Acar *et al.*<sup>[11]</sup> who carried an elective [planned] CS at 37 weeks for females with placenta previa

In the current work, we found significant decrease of blood after delivery when compared to pre-partum values. Four patients [8.3%] need ICU admission, and nine patients [18.75%] need blood transfusion. However, no patients need further surgical intervention or developed DIC. In addition, no mortality had been reported in the current work.

This reflects the safety and efficacy of the procedure. We believed that, that the prior

ligation of uterine arteries is associated with reduced risk of bleeding, although placenta previa itself associated with higher risk of bleeding.

Acar *et al.*<sup>[11]</sup> reported that, the mean blood loss was  $1350 \pm 750$  ml and their patients' needs blood transfusion. They clamped the uterine artery and used uterine sutures. However, the advanced invasive placenta may be responsible for high bleeding. However, they used a conservative management for females who want fertility preservation. Their conservative technique included intracavitary suture technique after occlusion of the proximal branch of the uterine artery with blockage of utero-ovarian anastomoses. Blood loss in the present trial is comparable to Amsalem *et al.*<sup>[1]</sup> who reported a range of 900–1600 ml of blood loss in scheduled conservative treatment with adjuvant prophylactic embolization of the uterine artery shortly after CS and no peripartum hysterectomy had been required in either series.

In controversy to the current work, Salim *et al.*<sup>[12]</sup> reported that, the use of prophylactic balloon did not be associated with significant reduction of blood loss or need for blood transfusion in patients with placental invasion. However, You *et al.*<sup>[13]</sup> reported a similar technique to the segmentally incision of the lower uterine segment, suggesting that, such technique permits direct observation of bleeding points with

direct hemostasis, especially in lower uterine segment.

The separation of the placenta increases the risk of bleeding and we strongly believe that placental no separation and segmental myometrial excision is a crucial step of our procedure that avoids excessive bleeding. These results are better than other procedures used as by **Soyer et al.** who performed pelvic embolization in emergency cases alone. The success rate was 83.3% after one or two sessions of embolization. They added, 56% of females with placenta accreta did not need embolization and thus stated that the usage of prophylactic embolization should not be warranted. The same can be applied for the prophylactic placement of balloon occlusion catheters<sup>[14]</sup>. Another case report by **Gaspore et al.** who used BUAL with delayed placental separation and placement of intrauterine Bakri balloon tamponade. They concluded that the application of the Bakri balloon and pelvic devascularization decreases the need for hysterectomy and the patient's fertility is preserved<sup>[4]</sup>.

Different techniques were reported for management of placental invasion, for example, **Palacios-Jaraquemada et al.**<sup>[15]</sup> reported uterine repair among anterior placenta percreta, with selective vascular ligation or surgical myometrial compression and used myometrial pulley sutures to repair anterior myometrial wall defects followed by fibrin glue, mesh and a cellulose layer application over this reconstruction. The uterine preservation rate was 73.5% which is lower than the current work [100%]. In addition, the uterine preservation rate in the current work is higher than those reported in other trials [78%–85%]<sup>[16,17]</sup>.

In agreement with the current work, **Lin et al.**<sup>[18]</sup> reported that, BUAL followed by delivery of the placenta in females with placental invasion effectively decrease intraoperative blood loss, reduce postpartum hemorrhage [PPH], and the risk of complications [e.g., hysterectomy]. In addition, **Wang et al.**<sup>[19]</sup> concluded that, prophylactic intraoperative bilateral uterine artery or internal iliac artery embolization represent an effective strategy to control intractable peripartum

hemorrhage and preserve fertility in placenta previa.

The strength of the current study represented by the multimodality and multistep approach for conservative management, which achieved good hemostasis before placental delivery. However, the small number of included patients represented one limiting step. In addition, the elective nature of the procedure prevents globalization of the safety and efficacy of the current technique. Future studied thus are warranted.

### **Conclusion:**

Combined uterine artery ligation, partial segmental myometrial resection and intrauterine balloon as a conservative treatment for placenta previa accrete a safe and effective procedure.

### **Financial and Non-financial Relationships and Activities of Interest**

Authors declare that there was no competing interest

### **REFERENCES**

1. **Amsalem H, Kingdom JC, Farine D, Allen L, Yinon Y, D'Souza DL, et al.** Planned caesarean hysterectomy versus "conserving" caesarean section in patients with placenta accreta. *J Obstet Gynaecol Can.* **2011**; 33[10]:1005-1010. [DOI: 10.1016/S1701-2163[16]35049-6].
2. **Silver RM, Barbour KD.** Placenta accreta spectrum: accreta, increta, and percreta. *Obstet Gynecol Clin N Am.* **2015**; 42:381–402. [DOI: 10.1016/ j.ogc.2015.01.014].
3. **Bailit JL, Grobman WA, Rice MM, Reddy UM, Wapner RJ, Varner MW, et al.** Morbidly adherent placenta treatments and outcomes. *Obstet Gynecol.* **2015**; 125 [3]: 683–689. [DOI: 10.1097/ AOG.0000000000000680].
4. **Gaspore C, D'Alfonso A, Armando N, Giuseppe R, Valentina P, Felice P.** Conservative Surgical Management of Placenta Previa and Accreta. A Case Report. *SOJ Surgery* **2014**; 1[1]: 3 pages. [DOI: 10.15226/2376-4570/1/1/00106].
5. **Meller CH, Izbizky GH, Otano L.** Outcomes of planned compared with urgent deliveries using a multidisciplinary team approach for morbidly adherent placenta. *Obstet Gynecol.* **2018**; 131: 1164–5. [DOI: 10.1097/ AOG.0000000000002666].
6. **O'Brien JM.** Placenta previa, placenta accreta, and vasa previa. *Obstet Gynecol* **2007**; 107: 203–4. [DOI: 10.1097/01.AOG.0000252286.61603.0e]

7. **Pinas-Carrillo A, Bhide A, Moore J, Hartopp R, Belli AM, Arulkumaran S, et al.** Outcomes of the first 50 patients with abnormally invasive placenta managed using the “Triple-P” conservative surgical approach. *Int J Gynaecol Obstet.* **2020**; 148 [1]:65-71. [DOI: 10.1002/ijgo.12990].
8. **Zhao X, Tao Y, Du Y, Zhao L, Liu C, Zhou Y, et al.** The application of uterine wall local resection and reconstruction to preserve the uterus for the management of morbidly adherent placenta: Case series. *Taiwan J Obstet Gynecol.* **2018**; 57[2]:276-282. [DOI: 10.1016/j.tjog.2018.02.017].
9. **Tskhay VB, Yametov PK, Yametova NM.** The use of modified triple-p method with adherent placenta long-term results. *MOJ Womens Health.* **2017**; 4[2]:30-32. [DOI: 10.15406/mojwh.2017.04.00079].
10. **Sanad AS, Mahran AE, Aboufotouh ME, Kamel HH, Mohammed HF, Bahaa HA, et al.** The effect of uterine artery ligation in patients with central placenta previa: a randomized controlled trial. *BMC Pregnancy Childbirth.* **2018**; 18[1]:351. [DOI: 10.1186/s12884-018-1989-5].
11. **Acar A, Ercan F, Pekin A, Elci Atilgan A, Sayal HB, Balci O, Gorkemli H.** Management of placental invasion anomalies with an intracavitary suture technique. *Int J Gynaecol Obstet.* **2018**; 143[2]:184-190. [DOI: 10.1002/ijgo.12593].
12. **Salim R, Chulski A, Romano S, Garmi G, Rudin M.** Pre-cesarean prophylactic balloon catheters for suspected placenta accreta: A randomized controlled trial. *Obstet Gynecol.* **2015**; 126: 1022–1028. [DOI: 10.1097/AOG.0000000000001113].
13. **You Y, Fu J, Chen H, Luo L, Liu X, Peng B.** Parallel transverse uterine incisions to control postpartum hemorrhage and preserve fertility during cesarean delivery for placenta previa and accreta. *Int J Gynecol Obstet.* **2016**; 134: 221–222. [DOI: 10.1016/j.ijgo.2016.02.013].
14. **Soyer P, Morel O, Fargeaudou Y, Sirol M, Staub F, Boudiaf M, et al.** Value of pelvic embolization in the management of severe postpartum hemorrhage due to placenta accreta, increta or percreta. *Eur J Radiol.* **2011**; 80: 729–735. [DOI: 10.1016/j.ejrad.2010.07.018].
15. **Palacios Jaraquemada JM, Pesaresi M, Nassif JC, Hermosid S.** Anterior placenta percreta: Surgical approach, hemostasis and uterine repair. *Acta Obstet Gynecol Scand.* **2004**; 83: 738–744. [DOI: 10.1111/j.0001-6349.2004.00517.x].
16. **Li GT, Li GR, Li XF, Wu BP.** Funnel compression suture: A conservative procedure to control postpartum bleeding from the lower uterine segment. *BJOG.* **2016**; 123: 1380–1385. [DOI: 10.1111/1471-0528.13685].
17. **Sentilhes L, Ambroselli C, Kayem G, Provansal M, Fernandez H, Perrotin F, et al.** Maternal outcome after conservative treatment of placenta accrete. *Obstet Gynecol.* **2010**; 115:526–534. [DOI: 10.1097/AOG.0b013e3181d066d4].
18. **Lin J, Lin F, Zhang Y.** Uterine artery ligation before placental delivery during caesarean in patients with placenta previa accreta. *Medicine [Baltimore].* **2019**; 98 [36]: e16780. [DOI: 10.1097/MD.00000000000016780].
19. **Wang J, Shi X, Li Y, Li Z, Chen Y, Zhou J.** Prophylactic intraoperative uterine or internal iliac artery embolization in planned cesarean for pernicious placenta previa in the third trimester of pregnancy: An observational Study [STROBE compliant]. *Medicine [Baltimore].* **2019** Nov; 98 [44]: e17767. [DOI: 10.1097/MD.00000000000017767].

# International Journal

<https://ijma.journals.ekb.eg/>

Print ISSN: 2636-4174

Online ISSN: 2682-3780

# of Medical Arts