

Pre-procedural Ultrasound Assessment as a Step Towards the Safety of Percutaneous Dilatational Tracheostomy: a Comparative Study

Ismail M Abdelgawad Ahmed¹ MD, Abdalla M Abdalla¹ MD, Usama I Abotaleb^{1*}  MD

*Corresponding Author

Usama I Abotaleb

us_usama@yahoo.com

Received for publication May 7, 2020;
Accepted July 28, 2020; Published
online September 2, 2020

Copyright 2020 The Authors published by Al-Azhar University, Faculty of Medicine, Cairo, Egypt. All rights reserved. This an open-access article distributed under the legal terms, where it is permissible to download and share the work provided it is properly cited. The work cannot be changed in any way or used commercially
doi: 10.21608/aimj.2020.29643.1221

¹Department of Anaesthesia and Intensive Care, Faculty of Medicine, Al-Azhar University, Cairo, Egypt.

ABSTRACT

Background: Percutaneous dilatational tracheostomy (PDT) is an inevitable procedure indicated for mechanically ventilated critically ill patients. Ultrasound (US) assisted PDT has emerged increasing safety issues. Case series were reported to confirm the advantages of USPDT.

Aim: The present study aimed to compare patients subjected to USPDT with those subjected to bronchoscope guided PDT only, regarding the easiness of technique, efficacy and safety.

Materials and Methods: A prospective, randomized, comparative clinical study carried on 49 adults mechanically ventilated critically ill patients in need to maintain a secure airway through elective PDT, using Ciaglia's Blue Rhino percutaneous dilatational tracheostomy technique. 5 patients were excluded for surgical conversion, and the remaining 44 were randomly divided into 2 groups; PDT group: patients subjected to fiber optic guided PDT, and USPDT group: patients underwent pre-procedural US imaging followed by fiber optic guided PDT. Time of the technique, procedure failure, procedure difficulty, and complications were documented, our follow up ends 24-hours after the technique.

Results: Pre-procedural US guided PDT was found to be easier ($P<0.05$), 1 puncture was needed in the USPDT group ($P<0.05$) with shorter time ($P<0.001$). The puncture site was changed in 31.8% of the PDT group of patients but not in the USPDT group. The pre-procedural US group showed less bleeding, transient hypoxemia ($P<0.05$) and total number of patients with minor complications ($P<0.05$).

Conclusion: Pre-procedural ultrasound assessment of trachea and Para-tracheal soft tissues can be considered as a reliable tool to increase safety and improve outcomes of percutaneous tracheostomy.

Key words: Dilatational tracheostomy; Percutaneous; mechanically ventilated; Ultrasound.

Disclosure: The authors have no financial interest to declare in relation to the content of this article. The Article Processing Charge was paid for by the authors.

Authorship: All authors have a substantial contribution to the article

INTRODUCTION

Tracheostomy is a commonly performed bedside procedure in prolonged ventilated critically ill patients.¹ Percutaneous dilatational tracheostomy (PDT) has well-known advantages and it's favored over surgical tracheostomy (ST),² however PDT heralds many peri-procedural complications as hemorrhage, pneumothorax, pneumomediastinum, false passage, posterior tracheal wall injury, subcutaneous emphysema, and difficult to place the tube.³ It is common for patients indicated for PDT to have rather difficult anatomical variations most often

due to obesity, chronic musculoskeletal pathology, previous injuries, or surgical procedures. Among the difficulties confronted; difficulty in locating the cricothyroid membrane and difficulties with a tracheal puncture when the tracheal anatomy is not easily palpable and attempting palpation of the usually used anatomical landmarks seems sometimes to be difficult or even impossible.^{4,5} Many assisting tools have been used to assist guidance during PDT and therefore decreasing the incidence of these peri-procedural problems.⁶ These include the laryngeal mask airway (LMA), pre-procedure ultrasound (US)

scanning, light wand for trans-illumination of the neck soft tissues, and flexible fiber optic bronchoscopy.^{7,8} US can be especially useful to assess tracheal midline, pre tracheal soft tissues including type and size of blood vessels in the area of interest, the sternomastoids and infrahyoid muscles, and lastly the jugular veins and carotid arteries before PDT.⁹ Also it may help inaccurate selection of size and length of the tracheostomy tube, especially in patients with an increased pre tracheal soft tissue thickness.¹⁰

The aim of the study is to compare fiber optic bronchoscope guided percutaneous dilatational tracheotomy outcomes between those patients with pre-insertion Ultrasound imaging of the neck (USPDT) and those without (PDT). Our primary outcome was the time of the technique, while ease of the procedure, failure, and complications as bleeding, transient hypoxemia, tracheal wall injury, or false passage were secondary outcomes.

PATIENTS AND METHODS

This prospective randomized comparative study was carried out in Al-Hussain and Sayed Galal university hospitals between July 2016 and December 2018. A total of 49 adults intubated mechanically ventilated patients admitted in intensive care were assessed for eligibility for PDT. Of those, five patients were excluded for surgical conversion, and 44 patients, scheduled to undergo bedside tracheostomy (*due to inability to protect airway or difficult weaning from mechanical ventilation*), were enrolled in the study. Approval for this study was obtained from the Institutional committee of ethics and informed consents were obtained from the legal guardian of patients. Patients were randomly divided into two equal groups: **PDT group**: represented patients subjected to flexible fiber optic bronchoscope guided PDT without US guidance, and **USPDT group**: represented patients who underwent pre-procedural US neck imaging followed by flexible fiber optic bronchoscope guided PDT. The following conditions were excluded: Age <16, obese patients with Body Mass Index (BMI) ≥ 45 kg/m², severe coagulopathy, and unsuitable anatomy (e.g., previous cervical surgery, cervical trauma, or tumors).

All tracheostomies were done as a bedside procedure in the intensive care unit, and patients monitored by capnography, pulse oximetry and noninvasive blood pressure. Positive end expiratory pressure (PEEP) were decreased to zero, synchronized intermittent mandatory ventilation (SIMV) mode was used and the ventilator set to deliver 6mL/kg tidal volume, respiratory rate 12/minute and fraction inspired oxygen (FiO₂) 50%. For analgesia and sedation, we used intravenous fentanyl 0.5 μ g/kg and propofol 3mg/kg/hour infusion plus lidocaine 2% subcutaneous infiltration, no muscle relaxants were used in our study.

The procedure details in the US-guided PDT cohort

Ultrasound examination was done with Sono Site M-Turbo (Fujifilm Sono Site, Inc., Washington, USA) portable ultrasound device. A short linear vascular probe (8-12 MHz) was used, the trachea was imaged in the vertical medial plane and continuous or pulsed

Doppler signals over the trachea were activated on the level of the second ring. Aiming to reduce the possibility of non visualization of veins, patients could be temporarily positioned in a head down position to improve venous filling in the scanned area. Care was taken during scanning to keep only minimum pressure with the ultrasound probe to avoid collapse of vessels by the probe pressure. When round, well demarcated structures, suspicious of being vascular in nature were identified anterior to the trachea, numerous maneuvers were useful to examine whether the structures seen were artery or vein. 1st, compression was applied with the probe to inspect for luminal reduction as a response to variable grades of compression. 2nd, a Doppler cursor was located over the structure to be tested and Doppler flow was displayed by sound or graph to screen for signal of pulsatile flow of arteries. 3rd, a square region of interest was placed around the structure and color Doppler analysis was performed (**Figure.1**).

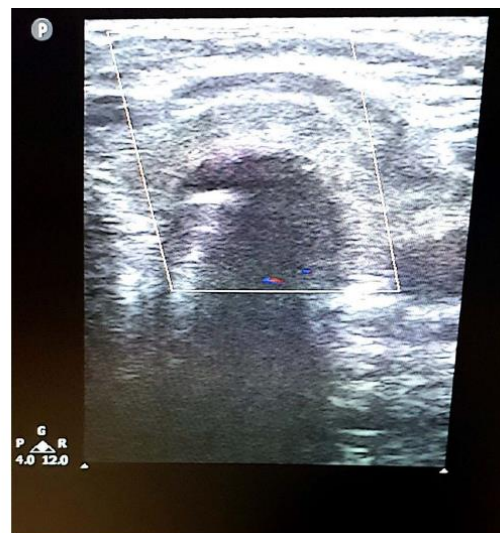

Fig. (1): Doppler US at the level of 2nd tracheal ring for preoperative scanning of vascular structures.

Then the patient was placed in tracheostomy position, the endotracheal tube was withdrawn thereafter till the cuff is just lower to the vocal cord. When the tip of the tube reached the 2nd tracheal ring, the intensity of the Doppler signal significantly increased due to an increased signal from turbulent air, proving the exact site of endotracheal tube. puncture site was typically chosen between 2nd and 3rd tracheal rings, following a clear ultrasonic confirmation of anatomy of the cricoid and thyroid cartilages and tracheal rings (**Figure: 2**). Cook Ciaglia Blue Rhino ® G 2 (Cook Medical Inc., Bloomington, USA) kit was used and Bronchoscopy was performed using flexible fiber optic bronchoscopes (Pentax Ltd, U.K.).

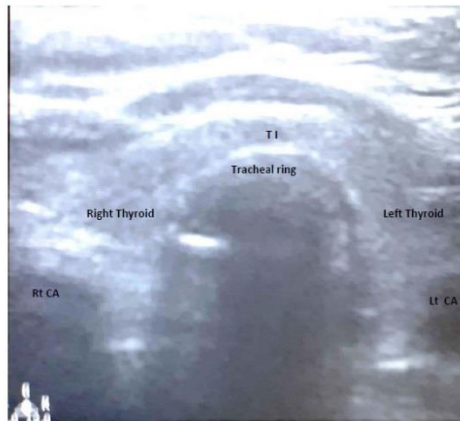


Fig. (2): Preoperative US assessment of the neck in the Intensive Care Unit. TI: Thyroid isthmus, RtCA & LtCA: Right & Left carotid arteries.

The time of technique, failure of the procedure, difficulty, and complications were assessed. Time of technique: defined as the time from the start till confirmation of the correct placement (expressed with min). Failure of the procedure: defined as conversion after the onset of PDT procedure to surgical tracheostomy. Difficulty: was assessed as follows: easy, some difficulty, or very difficult, some difficulty considered if there was difficulty to define landmarks, or need to change in puncture site due to bleeding, while very difficult considered if there was the inability to define landmarks (but no failure). Complications were classified to minor or major: *Minor complications* include; transient hypotension (systolic blood pressure below 80% of the start reading) for less than 5 minutes, transient hypoxemia (peripheral oxygen saturation [SpO₂] < 90% for less than 5 minutes), localized minor bleeding, localized subcutaneous emphysema, inadvertent cuff puncture, accidental decannulation, while *Major complications* include; injury of trachea or esophagus, false passage, pneumothorax, pneumomediastinum, persistent hypotension (more than 5 min), persistent hypoxemia (SpO₂ < 90% for more than 5 min), major bleeding (stomal, intratracheal, or bleeding requiring surgical repair).

The sample size was calculated using G* Power 3.1.9.2 program, Kiel, Germany; depending on our primary outcome (Time of technique), In a previous study,¹ time of technique in PDT and USPDT were 16.8±4.3 and 12.1±4.6 min respectively, we planned our study to detect 5% significance level (α) at a power of 80% (1- β). The minimum sample size was to study 16 patients in each group (and increase 25% [= 4 patients] for dropout), we investigated 22 patients in each group.

Statistical analysis: The data were collected, tabulated, and analyzed with SPSS 21.0 (Statistical Package for Social Science, Inc., Chicago, USA). Quantitative data were presented as either mean±standard deviation or median and percentiles (25th-75th) as appropriate. Qualitative data were presented as frequencies and percentages. Kolmogorov-Smirnov test was used for normality testing. Normally distributed data were compared using the Student t-test, whereas non normally

distributed data were compared with the Mann-Whitney test. χ^2 or Fisher exact tests were used to test the association between qualitative variables. P values <0.05 were considered significant.

RESULTS

Demographic data

There were no statistically significant differences regarding demographic data (**Table. 1**).

Procedure details

Three patients (13.6%) in the US group were excluded pre-procedural and converted for surgical tracheostomy after the US examination due to the presence of vessels beneath, but no surgical interference (failure) was needed after the start of the procedure and during the observational period in both groups.

Time of technique was shorter, the procedure was easier with less number of tracheal punctures in the USPDT group (**Table. 2**)

Complications

No major complications were identified in both groups. While the number of patients with minor bleeding and transient hypoxemia were significantly higher in PDT patients. In general, the total number of patients with minor complications was significantly higher in the PDT group (**Table. 3**).

DISCUSSION

There is an increasing attitude of literature proving the value of ultrasound in intensive care patients including airway managing; encouraged by increasing availability of portable, small, ultrasound machines with high resolution leading to its increased usefulness in intensive care settings. To our best of knowledge, the current study is the first prospective study conducted in Egypt to compare the effectiveness and safety between USPDT and those of bronchoscopy guided PDT without the pre-procedural US.

In the present study, 44 patients were recruited for PDT insertion. They were randomly divided into two groups: 22 patients opt to bronchoscopy-guided PDT and 22 in the pre-procedural US group (USPDT group) with a mean age of 56.14±16.85, and 52.68±15.78. Female to Male ratio was 1:1.2 compared to 1:1.75 respectively (P>0.05).

Three patients (13.6%) in the USPDT group were excluded pre-procedural and converted for surgical tracheostomy after US examination due to the presence of vessels beneath; reflecting the safety of US examination prior to PDT.

The procedure was easy (P<0.05) in 84.2% of patients opt to US-guided PDT with less time (P<0.001) as compared to the PDT group. The puncture site was changed in 31.8% of the bronchoscopy guided PDT cohort, while none of the US-guided PDT patients required a change of puncture site. A previous study in Brazil¹¹ included 11 patients retrospectively underwent bronchoscopy-guided PDT and 49 US-guided PDT with a mean age of (49±18.7 and 52±19.8 respectively), males were (46% and 67% respectively); they reported the US to

be effective, as a convert to surgical tracheostomy wasn't needed and only one case of US-guided PDT cohort required bronchoscopy assistance at the stage of guidewire withdrawal, the procedure easy to perform, 2 punctures were needed more in bronchoscopy guided group ($P > 0.05$). On the other hand, Gobatto and colleagues studied on 58 patients to the bronchoscopy group and 60 patients to ultrasound group, they reported portable ultrasound to be a simple technique for screening of blood vessels and for locating the midline before the procedure, procedure failure was 1.7% of cases with tracheal punctures median 2 in both groups, and the puncture site was changed in 23.3% of the US group¹². Other investigators reported puncture site change in 18 % of the studied US population.^{11,13} In our study the procedure length was shorter in the USPDT cohort ($P < 0.001$), this coincides with previous authors.^{13,14,15}

In the present study, no major complications were detected in both study groups. Injury to blood vessels was highlighted in previous studies and they recommended the use of ultrasound to identify them,^{16,17} and interestingly, a research in London collecting data from computerized tomography (CT) angiography to study neck vasculature; revealed that 187 out of 343 patients (55%) verified a pre-tracheal vessel; vein in 131 and artery in 56.¹⁸ Three previous randomized controlled trials¹⁹⁻²¹ compared USPDT with landmark or bronchoscopy guided PDT; the total minor complication rates vary between 11.52% to 56.75 %; without difference between both compared groups. Contrarily, the current results

showed a lower total minor complication rate in the bronchoscopy group ($P < 0.05$).

In comparison to previous results reported in a meta-analysis comparing surgical tracheostomy with PDT in a total of 1212 patients; enrolled in 17 randomized controlled studies, the overall incidence of bleeding and infection in both techniques was 5.7% and 6.6 % respectively.²² Other authors recruited 12 patients aged (30-66), females were 66.67 % patients; they performed PDT guided with the pre-procedural US without complications.²³ In the current study, the bronchoscopy-guided group revealed more minor bleeding and transient acute hypoxemia. Complications in previous studies widely varied; probably attributed to the discrepancy in sample size, candidate population, and different equipment.^{11,13,24}

Limitations of our study we did not record or compare late complications *e.g. infection and stenosis*.

Conclusion

Pre-procedural US-guided percutaneous dilatational tracheostomy (USPDT) can be considered as a reliable tool to increase safety and improve outcomes of elective tracheostomy.

Conflicts of interest: There are no conflicts of interest.

Acknowledgment: We would like to acknowledge all intensive care residents.

Variable	PDT group (n=22)	USPDT group (n=22)	P-value
Sex: males	12 (54.5%)	14 (63.6%)	0.65
females	10 (45.5%)	8 (36.4%)	
Age (years)	56.14±16.85	52.68±15.78	0.18
Body mass index (Kg/m ²)	34.45±4.68	33.5±3.66	>0.05
PaO ₂ before PDT	94.64±1.33	95.23±1.27	>0.05
PaO ₂ after PDT	94.5±1.3	94.86±1.55	>0.05
Diagnosis of admission:			
Pneumonia	8 (36.4%)	7 (31.8%)	>0.05
traumatic brain injury	8 (36.4%)	10 (45.5%)	
CNS neoplasm	6 (27.2%)	5 (22.7%)	
Indication for intubation:			
Respiratory failure	8 (36.4%)	9 (40.9%)	>0.05
inability to protect the airway	14 (63.4%)	13 (59.1%)	
Indication for tracheostomy:			
Difficult weaning	11 (50%)	13 (59.1%)	>0.05
inability to protect the airway	11 (50%)	9 (40.9%)	
Anatomical difficulties:			
None	8 (36.4%)	6 (27.2%)	>0.05
short neck	10 (45.5%)	11 (50%)	
limited neck extension	4 (18.1%)	5 (22.7%)	
MV before tracheostomy (days)	15.91±3.71	14.14±2.9	>0.05

Values are expressed as mean ± SD (standard deviation), or number (percentage). PaO₂: arterial oxygen pressure, FiO₂: the fraction of inspired oxygen, CNS: central nervous system, MV: mechanical ventilation.

Table (1): Demographic characteristics of the patients

Variable	PDT group (n=22)	USPDT group (n=19)	P-value
Procedure difficulty:			
Easy	11 (50%)	16 (84.2%)	<0.05*
some difficulty	7 (31.8%)	3 (15.8%)	
difficult/very difficult	4 (18.2%)	0	
No. of tracheal punctures:			
1 puncture	15 (68.2%)	19 (100%)	<0.05*
2 punctures	7 (31.8%)	0	
Change in puncture site	7 (31.8%)	0	–
Procedure length (min)	15.27±2.51	11.74±2.16	<0.001*

Values are expressed as mean ± SD (standard deviation), or number (percentage). NA denotes not applicable, * P is significant at <0.05.

Table (2): procedure details in the target patients

Variable n (%)	PDT group (n=22)	USPDT group (n=19)	P-value
Transient hypotension	3 (13.6%)	4 (21.1%)	>0.05
Minor bleeding	8 (36.4%)	0 (0%)	<0.05*
Transient acute hypoxemia	8 (36.4%)	1 (5.3%)	<0.05*
Surgical emphysema	1 (4.5%)	0 (0%)	>0.05
Total Number with minor complications	13 (59.1%)	4 (21.1%)	<0.05*

Values are expressed as number (percentage), * P is significant at <0.05.

Table (3): Complications of the procedure

REFERENCES

- Song J, Xuan L, Wu W, Zhu D, and Zheng Y. Comparison of Percutaneous Dilatational Tracheostomy Guided by Ultrasound and Bronchoscopy in Critically Ill Obese Patients. *J Ultrasound Med.* 2018 May;37(5):1061-1069.
- Pattnaik SK, Ray B, and Sinha S. Griggs percutaneous tracheostomy without bronchoscopic guidance is a safe method: A case series of 300 patients in a tertiary care Intensive Care Unit, *Indian Journal of Critical Care Medicine.* 2014;18(12):778-82.
- Walz MK and Schmidt U. Tracheal lesion caused by percutaneous dilatational tracheostomy: a clinicopathological study, *Intens. Care Med.* 1999;25:102-5.
- Byhahn C, Lischke V, Meininger D, Halbig S, and Westphal K. Perioperative complications during percutaneous tracheostomy in obese patients. *Anaesthesia* 2005;60(1):12-15.
- Elliott DS, Baker PA, Scott MR, Birch CW, and Thompson JM. Accuracy of surface landmark identification for cannula cricothyroidotomy. *Anaesthesia* 2010;65(9):889-94.
- Hassanin EG, Elgnady AA, El-Hoshy MS, Beshey BN, and Abdelhady AM. Fiberoptic bronchoscopic guidance in percutaneous dilatational tracheotomy. *Egyptian Journal of Chest Diseases and Tuberculosis* 2013;62: 519-27.
- Boran OF, Bilal B, Çakır D, Oksuz H, Yazar FM et al. The Effect of Flexible Lightwand and Ultrasonography Combination on Complications of the Percutaneous Dilatational Tracheostomy Procedure. *Cureus.* 2019 Jul 25;11(7):e5232.
- Rolling E, Heydenreich U, Reotman B, Hopf F, and Muhr G. Ultrasound and bronchoscopic controlled percutaneous tracheostomy on trauma ICU, *Injury* 2000;31:663-8.
- Boran ÖF, Bilal B, Bilal N, Öksüz H, Boran M, and Yazar FM. Comparison of the efficacy of surgical tracheostomy and percutaneous dilatational tracheostomy with flexible light wand and ultrasonography in geriatric intensive care patients. *Geriatr. Gerontol. Int.* 2020;20:201–205.
- Hardee PS, Ng SY, and Cashman M. Ultrasound imaging in the preoperative estimation of the size of the tracheostomy tube required in specialized operations in children. *Br J Oral Maxillofac Surg* 2003;41(5):312–16.
- Gobatto AL, Besen BA, Tierno PF, Mendes PV, Cadamuro F et al. Comparison between ultrasound- and bronchoscopy-guided percutaneous dilatational tracheostomy in critically ill patients: A retrospective cohort study *Journal of Critical Care* 2015;30:220.e13-220.e17.
- Gobatto ALN, Bruno Besen BAM, Tierno PFG, Mendes PV, Cadamuro F, et al. Ultrasound-guided percutaneous dilatational tracheostomy versus bronchoscopy-guided percutaneous dilatational tracheostomy in critically ill patients (TRACHUS): a randomized noninferiority controlled trial. *Intensive Care Med* 2016;42:342–51.

13. *Guinot PG, Zogheib E, Petiot S, Marianne JP, Guerin AM, et al.* Ultrasound-guided percutaneous tracheostomy in critically ill obese patients. *Crit Care* 2012;16:R40–7.
14. *Higgins KM and Punthakee X.* Meta-analysis comparison of open versus percutaneous tracheostomy. *Laryngoscope* 2007;117:447–54.
15. *Kaylie DM, Andersen PE, and Wax MK.* An analysis of time and staff utilization for open versus percutaneous tracheostomies. *Otolaryngol Head Neck Surg* 2003;128:109–14.
16. *Aggarwal R, Soni KD, Goyal K, Singh GP, Sokhal N, and Trikha A.* Does Real-Time Ultrasonography Confer Any Benefit During Bronchoscopy Guided Percutaneous Tracheostomy: A Preliminary, Randomized Controlled Trial. *Indian J Crit Care Med.* 2019 May;23(5):236-238.
17. *Iftikhar IH, Teng S, Schimmel M, Duran C, Sardi A and Islam S.* A Network Comparative Meta-analysis of Percutaneous Dilatational Tracheostomies Using Anatomic Landmarks, Bronchoscopic, and Ultrasound Guidance Versus Open Surgical Tracheostomy. *Lung.* 2019 Jun;197(3):267-275.
18. *Rees J, Haroon Y, Hogan C, Saha S and Derekshani S.* The ultrasound neck imaging for tracheostomy study: A study prompting ultrasound screening before percutaneous tracheostomy procedures to improve patient outcomes. *Journal of the Intensive Care Society* 2018;19(2):107–113.
19. *Yavuz A, Yilmaz M, Goya C, Alimoglu E and Kabaalioglu A.* Advantages of US in percutaneous dilatational tracheostomy: randomized controlled trial and review of the literature. *Radiology* 2014;273:927–936.
20. *Rudas M, Seppelt I, Herkes R, Hislop R, Rajbhandari D and Weisbrodt L.* Traditional landmark versus ultrasound-guided tracheal puncture during percutaneous dilatational tracheostomy in adult intensive care patients: a randomized controlled trial. *Crit Care* 2014;18:514
21. *Ravi PR and Vijay MN.* Real-time ultrasound-guided percutaneous tracheostomy: is it a better option than bronchoscopic guided percutaneous tracheostomy? *Med J Armed Forces India.* 2015; 71:158–164.
22. *Delaney A, Bagshaw SM, and Nalos M.* Percutaneous dilatational tracheostomy versus surgical tracheostomy in critically ill patients: a systematic review and meta-analysis. *Critical Care* 2013;10: R55.
23. *Mitra S, Kapoor D, Srivastava M and Sandhu H.* Real-time ultrasound-guided percutaneous dilatational tracheostomy in critically ill patients; a step towards safety. *Indian journal of critical care medicine* 2013; 17(6):367-9.
24. *Fikkers BG, Staatsen M, van den Hoogen FJ and van der Hoeven JG.* Early and late outcome after single step dilatational tracheostomy versus the guide wire dilating forceps technique: a prospective randomized clinical trial. *Intensive Care Med* 2011;37:1103–9.