

## Retropupillary Fixation of Iris-Claw Intraocular Lens versus Trans-Scleral Suturing Fixation for Aphakic Eyes without Capsular Support

Elaraby A Nassar, Adel A Othman, Mohamed K Mohamed, Ahmed M Sakr\*

Department of Ophthalmology, Faculty of Medicine, Al-Azhar University, Cairo, Egypt

\*Corresponding Author: Ahmed M. Sakr; Email: dr\_sakrol@yahoo.com

### ABSTRACT

**Background:** many reasons can lead to an aphakia without sufficient capsular support for a posterior chamber intraocular lens, such as intraoperative complications during phacoemulsification, intracapsular cataract extraction, ocular trauma and lens dislocation caused by various reasons.

**Aim of the Work:** was to compare retropupillary fixation of an iris-claw IOL (artisan aphakia lens) with transscleral suturing fixation of a posterior chamber IOL for aphakic eyes without sufficient capsular support as regards safety, visual recovery and complications of the procedure.

**Material and Methods:** this a prospective interventional case series study included a total of 45 eyes of 42 patients of the age group 13-60 years, selected from those attending the Ophthalmology Department at Al-Azhar University Hospitals according to the inclusion and exclusion criteria.

**Results:** in group A, the duration ranged from 15 to 45 min with a mean of  $30.30 \pm 6.06$  min, in group B, the duration ranged from 35 to 85 min with a mean  $60.60 \pm 12.41$  min. The P-Value was  $< 0.001$ . The IOP showed at day 1 postoperative was higher in group B  $20.06 \pm 4$  than group A  $16.40 \pm 3.9$  p value was 0.012, however IOP was nearly at the same level at the end of the follow up period  $15.23 \pm 3.63$  in group A and  $15.23 \pm 3.63$  in group B with p value 0.713.

**Conclusion:** the results of our study indicated that IC-IOL and SF-PCIOL implantations are both satisfactory in correcting aphakia without sufficient capsular support to hold an IOL in the posterior capsule.

**Keywords:** Aphakia, Iris Claw Intraocular Lenses

### INTRODUCTION

Several surgical methods of intraocular lens (IOL) implantation for eyes without sufficient capsular support have been developed. Angle-fixated anterior chamber IOL implantation is one therapeutic option and has technical advantages such as ease and minimal invasion during the surgery. However, several complications such as progressive damage of corneal endothelial cells, decompensation, chronic inflammation in the anterior chamber, secondary glaucoma, and cystoid macular edema have been reported<sup>(1)</sup>. Implantation of an iris-claw-fixated anterior chamber (IC-IOL) is another method. Early generations of iris-claw anterior chamber IOLs lacked adequate space between the IOL and iris or corneal endothelial cells, which can lead to damage to the iris or corneal endothelial cells. Later generations of iris-claw-fixated anterior chamber IOLs were developed with vaulted optic design, which can provide enough space for aqueous flow between the IOL and iris to avoid iris chafing. Because the lens was originally designed for surgical correction of phakic myopic eyes and the haptics are enclavated to the mid-peripheral iris stroma, it barely interferes with physiological movement of the pupil. This new design can reduce dispersion of iris pigment epithelium that can cause chronic ocular inflammation<sup>(2)</sup>. Previous studies have reported the efficacy of IC-IOL implantation in the anterior chamber for correction of refractive error in

aphakic eyes without adequate capsular support. However, IC IOL implantation in the anterior chamber may cause damage to the corneal endothelial cells<sup>(2)</sup>. In contrast, there have been various reports regarding the complications associated with trans scleral suturing fixation, such as ciliary choroidal body hemorrhage, vitreous prolapse into the anterior chamber, retinal detachment, IOL dislocation, uveitis, cystoid macular edema, and conjunctival erosion. Although the technique of trans scleral suturing fixation has been improved to reduce those risks associated with the surgery, most of these techniques are still complex and invasive and require extensive experience to be performed safely and in a short time period<sup>(3)</sup>. Retropupillary fixation of Artisan IOL in the posterior chamber is expected to be a less invasive and safer method of posterior chamber IOL implantation for aphakic eyes without sufficient capsular support<sup>(4)</sup>. The aim of this work is to compare retropupillary fixation of an iris-claw intraocular lens (IOL) (artisan aphakia lens) with trans scleral suturing fixation of a posterior chamber IOL for aphakic eyes without sufficient capsular support as regards safety, visual recovery and complications of the procedure.

### AIM OF THE WORK

The aim of the work was to compare retropupillary fixation of an iris-claw IOL (artisan aphakia lens) with transscleral suturing fixation of a posterior chamber IOL for aphakic eyes without

sufficient capsular support as regards safety, visual recovery and complications of the procedure.

## PATIENTS AND METHODS

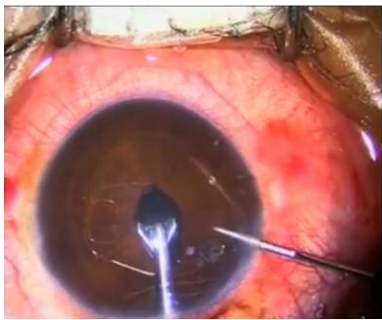
This prospective interventional case series study included a total of 45 eyes of 42 patients of the age group 13-60 years attending at the Ophthalmology Department, Al-Azhar University Hospitals. Approval of the ethical committee and a written informed consent from all the subjects were obtained. This study was conducted between July 2015 and December 2017. The 45 eyes were divided randomly into 2 groups A and B. Group A: included 25 eyes in which the iris claw lens was used, the lens used in this study was the Artisan aphakia IOL (Ophtec BV, Groningen, The Netherlands) which was a PMMA IOL with an 8.5-mm length, 1.04-mm maximum height and 5.4-mm optical zone width. Group B: included 20 eyes in which a single piece PMMA IOL (Eye-O-Care, India) was implanted. The IOL is 6 mm optic, 12.75 mm overall diameter, and has one eyelet for suture fixation in each haptic. A constant was 118.2. **Inclusion criteria:** Surgical aphakia with no capsular support, with CDVA 4/60 or better on Snellen chart including: Aphakic eyes after complicated cataract surgery, crystalline lens subluxation (Marfan syndrome, pseudoexfoliation syndrome or trauma), 2<sup>nd</sup> intervention in traumatized eyes, cases with subluxated or dislocated IOLs. **Exclusion criteria:** Surgical aphakia with decompensated corneas, aphakic patients with posterior segment pathologies like cystoid macular edema, choroidal neovascular membrane, aphakic patients with insufficient iris tissue, and rubeosis iridis, aphakic patients with intractable glaucoma. **Ophthalmic examination:** Complete ophthalmic examinations were performed to all patients including the following: A) Visual acuity: The CDVA was measured in log MAR units. B) Slit lamp biomicroscopy of the anterior segment: 1) Cornea: The cornea was examined for the presence of opacities, scars, corneal edema and keratic precipitates. 2) Anterior chamber: was examined for the presence of flare, cells or vitreous. Depth regularity and the presence of anterior synechia were checked. The angle of anterior chamber was examined using 3 mirrors gonioscopy lens. Iris and Pupil: were examined for pupil shape, reactivity, maximum dilatation, iridectomies and presence of synechia. Areas of

lens capsule or lens matter remnants and anterior vitreous face were carefully examined. C) Fundus examination: Using direct and indirect ophthalmoscope and slit lamp biomicroscopy with auxiliary lens (+90 D). D) Tonometry: The intraocular pressure was recorded pre- and postoperatively using Goldman applanation tonometer. E) Keratometric readings using autorefractometer. F) Biometry: The available optical power of the Artisan aphakia model 205 ranged from +2.0 diopters (D) to +30.0 D. The manufacturer's recommended an A-constant to be 115 for anterior chamber implantation. We used an A-constant of 116.5 and the Sanders-Retzlaff-Kraff/ T formula to calculate the IOL power for retropupillary implantation. G) Fully informed consent was obtained. IOL implantation were operated upon as a primary procedure with lens extraction or as a secondary procedure 4 weeks after the 1<sup>st</sup> one. Almost all eyes (only 3 cases under general anesthesia) were operated upon under local anesthesia (peribulbar injection of mixture of lignocaine, bupivacain and hylase). Postoperative routine medication included topical drops (combined antibiotic and steroid) given 5 times daily and tapered slowly over 4 weeks. **Group A:** Iris claw IOL: Vertical paracentesis at 9 o'clock and 3 o'clock, triamcinolone assisted anterior vitrectomy was performed before IOL insertion if required, acetylcholine chloride 1% (Miochol) was injected intracamerally, a 5.5-mm corneal incision was made at 12 o'clock position, sodium hyaluronate 1.0% (Healon) was instilled through the side port incision to maintain sufficient ACD for endothelial protection and to facilitate lens manipulation, the iris-claw IOL was then inserted upside down (with its convex surface placed posteriorly), rotated with to a horizontal position, and centered on the pupil, the optic of the reversed iris-claw IOL was held securely with a special forceps (Artisan IOL forceps) (Fig.1). Next, the two haptics were gently slid behind the iris and the optic was lifted slightly forward toward the posterior surface of the iris so that the claw configuration of the haptic could be recognized from above on the iris anterior surface, with the other hand, a long micro-spatula was used through a lateral paracentesis at either 3 or 9 o'clock based on the surgeon's non-dominant hand, to insert iris tissue into the claw.



**Fig. (1):** Artisan IOL forceps.

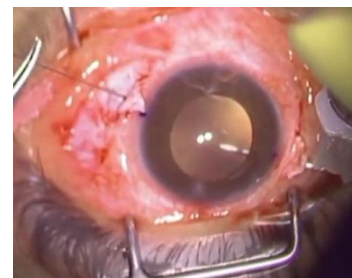
An adequate iridectomy or iridotomy was performed (if not already present) to avoid postoperative pupillary block. 10-0 nylon sutures were used to close the corneal wound. All ophthalmic viscosurgical device (OVD) material anterior to the IOL was removed after completion of the procedure. Stromal hydration of the two paracentesis. At the end of surgery, 2 mg betamethasone and 20 mg gentamicin were injected subconjunctivally.



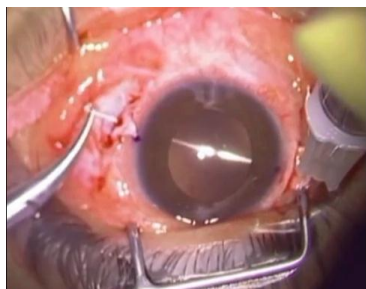
**Fig. (2):** Enclavation of the iris into the right hand side claw.

**Group B:** Scleral fixated IOL: Conjunctival peritomy at around 4 o'clock and at 10 o'clock were fashioned, followed by wet field cautery. These sites are used in most cases unless a useful capsular remnant is found; the sites were adjusted accordingly. Marking the planned site of scleral flap for better centration of the IOL. Partial thickness triangular scleral flaps were done at 10 and 4 in using Bard-Parker knife No 15 and a 45 degree crescent knife was used to facilitate flap dissection. A double armed 10/0 prolene suture on straight and curved needles is used. The straight needle is held by the needle holder and introduced 1.5 mm behind the limbus directed perpendicularly till it appeared in the pupil, parallel to the iris plane. On the other hand an -insulin syringe with 27 gauge needle bent 120 degree, is introduced in the same way till it meets the straight needle and the straight needle is driven out of the globe guided by the insulin needle. The 27 gauge needle was withdrawn carrying in its hollow the straight needle of 10/0 prolene out in the scleral bed at the desired exit site. Now, an uninterrupted 10/0 prolene thread is seen extended through the posterior chamber.

Clear corneal incision is done using microkeratome at 12 o'clock. The needle inlet and exit must be exactly in the same meridian (180 degree apart) to avoid lens decentration. Triamcinolone assisted anterior vitrectomy was performed before IOL insertion if required. The prolene suture is withdrawn from the A.C. by McPherson forceps or a Sinsky hook then divided by the scissors so we have two ends. Each of the ends of prolene suture is tied to a hole in the corresponding haptic of a PMMA IOL (Eye-O-Care, India). At this time the corneal section is enlarged to 7 mm by the microkeratome. During section enlargement, a great attention must be given not to cut the prolene suture, this better done by hooking the suture by Sinsky hook to one side of the section and enlarge in the other direction. The IOL is implanted by introducing the lower haptic first, the optic and finally the upper haptic, this is better accompanied by gentle pulling on the suture by the assistant to keep it slightly stretched guiding the haptics to the sulcus and prevents suture interlacement. The corneal section is closed by 10/0 silk suture in 3 interrupted or double figure of eight stitches. The tension on both haptics is adjusted so that the IOL is seen to be well centered. The curved needle at the lower end of the suture is grasped and passed in the sclera just near the suture exit making a loop to which the suture is tied. The knot is trimmed and the scleral flap is closed by 6/0 vicryl suture. The same is repeated in the other site after the long needle is bent to facilitate its passage in the sclera. The conjunctiva is closed with 6/0 vicryl sutures. At the end of surgery, 2 mg betamethasone and 20 mg gentamicin were injected subconjunctivally.



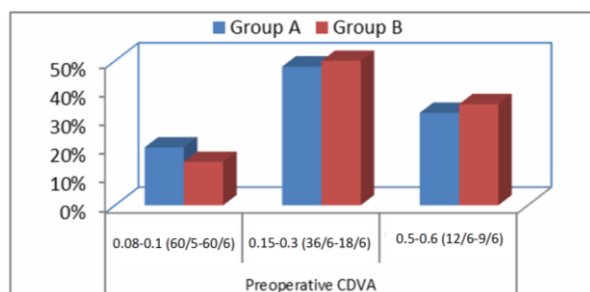
**Fig (3):** Straight needle of prolene suture and bent needle of insulin are directed towards the midpupil.



**Fig (4):** The straight needle is introduced till it meets the insulin needle.

**Post operative follow-up:** Follow up of patients was carried at the first postoperative day, at the end of the first week, at the end of the second week, at the end of the first month, at the end of the third and six months. **The following points were checked:** **1) Cornea:** was examined for edema, **2) Anterior chamber:** Was examined for the presence of flare or aqueous cells as a signs of anterior chamber reaction. **3) Intra ocular lens: Stability** of IOL was checked at the end of eye movements at the 6 cardinal directions by asking patient to look in different gaze direction and observing the IOL if it is tremulous or stable. **Decentration:** Intraocular pressure measurement, Refraction and k readings, visual Acuity, posterior segment examination for: a) Vitreous hemorrhage, b) CME, c) Retinal detachment. **Statistical Methodology:** Recorded data were analyzed using the statistical package for social sciences, version 20.0 (SPSS Inc., Chicago, Illinois, USA). Quantitative data were expressed as mean± standard deviation (SD). Qualitative data were expressed as frequency and percentage. The p-value was considered significant as the following: Probability (P-value), p-value <0.05 was considered significant, p-value <0.001 was considered as highly significant, p-value >0.05 was considered insignificant.

## RESULTS



**Fig (5):** Preoperative corrected distance visual acuity.

**Table (1):** Duration of surgery (min) in both groups

Duration of surgery (min)	Group A (N=25)	Group B (N=20)	t-test	p-value
Range	15-45	35-85	9.812	<0.001**
Mean±SD	30.30±6.06	60.60±12.41		

\*\*P-value <0.001 highly significant

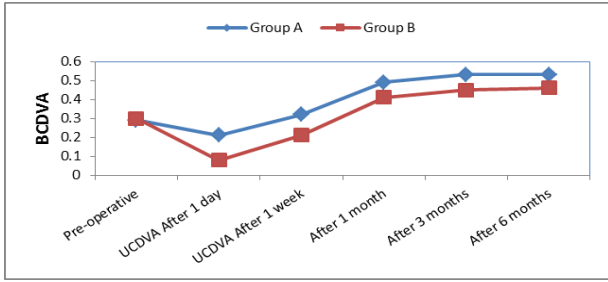
**Table (1):** shows the operative data: **Duration of surgeries.** This table shows highly statistically significant difference between groups according to the duration of surgery where the time in group B was nearly double that in group A.

**Table (2):** Comparison between groups according to CDVA

CDVA	Group A (N=25)	Group B (N=20)	t-test	p-value
Pre operative	0.29±0.06	0.30±0.07	0.48 5	0.634
Posoperative				
CDVA After 1 day	0.21±0.07 #	0.08±0.03 #	7.63 4	<0.001* *
CDVA After 1 week	0.32±0.10 #	0.21±0.07 #	2.19 8	0.034*
After 1 month	0.49±0.15 #	0.41±0.13 #	1.80 2	0.079
After 3 months	0.53±0.16 #	0.45±0.14 #	1.68 3	0.101
After 6 months	0.53±0.16 #	0.46±0.14 #	1.47 2	0.149

\* P-value <0.05 significant; \*\*p-value <0.001 highly significant  
# Significant difference from pre-operative, using Paired Sample t-test

The postoperative corrected distance visual acuity (CDVA) was measured in the first postoperative day, first week, first month, after 3 and 6 months and the results were as follows (table 6, Fig.19, 20). There was a statistically significant difference between groups according to CDVA after 1 day and after 1 week. The CDVA was better in group A than group B in the 1st week post-operative, also during the 1st week CDVA was dropped below the preoperative level in both groups then became better after the 1st month.



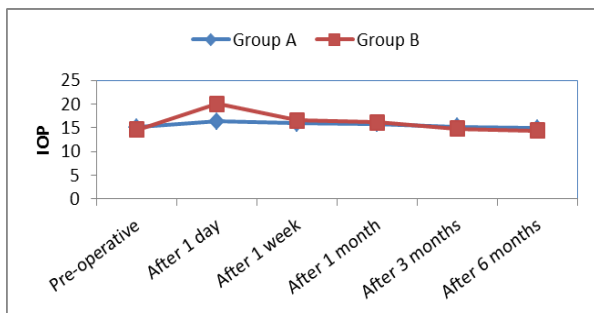
**Fig (6):** Line chart between groups showing that CDVA was better than the preoperative value in both groups with slightly higher level in group A.

**Table (3):** Comparison between groups according to IOP

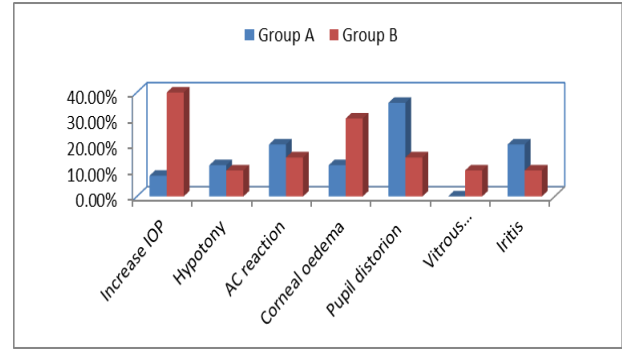
Mean IOP	Group A (N=25)	Group B (N=20)	t-test	p-value
Pre operative	15.10±3.60	14.60±3.48	0.447	0.658
Posoperative				
After 1 day	16.40±3.91#	20.06±4.78#	2.654	0.012*
After 1 week	15.94±3.80#	16.59±3.95#	0.530	0.599
After 1 month	15.86±3.78#	16.17±3.85#	0.257	0.798
After 3 months	15.23±3.63	C	0.371	0.713

\* P-value <0.05 significant  
#significant difference from pre-operative, using Paired Sample t-test

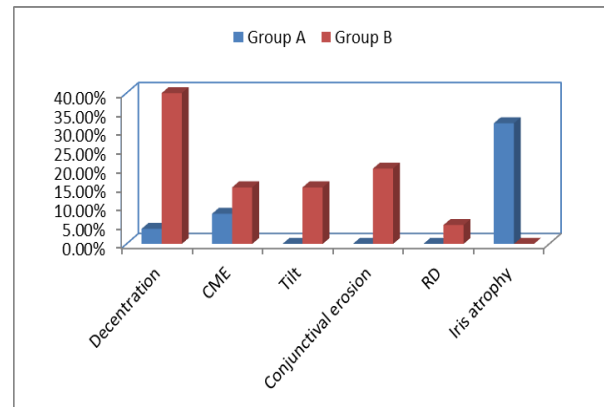
This table shows statistically significant difference between groups according to IOP where, at day 1 postoperative with higher level in group B, however IOP was nearly at the same level at the end of the follow up period.



**Fig (7):** Line chart explaining IOP difference between both groups.



**Fig (8):** Bar chart explaining early postoperative complications in both groups



**Fig (9):** Comparison between groups as regard to late complications.

**DISCUSSION**

In this study, 45 eyes of 42 patients (three patients were bilateral) were included. Artisan aphakic iris claw lenses were implanted retro pupillary in 25 eyes (Group A) while single piece PMMA IOLs with one eyelet in each haptic (for scleral fixation) were implanted in 20 eyes (Group B). In this series, 28 eyes (62.23%) were aphakic after cataract surgery with accidental rupture of posterior capsule during operation, with inadequate capsular support for IOL implantation. Six eyes (13.33%) were aphakic after I.C.C.E (which is performed due to lens subluxation). Four eyes (8.89%) were having traumatic cataract with posterior capsule tears that hindered primary implantation and seven (15.55) cases with IOL subluxation. In the present study the mean surgical time in the artisan IOL group (30.30 ± 6.06 min) was significantly shorter than that in the scleral fixation group of (60.60 ± 12.41 min) (P value < 0.001\*\*). *Hara et al.* (5) stated similar results. He said that the mean surgical time in the artisan IOL group (20.0±8.9 min) was significantly shorter than

that in the scleral fixation group ( $49.7 \pm 18.9$  min) ( $P < 0.0001$ ). **The mean CDVA** significantly deteriorated 1 day after surgery in the scleral fixation group compared with preoperative CDVA. This presumably occurred due to ciliary choroidal body hemorrhage and high IOP from invasive manipulation. Most of eyes undergoing retropupillary fixation of the Artisan IOL showed no decrease in CDVA 1 day postoperatively. In eyes undergoing implantation of the scleral fixed IOL, mean postoperative CDVA recovered to the preoperative level in 1 week. The retropupillary fixation of the Artisan IOL showed earlier visual recovery and fewer complications than scleral fixation of the posterior chamber IOL. Similar results were reported by *Hara et al.*<sup>(5)</sup> with no statistically significant changes in CDVA (log-MAR) the RPIC IOL group at each examination point before and after surgery: preoperative  $0.49 \pm 0.46$ , 1 day  $0.61 \pm 0.39$ , 1 week  $0.41 \pm 0.21$ , 2 weeks  $0.32 \pm 0.21$ , 1 month  $0.35 \pm 0.26$ , and 6 months  $0.28 \pm 0.28$ . In the transscleral suturing fixation group, CDVA at postoperative day 1 ( $0.97 \pm 0.84$ ) was statistically significantly worse than preoperative CDVA ( $0.41 \pm 0.41$ ) ( $P < 0.05$ ) and recovered at postoperative week 1 ( $0.59 \pm 0.33$ ) compared to the preoperative level. *Rao and Sasidharan*<sup>(6)</sup> performed posterior iris claw lenses for aphakic cases. They reported visual outcome at 6 months. Majority, i.e. 80% of patients, had visual acuity of 20/40 (Decimal 0.5) or better. **The mean IOP** at the first day postoperative was ranged in group A from 12 to 21 with a mean of  $16.40 \pm 3.91$  mmHg; in group B it ranged from 14 to 28 with a mean of  $20.06 \pm 4.78$  mmHg with statistically significant difference between the groups ( $P = 0.012^*$ ). This rise in IOP was attributed to postoperative iridocyclitis and residual viscoelastic substance. All cases responded to topical steroids and topical antiglaucoma medications. Three months postoperative, the IOP in group A ranged from 13 to 20 with a mean of  $15.23 \pm 3.63$  mmHg, in group B it ranged from 12 to 18 with a mean of  $14.81 \pm 3.53$  mmHg with no statistically significant difference between the groups ( $P = 0.019$ ). Consistent with our results *Hara et al.*<sup>(5)</sup> stated that mean preoperative IOP showed no significant differences between groups (Verisyse IOL  $14.8 \pm 2.2$  mmHg and scleral fixation group  $13.9 \pm 3.5$  mmHg), IOP at postoperative day 1 in the scleral fixation group ( $20.2 \pm 7.4$  mmHg)

was statistically significantly higher than the Verisyse IOL group at the same time period ( $13.3 \pm 3.9$  mmHg) ( $P = 0.0126$ ). No significant differences were noted in mean IOP between the Verisyse IOL and scleral fixation groups at 1 week ( $15.2 \pm 5.8$  and  $14.7 \pm 7.7$  mmHg), 2 weeks ( $14.3 \pm 4.9$  and  $13.5 \pm 3.7$  mmHg), 1 month ( $16.0 \pm 2.8$  and  $12.4 \pm 3.4$  mmHg), and 6 months ( $15.5 \pm 2.1$  and  $13.7 \pm 1.9$  mmHg), respectively. Compared to our study; *Jose' et al.*<sup>(7)</sup> stated that an elevated intraocular pressure probably steroid induced, was found in 3 eyes (18.75%) after secondary Artisan lens implantation during the first 6 weeks after surgery. Once the steroids were discontinued, IOP decreased to normal values. **With regard to complications in this work:** Mild anterior chamber reaction occurred in 5 (20.0%) eyes with iris claw group and 3 (15.0%) eyes in scleral fixation group. These results are comparable with the results obtained by *Hazar et al.*<sup>(8)</sup> who reported 5 (20.8%) cases after retropupillary iris fixed IOL and 3 (9.6%) cases after scleral fixed IOL implantation. No significant difference was found between the groups in terms of incidence of anterior chamber reaction. Transient corneal oedema occurred in 3 (12.0%) cases in group A and 6 (30.0%) in group B. *Hazar et al.*<sup>(8)</sup> also reported a similar results with lower rate of corneal oedema, 1 (4.1%) in retropupillary iris claw group than in scleral fixation group 3 (9.6%). Persistent pupillary distortion occurred in 9 (36.0%) cases in retropupillary iris claw group and 3 (14.3%) cases in scleral fixation group at the last follow-up. This high rate of pupillary distortion in group A was rendered to the high number of irregular pupils preoperatively. *Baykara et al.*<sup>(9)</sup> found persistent pupil ovalization after posterior iris claw IOL implantation in 12.7% of eyes. *Gonnermann et al.*<sup>(10)</sup> also recorded that persistent pupil ovalization was documented in 19 eyes (13.9%) in retro pupillary iris claw group. *Luk et al.*<sup>(11)</sup> reported 2 (1.9%) cases of drawn up pupil during his study on scleral fixed IOL. In contrast to our results *Hazar et al.*<sup>(8)</sup> has reported 4 (12.9%) cases of pupillary distortion in scleral fixation group while 0 (0%) cases in retropupillary iris claw group. In the present study, no postoperative haemorrhage occurred in the iris claw group, whereas ciliary body haemorrhage was seen in 2 (10.0%) of eyes in the scleral fixation group. Bleeding typically occurred during needle passage.

Vitrous haemorrhage was mild and was completely resolved. *Almashad et al.*<sup>(12)</sup> reported three (20%) cases of vitrous haemorrhage with scleral fixed IOL. Our results were comparable to the results obtained by *Hara et al.*<sup>(5)</sup> who recorded no cases of haemorrhage in the Verisyse IOL group, whereas ciliary choroidal body haemorrhage was seen in 20% of eyes in the SuperFlex620H scleral fixation and 33% of eyes in the CP60NS scleral fixation group. *Hazar et al.*<sup>(8)</sup> reported 1 (4.1%) cases of haemorrhage in retropupillary iris claw cases while they reported 2 (6.4%) eyes of vitrous haemorrhage in scleral fixation cases. In this work, CME was found in 2 patients (8.0%) of retropupillary iris claw cases and in 3 patients (15.0%) of scleral fixation cases. These patients underwent extensive anterior vitrectomy during the operation. They developed gradual deterioration of vision after initial improvement and the condition was confirmed by optical coherence tomography (OCT macula). It was managed by topical treatment (steroidal and non steroidal anti-inflammatory eye drops), oral Dimox with good improvement. *Almashad et al.*<sup>(12)</sup> reported no cases of CME in scleral fixed IOL. *Hara et al.*<sup>(5)</sup> also recorded no cases of CME in the Verisyse IOL group, and 1(3.2%) case in the scleral fixation group. *Gonnermann et al.*<sup>(10)</sup> reported 12 (8.7%) cases of CME in retropupillary iris claw cases. The previous studies were conducted in a larger groups of patients. In this work, decentration was observed in one (4.0%) cases of retropupillary iris claw group and 8 (40.0%) cases of scleral fixation group. However decentration was mild to moderate in the majority of cases and has no effect on the visual outcome. *Perz et al.*<sup>(13)</sup> reported 2 (4.8 %) of IOL decentration in iris fixated Worst claw group while they reported 2 (15.3%) in sutured sulcus-fixated PC lens group. *Durak et al.*<sup>(14)</sup> reported decentration greater than 1.0 mm in 7 eyes (16.7%) after secondary implantation and in 1 eye (7.1%) after primary implantation of scleral fixed IOL. In this work, suture erosion through the conjunctiva was found in 4(20%) group B. These results are similar to *Gonnermann et al.*<sup>(10)</sup>, *Hara et al.*<sup>(5)</sup> and *Rao et al.*<sup>(26)</sup> who had reported 4(20.0%) case of knot erosion in group B in spite of covering the suture by scleral flaps<sup>(10), (5), (6)</sup>. On the other hand *Almashad et al.*<sup>(12)</sup> reported no case of erosion as they were doing four point scleral fixation of posterior chamber IOL. The cases of

erosion in this study were treated by trimming of the suture with application of cautery to its free ends and covered again by the conjunctiva. No cases of IOL dislocation were recorded in either group. *Almashad et al.*<sup>(12)</sup> reported no case of IOL dislocation after scleral fixed IOL. Our results were consistent with the results obtained by *Hara et al.*<sup>(5)</sup> and *Rao et al.*<sup>(26)</sup> who reported 0(0%) case of dislocation after retropupillary iris claw IOL implantation and only 1(5.8%) after scleral fixed IOL implantation<sup>(5,6)</sup>. While *De Silva et al.*<sup>(15)</sup> reported 2 (1.7%). *Gonnermann et al.*<sup>(10)</sup> reported 12(8.7%) of haptic dislocation after iris claw IOL implantation. This may be attributed to the younger age group of patients and a different type of ICIOL used in their study. In this work no cases of retinal detachment was recorded in group A, but only one case was recorded 2 months post operatively in group B and was referred for the vitreoretinal unit. Vitrectomy with silicon oil injection was done and good improvement was obtained. Comparable results were obtained by *Ohta et al.*<sup>(16)</sup> who reported 2 (5%) cases of retinal detachment after sutured scleral fixation. In this case series no cases of iris atrophy was recorded in group B, but 8 cases (32.0%) in group A had variable degrees of iris atrophy at the enclavation site. In all cases no effect on the final visual outcome was noted. *Forlini et al.*<sup>(17)</sup> reported iris atrophy only in (5.0%) of cases on long term follow up period of 7 years.

## CONCLUSION

The results of our study indicated that IC-IOL and SF-PCIOL implantations are both satisfactory in correcting aphakia without sufficient capsular support to hold an IOL in the posterior capsule. Iris-Claw IOLs have now matured to a stage that they can be used with considerable safety and efficacy. The new designs as well as the evolution of surgical techniques and instrumentation have made them an impressive option for primary or secondary implantation in aphakic eyes. The surgical procedure is easier, shorter and safer than those used for scleral sutured IOLs. The retropupillary placement has the advantages of a true posterior chamber IOL with low intra- and postoperative complications and short learning curve. We can believe that it is a better option than a scleral-fixated or an angle-fixated IOL. However placement of a SFIOL remains the only option for patients whose eyes lack both iris and capsular support.

## CONFLICTS OF INTEREST

There are no conflicts of interest.

## REFERENCES

1. Kirby DB (1999): Procedures in intracapsular cataract extraction: a new method. Transactions of the American Ophthalmological Society, 39:150-7.
2. Tarbet KJ, Mamalis N, Theurer J, Jones BD, Olson RJ (1995): Complications and results of phacoemulsification performed by residents. Journal of Cataract & Refractive Surgery, 21(6):661-5.
3. Mohr A, Hengerer F, Eckardt C (2002): Retropupillary fixation of the iris claw lens in aphakia. 1 year outcome of anew implantation technique. Der Ophthalmologe: Zeitschrift der Deutschen Ophthalmologischen Gesellschaft, 99(7):580-3.
4. Teng H & Zhang H (2014): Comparison of Artisan iris-claw intraocular lens implantation and posterior chamber intraocular lens sulcus fixation for aphakic eyes. International Journal of Ophthalmology, 7(2): 283.
5. Hara S, Borkenstein AF, Ehmer A, Auffarth GU (2011): Retropupillary fixation of iris-claw intraocular lens versus transscleral suturing fixation for aphakic eyes without capsular support. Journal of Refractive Surgery, 27(10):729-35.
6. Rao R, Sasidharan A (2013): Iris claw intraocular lens: a viable option in monocular surgical aphakia. Indian Journal of Ophthalmology, 61(2):74.
7. José L, Guéll L, Fortino V, Francois M, Mercedes V, Oscar G, Felicidad M (2005): Secondary Artisan-Versysaphakic lens implantation. J Cataract Refract Surg., 31:2266–2271.
8. Hazar L, Kara N, Bozkurt E, Ozgurhan EB, Demirok A (2013): Intraocular lens implantation procedures in aphakic eyes with insufficient capsular support associated with previous cataract surgery. Journal of Refractive Surgery, 29(10):685-91.
9. Baykara M, Ozcetin H, Yilmaz S, Timuçin ÖB (2007): Posterior iris fixation of the iris-claw intraocular lens implantation through a scleral tunnel incision. American Journal of Ophthalmology, 144(4):586-91.
10. Gonnermann J, Torun N, Klamann MK, Maier A-KB, Sonnleithner CV, Jousseaume AM *et al.* (2013): Visual outcomes and complications following posterior iris-claw aphakic intraocular lens implantation combined with penetrating keratoplasty. Graefes Archive for Clinical and Experimental Ophthalmology, 251(4):1151-6.
11. Luk AS, Young AL, Cheng LL (2013): Long-term outcome of scleral-fixated intraocular lens implantation. British Journal of Ophthalmology, 303-325.
12. Almashad GY, Abdelrahman AM, Khattab HA, Samir A (2010): Four-point scleral fixation of posterior chamber intraocular lenses without scleral flaps. British Journal of Ophthalmology, 94(6):693-5.
13. Pérez-Torregrosa VT, Menezes JL, Harto MA, Maldonado MJ, Cisneros A (1995): Digital system measurement of decentration of Worst-Fechner iris claw myopia intraocular lens. Journal of Refractive Surgery, 11(1):26-66.
14. Durak A, Oner HF, Koçak N, Kaynak S (2001): Tilt and decentration after primary and secondary transsclerally sutured posterior chamber intraocular lens implantation. Journal of Cataract & Refractive Surgery, 27(2):227-32.
15. De Silva SR, Arun K, Anandan M, Glover N, Patel CK, Rosen P (2011): Iris-claw intraocular lenses to correct aphakia in the absence of capsule support. Journal of Cataract & Refractive Surgery, 37(9):1667-72.
16. Ohta T, Toshida H, Murakami A (2014): Simplified and safe method of sutureless intrascleral posterior chamber intraocular lens fixation: Y-fixation technique. Journal of Cataract & Refractive Surgery, 40(1):2-7.
17. Forlini M, Soliman W, Bratu A, Rossini P, Cavallini GM, Forlini C (2015): Long-term follow-up of retropupillary iris-claw intraocular lens implantation: a retrospective analysis. BMC Ophthalmology, 15(1):143.